Google

This is a digital copy of a book that was preserved for generations on library shelves before it was carefully scanned by Google as part of a project to make the world's books discoverable online.

It has survived long enough for the copyright to expire and the book to enter the public domain. A public domain book is one that was never subject to copyright or whose legal copyright term has expired. Whether a book is in the public domain may vary country to country. Public domain books are our gateways to the past, representing a wealth of history, culture and knowledge that's often difficult to discover.

Marks, notations and other marginalia present in the original volume will appear in this file - a reminder of this book's long journey from the publisher to a library and finally to you.

Usage guidelines

Google is proud to partner with libraries to digitize public domain materials and make them widely accessible. Public domain books belong to the public and we are merely their custodians. Nevertheless, this work is expensive, so in order to keep providing this resource, we have taken steps to prevent abuse by commercial parties, including placing technical restrictions on automated querying.

We also ask that you:

+ *Make non-commercial use of the files* We designed Google Book Search for use by individuals, and we request that you use these files for personal, non-commercial purposes.

+ *Refrain from automated querying* Do not send automated queries of any sort to Google's system: If you are conducting research on machine translation, optical character recognition or other areas where access to a large amount of text is helpful, please contact us. We encourage the use of public domain materials for these purposes and may be able to help.

+ *Maintain attribution* The Google "watermark" you see on each file is essential for informing people about this project and helping them find additional materials through Google Book Search. Please do not remove it.

+ *Keep it legal* Whatever your use, remember that you are responsible for ensuring that what you are doing is legal. Do not assume that just because we believe a book is in the public domain for users in the United States, that the work is also in the public domain for users in other countries. Whether a book is still in copyright varies from country to country, and we can't offer guidance on whether any specific use of any specific book is allowed. Please do not assume that a book's appearance in Google Book Search means it can be used in any manner anywhere in the world. Copyright infringement liability can be quite severe.

About Google Book Search

Google's mission is to organize the world's information and to make it universally accessible and useful. Google Book Search helps readers discover the world's books while helping authors and publishers reach new audiences. You can search through the full text of this book on the web at http://books.google.com/


LANE MEDICAL LIBRARY STANFORD
2 45 0175 6683

LANE
MEDICAL LIBRARY
Library
Dr. Tracy G. Russell



TREATISE
ON
FRACTURES

BY

JOHN B. ROBERTS, A.M., M.D., F.A.C.S.

PROFESSOR OF SURGERY IN THE PHILADELPHIA POLYCLINIC AND COLLEGE FOR GRADUATES IN MEDICINE; SOMETIME CHAIRMAN OF FRACTURE COMMITTEE OF AMERICAN SURGICAL ASSOCIATION; MEMBRE DE LA SOCIÉTÉ INTERNATIONALE DE CHIRURGIE

AND

JAMES A. KELLY, A.M., M.D.

ATTENDING SURGEON TO ST. JOSEPH'S, ST. MARY'S AND ST. TIMOTHY'S HOSPITALS; ASSOCIATE IN SURGERY IN THE PHILADELPHIA POLYCLINIC AND COLLEGE FOR GRADUATES IN MEDICINE

WITH 909 ILLUSTRATIONS:
RADIOGRAMS, DRAWINGS AND PHOTOGRAPHS

PHILADELPHIA & LONDON
J. B. LIPPINCOTT COMPANY

Copyright 1916, by J. B. Lippincott Company

Electrotyped and printed by J. B. Lippincott Company
The Washington Square Press, Philadelphia, U. S. A.

R64
1916

PREFACE

THE object of this book is to supply student and medical practitioner with a clear, concise, and systematic presentation of the subject of fractures.

In the following pages, a careful classification of the varieties of fracture occurring in each bone is given, together with statistics, symptomatology, diagnosis, prognosis and treatment. The varieties of fracture are shown by well-selected radiograms, the displacement of fragments is illustrated by accurate drawings, and when possible the methods of reduction and the application of retentive apparatus is presented by photographs.

The universal use of the Röntgen ray as a means of accurate diagnosis has brought about greater success in the recognition of fractures and has shown that many received methods of treatment are faulty or imperfectly understood. As a result, many fractures have been operated upon in which good anatomical and functional results could have been obtained by more conservative measures.

The purpose of the authors is to present a lucid view of the subject in the light of recent discoveries, to point out an accurate scientific procedure, whether operative or otherwise, according to the character of individual injuries and to urge the general practitioner, as well as the surgical specialist, to the study of methods, operative or non-operative, with augury of propitious result.

The authors are indebted to Drs. M. B. Miller, J. H. Jopson, G. G. Davis, G. P. Müller, J. H. Hutchinson, J. M. Spellissy, L. J. Hammond, J. T. Rugh, E. R. Kirby, J. H. Ross, J. A. Boger, A. C. Wood, H. S. Carmany, A. Hewson, O. A. Rath, J. Chalmers Da Costa, C. F. Nassau, M. M. Franklin, J. F. X. Jones, A. A. Sender, F. C. Hutton, and M. F. Percival, for many röntgenograms.

The photographs of specimens, patients, dressings and copies of skiagrams were made by Mr. Meyer S. Lentz, the original drawings

80026

[redacted]

THE object [redacted]
ioner with a [redacted]
fractures.

In the [redacted]
acture occurring [redacted] 112
matology, diagnosis [redacted] 251
ire are shown by [redacted] 255
agments is illustrated [redacted] 264
ethods of reduction [redacted] 278
resented by photographs [redacted] 290
The universal use [redacted] 353
liagnosis has brought [redacted] 417
tures and has shown [redacted] 422
faulty or imperfectly [redacted] 431
been operated upon [redacted] 435
could have been obtained [redacted] 457
The purpose [redacted] 525
in the light of recent [redacted] 540
procedure, whether [redacted] 599
of individual injuries [redacted] 622
the surgical specialist [redacted] 629
operative, with [redacted] 631
The authors [redacted] 638
G. P. [redacted] 646

by Mr. Erwin F. Faber, to both of whom the authors are grateful for skill, patience and untiring energy.

In all instances an endeavor has been made to give proper credit in the text and illustrations to the work of other writers.

Finally they wish to thank the publishers for many helpful suggestions and active coöperation in the presentation of this volume to the medical profession in such an attractive form.

JOHN B. ROBERTS
JAMES A. KELLY

Philadelphia,
January, 1916.

CONTENTS

I. General Considerations 1
II. The Operative Treatment of Closed Fractures 85
III. Fractures of the Cranium 116
IV. Fractures of the Bones of the Face 172
V. Fractures of the Malar Bone 180
VI. Fractures of the Superior Maxilla 185
VII. Fractures of the Mandible 188
VIII. Fractures of the Hyoid Bone 205
IX. Fractures of the Cartilages of the Larynx and Trachea 208
X. Fractures of the Vertebræ 212
XI. Fractures of the Sternum 251
XII. Fractures of the Ribs and the Costal Cartilages 255
XIII. Fractures of the Clavicle 264
XIV. Fractures of the Scapula 278
XV. Fractures of the Humerus 290
XVI. Fractures of Radius and Ulna 353
XVII. Fractures of the Carpal Bones 417
XVIII. Fractures of the Metacarpal Bones 422
XIX. Fractures of the Phalanges 431
XX. Fractures of the Pelvis 435
XXI. Fractures of the Femur 457
XXII. Fractures of the Patella 525
XXIII. Fractures of the Tibia and Fibula 540
XXIV. Fractures of the Tarsal Bones 599
XXV. Fractures of the Metatarsal Bones 622
XXVI. Fractures of the Phalanges of the Foot 629
XXVII. Fractures of the Small Sesamoid Bones 631
XXVIII. Birth Fractures 638
XXIX. Gunshot Fractures 646

ILLUSTRATIONS

FIG.		PAGE
1.	Osteomyelitis (typhoid) of femur	9
2.	Sarcoma of right humerus	9
3.	Pathologic fracture of right femur	10
4.	Pathologic fracture of right humerus	10
5.	Types of fractures	12
6.	Fractures considered in relation to the character and line of fracture	13
7.	Fractures considered in relation to the position of the fracture	14
8.	Articular fractures	14
9.	Fractures considered in relation to the number of fragments	15
10.	Varieties of displacement of fragments	16
11.	Röntgenogram showing pseudarthrosis of radius and ulna	26
12.	Pseudarthrosis following open fracture of radius and ulna, operated upon twice	27
13.	Vicious union	28
14.	Röntgenogram showing diacondylar fracture of humerus	29
15–16.	Moist gangrene of hand and part of forearm	30
17.	Ischæmic muscular atrophy	31
18.	The same after operation	31
19.	Ischæmic muscular atrophy	32
20.	The same after operation	32
21.	Epiphyseal lines of upper end of right humerus	40
22.	Epiphyseal lines and centre of lower end of humerus, and upper ends of radius and ulna	41
23.	Epiphyseal lines and centres of lower ends of radius, carpal, metacarpal and phalyngeal bones of hand	42
24.	Epiphyseal lines of pelvis and upper end of femur	43
25.	Epiphyseal line of crest of ileum	44
26.	Epiphyseal lines and centres of lower end of femur, patella, and upper ends of tibia and fibula	45
27.	Epiphyseal lines and centres of lower end of tibia and fibula, and of calcaneum	46
28.	Epiphyseal lines and centres of metatarsal and phalyngeal bones of foot	47
29.	Interference with subsequent growth of the fourth metacarpal following a previous epiphyseal separation	50
30.	Method of making moulded gypsum splints	65
31.	Moulded gypsum shoulder-cap	66
32–34.	Method of using gypsum bandages in treating fracture of the clavicle	66
35.	Gypsum case applied over flannel bandage for fracture of shafts of both bones of forearm	67
36.	Moulded gypsum splint for fracture of shaft of radius or of ulna	67
37.	Anterior and posterior gypsum splints for fracture of lower end of radius	67
38.	Method of applying gypsum splints by means of muslin bandage	67
39.	Moulded gypsum splint for fracture of first metacarpal	68
40.	Circular gypsum case for fracture of carpal bones or of first metacarpal	68
41.	Method of holding lower extremity for application of circular gypsum case in treatment of fracture of bones of leg	69
42.	Finished gypsum case applied to lower thigh, leg, and foot	69
43–44.	Moulded gypsum splints for fractures about the ankle-joint	70

FIG. PAGE
45. Moulded gypsum splint for fracture of the metatarsal bones..... 71
46. Method of applying traction to leg and thigh. The Buck's extension apparatus 72
47. Bardenheuer's method of extension..... 73
48. Thos. Bryant's method of vertical traction..... 74
49. Oblique traction used for subtrochanteric fracture of femur..... 74
50. Steinmann's method of nail extension..... 75
51. Steinmann's method of nail extension for fracture of the femur..... 76
52. Zuppinger's method of traction and support for fracture of the femur..... 77
53. Zuppinger's method of traction and support for fracture of the bones of the leg 78
54. This figure illustrates the control of the leg in plating fractures, on applying gypsum case, using Dr. Hawley's table..... 90
55. Flexion and abduction of the thigh in the treatment of subtrochanteric fractures of the femur..... 90
56. Subject with legs in extreme abduction, the Whitman position for the treatment of fracture of the neck of the femur..... 91
57. Support and traction of the left arm with counter-traction by a wide sling around the body..... 92
58. Traction with pulleys and Levis's plate during operative fixation of old femoral fracture..... 92
59. Fixation with two wire sutures of aluminum opposite planes..... 93
60. Low fracture of surgical neck of right humerus..... 93
61. Application of Lane plate in low fracture of surgical neck of right humerus..... 93
62–65. Fracture of internal condyle of humerus..... 94
66–69. Fractures of middle of shaft of radius and ulna..... 95
70–72. Result of operation in case of fracture of shafts of radius and ulna 96
73. Lane's bone plate 97
74. Subtrochanteric fracture of left femur..... 98
75. Lowman's cone clamp for adjusting plate; Pierce's bone screw holder and screw driver; Sherman's tap screws..... 98
76–77. Spiral fracture of shaft of right femur..... 99
78–79. Transverse fracture of shaft of femur..... 100
80. Oblique fracture of shaft of left femur; moderate overlapping of fragments..... 101
81. Oblique fracture of shaft of left femur; application of Sherman plate..... 101
82–82*a*. Photographs of above patient taken after eight weeks..... 101
83–84. Separation of lower epiphysis of femur..... 102
85–86. Closed fractures of shafts of tibia and fibula..... 102
87–88. Communited fractures of tibia and fibula..... 103
89–90. Application of Lane plate and screws followed by moderate necrosis of ends of fragments..... 103
91–92. Lane plate and screws removed, beginning union..... 104
93–94. Final results. No shortening, good function..... 104
95–96. Oblique fractures of shafts of tibia and fibula..... 105
97–98. Application of Lane plate and screws to tibia..... 105
99–100. Final result in fracture of tibia and fibula after application of Lane plate and screws..... 106
101–102. Open oblique fractures of tibia and fibula..... 107
103–104. Result obtained after reduction and immobilization in gypsum case..... 108
105–106. Osteotomy for malunion..... 108
107–108. Closed fracture of shaft of the tibia, followed by an acute suppurative osteomyelitis..... 109
109–110. Photographs of Figs. 107 and 108 showing shortening, deformity and muscular atrophy..... 110

FIG. PAGE
111. (*a*) Albee's electric twin saw used in removing transplant from tibia and for cutting groove in the fractured bone; (*b*) Albee's dowel cutter 111
112. Albee's method of inlay bone graft for fixation of fractures 112
113–114. Open ununited fractures of tibia and fibula 113
115–116. Inlay bone graft in place in tibia 113
117. Front view of skull 117
118. Lateral view of skull 118
119. Craniocerebral localization 119
120. The inner surface of the base of the skull 120
121. Calvarium; transverse fracture of the vault 122
122. Skull. Fracture of the base 122
123. Skull without calvarium; fracture of the right temporal and parietal bones ... 122
124. Röntgenogram showing fissured fracture of cranium 123
125. Fissured fracture of vault of skull, occipital region 123
126. Comminuted fracture of skull, frontal region 124
127. Skull; lower half; fracture of the base 124
128. Skull; extensive fracture involving the right parietal, frontal, temporal, occipital and sphenoid bones 124
129–130. Calvaria. Fracture of the right parietal bone 125
131–132. Fracture of skull left parietal region—epidural hemorrhage 126
133. Skull; fracture of the superior angle of the occipital bone with fracture of both temporal bones in horizontal line separating the squamous from the mastoid portions and passing through the auditory canals 127
134. Röntgenogram showing depressed comminuted fracture of skull, parietal region 128
135. *a* and *b*. Calvarium; fracture of the right parietal, compound comminuted, and depressed. 128
136. Calvarium; depression of the right parietal 129
137. Calvarium; depressed fracture of the left parietal bone 5.5 cm. long in the left parietal bone parallel to the interparietal suture 129
138. Anterior half of calvarium. Punctured fracture at three points with depression of the internal table 129
139. Calvarium; fracture of left frontal and both parietals 129
140. Diagrammatic illustration showing effects of a perforating bullet wound of skull and brain 130
141. Gunshot wounds of head with fractures of skull 131
142. Base of brain case with two probes indicating direction of bullets 131
143. Fracture of the base of the skull by transmitted force applied to the lower jaw 133
144. Line of fracture of base, from force applied to the median frontal region 135
145. Line of fracture of base, from force applied to the lateral frontal region 135
146. Lines of fracture of base, from force applied in the region of the external ear. 136
147. Line of fracture of base, from force applied in the region of the mastoid 136
148. Line of fracture of base, from force applied to the lateral occipital region 137
149. Lines of fracture of the base from force applied to the posterior occipital region 137
150. Fracture of the base with laceration of the carotid arteries 140
151. Fracture of the base with laceration of the cavernous sinus 140
152. Shows position of cranial nerves and their liability to laceration in various fractures at the base of the skull 143
153. Cerebral pressure from an extradural clot from hemorrhage from the posterior branch of the middle meningeal artery 143
154. Krönlein's method for points of election for trephining in meningeal hemorrhage 145
155. Temperature chart showing primary shock in fracture of base with subsequent rise to normal 149

FIG. PAGE
156. Temperature chart showing primary shock in fracture of base with subsequent rise and later return to normal 150
157. Temperature chart showing rapid and progressive rise of temperature in fracture of the base followed by death fourteen hours after admission 151
158. Chart showing moderate elevation of temperature which remains stationary followed by recovery 151
159. Temperature chart showing moderate rise followed by fall to below normal, ending fatally 152
160. Temperature chart in a case of fracture of the base and marked laceration of the brain, showing variable temperature changes ending in ultimate recovery 153
161. Method of trephining with the Hudson instruments. After exposure of the site of the fracture the skull may be opened at the site of depression 163
162. Hudson's trephine bits, showing the use of the spiral perforator, the spiral follower and the enlarging burr 163
163. Removing a button of bone at the edge of the depressed fracture by means of the hand trephine 164
164. Elevating depressed fragment of bone after trephine opening has been made ... 164
165. Showing method of exposure of anterior and posterior branches of the middle meningeal artery at the points of election 165
166. Showing method of enlarging trephining openings at points of election to reach the anterior and posterior branches of the middle meningeal artery .. 167
167. Trephine opening for subdural hemorrhage 168
168. Enlargement of trephine opening with rongeur forceps, and incision of dura .. 168
169. After washing out subdural clot a rubber-tube drain is inserted and the dura closed by interrupted sutures about the drain. The end of the latter is carried through the temporal fascia and skin 169
170. Shows suture of the temporal muscle by interrupted sutures of catgut, and partial closure of the temporal fascia 169
171. Diagram of side of nose showing relations of bones and cartilages 172
172. Diagram of the bones and cartilages of the nose, anterior view 172
173. Diagram of the septum of the nose 172
174. (*a*) Fracture of nasal bones and nasal process of left maxilla 173
(*b*) Fracture of nasal bones and nasal process of right maxilla 173
(*c*) Fracture and dislocation of nasal bones 173
175–176. Showing depressed healed fractures of right frontal, malar, superior maxilla and nasal bones 173
177. Showing fracture of nasal bones with depression of fragments 174
178. Skull; old fracture of nasal bones and left zygoma 175
179. Skull; fracture of the nasal bones; union 175
180. Mosher's method of reducing, with thumb and elevator, fracture dislocation of nasal bones 177
181. Diagram of septal lesions due to blow in front 178
182. Robert's use of pins to hold fragments of fractured septal cartilage in corrected position 178
183. Method of palpation of malar bones 181
184. Lower half of skull. Fracture of the left malar; union 181
185. Skull; old fracture of the nasal and left malar bones 181
186. Skull; fracture of left malar 182
187. Lothrop's method of reduction of depressed and comminuted fractures of the malar and superior maxilla 183
188. Matas's method of reduction of a depressed fracture of the zygomatic arch .. 183

FIG. PAGE
189. Mandible, outer aspect ... 188
190. Fracture of mandible through symphysis ... 189
191. Mandible; old fracture of the body; union ... 190
192. Fracture of mandible, through mental foramen ... 191
193. Inferior maxilla; ununited fracture ... 192
194. Fracture of mandible through body ... 193
195. Fracture of mandible, malar region, showing type of displacement of fragments ... 193
196. Fracture of mandible through angle ... 194
197. Fracture of mandible through malar region showing type of displacement of fragments ... 195
198. Infeiror maxilla; oblique fracture of the ramus ... 195
199. Fracture of mandible through neck of condyle ... 196
200. Condyloid process "bent" in and forward to almost a right angle with the ramus ... 197
201. Posterior view of mandible showing a united fracture of neck of left condyle 197
202. An anterior view of the same skull ... 198
203. Fracture of mandible through base of anterior part of alveolar process ... 198
204. Method of determining crepitus and abnormal mobility of fragments in fracture of the mandible ... 199
205. Moulded felt chin splint padded with several layers of sheet-wadding ... 200
206. Application of occipitomental roller bandage to hold chin splint in place in fracture of the mandible ... 200
207. A fracture of the mandible showing interdental splint in position ... 201
208. An interdental splint holding the mandible together where a pathological separation of bone occurred, causing the loss of a complete section of bone ... 201
209. An interdental splint used in case of a compound fracture of the mandible ... 202
210. Two compound fractures at the angles of the mandible treated by a mandibullomaxillary splint ... 202
211. Röntgenogram showing method of suture of fragments of the mandible with silver wire ... 203
212. The hyoid bone, anterior view ... 205
213. Fracture of the hyoid bone ... 206
214. Adult spine, lateral view ... 213
215–216. Method of palpation through the mouth of the anterior surface of the bodies of the upper cervical vertebræ ... 214
217. Method of palpation of the coccyx through the anus ... 215
218. Compression fracture of the body of the first dorsal vertebra ... 216
219. Fracture-dislocation of the fourth and fifth dorsal vertebræ ... 216
220. Last three dorsal and first lumbar vertebræ. Fracture of the body of the twelfth dorsal ... 217
221. Ninth, tenth, eleventh and twelfth dorsal, and first two lumbar vertebræ. Fracture of the last dorsal ... 217
222. Eleventh and twelfth dorsal and first lumbar vertebræ. Vertical fracture of the twelfth dorsal and crescentic fracture of the upper and anterior lip of the first lumbar ... 217
223. Old compression fracture of bodies of second, third and fourth cervical vertebræ 218
224. Fracture of body of fifth cervical vertebra ... 219
225. Diagram to show types of isolated fracture of the arches, spinous and transverse processes of the vertebræ ... 220

FIG. PAGE

226. Six lower cervical vertebræ. Fracture of the left lamina and pedicle of the fourth and of the laminæ of the fifth cervical vertebræ..... 220
227. Compression fracture of fourth and fifth cervical vertebræ..... 220
228. Fracture of lateral processes of the fifth and sixth cervical vertebræ, left side 220
229. Dislocation forward of sixth cervical vertebræ..... 221
230. The lower dorsal and four upper lumbar vertebræ with portions of the three lower ribs of both sides..... 222
231. Cervical vertebræ; luxation of the atlas..... 222
232. Fracture-dislocation of fourth cervical vertebra..... 223
233. Fracture-dislocation of bodies of eighth and ninth vertebræ..... 224
234. The relation of the segments of the spinal cord and their nerve-roots to the bodies and spines of the vertebræ..... 226
235. Position in lesion of spine between the fifth and sixth cervical vertebræ..... 228
236. Position in luxation of the sixth and seventh cervical vertebræ..... 228
237. Anæsthesia resulting from a lesion of the fifth cervical segment..... 229
238. Area of anæsthesia in a lesion involving the sixth cervical segment on the right and the fifth cervical segment on the left..... 229
239. Anæsthesia produced by a lesion of the seventh cervical segment..... 230
240. Anæsthesia produced by a lesion of the first dorsal segment..... 230
241. Areas of anæsthesia in fracture of the spine involving the sixth and seventh cervical vertebræ..... 231
242. Right-sided anæsthesia due to lesion of the fifth cervical segment and left-sided anæsthesia due to a lesion of the first dorsal segment..... 231
243–244. Anæsthesia produced by a lesion of the eleventh dorsal segment. Anterior and posterior views..... 232
245. Area of anæsthesia following injury to the seventh dorsal segment..... 233
246–247. Area of anæsthesia produced by a lesion of the lower two lumbar segments on the left side and of the entire lumbar segment of the right side, anterior and posterior views..... 234
248–249. Anæsthesia following a lesion of the fifth lumbar segment..... 235
250. Anæsthesia following a lesion of the fifth sacral segment..... 236
251–252. Show area of anæsthesia in fracture involving the fourth lumbar segment 237
253. Anæsthesia following a lesion of the second sacral segment..... 238
254. Anæsthesia following a lesion of the third sacral segment..... 238
255. Anæsthesia following a lesion of the fourth sacral segment..... 239
256. Anæsthesia due to compression of the cauda equina..... 239
257. Showing deformity in compression fracture of the body of the second lumbar vertebra..... 249
258–259. Showing use of spinal convalescent brace for fracture of vertebræ..... 249
260–261. Showing use of convalescent brace in the treatment of fractures of cervical vertebræ..... 250
262. Sternum, anterior view..... 252
263. Sternum, transverse fracture of, union..... 253
264. Sternum, oblique fracture of; union..... 253
265. Showing type of displacement usual in fractures of the sternum..... 254
266. Left rib; fracture; union..... 257
267. Röntgenogram of healed fractures of the fourth to ninth left ribs 258
268. Showing relation of intercostal artery, vein and nerve to the rib..... 259
269. Method of making alternate pressure over rib near seat of fracture to determine abnormal mobility and pain..... 259
270. Method of making anteroposterior compression of the chest-wall..... 259
271. Compression injury of chest..... 260

FIG. PAGE
272. Cross-section of chest, showing normal relations of intrathoracic structures to the overlying ribs 260
273. Diagrammatic representation of complications in fracture of the ribs 260
274–275. Method of application of the adhesive plaster swathe in the treatment of fractures of the ribs 261
276. Right clavicle, upper surface 264
277. Palpation of clavicle, method of determining crepitus, abnormal mobility and deformity 265
278. Fracture of the middle third of the clavicle, direct violence 266
279. Fracture of the middle third of the clavicle by indirect violence, characteristic deformity 267
280. Fracture of the clavicle, junction of the middle and inner thirds 268
281. Fracture of middle third of clavicle, absence of displacement of fragments produced by indirect violence 268
282. Shows typical displacement of fragments in complete fracture of middle third of clavicle 269
283. Drawing to demonstrate typical displacement of fragments in fracture of middle third of clavicle 269
284. Fracture of outer end of clavicle 270
285. Fracture of tip of outer end of clavicle 271
286. Fracture of the outer end of the clavicle 271
287. Showing the attachments of the coracoclavicular and coraco-acromial ligaments and the reason for absence of displacement in fractures of the outer end of the clavicle 272
288. Fracture of the inner end of the clavicle 273
289–292. Method of applying Sayre dressing for fracture of the clavicle 274
293. Finished Sayre dressing for fracture of the clavicle 275
294–295. Application of claviculo-humeral bandage in fracture of the clavicle unattented by any great degree of deformity 276
296–297. Stimson's "figure-of-eight" dressing for fracture of the acromial end of the clavicle 277
298. Right scapula, anterior view 279
299. Method of palpation for suspected fracture of scapula 280
300. Method of palpation of coracoid processes of the scapulæ 280
301. Left scapula; stellate fracture of the superior angle 280
302. Fracture through spine of scapula 281
303. Right scapula; comminuted fracture of the base of the acromion process; union 281
304. Fracture through base of acromial process of scapula 282
305. Sprain-fracture of acromial process of scapula 283
306. Separation of the epiphysis of the acromial process of the scapula 283
307. Method of determining abnormal mobility and crepitus in fracture of the acromial process of the scapula by forced hyperabduction of the arm 284
308. Dressing to immobilize shoulder in fracture of scapula 285
309. Fracture of the surgical neck of the scapula 286
310. Displacement of fragments in fracture through the neck of the scapula 287
311. Method of determining crepitus and abnormal mobility in fracture of the neck of the scapula by forced elevation of the shoulder 287
312. Tear-fracture of epiphysis of coracoid process of scapula 288
313. Right humerus, front view 291
314. Upper end of humerus showing cupping of epiphysis to receive the pointed head of the diaphysis 292
315. Röntgenogram of normal shoulder-joint 292

FIG. PAGE
316. Röntgenogram showing normal epiphysis of upper end of humerus..... 292
317. Method of determining crepitus and abnormal mobility in fracture of the upper end of the humerus..... 293
318. Method of determining crepitus and abnormal mobility in fracture of the shaft of the humerus..... 293
319. Method of palpation of the condyles of the humerus..... 293
320. Showing the normal relation of the olecranon process of the ulna and of the condyles of the humerus in full extension of the elbow..... 293
321. Palpation of the head of the radius..... 294
322. The carrying angle; formed by the deviation of the axis of the forearm from the humeral axis..... 294
323. Incomplete fracture of the head of the humerus..... 295
324. Fracture of the anatomical neck of the humerus, with dislocation of the head into the axilla..... 295
325. Fracture of the humerus through the greater tuberosity, with dislocation of the head into the axilla..... 297
326. Fracture of the humerus through the tuberosities..... 297
327. Fracture of the greater tuberosity and of the surgical neck of the humerus... 298
328. Humerus, right; fracture of the greater tuberosity..... 299
329. Usual character of epiphyseal separation..... 302
330. Separation of upper epiphysis of humerus..... 302
331. Separation of upper epiphysis of humerus..... 303
332. (Same as Fig. 331, after reduction.)..... 303
333–335. Photographs of case (Figs. 331 and 332) of separation of upper epiphysis of left humerus..... 304
336. Oblique fracture of surgical neck of left humerus..... 305
337. Comminuted fracture of surgical neck of right humerus..... 305
338. Humerus, left; fracture of the surgical neck. Union..... 306
339. Method of determining shortening in fracture of the humerus..... 306
340. Fracture of humerus through surgical neck..... 307
341. Drawing to show the displacement of fragments in case Fig. 340..... 307
342. Method of reduction of fragments in fracture of the surgical neck of the humerus by traction and manipulation..... 308
343. Dressing for fracture of the surgical neck of humerus..... 309
344. Shows completed dressing for fracture of the surgical neck of the humerus... 309
345. Spiral fracture of shaft of humerus..... 310
346. Irregular transverse fracture of the shaft of the humerus..... 310
347. Transverse fracture of middle of shaft of humerus..... 310
348. Oblique fracture of shaft of humerus with over-riding and angular deformity. 310
349. Long oblique fracture of shaft of humerus..... 311
350. Transverse fracture of the shaft of the humerus..... 312
351. Drawing made from Fig. 350 to demonstrate the action of the muscles..... 312
352. Röntgenogram of oblique fracture of the shaft of the humerus in the region of the musculospiral nerve..... 314
353. Drawing to show operation for musculospiral paralysis occurring as a complication of fracture of the shaft of the humerus..... 315
354–356. Method of applying dressing for fracture of shaft of humerus..... 317
357–358. Röntgenograms of normal adult elbow region..... 320
359–360. Röntgenograms of normal elbow region in child aged 11 years..... 320
361. Supracondylar fracture of humerus..... 321
362. Supracondylar fracture of humerus, extension type..... 321
363–364. Supracondylar fracture of humerus..... 321

FIG. PAGE
365–366. Low fracture of the shaft of the humerus 322
367. Diacondylar fracture of humerus with marked lateral and posterior displacement of lower fragment 325
368. Diacondylar fracture of humerus with little displacement of fragments..... 325
369. Oblique diacondylar fracture of humerus, with line of fracture running downward and outward (adduction type)..... 325
370. Oblique diacondylar fracture of humerus, with line of fracture running downward and inward..... 325
371. Diacondylar fracture of humerus, "Posadas type," with dislocation of head of radius..... 326
372. Diacondylar fracture of humerus, "Posadas type"..... 326
373–374. Intercondylar T- or Y-fractures of lower end of humerus 327
375. Intercondylar atypical fracture of lower end of humerus..... 327
376–377. Separation of lower epiphysis of humerus. Anteroposterior and lateral views..... 329
378–379. Separation of lower epiphysis of humerus, with small fragment of diaphysis attached..... 329
380–381. Fractures of external epicondyle of humerus..... 330
382–383. Fracture of external condyle of humerus. Anteroposterior and lateral views..... 331
384–385. Fracture of external condyle of humerus, fall upon hand with arm extended. Anteroposterior and lateral views..... 332
386–387. Separation of the epiphyses of the capitellum of the humerus..... 333
388–389. Fracture of the internal epicondyle of the humerus 334
390. Fracture of the internal epicondyle of humerus. Marked downward and forward displacement of the epicondyle..... 335
391. Fracture of the internal epicondyle of the humerus without displacement of the fragments..... 335
392–393. Tear-fractures of the internal condyle of the humerus..... 336
394. Fracture of the internal condyle of the humerus..... 336
395–397. Fracture of the capitellum..... 337
398. Diacondylar fracture of the humerus..... 342
399. Effect hyperflexion has in maintaining reduction of fragments..... 343
400. Method of reduction of fractures of the lower end of the humerus..... 344
401–402. Old fracture of external condyle of humerus, untreated..... 345
403–404. Right cubitus valgus. Old fracture of external condyle of humerus. Untreated..... 346
405–406. Old fracture of internal condyle of humerus..... 347
407–408. Right cubitus varus. Old fracture of internal condyle of humerus..... 348
409. Method of maintaining hyperflexion of elbow by adhesive plaster strip..... 349
410. Rubber tubing sling. Finished dressing in position of hyperflexion..... 349
411. Right radius; flexor surface..... 354
412. Right ulna; outer surface..... 354
413. Lower portion of left humerus with radius and ulna. Incomplete double fracture of the radius and ulna..... 355
414–415 Fracture of shafts of radius and ulna..... 356
416–417. Multiple incomplete fractures of shafts of radius and ulna..... 357
418. Fracture of shafts of radius and ulna..... 358
419. Complete fracture of shafts of radius and incomplete fracture of ulna..... 358
420. Drawing to show the usual displacement of fragments in fractures of the shafts of the radius and ulna..... 359
421. Bone of right upper extremity; union with co-ossification..... 360

FIG. PAGE
422. Method of dressing with well-padded anterior angular splint, with forearm at right angle to arm and in full supination. 362
423–424. Application of padded right-angle anterior splint and posterior splint for fracture of shafts of radius and ulna 362
425. Showing areas of pressure necrosis from poorly padded anterior and posterior splints applied too tightly 363
426. Posterior deformity from green-stick fracture of shafts of radius and ulna before reduction 363
427. Tear-fracture of the tip of the olecranon process by muscular action 364
428. Fracture of olecranon exostosis from direct pull upon flexed elbow 364
429. Incomplete fracture of base of olecranon process. Direct violence 365
430. Comminuted fracture of olecranon. Direct violence 365
431. Transverse fracture of olecranon process. Muscular action. Very little separation of fragments 366
432. Transverse fracture of olecranon process. Marked separation of fragments . . 366
433. Showing the action of the triceps muscle in causing separation of fragments in fracture of the olecranon process 367
434–435. Slight deformity after incomplete fracture at base of olecranon process . 368
436–437. Straight splint applied to internal surface of arm and flexor surface of forearm for fracture of the olecranon process 369
438. Application of the internal right-angle splint for fracture of the olecranon process when there is no separation of fragments 369
439. Method of suture in fracture of the olecranon process attended by separation of fragments 370
440. Fracture of coronoid process of ulna 371
441. Fracture of the coronoid process of the ulna, complicating a posterior dislocation of radius and ulna previously reduced 371
442. Fracture of coronoid process of ulna 372
443. Fracture of coronoid process of ulna complicating a fracture of the olecranon process 372
444. Fracture of base of coronoid process of ulna complicating a diacondylar fracture of the humerus 372
445. Fracture of shaft of ulna, upper third 373
446. Fracture of shaft of ulna, lower third 373
447. Fracture of shaft of ulna, middle third 374
448. Multiple fracture of shaft of ulna, lower third 374
449. Showing type of displacement in fracture of the shaft of the ulna from direct violence 376
450. Fracture of the head of the radius. No displacement of fragments 377
451. Fracture of the head of the radius; slight displacement of fragment; complicated by fracture of coronoid process of the ulna 377
452. Fracture of head of radius. Moderate displacement of the fragment 378
453. Fracture of the head of the radius complicating posterior luxation of radius and ulna which had been reduced 378
454. Posterior luxation of the radius and of the ulna 379
455–456. Posterior luxation of the radius and ulna 380
457. Fracture of the upper radial epiphysis 380
458. Fracture of the neck of the radius with marked displacement of fragments . . 381
459. Fracture of the neck of the radius 381
460. Fracture of the shaft of the radius, upper third 383
461. Fracture of the shaft of the radius, junction of middle and upper thirds 384
462. Fracture of the shaft of the radius, middle third 384

FIG. PAGE
463. Fracture of the shaft of the radius, lower third 384
464. Drawing to show the effect of the triceps muscle in causing displacement of the upper fragment in fracture of the upper third of the shaft 384
465. Drawing to show the action of the pronator quadratus muscle in producing displacement of the lower fragment in fracture of the lower third of the radius 385
466. Low transverse fracture of radius and ulna 388
467. Low transverse fracture of radius and ulna. Marked displacement of lower fragments 388
468. Fracture of the tip of the styloid process of the radius 389
469. Fracture of the base of the styloid process of the radius 389
470. Fracture of the base of the styloid of the radius and of the styloid of the ulna.. 389
471. Separation of lower epiphysis of radius with fracture of outer part of the diaphysis 389
472. Irregular transverse fracture of lower end of radius 390
473. Transverse fracture of lower end of radius with impaction of fragments and posterior displacement of the lower fragment 391
474. Transverse fracture of the lower end of the radius with outward and posterior displacement of the lower fragment 391
475. Old united Colles' fracture with ununited fracture of styloid process of ulna .. 392
476. Atypical type of fracture of lower end of radius 392
477. Healed fracture of lower end of radius 392
478. Type of so-called reversed Colles' fracture 393
479. Fracture of the lower end of the radius with anterior displacement of the carpal fragment 394
480. Separation of lower radial epiphysis with posterior displacement of epiphysis, and a small fragment of the diaphysis 394
481. Separation of lower radial epiphysis and fracture of the anterior portion of the lower edge of the diaphysis, with anterior displacement of the lower fragment 394
482. Separation of lower radial epiphysis with posterior displacement of the lower fragment 394
483. Separation of the lower radial epiphysis with outward and posterior displacement of the epiphysis 396
484. Fracture through the carpal articular surface with separation of the posterior articular edge 396
485. Fracture through the carpal articular surface with separation of the posterior articular edge 396
486. Fracture through the carpal articular surface with separation of the anterior articular edge 397
487. Incomplete (green-stick) fracture of the lower end of the radius 398
488. Incomplete (green-stick) fracture of the lower end of the radius, with fracture of the styloid of the ulna 399
489–493. Types of longitudinal fissure fracture of the lower end of the radius 399
494. Isolated oblique fracture of the lower end of the radius, with the line of fracture running downward and outward 400
495. Isolated oblique fracture of the lower end of the radius with the line of fracture running downward and inward 401
496. Isolated oblique fracture of the lower end of the radius with the line of fracture running downward and inward; also a fracture of the lower third of the ulna 401
497–498. Types of sprain-fracture of the lower end of the radius 402
499. Chauffeur's fracture. Line of fracture is at base of styloid process. No displacement of fragments 403

FIG. PAGE
500. Chauffeur's fracture. Line of fracture is transverse at lower end of radius; also involves styloid of radius; also a fracture of styloid of ulna 403
501. Chauffeur's fracture by muscular action 403
502. Unreduced Colles's fracture, 7 weeks old 404
503–504. Old fracture of radius (Colles's type) and of styloid process of ulna with rupture of radio-ulnar ligaments 404
505. Deformity which may occur in fracture of the lower end of radius and ulna. . . 405
506. Method of palpation to determine the relative positions of the styloid processes of the radius and of the ulna 405
507. Diagrammatic drawing to show the various lesions with their deformities that may occur about the wrist-joint 406
508. Method of breaking of impaction of classic fracture at the lower end of the radius by increasing the deformity 409
509. Method of reduction of classic fracture at the lower end of the radius by forcible carrying forward of the lower fragment with adduction of the hand . . 409
510. Morton's method of reducing Colles's fracture by sudden snapping of the lower fragment forward 409
511–512. Show application of posterior padded straight splint for immobilization of fracture at the lower end of the radius 410
513. Demonstrating the plane of the posterior aspect of the bones of the forearm and hand 411
514. Method of application of anterior and posterior padded splints for fracture at the lower end of the radius 411
515–517. Method of application of the anterior and posterior padded abduction splint 412
518–519. Use of the Levis metal splint in the treatment of fractures at the lower end of the radius 413
520. Anterior view of the bones of the carpus and the metacarpus 417
521. Comminuted fracture of the carpal scaphoid 419
522. Fracture of the carpal scaphoid 419
523–524. Sprain-fracture of the tubercle of the carpal scaphoid 420
525. Fracture of the carpal scaphoid with backward luxation of the radial fragment which was removed at operation 420
526. Fracture of the carpal semilunar, direct violence 420
527. Transverse fracture of first metacarpal at junction of base and the shaft . . 422
528. Oblique fracture of the shaft of the first metacarpal 422
529-531. Oblique fractures of the base of the first metacarpal involving the articular surface 423
532–533. Separation of the epiphysis of the first metacarpal with a fracture of a portion of the diaphysis 424
534. Separation of the epiphysis of the second metacarpal 424
535. Transverse fracture of shaft of fourth metacarpal 424
536. Fractures of shafts of second, fourth and fifth metacarpals 425
537. Comminuted fracture of the base of the fifth metacarpal 425
538. Arrest of growth of fourth metacarpal following previous separation of its epiphyses 425
539. Method of determining crepitus and mobility of fragments in fracture of the metacarpals 426
540-542. Method of application of padded gutter aluminum splint for fractures of the first metacarpal 427
543–545. Method of application of padded posterior wood splint for fractures of the second to the fifth metacarpals 428

FIG. PAGE

546–548. Method of application of padded palmar splint for fracture of the second to fifth metacarpals, when a tendency to recurrence of deformity is not present 429
549. Transverse fracture of proximal phalanx of thumb 432
550. Comminuted fracture of proximal phalanx of fifth finger 432
551. Articular fracture of base of middle phalanx of third finger. "Base-ball" finger 432
552. Articular fracture of head of middle phalanx of thumb. "Base-ball" thumb . . 432
553. Separation of epiphysis of proximal phalanx of ring finger 433
554-556. Method of application of padded aluminum splint for fractures of phalanges of index finger 433
557-559. Method of application of padded aluminum splint for fractures of phalanges of fingers 434
560. Right innominate bone, outer aspect 436
561. Male pelvis, anterior view 437
562-564. Fractures of pelvis 438
565. Pelvis with fourth and fifth lumbar vertebræ 440
566. Fracture of the pelvis 441
567. Pelvis; fracture of the sacrum and left innominate 442
568. Fracture of the floor of the acetabulum with central dislocation of the head of the right femur 442
569-571. Photographs of case of fracture of the floor of the acetabulum 443
572–573. Fractures of the pelvis 444, 445
574. Portion of left innominate bone 446
575. Right innominate 446
576. Irregular fracture of ala of ilium 446
577. Fracture of the anterior superior spine of the ilium 447
578. Normal epiphysial line of the crest of the ilium 448
579. Left innominate; old fracture; exostosis 449
580. Method of measuring the distance from the median line of the abdomen to both trochanters 450
581. Method of lateral compression to determine crepitus and mobility in suspected fracture of the pelvis 450
582. Method of determining crepitus and mobility in suspected fracture of the rim of the acetabulum or in Malgaigne's double fracture of the pelvis 450
583. Drawing to show rupture of the bladder and urethra complicating fracture of the pelvis 453
584. Application of circular adhesive plaster swathe in fracture of the pelvis 456
585. Completed adhesive plaster swathe for fracture of the pelvis 456
586. Right femur, anterior view 458
587. View of outer surface of the bones of the hip showing Roser-Nélaton line 459
588. Outer surface of right hip and thigh showing Roser-Nélaton line and Bryant's triangle 460
589. Measurements from the anterior superior spine of the ilium to the internal malleolus to determine shortening on the injured side 460
590. Elevation of the great trochanter in fracture of the neck of the femur 461
591. Relaxation of the fascia lata which occurs in fracture of the femur 461
592. Method of measuring from the anterior superior spine of the ilium to the internal malleolus 463
593. Showing the shortening which occurs in fracture of the neck or of the shaft of the femur as compared with the well side 463
594. Portions of femoral head 464
595. Femur: intracapsular fracture of the neck 465

FIG. PAGE
596. Femur, right; fracture of the base of the neck. 465
597. Femur, upper third of; intracapsular fracture of the neck. 465
598-605. Fractures of the neck of the femur. 466, 467, 468, 469
606. Showing method of determining false motion in fractures of the neck of the femur. 470
607. Showing why the arc of rotation is shortened, in unimpacted fractures of the neck of the femur. 471
608. Anterior luxation of the right hip-joint. 477
609. Method of applying Buck's traction apparatus. 477
610. Principles to be considered in Whitman's abduction method for the treatment of fractures of the neck of the femur. 478
611. The elevation of the head of the bed. 479
612. The plaster spica holding the limb at the limit of normal abduction. 480
613. Application of plaster-of-Paris case. 480
614-617. Fractures of the femur through the trochanters. 484
618-619. Fractures of the great trochanter of the femur. 485
620. Drawing to show the type of displacement which occurs in fracture of the great trochanter. 486
621–622. Subtrochanteric fractures of the femur. 488
623. Modified Zuppinger's apparatus for treatment of fractures in the subtrochanteric region. 489
624-626. Types of fracture of the upper third of the shaft of the femur. 490
627-629. Types of fracture of the middle of the shaft of the femur. 491
630-633. Types of fracture of the lower third of the shaft of the femur. 492
634-638. Types of fracture of the shaft of the femur occurring during childhood. 493
639. Method of determining abnormal mobility and crepitus in fracture of the shaft of the femur. 496
640. Femur; fracture through trochanters. 497
641. Femur, right; fracture of the upper shaft. 497
642. Femur, right; fracture of the neck, trochanter major and shaft; recent. 497
643. Femur, right; transverse fracture of middle shaft. 497
644. Femur, left; fracture of the middle shaft. 498
645. Femur, left; fracture of the lower shaft; union with deformity. 498
646. Femur; fracture of the shaft, junction of the middle and lower thirds. 498
647. Drawing to show type of displacement which may occur in fractures of the upper third of the shaft of the femur. 499
648. Fracture of the middle of the shaft of the femur in childhood. 500
649. Drawing to show the action of the thigh muscles in causing displacement of fragments. 500
650. Method of applying Buck's traction apparatus. 503
651. Second stage of the modified Buck's traction apparatus. 504
652. The dressing completed. 504
653–655. Vertical extension for the treatment of fractures of the femur in children 507
656–657. Method of vertical extension by Bryant's method for fracture of the shaft of the femur. 508
658. Christen's suspension method for treatment of fractures of the shaft of the femur in children. 509
659. Convalescent splint to be used in the treatment of fractures of the femur. . . . 510
660. Supracondylar fracture of the femur. 511
661. Drawing to show the pull exerted by the gastrocnemius muscle in producing posterior displacement of upper end of lower fragment. 511

FIG. PAGE
662–663. Comminuted supracondylar fractures of the femur 512
664. Supracondylar fracture of the femur 512
665. Comminuted supra-intracondylar fracture of the femur. Anteroposterior view 512
666. Comminuted supra-intracondylar fracture of the femur. Lateral view 513
667. Supracondylar fracture of the femur in a child aged three years 513
668. Femur, right; fracture of the lower shaft 514
669. Femur, left; comminuted intercondylar fracture 514
670–671. Fracture of internal condyle of femur. Anteroposterior and lateral views 515
672. Separation of the lower femoral epiphysis. Lateral and anteroposterior views 516
673. Separation of the lower femoral epiphysis. Lateral and anteroposterior views 517
674. Femur; separation of lower epiphysis 518
675. Separation of the lower femoral epiphysis 519
676. Method of reduction of separation of the lower epiphysis of the femur 520
677–678. Tear-fracture of a part of the external condyle of the femur 521
679. Tear-fracture of a part of the internal condyle of the femur 521
680. Method of determining abnormal mobility in fracture of the external condyle of the femur by a forced varus position 522
681. Method of determining abnormal mobility in fracture of the internal condyle of the femur by a forced valgus position 522
682. Myosites ossificans traumarica following strain of adductor muscles 523
683. Incomplete transverse fracture of the patella 526
684. Transverse fracture of the patella, lower third 526
685. Transverse fracture of the patella with marked rotation of the lower fragment 526
686. Transverse fracture of the patella, middle third, with separation of the fragments 526
687. Incomplete transverse fracture of the patella, lower third, direct violence 527
688. Transverse fracture of the patella, middle third. Marked separation of fragments 527
689. Transverse fracture of the patella, with moderate bony union 527
690. Old transverse fracture of the patella, upper third, with extreme separation of the fragments 527
691. Drawing to show the mechanism of fracture of the patella by muscular action 528
692. Method of non-operative treatment of fracture of the patella on inclined plane 533
693. Application of the posterior hand splint in fracture of the patella to be used during convalescence 533
694. Fracture of the patella 534
695. Fracture of the patella, untreated for six months 537
696. Fracture of the patella showing moderate approximation by silver wire suture 537
697–700. Examples of suture of patellar fragments in which the silver wire used for suture was either extruded or broken 538
701. Right tibia, anterior view 541
702. Right fibula, anterior view 542
703. Tear-fracture of tibial tubercle 544
704. Normal epiphysis of upper end of tibia with separate centre of ossification for tibial tubercle 544
705. Tear-fracture of tibial tubercle 544
706. Comminuted fracture of the upper end of the tibia and fibula 544
707–708. Fracture of the external tuberosity of the tibia 545
709. Fracture of external tuberosity of the tibia 545
710. Fracture of internal tuberosity of the tibia 545

FIG. PAGE

711–712. Longitudinal T- or Y-fracture of the upper end of the tibia, with separation of both tuberosities 546
713–714. Fracture of the upper end of the tibia (T-shaped, articular of the head) and of the fibula 546
715–717. Types of compression fracture of the upper end of the tibia including both tuberosities 547
718–719. Transverse anteroposterior fracture of the upper end of the tibia, and oblique fracture of the neck of the fibula 548
720–721. Lateral oblique fracture of the tibia with fracture of the fibula..... 548
722–723. Transverse fracture of the upper end of the tibia..... 549
724. Fracture of the internal tuberosity of the tibia..... 549
725. Fracture of the intercondylar eminence..... 549
726. Anteroposterior oblique fracture of the upper end of the diaphysis of the tibia . . 550
727. Incomplete transverse fracture of the upper ends of the tibia and fibula..... 550
728–730. Fractures of the upper end of the fibula..... 552
731. Relation of the external peroneal nerve with the head and neck of the fibula 553
732. Fracture of the head of the tibia; epiphyseal 554
733. Spiral fractures of the shafts of the tibia and fibula..... 555
734. Comminuted fracture of the shaft of the tibia and fracture of the shaft of the fibula..... 556
735. Transverse fracture of the shafts of the tibia and fibula..... 556
736. Oblique fracture of the shaft of the tibia with a double fracture of the shaft of the fibula..... 556
737. Oblique fractures of the shafts of the tibia and fibula, considerable overriding of the fragments..... 556
738. Spiral fracture of the shaft (low) of the tibia with spiral fracture of the shaft (high) of the fibula..... 557
739–740. Double spiral fracture of the shaft of the tibia..... 557
741. Spiral fracture of the shaft of the tibia..... 557
742. Double spiral fracture of the shaft of the tibia..... 558
743. Old healed fracture of the shaft of the tibia and recent fracture of the shaft of the fibula..... 558
744. Oblique fracture of the shafts of the tibia and fibula..... 558
745–746. Incomplete fracture of the shaft of the tibia in a boy aged 12 years..... 558
747–748. Oblique fracture of the shaft of the tibia; boy aged 5 years..... 559
749. Tibia and fibula (left). Fracture of both bones below middle 560
750. Tibia and fibula, right. Fracture of both bones; union..... 560
751. Characteristic displacement of fragments in olbique fractures of the shafts of the tibia and fibula..... 560
752. Method of determining abnormal mobility and crepitus in fracture of the shafts of the tibia and fibula..... 561
753. Method of measurement from the internal tuberosity to the internal malleolus of the tibia to determine shortening..... 561
754. Showing how shortening may take place..... 563
755. Method of treating fractures of both bones of the leg in a swinging fracture box. 564
756*a*. Modified Zuppinger traction apparatus for treating fractures of both bones of the leg 565
756*b*, 756*c*. Cabot posterior wire splint used in treating fractures of both bones of the leg unattended by deformity 565
757–758. Transverse fractures of shafts of tibia and fibula..... 566
759–760. Transverse fracture of the shafts of the tibia and fibula..... 566
761–762. Oblique fractures of the shafts of the tibia and fibula..... 567

FIG. PAGE
763–764. Oblique fractures of the shafts of the tibia and fibula 567
765–766. Photographs showing result obtained in fracture of shafts of tibia and fibula 568
767–768. Transverse fracture of the tibia with incomplete fracture of the fibula 569
769–770. Transverse fracture of the tibia and incomplete fracture of the fibula 569
771. Photograph showing a result often obtained in badly comminuted open fractures of the bones of the leg followed by suppuration 570
772. Spiral fracture of the shaft of the tibia 571
773. Transverse fracture of the shaft of the tibia 571
774. Transverse fracture of the shaft of the tibia with the separation of a three-cornered fragment 571
775. Comminuted fracture of the shaft of the tibia 571
776. Comminuted fracture of the shaft of the fibula. Direct violence 572
777. Oblique fracture of the shaft of the fibula 572
778–782. Types of supramalleolar fractures of the tibia and fibula 573, 574
783. Supramalleolar fracture of tibia and fibula 575
784. Fracture of internal malleolar portion of lower epiphysis of the tibia 577
785. Separation of the lower tibial epiphysis with fracture of the fibula 577
786. Separation of lower tibial epiphysis with fracture of lower end of diaphysis and fracture of the lower end of the fibula 579
787. Showing the normal structures of the ankle-joint 580
788. Showing the most common types of fracture about the ankle-joint, and methods of reduction of these types of fractures 581
789. Fracture of fibula with rupture of internal lateral and tibio-fibular ligaments ... 582
790. Fracture of the fibula with fracture of the internal malleolus 583
791. Fracture of the fibula (low) with fracture of the internal malleolus 583
792. Fracture of the fibula with fracture of the internal malleolus. Marked posterior displacement of the foot 584
793. Method of determining crepitus in fracture of the lower end of the fibula by rocking of the lower fragment 585
794. Method of determining lateral mobility of the ankle-joint in fractures of the malleoli 585
795. Method of reduction of classic Pott's fracture by forced inversion of the foot and correction of posterior displacement if it is present 586
796. Application of a pillow and side splints for temporary immobilization of fragments before placing the foot and leg in a gypsum case 586
797. Method of holding the foot and leg while a gypsum case is being applied 587
798. Fracture of the fibular malleolus with fracture of the internal malleolus and posterior articular edge of the tibia 588
799. Fracture of the fibular malleolus, internal malleolus and posterior articular edge of the tibia 589
800. Fracture of the fibula, of the internal malleolus and of the external articulating edge of the tibia 589
801–803. Types of fracture of the malleoli by inversion and adduction of the foot. 592
804. Atypical inverted Pott's fracture 593
805–806. Isolated fracture of the internal malleolus 594
807–808. Isolated fracture of the external malleolus 595
809–810. Fracture of the anterior articular edge of the lower end of the tibia 597
811. Anterior view of bones of foot 599
812. Röntgenogram showing bones of normal foot, lateral view 600
813. Röntgenogram showing normal bones of foot, anteroposterior view 602

FIG. PAGE
814. Fracture of neck of astragalus. 603
815. Compression fracture of neck of astragalus. 604
816. Fracture of neck of astragalus. 604
817. Fracture of external process of astragalus. 605
818. Fracture of the body of the astragalus with outward dislocation of anterior fragment 606
819. Compression fracture of body of astragalus. 607
820. Compression fracture of body of astragalus and of calcaneum with dislocation at astragalo-scaphoid joint 607
821. Compression fracture of body of astragalus 608
822. Fracture of the posterior process of the astragalus. 608
823–825. Types of tear-fracture of the posterior process of the calcaneum. 609
826–828. Types of fracture of posterior process of calcaneum. 610, 611
829–831. Types of compression fractures of the calcaneum. 612
832. Fracture of epiphysis of posterior process of calcaneum. 613
833. Method of determining lateral normal motion in the foot. 614
834. Fracture of left calcaneum, anterior and posterior views. 614
835. Cotton's method of reduction of a fracture of the posterior process of the calcaneum with upward displacement of the fragment. 615
836. Cotton's method of correcting lateral broadening below the malleoli by compression of fragments with a hammer and piece of felt. 616
837. Fracture of the body of the calcaneum with upward displacement of the fragment. 617
838. Drawing to show the pull exerted by the tendo-Achilles in fracture of the posterior portion of the body of the calcaneum. 617
839. Method of approximation of fragments in fracture of posterior portion of body of calcaneum by open operation. 618
840–842. Types of fractures of the tuberosity of the tarsal scaphoid. 619
843. Fracture of cuboid. 620
844, 845. Tear-fractures of the internal cuneiform. 620
846. Comminuted fracture of the first metatarsal. 623
847. Comminuted fracture of the first metatarsal, longitudinal in type. 623
848. Transverse fracture of the first and second metatarsals. 623
849. Longitudinal fracture of the first metatarsal. 623
850. Fracture dislocation of the base of the first and of the shafts of the second, third and fourth metatarsals. 624
851. Transverse fracture of the shaft of the second metatarsal. 624
852. Fracture of the shaft of the second, third and fourth metatarsals. 624
853–855. Types of fracture of the tip of the tuberosity of the fifth metatarsal. 625
856–857. Types of fracture of the base of the tuberosity of the fifth metatarsal. . . 626
858-859. Types of fracture through the proximal end of the shaft of the fifth metatarsal. 626
860–864. Types of fracture of the shaft of the fifth metatarsal. 627
865. Method of determing abnormal mobility and crepitus in fracture of the shafts of the metatarsals. 628
866. Transverse fracture of the proximal phalanx of the great toe. 629
867. Oblique fracture of the proximal phalanx of the second toe. 629
868. Spiral fracture of the proximal phalanx of the fifth toe. 630
869. Comminuted fracture of the distal phalanx of the great toe, involving the epiphysis of the base. 630
870. Fracture of exostosis of distal phalanx of great toe. 630

FIG. PAGE
871. Constant sesamoid bones of the thumb..... 631
872. Shows only one constant sesamoid bone at the metacarpophalangeal joint of the thumb, one accessory sesamoid head of second metacacarpal, one at head of third metacarpal, and two at head of the fifth metacarpal..... 631
873–874. Shows two accessory carpal sesamoid bones in tendon sheaths of flexor tendon to fifth finger 632
875. Constant sesamoid bones at head of the first metatarsal bone..... 632
876–877. Types of os trigonum 632, 633
878. Os tibiale externum, in the tendon sheath of the tibialis posticus tendon..... 633
879. Double os peroneale, situated in the tendon of the peroneus longus muscle... 633
880. Accessory sesamoid in the tendon of the gastrocnemius muscle..... 634
881. Shows the two constant sesamoids at the head of the first metatarsal, and accessory sesamoids at the heads of the second, third, fourth and fifth metatarsals..... 634
882. Comminuted fracture of the tibial sesamoid of the great toe..... 635
883. Fracture of the tibial sesamoid of the great toe..... 635
884. Fracture of fibular sesamoid, accompanying comminuted fracture of the head of the first metatarsal..... 636
885. Fracture of the tibial sesamoid..... 636
886. Fracture of the fibular sesamoid, run over by a motorcycle..... 636
887. Fracture of the tibial sesamoid; injured while playing base-ball..... 636
888. Old fracture of sesamoid in a base-ball player..... 637
889. Fracture of the sesamoid of the thumb..... 637
890. Fractures of right humerus and both clavicles..... 640
891. Fracture of shaft of femur, at end of ten weeks..... 641
892–893. Radiographs of normal and injured femur for comparison, (10 days and four months) 642
894. Long side splint used in fracture of shaft of femur..... 643
895. Aluminum splint used in fracture of humerus..... 644
896. Makin's five types of fracture observed in military life..... 647
897–897*a*. Gunshot fractures of the palate and the body of the sphenoid bones 648, 649
897*b*. Perforating gunshot fracture of the frontal and the nasal bones..... 650
898. Gunshot fracture of the mandible..... 651
899. Gunshot fracture of the left humerus..... 652
900. Gunshot fracture of the humerus; note butterfly type of fracture, and fragmentation of the bullet..... 653
901–902. Gunshot fractures of the carpus..... 654, 655
903. Gunshot fracture of the proximal phalanx of the middle finger..... 655
904. Gunshot fracture of the tibia..... 656
905. "Aeroplane" bracket splint for holding arm in abduction and forearm in extension..... 657
906. "Aeroplane" bracket splint to hold arm in abduction and forearm flexed.... 658
907. Gypsum encasement with basket braces of wire and gypsum gauze for immobilization of infected open and comminuted fractures..... 659
908. Tibia and fibula, upper extremities of right..... 660
909. Basket plastic splint with steel bones arranged for immobilization with extented knee and some traction on fracture 661

TREATISE ON FRACTURES

CHAPTER I

GENERAL CONSIDERATIONS

Definitions.—A fracture is a sudden separation of osseous fibres due to injury; in a general way it refers to the breaking of a bone or cartilage. It is applied somewhat incorrectly to a traumatic separation of an epiphysis from its diaphysis, though that lesion is properly called a diastasis.

A dislocation or luxation is the sudden displacement of the articular surfaces of the adjoining bones from their normal relation. The term is also used to describe the displacement of an articular or intra-articular fibrocartilage from its normal relations. A dislocation is complete when the normal articular surfaces of the bone involved are entirely displaced; incomplete when the articular surfaces of the bone involved still retain partial contact. The latter condition is more properly termed a subluxation.

A sprain or distortion may be described as an injury to a joint or the structures in proximity to a joint, in which the joint motions have been forcibly carried beyond normal physiological limits. Sprains are usually the result of indirect violence, although they may be produced by muscular action alone. The force would probably result in a fracture or dislocation if the violence were greater. The injury generally consists in partial or minute tearing of portions of ligaments, tendons, or fascias, or the bruising of the articular cartilages.

A sprain-fracture is the partial or complete separation of a small portion of a bone near a joint to which a tendon or ligament is attached, as a result of sudden violence acting upon the tendon or ligament involved.

Statistics.—A review of statistics showing the liability of individual bones to fracture shows that, as a rule, these statistics are incomplete as to classification or that the location of fractures of individual bones is not given. Another source of error is the fact that many fractures are omitted entirely, many are diagnosed as subluxations, and many as sprains. This results in the inevitable worthlessness of the average statistics.

The following statistics are deemed valuable: The combined statistics of Bruns, Chudowsky, Immelmann and those of Plagemann, but one can realize the inaccuracies that are shown by combined statistics. The records of Plagemann from the Rostock clinic are prob-

ably the most accurate that are anywhere presented. They are divided into three groups: The statistics of the first and second groups are based in many cases on X-ray examinations; those of the third group are based on X-ray examinations of all suspected fractures.

TABLE I.

	A Bruns	B Chudowsky	C Immelmann	D Plagemann, Rostock Clinic 3664 Fractures. Years 1891-1910 Rostock Statistics		
				Oct. 1, 1891 to Oct. 1, 1899	Oct. 1, 1899 to Oct. 1, 1905	Oct. 1, 1905 to Aug. 1, 1910
Fractures	8560	2366	4048	1106	1165	1393
	Per cent.	*Per cent.*	*Per cent.*	*Per cent.*	*Per cent.*	*Per cent.*
Skull (vault and base)	292 = 3.4	90 = 3.8		31 = 2.8	34 = 3.07	59 = 4.23
Nasal	95 = 1.1	23 = 0.97	20 = ½	11 = 1.	7 = 0.63	9 = 0.64
Superior maxilla	55 = 0.6	12 = 0.5		9 = 0.81	7 = 0.63	6 = 0.43
Inferior maxilla	102 = 1.1	44 = 1.9		10 = 0.9	5 = 0.452	11 = 0.79
Total	544 = 6.3	169 = 7.14	.....	61 = 5.52	53 = 4.55	85 = 6.11
Vertebræ	39 = 0.4	14 = 0.59	35 = 1¼	23 = 2.03	24 = 2.17	23 = 1.65
Pelvis	70 = 0.8	23 = 0.97	70 = 1¾	8 = 0.72	6 = 0.54	17 = 1.22
Ribs	819 = 9.5	193 = 8.15	.....	67 = 6.05	29 = 2.62	40 = 2.87
Sternum	17 = 0.1	6 = 0.25	.....	2 = 0.18	1 = 0.09	5 = 0.359
Scapula	100 = 1.1	20 = 0.84	63 = 1⅝	9 = 0.81	5 = 0.452	13 = 0.93
Total	1045 = 12.0	256 = 10.80	.....	109 = 9.85	65 = 5.57	89 = 7.03
Clavicle	960 = 11.2	113 = 4.17	40 = 1	69 = 6.2₃	60 = 5.4	54 = 3.87
Humerus	866 = 10.1	210 = 8.17	940 = 23½	128 = 11.48	131 = 11.85	194 = 13.92
Ulna and radius	752 = 8.7	125 = 5.32		84 = 7.5	147 = 13.3	134 = 9.62
Ulna	215 = 2.5	79 = 3.34	1300 = 32½	23 = 2.03	27 = 2.44	Ulna 20 = 1.43 Olecranon and coronoid process 11 = 0.79 — 2.22
Olecranon	103 = 1.2					
Radius	828 = 9.6	253 = 10.69		123 = 11.1	61 = 5.5	73 = 5.24
Carpus	.....	55 = 2.29	35 = ⅞	.....	3 = 0.27	29 = 2.08
Metacarpals	168 = 1.9		55 = 1⅜	14 = 1.3	33 = 3	35 = 2.51
Phalanges	419 = 4.8	233 = 9.84	150 = 3¾	72 = 6.5	98 = 8.86	75 = 5.405
Total	3351 = 39.1	955 = 39.65	2480 = 61.26	444 = 40.14	500 = 42.91	571 = 40.99
Femur	1086 = 12.6	251 = 10.60	425 = 10⅝	173 = 15.5	151 = 13.6	150 = 10.81
Patella	123 = 1.4	25 = 1.05	120 = 3	12 = 1.08	12 = 1.1	35 = 2.51
Tibia and fibula	879 = 10.2	352 = 14.87		166 = 15	213 = 19.2	168 = 12.06
Tibia	160 = 1.8	59 = 2.46	470 = 11¾	14 = 1.3	42 = 3.8	61 = 4.38
Fibula	176 = 2.0	74 = 3.12		33 = 3	27 = 2.44	57 = 4.09
Tarsals	.....		140 = 3½	11 = 1	17 = 1.5	37 = 2.65
Metatarsals	73 = 0.8	112 = 4.69	145 = 3⅝	11 = 1	12 = 1.08	49 = 3.51
Phalanges	45 = 0.5		30 = ¾	3 = 0.27	12 = 1.08	24 = 1.71
Sesamoids	.....	.....	.....	.....	.....	4 = 0.29
Totals	2660 = 31.0	873 = 36.79	1385 = 34.21	423 = 38.24	487 = 41.8	585 = 41.99

TABLE II (PLAGEMANN)

. Fractures of the skull (59 cases, 4.23 per cent.).
. Fractures of the extremities:
1. Fractures of the humerus (194 cases, 13.39 per cent.):
   (*a*) Of the upper end (73 cases, 5.24 per cent.):
      (1) Fractures of the anatomical neck..... 4 (0.29)
      (2) Fractures of the greater tubercle..... 30 (2.15)
      (3) Fractures through the tubercle..... 10 (0.71)
      (4) Separation of the upper epiphysis..... 7 (0.509)
      (5) Fractures of the surgical neck..... 22 (1.57)
   (*b*) Of the shaft..... 18 (1.29)
   (*c*) Of the lower end:
      (1) Supracondylar fractures..... 43 (3.08)
      (2) Supracondylar—intercondylar..... 11 (0.78)
      (3) Fractures of the external condyle..... 15 (1.07)
      (4) Fractures of the internal epicondyle..... 18 (1.29)
      (5) Separation of the lower epiphysis..... 10 (0.71)
      (6) Fracture of the cubital process..... 6 (0.43)
2. Fractures of the bones of the forearm (238 cases, 17.09 per cent.):
   (*a*) Both bones of the forearm (134 cases, 9.62 per cent.).
      (1) Fracture of the upper ends of both bones..... 7 (0.509)
      (2) Fracture of the shafts of both bones..... 47 (3.37)
      (3) Fracture of the lower ends of both bones..... 80 (5.74)
         Darunter Fr. Supra-epiphysaria antibrachii 13 (0.93)
   (*b*) Fractures of the radius alone (73 cases, 5.24 per cent.):
      (1) Fractures of the head and neck of the radius..... 23 (1.65)
      (2) Fractures of the shaft of the radius..... 12 (0.85)
      (3) Fractures of the lower end of the radius..... 38 (2.72)
   (*c*) Fractures of the ulna alone (31 cases, 2.22 per cent.):
      (1) Fractures of the olecranon and coronoid processes..... 11 (0.78)
      (2) Fractures of the shaft of the ulna..... 15 (1.07)
      (3) Fractures of the lower end of the ulna..... 5 (0.359)
3. Fractures of the bones of the hand (139 cases, 9.98 per cent.):
   (*a*) Carpal fractures (29 cases, 2.08 per cent.):
      (1) Fractures of the scaphoid..... 13 (0.93)
      (2) Fractures of the semilunar..... 5 (0.359)
      (3) Fractures of the cuneiform..... 3 (0.21)
      (4) Fractures of the os magnum..... 1 (0.07)
      (5) Fractures of several carpal bones..... 7 (0.509)
   (*b*) Metacarpal fractures (35 cases, 2.51 per cent.):
   (*c*) Fractures of the phalanges (75 cases, 5.405 per cent.).
4. Fractures of the femur (150 cases, 10.81 per cent.):
   (*a*) Fractures of the upper end (84 cases, 6.04 per cent.):
      (1) Fractures of the neck of the femur(60 cases, 4.307 per cent.):
         (*a*) Fractures of the neck, close to head..... 11 (0.78)
         (*b*) Fractures of the neck, intermediate..... 20 (1.43)
         (*c*) Fractures through base of neck and trochanters.... 5 (0.359)
         (*d*) Fractures of the neck at base..... 24 (1.79)
      (2) Separation of the upper epiphysis..... 4 (0.29)
      (3) Fractures through the trochanters..... 7 (0.509)
      (4) Fracture of the great trochanter..... 2 (0.143)
      (5) Fractures below the trochanters..... 11 (0.78)
   (*b*) Fractures of the shaft of the femur (55 cases, 3.94 per cent).
   (*c*) Fractures of the lower end of the femur (12 cases, 0.89 per cent.):
      (1) Supracondylar fractures..... 8 (0.57)
      (2) Fractures of the internal epicondyle..... 7 (0.509)
      (3) Separation of the lower epiphysis of the femur..... 2 (0.143)
      (4) Fractures of the condyles..... 2 (0.143)
5. Fractures of the patella (35 cases, 2.51 per cent.):
   (*a*) Fractures of the upper third..... 5
   (*b*) Fractures of the middle third..... 22
   (*c*) Fractures of the lower third..... 8
6. Fractures of the bones of the leg (286 cases, 20.53 per cent.):
   (*a*) Fractures of tibia and fibula (168 cases, 12.06 per cent.).
      (1) Fractures of the upper end of tibia and fibula..... 4 (0.29)
      (2) Fractures of the shafts of tibia and fibula..... 92 (6.604)
      (3) Supramalleolar fractures (Malgaigne)..... 22 (1.57)
      (4) Fractures of the lower ends of tibia and fibula..... 50 (3.59)

TABLE II (PLAGEMANN)—*Continued*

(*b*) Fractures of the tibia, alone (61 cases, 4.38 per cent.):
- (1) Fractures of the upper end of the tibia..... 19 (1.36)
- (2) Fractures of the shaft of the tibia..... 24 (1.79)
- (3) Fractures of the lower end of the tibia..... 18 (1.29)

(*c*) Fractures of the fibula, alone (57 cases, 4.09 per cent.):
- (1) Fractures of the head and neck of the fibula..... 13 (0.93)
- (2) Fractures of the shaft of the fibula..... 30 (2.15)
- (3) Fractures of the external malleolus..... 14 (1.005)

7. Fractures of the bones of the foot (114 cases, 8.18 per cent.):
   (*a*) Fractures of the tarsal bones (37 cases, 2.65 per cent.):
   - (1) Fracture of the calcaneus, alone..... 17 (1.22)
   - (2) Fracture of the astragalus, alone..... 5 (0.350)
   - (3) Fracture of the calcaneus and astragalus..... 4 (0.29)
   - (4) Fracture of the scaphoid..... 7 (0.509)
   - (5) Fracture of the cuboid..... 1 (0.07)
   - (6) Fracture of the cuneiform..... 3 (0.21)

   (*b*) Fractures of the metatarsals (49 cases, 3.51 per cent.).
   (*c*) Fractures of the phalanges (24 cases, 1.71 per cent.).
   (*d*) Fractures of the sesamoids (4 cases, 0.29 per cent.).
8. Fractures of the clavicle (54 cases, 3.87 per cent.).
9. Fractures of the scapula (13 cases, 0.93 per cent.).

TABLE III (PLAGEMANN)

STATISTICS FROM ROSTOCK CLINIC BASED UPON 1393 CASES. CONFIRMED BY RÖNTGENOGRAM

	1–10	11–20	21–30	31–40	41–50	51–60	61–70	71–90	Number of Cases and Percentages
Fracture of skull	3	11	16	11	6	6	6	..	59 = 4.23
Fracture of the vertebræ	..	2	3	7	8	1	..	..	23 = 1.65
Fracture of the pelvis	2	2	3	5	3	1	1	..	17 = 1.22
Fracture of the ribs	1	1	8	4	10	8	5	3	40 = 2 87
Fracture of the sternum	..	1	..	2	.	2	..	..	5 = 0.359
Fracture of the scapula	..	..	3	2	4	2	2	..	13 = 0.93
Fracture of the clavicle	27	6	5	2	8	3	1	..	54 = 3.87
Upper extremity (571 cases, 40.99 per cent.)									
Humerus, fractures of (194 cases, 13.93 per cent.):									
Fracture of anatomical neck		..	..	..	2	1	..		4 = 0.29
Fracture of greater tuberosity	..	2	4	11	4	8	1		30 = 2.15
Fracture through the tuberosities	.	..	..	2	2	4	2		10 = 0.71
Fracture of the surgical neck	1	6	.	4	3	6	1		22 = 1.57
Epiphyseal separation, upper end	1	6	..	..	..	..	..		7 = 0.509
Fracture of the shaft	5	5	4	1	1	2	..		18 = 1.29
Fracture, supracondylar	36	4	2	.	1	..	1		43 = 3.08
Fracture, supracondylar-intercondylar	..	3	1	2	1	2	1		11 = 0.78
Fracture, external condyle	5	6	2	.	2	.	..		15 = 1.07
Fracture, internal epicondyle		17	1	..	.	.	..		18 = 1.29
Epiphyseal separation, lower end	8	2	.	..	.	.			10 = 0.71
Fracture, cubital process	..	5	.	.	.	..	.		6 = 0.43
Radius and ulna, fractures of (238 cases, 17.09 per cent.):									
Fracture both bones, upper end	1	1	1	2	.	1	..		7 = 0 509
Fracture of shaft of both bones	23	11	4	6	2	1	.		47 = 3.37
Fracture both bones, lower end	8	23	5	15	11	13	4		80 = 5.74
Radius, fractures of (73 cases, 5.24 per cent.):									
Fracture, head and neck of radius	3	5	9	3	2	1	..	..	23 = 1.65
Fracture of radius, shaft	2	4	4	2	.	..	.	..	12 = 0.85
Fracture of radius, lower end	8	23	5	15	11	13	4	1	80 = 5.74
Ulna, fractures of (31 cases, 2.22 per cent.)									
Fracture of olecranon and coronoid processes	..	2	4	4	1	..	..	..	11 = 0.78
Fracture of ulna, shaft	1	2	4	6	1	.	..	..	15 = 1.07
Fracture of ulna, lower end	..	2	..	2	1	..	..	..	5 = 0.359

TABLE III (PLAGEMANN)—*Continued*

STATISTICS FROM ROSTOCK CLINIC BASED UPON 1393 CASES. CONFIRMED BY RONTGENOGRAM

	1–10	11–20	21–30	31–40	41–50	51–60	61–70	71–90	Number of Cases and Percentages
Bones of hand, fractures of (139 cases, 9.98 per cent.):									
(*a*) Carpal fractures (29 cases, 2.08 per cent.):									
Fracture of the scaphoid	.	1	4	3	3	1	1	..	13 = 0.93
Fracture of the semilunar	..	1	1	1	1	1	..	.	5 = 0.359
Fracture of the cuneform	..	..	1	1	1	..	..	.	3 = 0.21
Fracture of the os magnum	..	..	..	..	1	.	..	.	1 = 0.07
Fracture of several carpal bones	..	1	..	4	1	1	.		7 = 0.509
(*b*) Metacarpals	1	5	8	7	2	8	2	..	35 = 5.405
(*c*) Phalanges	8	12	22	18	13	..	2	..	75 = 5.405
Lower extremity (585 cases, 41.99 per cent.)									
Femur, fractures of (150 cases, 10.81 per cent.):									
Fracture of neck of femur below head	..		..	2	1	3	2	3	11 = 0.78
Fracture of neck of femur about middle	..	.	..	2	.	5	5	8	20 = 1.43
Fracture through trochanters and neck	..	..	..	1	..	1	2	1	5 = 0.359
Fracture of neck of femur near trochanters	..	..	..	1	3	6	2	12	24 = 1.79
Separation of upper epiphyses of femur	..	4	..		..	..	..	.	4 = 0.29
Fracture through the trochanters	..	..	..	1	3	1	2	..	7 = 0.509
Fracture of the great trochanter	..	..	..	..	..	..	1	1	2 = 0.149
Fracture below the trochanters	3	1	..	1	..	1	3	2	11 = 0.78
Fracture of the shaft of the femur	30	7	5	4	..	7	1	1	55 = 3.94
Fracture supracondylar, of femur	3	2	..	1	.	1	1	.	8 = 0.57
Fracture of internal epicondyle	.	2	..	4	1	..	.	..	7 = 0.509
Fracture of condyle of femur	..	..	..	1		..	1	.	2 = 0.143
Separation of lower epiphyses of femur	..	2	..	..	.	..	.	..	2 = 0.143
Patella, fractures of (35 cases, 2.51 per cent.)	1	3	5	11	5	7	2	1	35 = 2.51
Bones of leg, fractures of (286 cases, 20.53 per cent.									
Fracture of upper end of tibia and fibula	..	.	..	1	1	1	1	.	4 = 0.29
Fracture of shaft of tibia and fibula	1	10	13	23	19	11	11	4	92 = 6.604
Intramalleolar fracture of both bones	1	..	1	6	7	5	..	2	22 = 1 57
Fracture of lower end of tibia and fibula	1	9	4	11	10	7	6	2	50 = 3.59
Tibia, fractures of (61 cases, 4.38 per cent):									
Fracture of upper end of tibia	1	2	4	5	6	..	..	1	19 = 1.36
Fracture of shaft of tibia	7	10	3	1	2	1	..	.	24 = 1.79
Fracture of lower end of tibia	.	3	5	4	2	2	2		18 = 1.29
Fibula, fractures of (57 cases, 4.09 per cent.):									
Fracture of upper end (head and neck)		5	7	..	..	..	..	1	13 = 0.93
Fracture of shaft of fibula	1	1	6	11	6	3	1	1	30 = 2.15
Fracture of external malleolus	.	2	1	3	5	2	1	.	14 = 1.005
Bones of foot, fractures of (114 cases, 8.18 per cent.):									
Fracture of calcaneus	.	1	..	6	1	1	4	..	17 = 1.22
Fracture of astragalus	.	1	..	1	2	..	1	..	5 = 0.359
Fracture of calcaneus and astragalus	..	..	1	1	1	..	1	..	4 = 0.29
Fracture of scaphoid	.	1	2	2	1	1			7 = 0.509
Fracture of cuboid	..	..	1	..	.	..	..		1 = 0.07
Fracture of cuneiform	..	..	1	2	..	..	..	..	3 = 0.21
Fracture of metatarsals	1	12	8	12	6	4	5	..	49 = 3.51
Fracture of phalanges	1	4	8	6	5	..	..	..	24 = 1.71
Fracture of sesamoids	..	..	1	2	1	..	..	.	4 = 0.29

Relationship of Fractures to Age, Sex and Season.—The influence of age upon the production of fractures is shown by Plagemann, not only as regards the periods of life in which fractures are most frequently seen, but also in the fact that certain types of fractures are more frequent at various periods of life. In the first and second decades the most frequent forms of fracture are the incomplete, the subperiosteal and epiphyseal separations, the bones most frequently involved being the clavicle, the lower end of the humerus, and the lower end of the radius. During the third, fourth, and fifth decades, the fractures most frequently met are those of an occupational violence and those of direct violence, the bones most frequently affected being the bones of the leg, the femur, the humerus, and the skull. During the sixth and seventh decades other influences are at work in the production of fractures. In this period we find the bones more brittle, the muscular tone of the body diminished, the special senses not so acute, and as a result we have most frequently fractures of the upper end of the femur, of the upper end of the humerus, and the lower end of the radius. It may be stated that, as a general rule, fractures occur in the greatest number during the second, third, and fourth decades of life.

Fractures are more frequently seen in men than in women. They occur in the proportion of about 4 to 1. The fact of this disproportion is due to the more active life of the male at all ages, to the occupations assumed by the male, and to the fact that men spend so much more time out of doors. During the third, fourth, and fifth decades fractures occur among men six or seven times more frequently than in women. In infancy and old age the proportion of fractures occurring in the two sexes is about equal. In old age fractures are a little more frequent in the female and are most often fractures of the upper end of the femur.

The influence of season in the occurrence of fractures is shown in the frequency of fractures seen in the summer season as compared with the winter season. This is due entirely to the fact that we are more active, spend more time out of doors, and that the various building trades and all business, in fact, are carried on more actively in the summer season. The occurrence of ice and snow in winter may perhaps modify these conclusions in some places.

Etiology of Fractures.—For the production of a fracture certain etiological factors must be present. These may be divided into (1) predisposing causes, and (2) the exciting or determining causes. Fractures may be divided into (1) traumatic and (2) pathologic fractures.

Predisposing Causes.—Certain bones are predisposed to fracture on account of their exposed position, curves, their function as levers, or the small proportion of osseous tissue. Other bones are less liable to

fracture owing to their unexposed position, their mobility, and the protection afforded by overlying muscles. Other factors are the elastic and yielding character of bones in infancy and adolescence, and in old age the brittle character of the bones, from senile atrophy and thinning of the cortex of the bones.

A predisposing factor of diastasis or epiphyseal rupture in early age is the presence of the epiphyseal cartilages; epiphyseal separations occur only at this period of life.

EXCITING CAUSES OF FRACTURE.—The exciting causes of fracture are (1) external violence, and (2) muscular action.

Fractures by External Violence.—These may be divided not only by the mechanical modes of their production, but also by the clinical difference into two classes—fractures by direct violence and fractures by indirect violence. In fractures by direct violence the bone is broken immediately beneath the point of the fracturing force. In fractures by indirect violence the fracture does not occur at the point immediately below the point of the producing force, but at a point distant. Fractures by direct violence may be complicated by extensive injury to the overlying soft parts, by sloughing of the parts, or by the production of an open or compound fracture. Examples of fracture by direct violence are fractures of the calcaneum by falls upon the feet, fractures caused by kicks, by falling timbers and by being struck with some heavy instrument, and gunshot fractures. In fractures by indirect violence the fracturing force is conveyed through the intervening bones; and the break occurs by leverage, torsion, or traction. Such forces produce occasionally transverse fractures, more generally, oblique, spiral, or comminuted fractures. Examples of fractures by indirect violence are fractures of the clavicle from a fall upon the hand, oblique or spiral fractures of the bones of the leg, fractures by torsion seen in fractures of the humerus and the so-called strength test, fractures by traction seen in fractures at lower end of elbow and at ankle in forced flexion, extension, adduction, or abduction.

Fractures by indirect violence more frequently involve the long bones because of their length, shape, and muscular and ligamentous attachments. Fractures by indirect violence may be modified according to the condition of the muscles of the part, the direction of the fracturing force, the position of the parts, and the anatomical structure of the bone involved. This is illustrated by the various forms of fracture that may occur in a fall upon the palm of the hand. Thus we may have fractures of the radius, humerus, or clavicle.

Fractures by Muscular Action.—Bones may be fractured (1) by the sudden contraction of muscle alone; (2) by contraction of muscles with part of the bone fixed so that a lever action is produced; and (3) by the sudden muscular action of a part in motion producing sudden arrest

of the part. Examples of the first class are fractures of the patella, of the olecranon, of the tuberosity of the calcaneum; examples of the second class are spiral or oblique fractures of the humerus in wringing out clothes, and in the so-called strength test; examples of the third class are fractures produced by throwing and lifting, shovelling. Other examples of fractures produced by muscular action are fractures of the ribs from violent coughing, fractures of the bones of the leg in missing steps, fractures of the long bones during the contractions of tetanus.

The patella is the bone most frequently fractured by muscular action. Next in order are the olecranon, the greater tuberosity of the humerus, occasionally the coracoid and acromion processes of the scapula, and many atypical fractures at the site of insertion of powerful muscles. Sprain fractures form a large class of fractures produced by muscular action.

Gunshot Fractures.—In considering the etiology of gunshot fractures, one must bear in mind that the resulting lesions vary greatly, depending upon the velocity of the bullet, its size, the part of the bone involved, and upon whether the lesions are produced in military or civil life. The character of the fracture produced by the high velocity bullet of war is entirely different from that produced in the ordinary revolver wound. Various degrees of bone lesion may occur. These may be classified as (1) a fissured fracture of one side of the cortex. (2) A depression of the cortex. (3) A transverse comminuted or fissured fracture without perforation of the bone. (4) A perforation of the bone. When this last form occurs in the spongy bone near the articular end of long bones or in flat bones, there is generally no comminution; when the shaft of the bone is involved there is generally extensive fissuring, comminution and destruction dependent upon the line of the projectile. (5) Guttered or notched fractures may be produced when only a small portion of the circumference of the bone is involved.

Fractures produced in military life are generally less extensive and less complicated by injury to soft parts than in former years, and the mortality has been greatly reduced. This is due to the high velocity of the bullet, its decreased size, its tendency to perforate without extensive comminution, and to the fact that wounds produced by it are, as a rule, aseptic. Fractures produced in civil life by the ordinary low velocity large-sized bullet are generally more comminuted, the destruction of the bone is greater, injury to the overlying soft parts is more extensive, and infection is more frequent. Fractures produced by bird-shot are rare, and are only possible when the distance is short, or the bone injured is very thin. The associated lesion of the soft parts is the chief characteristic, and in some the associated injuries to viscera are very important. Shrapnel causes great mutilation of all structures.

PATHOLOGIC FRACTURES.—This term is given to that class of

fractures which follows some slight injury, or muscular action alone, or without any demonstrable cause. Pathologic fractures are met in bones in which there is a brittleness or lack of resistance due to a local lesion or to a general disease producing a general fragility of the osseous structures. These fractures are sometimes termed spontaneous fractures. It can be readily understood why fracture may occur in bones the seat of local lesions in which the osseous tissue is destroyed and replaced by other forms of tissue. It has been observed by several authors that in cases in which spontaneous fractures occur there have been found in



Fig. 1.—Osteomyelitis (typhoid) of femur. Pathologic fracture. Patient fell while wearing a brace.
Fig. 2.—Sarcoma of right humerus. Pathologic fracture.

the urine varying quantities of phosphoric acid. It has been suggested that this has been the result of the decalcification of the bone by some metabolic process, for which we are at present unable to account. These changes have been observed in cases of cancer and diabetes.

Pathologic fractures may be classified as follows: (1) fractures the result of local bone disease; and (2) fractures in which the rarefaction of the bone is the result of a general disease. Of the first class fractures have been observed in the following conditions:

A. Inflammatory processes: (1) Infectious osteomyelitis (Fig. 1); (2) tuberculous osteomyelitis.

B. New growths of bone: (1) Sarcoma, primary (Fig. 2), and metastatic; (2) carcinoma, metastatic (Figs. 3 and 4); (3) benign bone cysts; (4) myeloma (albumosa); (5) lymphomata, malignant, metastatic; (6) metastatic tumors, thyroid in origin; (7) metastatic tumors from the adrenal; (8) echinococcus cysts.

C. Aneurisms.

D. Fracture the result of fragility of bones due to a general disease.

FIG. 3 FIG. 4



FIG. 3.—Pathologic fracture of right femur due to metastasis from carcinoma of left breast. Operated two years previously; local recurrence in scar, left axillary and supraclavicular regions.

FIG. 4.—Pathologic fracture of right humerus due to metastatic growth from primary carcinoma of prostate gland.

Of the second class fractures have been observed as follows:

A. Disease of the nervous system: (1) locomotor ataxia; (2) syringomyelia; (3) paresis.

B. Rickets.

C. Syphilis.

D. Idiopathic rarefaction.

E. Rarefaction from disease.

F. Osteomalacia; scurvy; rarefaction due to chronic diseases; diabetes; osteitis deformans; osteogenesis imperfecta.

Fractures in Utero.—Intra-uterine fractures are of two kinds, (1) spontaneous fractures, and (2) pathologic fractures. The spontaneous fractures may be the result of external violence, as blows, kicks, punctured and bullet wounds to the mother, which is extremely rare, but children have been borne with one or more fractures, some in a state of partial union in which there has been a history of external

violence. Pathologic intra-uterine fractures are generally the result of syphilis, rickets, osteochondrosis, parenchymatous osteitis or amniotic adhesions. Very often it is difficult to differentiate intra-uterine from intrapartum fractures.

Intrapartum Fractures.—Fractures may occur during delivery. They may be spontaneous, but as a general rule they are the result of faulty management of the delivery, or disproportion of the size of the fœtus and the pelvis, or undue haste. The bones most frequently fractured are the femur, humerus, clavicle, tibia and fibula, radius and ulna. The most common lesion is epiphyseal separation, although fractures of the shaft of the bone may occur.

Varieties of Fracture.—Fractures should be classified as to variety as follows:

A. Fractures considered in relation to the condition of the surrounding soft parts: Fractures are divided into two classes: (1) closed fractures; and (2) open fractures. A closed fracture is one in which there is no communication between the outside air and the seat of fracture. They are sometimes designated as simple or subcutaneous fractures. An open fracture is one in which the seat of fracture is exposed to atmospheric contact through a wound of the muscles, fascia, and skin. These fractures are sometimes called compound fractures. The open character of the fracture may be due to the direct vulnerating force, to projection of the end of a fragment through the soft parts, to the weight of the unsupported limb, or the subsequent sloughing of the overlying soft parts. It can be readily understood that open fractures are more dangerous and lead to more complications than closed fractures. Union is less rapid, and infection followed by osteomyelitis and septicæmia may occur, necessitating amputation occasionally as a last resort. Death is not unusual in infected fractures, unless the lesion is treated with an aseptic or antiseptic technic and great surgical skill.

B. Fractures classified according to degree: Fractures may be classified as (1) incomplete, and (2) complete.

1. Of the incomplete fractures (Fig. 5) we have:

(*a*) Fissures. This form of fracture consists in a linear break without separation of the fragments to any appreciable extent. The most frequent sites are the vault and base of the skull; and the humerus and tibia. When they involve the long bones they as a rule begin at the articular surface.

(*b*) Infraction; green-stick or true incomplete fracture. This is a fracture involving only a portion of the diameter of the shaft with bending or angulation of the remaining fibres at the point of fracture. It occurs only in children, whose bones are normally elastic from a relatively large amount of organic material in their composition. It

happens most frequently in the bones of the forearm, clavicle, tibia, femur and humerus.

(*c*) Depressions or indentations. This variety of fracture is a depression of the cortex of the bone without complete fracture as a result of direct external violence. It is most commonly observed in the skull, involving the outer table, and in the spongy bones.

(*d*) Splitting of a portion of the cortex. This is a separation of the fibres of the cortex, with possibly a part of the underlying spongy bone as a result of direct violence. It does not involve the entire thickness of the bone and is generally produced by a sharp-cutting instrument like an axe or sabre.

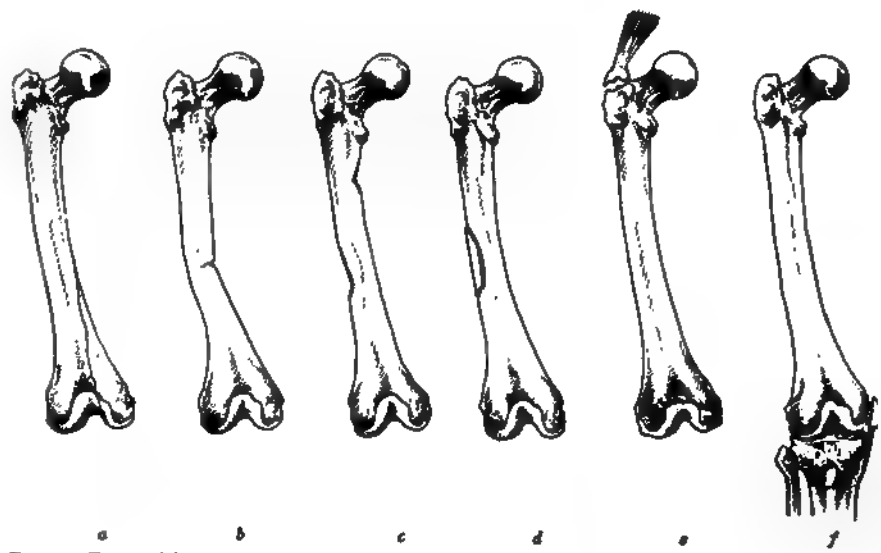

FIG. 5.—Types of fractures. *a*, fissure; *b*, infraction; *c*, depression or indentation; *d*, splitting of a portion of cortex; *e*, separation of an hypophysis; *f*, sprain fracture.

(*e*) Separation of an hypophysis; sprain-fracture. These fractures occur as a result of violent and sudden muscular action, tearing off a small process of attached bone, or are due to a sudden increase of tension upon a ligament, producing the same result. Sprain-fracture is very frequent according to Ross and Stewart, who estimated it to occur in 15 per cent. of all fractures. The lesion generally consists of the tearing off of a small scale of bone, to which a muscle, tendon, or ligament is attached, close to a joint.

2. A complete fracture is one in which the line of fracture involves the entire thickness of the bone, separating it into two or more frag-

sidered in relation to the direction and character
e (Fig. 6):

(*a*) Longitudinal. Longitudinal fractures are those in which the line of fracture is not further from the long axis of the bone than 15 or 20 degrees. They are extremely rare, except in perforating fractures such as are caused by gunshot wounds.

(*b*) Transverse. In this variety the plane of fracture makes nearly a right angle with the long axis of the bone. Transverse fractures are rare. They are most frequently found in the lower end of the radius, the middle of the humerus, the patella, and the flat bones. At times they are caused by muscular action.

(*c*) Oblique. This variety is characterized by a single or double line of fracture, making an angle with the long axis of the bone; which is neither that of a longitudinal nor that of a transverse fracture. The majority of fractures are oblique. It is most commonly observed in fractures of the shaft of the humerus, tibia and femur. Such fractures may be multiple.

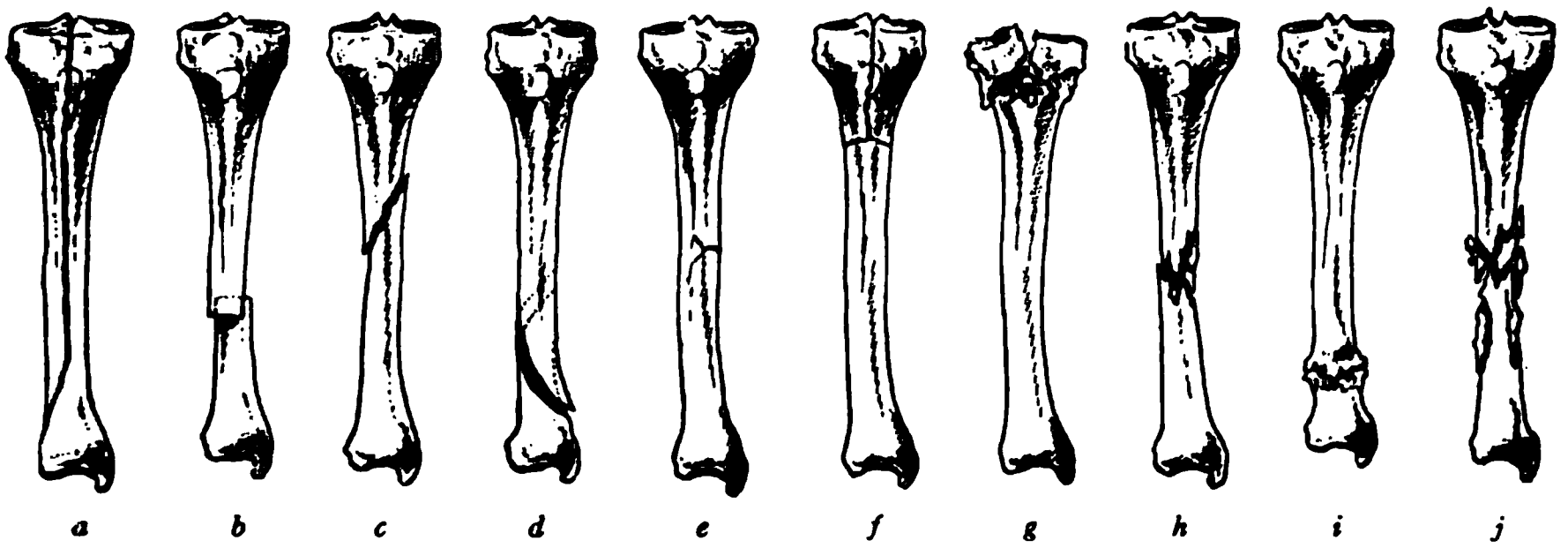

FIG. 6.—Fractures considered in relation to the character and line of fracture: *a*, longitudinal fracture; *b*, transverse; *c*, oblique; *d*, spiral; *e*, subperiosteal; *f*, V-, T-, or Y-shaped; *g*, compression; *h*, comminuted; *i*, impacted; and *j*, crushing.

(*d*) Spiral. In this variety the line of fracture is a prolonged oblique fracture encircling the entire circumference of the bone. It is produced by torsion, or twisting, when a part of the extremity is fixed. The tibia, humerus, and femur are most frequently involved. A subvariety of this fracture is the third fragment fracture, which consists of a small third fragment being detached at the seat of fracture. This type of fracture is also seen in some types of oblique fracture.

(*e*) Subperiosteal. This term is given to that form of fracture generally transverse in direction in which there is no separation of the fragments and the periosteum is not lacerated. Such lesions generally result from direct violence, and are most frequently seen in the tibia and radius and ulna.

(*f*) V-, T-, or Y-shaped. These fractures are so named from the direction of the lines of fracture resembling the letters named; and are most frequently seen at the lower end of the humerus and the lower end of the femur.

(*g*) Compression. Compression fractures are those due to a driving together of the cortical and spongy layers of bone as a result of condensing force. They are seen most frequently in the calcaneum, astragalus, and vertebræ, and result most frequently in falls from a height, when the patient lands on the soles of his feet.

(*h*) Comminuted. When there are not only two fragments, but the bone has been extensively splintered at the seat of fracture, the injury is termed a comminuted fracture. This form is seen most frequently in the long bones as a result of gunshot injuries or when the bones have sustained injuries from great forces or are brittle because of senile changes.

(*i*) Impacted. This variety of fracture is the result of violent driving together of the two fragments, so that the fibres become entangled and immobility with fixation is present. It is seen chiefly in fractures at the neck of the femur, lower end of the radius, and the cervical neck of the humerus

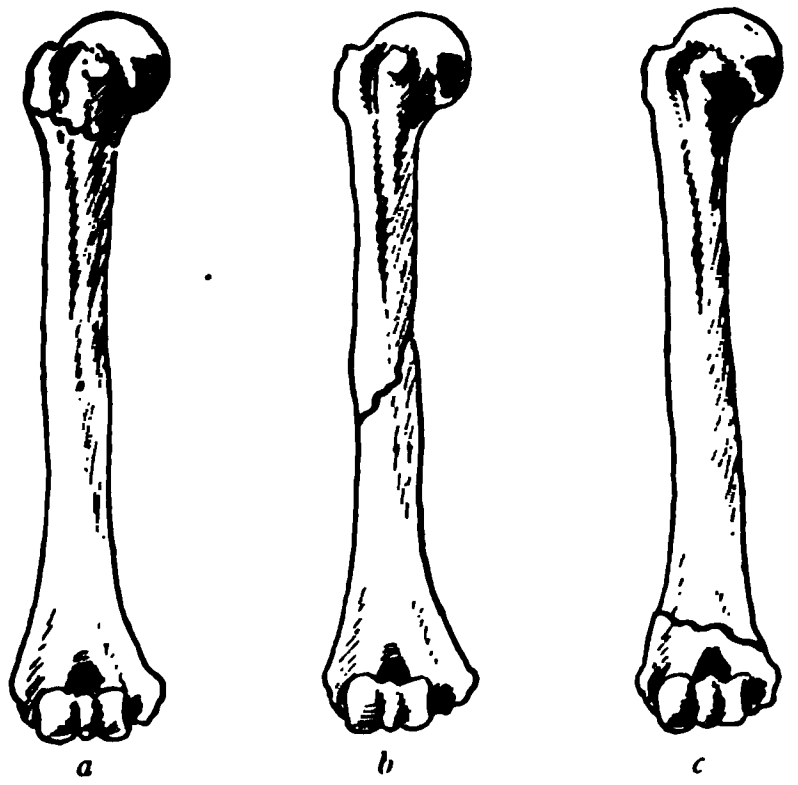

FIG. 7.—Fractures considered in relation to the position of the fracture: *a*, upper end; *b*, shaft; and *c*, lower end.

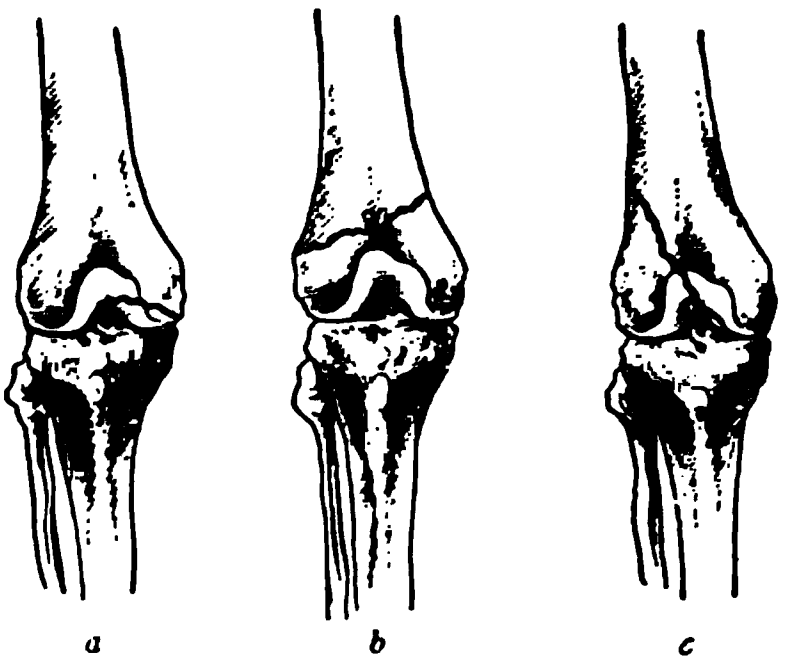

FIG. 8.—Articular fractures. *a*, intra-articular; *b*, para-articular; and *c*, true-articular.

(*j*) Crushing. This variety of fracture is seen as a result of direct violence, as when a heavy body, like the wheel of a wagon, passes over the foot. It is a form of comminuted fracture. It is found most frequently in the carpal or tarsal bones, and differs from the compression fracture in that the latter is the result of indirect violence, as a rule, while the former is due entirely to direct violence.

D. Fractures considered in relation to the position of fracture (Fig. 7): Fractures are generally referred to as involving certain portions of a bone, such as fracture of the shaft, fracture of the upper or lower ends of a bone; fractures of certain parts of the shaft, as fracture of the middle of the shaft of the femur; fracture of certain prominences, such as fracture of condyles, or apophysis.

E. Fractures involving a joint or articular fractures are those

fractures in which the joint surface is involved in the line of break (Fig. 8). They comprise three classes: (1) Intra-articular fractures in which the line of fracture is entirely within the joint; (2) para-articular fractures in which the line of fracture is near the joint, so that subsequent healing may directly interfere with joint functions, and (3) true articular fractures in which the line of fracture involves both intra- and extra-articular bone. All of these fractures may vary from a simple fissure with no laceration of the capsule to an extensive comminuted fracture with extensive lacerations of the capsule. The most common type of articular fractures are those of the neck of the femur, of the lower articular end of the humerus, of the lower end or the head and neck of the radius, fracture about the ankle-joint, and fracture of patella and of the olecranon.

F. Epiphyseal separations: These consist in a partial or complete separation of the epiphysis from the diaphysis before the time when

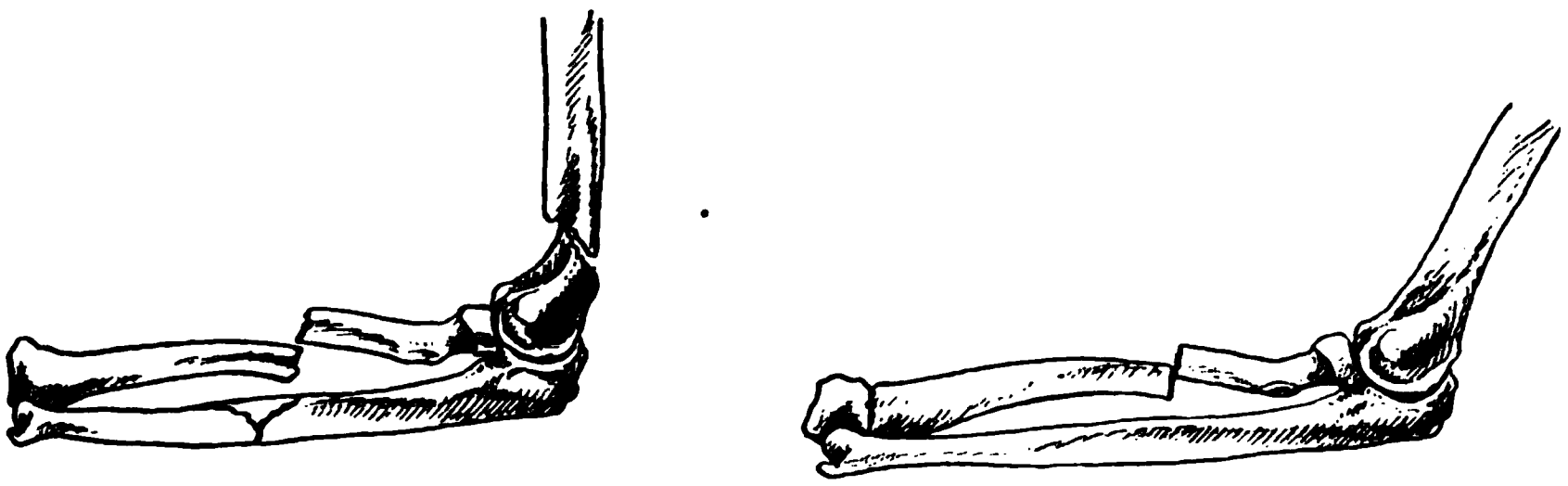

a *b*

FIG. 9.—Fractures considered in relation to the number of fragments; *a*, multiple fracture, and *b*, double fracture.

ossification takes place in the epiphyseal cartilage. In females the last epiphysis unites about the twenty-third and in males about the twenty-fifth year. The epiphyses most frequently involved are lower epiphyses of femur, radius and humerus, and the upper epiphysis of humerus. In epiphyseal separations there is generally a portion of the diaphysis carried away with the epiphysis. The injury is usually the result of excessive strain upon the articular ligaments. There is always the possibility of arrest of growth in the bone affected, due to faulty replacement of the epiphysis or to premature ossification of the epiphyseal cartilage.

G. Fractures considered in relation to the number of fragments: In contra-distinction to the varieties of fracture which presuppose that the break is limited to or radiates from one point, there are *multiple* fractures (Fig. 9, *a*). This term is applied to fracture of two or more bones, and sometimes to more than two non-communicating lines of fracture in a single bone. Fractures occurring in two adjacent bones, like the ulna and fibula, are not designated as multiple fractures. The term *double* fracture (Fig. 9, *b*) is applied to two unconnected lines of

fracture occurring in the same bone. Multiple fractures are usually the result of direct external violence, and frequently the force is very great. Fractures of this variety are often troublesome to treat satisfactorily, because of the difficulty of enforcing quiet upon the patient. There may be, in addition, considerable destruction of the overlying soft parts on account of the degree of the violence sustained at the time of injury.

Displacement of Fragments.—The relative position of the fragments of a broken bone gives rise to several forms of displacement. While the classification of Malgaigne has been, as a rule, adopted in considering displacement of fragments, it should be realized that displacements are generally a combination of two forms of displacement. As a rule it is the distal fragment which occupies the abnormal position.

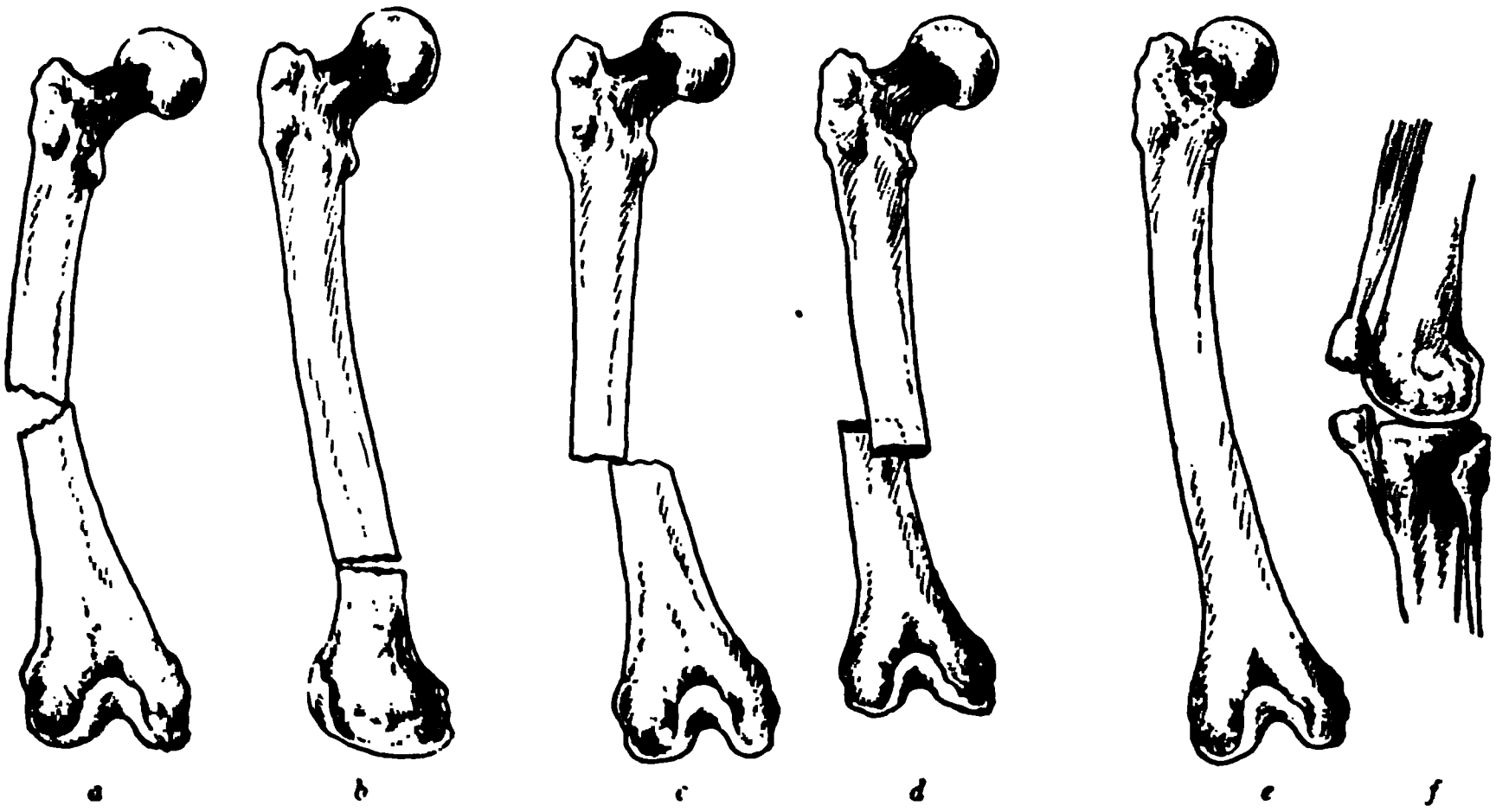

FIG. 10.—Varieties of displacement of fragments: *a*, angular; *b*, rotary; *c*, transverse; *d*, longitudinal; *e*, impaction or crushing; and *f*, diastasis or longitudinal with separation.

Transverse fracture of the olecranon and patella are exceptions to this rule. In comminuted fractures the displacement is too complex in nature to permit of classification.

Varieties of Displacement (Fig. 10).—The forms of displacement may be classified as:

(1) *Angular displacement*, or tilting, in which the axes of the fragments form an obtuse angle. This form of displacement is most commonly seen in green-stick fractures.

(2) *Rotary displacement*, consisting in rotation of one fragment on its long axis in relation to the other fragment. The rotating fragment is generally the distal, or lower, the fixed fragment is the proximal, or upper, one. The best example of this type of displacement is seen in fracture of the neck or shaft of the femur.

(3) ***Transverse displacement*** consists in a deviation of the frag-

ments anteroposteriorly or laterally or a combination of the two. This form is very rare, and is seen generally in combination with some other form of displacement. The usual position of this form is in transverse fracture of femur or humerus.

(4) *Longitudinal displacement* is a change in the length of the bone. Overlapping of the fragments is the common displacement. It is generally combined with other varieties of displacement, and is most common in oblique and spiral fractures. Separation of fragments occurs in fractures of patella and olecranon.

(5) *Impaction or crushing displacements* consist in the penetration of a broad fragment by a narrow one (impaction) or in the destruction of the osseous structure into small pieces (crushing). Impaction displacement is usually accompanied by rotary displacement, and is most common in fractures of the neck or through the trochanters of the femur, fractures of the upper end of the tibia, and of the lower end of the radius. Crushing displacements are most commonly seen in fractures of the tarsal bones.

(6) *Diastasis* should be applied only to epiphyseal separations. It is sometimes used for a separation of the fragments of the bone in fractures such as occur in breaks of the patella and olecranon.

Fractures in Which No Displacement Occurs.—In some varieties of fracture there is no displacement of the fragments. This may be due to (1) incompleteness of the line of fracture, as in fissure fracture; (2) to the fragments being held together by the surrounding periosteum and muscles, and occasionally by a parallel bone, as in subperiosteal fractures and fractures of the forearm and of the fibula; and (3) to the support of surrounding ligaments, as in some fractures of the patella and olecranon.

Etiology of Displacement of Fragments.—Displacement of fragments is due to several causes. The chief are the fracturing force and muscular contraction. Œdema and infiltration of the soft parts, and muscular spasm keep up deformity. Muscular action in nearly every instance causes shortening, excepting in fractures of the patella, olecranon, and separation of epiphyses and apophyses. In these fractures the longitudinal deviation consists generally in separation of the pieces of bone. This is due to the powerful muscular attachments to one of the fragments. It is not always possible to predict the character and extent of displacement that will occur in a fracture at a given locality, for it depends on the direction and nature of the line of fracture as well as on the muscular attachments. Displacements occur more frequently and in greater variety in oblique and spiral fractures and less frequently in transverse fractures.

Symptomatology.—The examination of every case of suspected fracture should proceed in a systematic manner. A careful history of

the accident, its nature and time should be first obtained. The previous history should be noted, and the possibility of a pathologic fracture and of deformities from previous injuries should be remembered. The patient should be examined as soon as possible after the receipt of the injury, unless there is marked shock present. In this way one may often detect fractures more readily, because swelling and ecchymosis and spasm of the muscles have not taken place. If, however, there is considerable shock present, it is advisable to defer examination until it has passed.

All clothing that may interfere with a careful examination of the part should be removed. It is also advisable to remove the clothing from the same part of the opposite side, so that the anatomical landmarks of the uninjured and injured sides may be carefully compared. This simple expedient will enable the surgeon to make a proper examination and help him arrive at an accurate diagnosis.

In many cases it is advisable to use a general anæsthetic, so that a thorough examination may not be prevented by reason of pain and muscular spasm. In children this is especially true, and anæsthesia is frequently required. At the same time reduction and immobilization may be performed.

The symptoms produced by a recent fracture may be divided into two classes: objective symptoms and subjective symptoms. The objective symptoms are deformity, abnormal mobility of the part, crepitus, and œdema and ecchymosis. The subjective symptoms are pain and tenderness, loss of function or impaired motion, intermittent muscular spasm.

DEFORMITY.—This is principally due to the displacement of fragments. Deformity is not always present. Fissure fractures and some impacted fractures give little if any deformity. Deformity is determined by inspection, palpation, and measurements of the parts. It is the result of several factors. These are, the fracturing-force, the weight of the distal portions of the limb, the pull exerted by certain groups of muscles, and the œdema and ecchymosis infiltrating the soft parts about the seat of fracture.

In many cases inspection will show the presence and site of fracture, which are confirmed by palpation. The non-injured side or symmetric part should always be examined and compared with the injured part. In considering the degree or existence of deformity, previous fractures and injuries should be taken into account, as well as exostoses, periosteal nodes, and shortening from chronic inflammatory conditions of joints and contracted tendons. The recurrence of deformity when restraining forces are relaxed is often a distinguishing characteristic of fracture and serves to differentiate it from dislocation. Careful and repeated measurements from fixed bony points should

always be made. This is only reliable in estimating shortening when the two sides are placed in the same relative positions; and then there is always some element of doubt if the subject is obese or there is moderate deformity or œdema. It should always be remembered that often there is an inequality in the length of the normal bones of the two halves of the body. This at times has been found to be from one to one and a half inches in the lower extremities. This asymmetry of uninjured long bones of the upper and lower extremities has an important bearing in medico-legal cases. Its relation to the prognosis in fracture treatment is readily seen.

ABNORMAL MOBILITY OF THE PART.—This is absolute proof of a fracture, excepting in very extensive dislocations. Abnormal mobility is sought by endeavoring to move one portion of the bone independently of the other. In doing this one may produce one or more of the various types of displacement. Absence of mobility must not be assumed until all forms of displacement have been attempted, as it is likely that displacement may be possible only in certain directions. Abnormal mobility is absent in incomplete, subperiosteal, and impacted fractures and occasionally in fractures involving joint surfaces. When one of two bones is broken the abnormal mobility may be slight. In some fractures the normal elasticity of the part or the proximity of a joint may simulate abnormal mobility and mislead the examiner. Error may thus occur in injuries of the sternum, ribs and fibula; in hurts near joints, because, there, motion is the normal condition; and in fractures in which the fragments are so small or deep-seated that they cannot be firmly grasped. This diagnostic difficulty is observed often in fractures of the surgical neck of the humerus, metatarsal fractures, and in atypical fractures of the upper end of the femur.

Abnormal mobility may be readily demonstrated in the shaft of a bone broken near its middle by placing the hand under the part at the supposed seat of fracture and endeavoring to raise it with this single point of support. Motion and angular displacement immediately result. It may also be determined in some cases by placing a finger of each hand upon the supposed upper and lower portions of a small fragment and producing a rocking motion. This may be seen in fractures involving the lower two inches of the fibula or of the ribs.

CREPITUS.—This is a rubbing sensation, conveyed to the examiner's hand, and is produced by forcible manipulation of the parts. The motion may give rise to a grating sound audible to the bystanders. In order that crepitus may be produced, certain factors are necessary. The ends of the fragments must be in apposition or capable of being brought into apposition by the surgeon or a third person, causing traction when manipulation is made. It is absent in impacted, green-stick, and incomplete fractures. It cannot be produced if the ends of

the fragments are separated, as in fractures of the olecranon and patella, if there is marked over-riding so that smooth portions of the bone are in apposition, or if portions of muscle, fascia, ligament, or other structures intervene. In old fractures, when the ends of the fragments have become covered with fibrous tissue, and in delayed union of fractures or pseudo-arthroses true crepitus is no longer to be elicited.

Fracture crepitus may be confounded with joint crepitus, with the fine crackling noted in inflammatory conditions of tendon sheaths and bursæ, and with various sounds resulting from cellular emphysema and pleuritic adhesions. The crepitus made upon manipulation may be discernible to the patient. It can often be distinguished by placing the palm of the hand over the seat of the injury, as in fracture of the ribs.

Œdema or Swelling.—This can hardly be classified as a distinct symptom of fracture because subcutaneous pouring out of blood and serum occurs in all severe injuries, yet it occurs so frequently with any forms of fracture that its importance should not be neglected. This serous or bloody swelling may be rapid and appear not only as generalized infiltration of the soft tissues surrounding the fracture, but may be shown by blebs or small vesicles occurring on the surface. These are filled with turbid or bloody serum.

Ecchymosis.—Bleeding into the interstices of the tissues, as a result of contusion of the soft parts overlying the broken bone, occurs within the first twenty-four hours. Ecchymosis appearing after the lapse of several days indicates that the blood has escaped from deep structures. This may begin to show after the first twenty-four hours, or may not be seen for four to five days. It is generally indicative of a fracture. The time of its appearance is due to the difficulty of reaching the surface through periosteum, muscles, and fascia. It may occur at a distance from the seat of fracture and shows in a dependent part of the body or limb, which it reaches by gravity. Very often ecchymosis is accompanied by the occurrence of blebs, and in some cases the parts may be so badly discolored as to lead the inexperienced to diagnose gangrene of the part. The absorption of the blood is generally very tardy, and the fracture may be firmly united before the final disappearance of the extravasation.

Pain and Tenderness.—Pain is a usual symptom in fractures. It varies greatly in severity. In fissured, incomplete, or impacted fracture pain may be slight. Pain is great in fractures involving a single supporting bone of a part, and in those in which a nerve is caught between the fragments or pressed upon by infiltration of the soft parts or by callus. Pain as a rule is not great when the fragments are separated. Tenderness is noted particularly in fractures produced by direct violence. It is of diagnostic value in differentiating ob-

scure fractures from contusions and sprains, and in determining the seat of the lesion in periosteal fractures, sprain fractures, in fractures of the carpal bones, and in deep-seated fractures.

Loss of Function.—In the presence of fractures this may be the result of pain, or it may be due to the loss of continuity in the bone. Motions which do not give pain at the seat of fracture and which may be performed by reason of a supporting parallel bone may be accomplished in many cases. This is particularly so in fractures in which certain motions do not bring stress at the seat of fracture. Loss of function may be absent in incomplete, partial, and impacted fractures. It is a common occurrence to see patients walking around with fracture of the lower end of the fibula, and sometimes even of the upper end of the femur.

Intermittent Muscular Spasms.—These are often present and may cause great pain. They result from stimulation produced by excitation of terminal nerve filaments in the muscles about the seat of fracture. Numbness and occasionally complete paralysis may be present as a result of pressure upon a nerve or complete destruction of a nerve, either at the time of injury or by subsequent pressure of the fragments or by callus.

The constitutional symptoms of fracture are those of shock or of a subsequent inflammatory process. In the usual closed fracture constitutional symptoms are generally slight. There may be a slight rise of temperature noted during the first three to four days. In open fractures the constitutional symptoms are those that occur as a result of the complications of open fractures. In old age the constitutional symptoms are liable to be more marked, and fractures may have serious terminations from sequellæ in the senile that are rare in the young.

Diagnosis.—In suspected fracture the diagnosis may often be readily made; but there are cases in which one or several of the cardinal symptoms of fracture are lacking, and therefore the diagnosis may be extremely difficult. In these instances careful examination should be made under general anæsthesia and comparison made with the opposite symmetrical parts.

Diagnosis is difficult in fractures near joints. The chief causes are normal mobility present at a joint, the difficulty of thoroughly grasping the small fragments so as to elicit the objective signs of fracture, and joint crepitus. The most characteristic signs of articular fracture are effusion into the joint, generally bloody in nature, and mobility greater than that found normally at the involved articulation.

Dislocations may be confused with fractures near joints; but in dislocations the normal motions of the articulation are impaired, and there is generally a sudden or abnormal check to free movement in some directions on manipulation by the examiner. In fractures the

movements are generally preternatural; they may be unlimited. Spontaneous recurrence after reduction of dislocations is very infrequent, while in fractures deformity is liable to be reproduced when fixation is removed. In dislocations, voluntary motions are not so impaired as in fractures, and there is more rigidity, while in fractures there is the appearance of helplessness. In dislocations, specific positions of the part are impossible on account of the change in bearing points of the articulation, and the relations of the normal bony landmarks of the joints are changed.

Fractures may be differentiated from epiphyseal separations by noting the site of the suspected fracture, by considering the age of the patient, by the character of the crepitus, which is soft and more indistinct than in fractures, by the tendency toward slight displacement, and by the localization of the abnormal mobility and pain at the level of the epiphyseal cartilage. Separations of epiphyses are often followed by diminished growth in the length of the bone due to the involvement of the epiphyseal cartilage. Epiphyseal separations are generally accompanied by a fracture of the meta-epiphyseal end of the diaphysis, and rarely by a splitting of the epiphysis.

At times it is difficult to determine the exact location and line of fracture. This very important information may usually be determined by careful palpation, measurements from known fixed points, and the position of various related prominences. Often the exact line of the break can only be inferred unless X-ray examinations are made in two planes. In fractures without deformity or crepitus the localized pain and tenderness present may enable the line of break to be recognized with reasonable probability.

Many fractures are overlooked at the time of injury and are only discovered afterward by the presence of callus, or by the persistence of pain and tenderness, or by loss of function of the part. This error occurs in fractures of the ribs, metacarpals, carpals, tarsals, sternum, and forearm; and in incomplete, subperiosteal, impacted, and sprain fractures. Many of the symptoms of fracture may be absent in these injuries.

Röntgen Rays in the Diagnosis of Fractures.—The use of the Röntgen rays in the diagnosis of fracture and injuries to joints is of great value. They not only show the line of fracture but also the number and relation of fragments. An exception to this, however, is their use in certain types of early epiphyseal separations. The Röntgen rays, however, should not be employed to the exclusion of other means of diagnosis. They are of especial value in deep-seated fractures, in fracture near joints, in fractures of the carpal and tarsal bones, in sprain fractures, and evulsion fractures. Careful examination and skilled interpretation of the X-ray plate should be painstakingly made.

One should first familiarize himself with the X-ray photographs of the normal bone, and especially with the articular portions.

If there is an X-ray equipment at hand, it should be used routinely in the study of all suspected fractures. Only by this use of the X-ray will a surgeon become familiar with the normal parts. He will also make many more correct diagnoses of obscure injuries, and he will be better able to make diagnoses in fractures from previous knowledge gained in X-ray plate interpretation when an X-ray examination is not feasible. Routine fluoroscopic examination is probably not advisable. While it is useful in gross fractures, it does not show small obscure lesions, unless one is carefully trained in its use. The necessary repetition of fluoroscopic examinations is dangerous to the examiner. A primary X-ray negative before reduction if feasible should be taken; another after reduction is desirable.

In some cases repeated X-ray negatives should be made at intervals of five days to a week, so as to note the position of the fragments. Many errors of interpretation are possible. The shadow produced on the X-ray negative is the result of different opacities of the parts rayed. Distortion of the parts, incorrect adjustments of the tube, the relative distance of the parts from the plate, the various angles of incident rays to the part, and the surrounding dressings tend toward error and misinterpretation of the plate. When possible two negatives of the bone should be made in planes at a right angle.

It is only by great care in the taking of X-ray negatives, by long practice in the interpretation of the plates, and by the combination of findings from this source with those from clinical examination of the injured parts that the Röntgen ray can become of greatest service in the diagnosis of fractures.

Repair of Fractures.—Repair in Recent Closed Fractures.—The repair of fractures does not differ materially from the repair which takes place in other tissues. The variation in the process of repair depends generally upon two factors: (1) proper anatomical apposition of the fragments; and (2) the proper nutrition of both fragments. Less callus is formed, union is more prompt, and disability less when perfect anatomical apposition is obtained and maintained. On the other hand, if the fragments are not placed in perfect apposition and so maintained, there is more irritation at the ends of the fragments, which causes an increased amount of exudation and callus. Union may be delayed or arrested, if the fragments are not maintained in place; or it may be obtained only by a great production of callus, such as is seen at times in fractures occurring among the insane. When one fragment has deficient or no blood supply, repair may be arrested and at times ceases.

Repair in fractures is carried on by two structures, the periosteum and the medulla, furnishing an osteogenetic bond or callus.

At the moment of injury there is more or less tearing and bruising of the periosteum, with rupture of blood-vessels of the periosteum and of the bone. The immediate result is interstitial hemorrhage, with effusion of fluid and an infiltration of leucocytes in the surrounding structures. This infiltration continues about four to six days. At the end of forty-eight hours there is proliferation of the cells of the periosteum and medulla and this is soon accompanied by a like proliferation of the endothelial cells of the involved blood-vessels, so that at the end of the fourth day there is a definite osteoblastic tissue formation. Microscopically this consists of large polymorphonuclear cells, many mitotic figures, and a fibroid stroma. This tissue is rapidly changed into chondroid and osteoid tissue which soon becomes bone.

At the end of a week the ends of the bone are surrounded by a spindle-shaped sheath, made up of osteophytes, osteoid spicules, and fibroblastic stroma. This is called callus, and may be divided into three forms: periosteal, or ring callus, which is external to the bone and surrounds the seat of fracture; intermediary callus, which is a prolongation of the periosteal callus between the ends of the fractured bones; and myelogenic or internal callus, which extends a short distance up and down the medullary cavity of the shaft at the seat of fracture. Callus is also spoken of as provisional callus, consisting of bone produced in excess, and definite callus, which occurs between the ends of the bone and is permanent. The callus is produced by the osteoblasts, and later changes into osteoid and later into osseous tissue.

With these changes are found blood-vessels extending into the callus, the process being similar to that seen in embryonal bone formation. These vessels enter the callus from the periosteum, the endosteum, and the fractured ends of the bones. As this process proceeds and vascularization is complete, the callus has been changed in places into hyaline cartilage and fibrous connective tissue. This is followed by the formation of bony lamellæ about the blood-vessels, and the production of Haversian systems and true bone formation begins. In this maner the callus is slowly changed into dense bony tissue until the fragments are firmly joined and the process of union is complete. Coincident with this stage there begins an absorption of the periosteal and endosteal callus, which if not removed would often interfere with the function of the parts. This absorption is carried on by the activity of the osteoclasts. The process is one of months or years, depending upon the amount of excessive callus and the degree of deformity. It finally results in the removal of all excessive callus, both periosteal and myelogenic, and in the rounding off of all irregularities. Where there was at first an excessive amount of callus, there finally results a symmetrical bone. In some fractures in which very little displacement of fragments occurs, the process may be so perfect that it may be im-

possible to determine the seat of fracture, and a longitudinal section of the bone will show a continuous marrow cavity.

The size of the callus depends upon the extent of the fracture and the displacement of the fragments. Comminuted fractures associated with a great degree of separation of the fragments are followed by the production of exuberant or luxuriant callus.

When the parallel bones of a part are fractured about the same location, the resulting callus may produce a bridge, causing synostosis of the two bones. When fractures involve joint surfaces, exuberant callus generally results, unless perfect anatomical apposition is made, and ankylosis may thus take place.

In articular fractures the fragments are displaced by the effusion into the joints, by the violence causing the fracture, and by the pull of certain muscles. In this class of fractures union occurs entirely from the myelogenic and intermediate callus, as there is no periosteum covering an articular surface. Unless accurate apposition of the fragments is obtained, there is generally a production of exuberant callus. This may interfere with normal joint motion by changing the contour of the joint surfaces and thus limiting motion.

In epiphyseal separation repair proceeds in the same manner as in fractures. There is, however, very little callus formed, and as a general rule little if any interference with the epiphyseal cartilage. Subsequently early ossification of this cartilage may materially interfere with the growth of the bone. This condition is rarely seen.

Repair in Recent Open Fractures.—The process of repair in open fractures is the same as in closed fractures, if there is no infection and the fracture is soon converted into a closed one. When infection takes place the process of repair is greatly prolonged, and in some cases occurs only after great destruction of bone. There are many stages to the process, depending upon the nature of the infection and whether the periosteum alone is involved, or the medullary cavity also infected. If only the periosteum is involved in septic infection, osteogenitic function depends entirely upon the bone and endosteum. Generally when an open fracture becomes infected there are the early stages of polynuclear infiltration and phagocytosis, after which callus formation takes place, accompanied by the discharge of particles of necrotic bone until subsequent healing occurs. In these cases the callus is more extensive and its various stages of ossification are greatly prolonged.

Repair in recent aseptic closed fractures treated by aseptic operation is identical with the stages seen in closed fractures not operated upon. The only difference is that probably the time of repair is somewhat lengthened, and at times the foreign bodies used in direct fixation of the fragments cause some irritation of the wound. This

produces a discharging sinus from the seat of fracture, with resulting localized caries. Removal of the plate or other means of fixation is, as a rule, promptly followed by closure of the wound. In fractures subjected to direct fixation requiring removal of a non-absorbable means of fixation, there is often some degree of infection present. The infecting agent has gained admission to the wound at the time of the operation, or subsequently through the stitch holes, or perhaps from the blood current, because the site of fracture is a place of lowered resistance.

Delayed Union, Non-union, Vicious Union.—The length of time for union to take place varies with different bones, and at different periods of life. Union takes place in the phalanges and metacarpals in about two to three weeks; about three to four weeks in fractures of the ribs and bones of the forearm; five to six weeks for fractures of

FIG. 11.—Röntgenogram showing pseudarthrosis of radius and ulna (see Fig. 12).

the humerus and bones of the leg; seven to ten weeks for fractures of the femur. Fractures of the neck of the femur take even longer. While we generally consider that union is firm in these bones in the time specified, the Röntgen ray has shown that the reparative process is not complete for a much longer time. Repair takes place more rapidly in children and the healthy than in the aged and infirm. Even at the end of the times mentioned the union is not firm enough to bear unusual stress or strain. This is particularly true as to the weight bearing of the lower extremities.

DELAYED UNION.—A fracture is classed as one of delayed union when there remains a degree of mobility and pain on motion after the usual time for consolidation has elapsed. Delayed union is generally the result of deteriorated health, and consolidation as a rule is secured by improving the general health and increasing local congestion by elastic compression and hot-water bathing.

Non-union.—A fracture is classified as ununited when the rigidity of union has not resulted after the usual means have been employed to obtain union for a much longer time than is customarily needed. It is a rare condition and occurs in the presence of definite bone disease, such as necrosis, sarcoma, osteomalacia and carcinoma, when the fragments are not in good apposition, or where the patient's general condition is so weakened that callus formation has not occurred. Failure of union may also be due to the interposition of soft parts, to poor blood supply, to infection, and to wide separation of the fragments, as in some fractures of the olecranon and patella, faulty immobilization, and muscular action. A fibrous union is the general sequence of such conditions. The ends of the fragments are found to be rounded, the medullary cavity is closed, and a moderate degree of exuberant callus and fibrous tissue surround the area of the ends of the fragments.

Fig. 12.—Photograph of false joint or pseudarthrosis following open fracture of radius and ulna, operated upon twice (see Fig. 11).

This condition is known as pseudarthrosis (Figs. 11 and 12). True joint formation is rare at the seat of an old fracture; but sometimes a serous bursa is developed between the fragments. The most frequent seats of non-union are the shafts of the humerus and femur, the patella, the olecranon, and the neck of the femur.

Vicious Union (Fig. 13).—This term is used to describe union of fragments in marked deformity. The deformity may be shortening from impaction and over-riding; shortening combined with rotation of the distal fragment; angularity at the seat of fracture; limitation of motion due to exuberant callus and changes in the normal relation of the joint surfaces. The term is also used to designate that union which takes place with the formation of exuberant callus and the inclusion in the callus of nerves, blood-vessels, muscles and tendons. The causes of vicious union are imperfect reduction of the fracture and imperfect or faulty methods of immobilization of the fragments. Vicious union is seen most frequently in fractures of the clavicle, of

the lower end of the humerus, of the lower end of the radius, of the upper end, shaft, and lower end of the femur, of the shaft of the tibia, and in fractures about the ankle-joint.

Infection in Fractures.—Infection of the seat of fracture may be due to several conditions. In closed fractures infection may occur through the blood stream. Infection occurring in this manner is generally in fractures at the lower ends of the bones or near the epiphyseal line, and is due to the lodgment of bacteria in the terminal vessels at this point. The condition is rare and sometimes occurs and presents all the symptoms of an acute osteomyelitis in addition of those of fracture. Diagnosis is difficult, and one should not be too hasty in making a positive diagnosis. In addition to the local signs, there is marked elevation of temperature, leucocytosis, and a marked increase in the polymorphonuclear percentage. Primary infection may take place at the seat of fracture through wounds of the soft parts over-

FIG. 13.—Vicious union. Femur, fracture of shaft, junction of middle and lower thirds. Union has occurred with marked over-riding, angulation, and outward rotation of the lower fragment. (Wistar Institute of Anatomy.)

lying the fracture. If the wound leads down to the site of fracture the injury is called an open fracture. In open fractures infection occurs generally at the time of injury. Secondary infection may occur from sloughing of the soft tissues overlying a closed fracture. Infection also may occur in closed fractures through an operation wound made in applying a direct fixation apparatus.

Complications of Fractures.—The complications of fractures may be classified under the following headings:

1. LESIONS OF THE OVERLYING SOFT PARTS.—These consist of contusions, lacerations, perforations by sharp fragments, and sloughing; bullæ and blebs and, occasionally, gangrene from pressure of exudate or of fragments; and later as sequels of a fracture there may be disturbances of nutrition shown by interference with the growth of the nails and hair, and the occurrence of eczema or other trophic changes in the skin.

2. INJURY TO IMPORTANT ARTERIES AND VEINS.—These may complicate either a closed or an open fracture. The vessels are in-

jured by pressure, by laceration, or by puncture. This complication is rare, and when it does occur is very serious. The fractures most frequently seen complicated by injury to arteries and veins are those of the skull (middle meningeal artery), the clavicle (subclavian artery or vein), the humerus (Figs. 14, 15, and 16) (brachial or axillary artery or vein), ribs (intercostal artery), innominate bone (internal iliac artery or vein), femur (femoral or popliteal vessels), and tibia (anterior tibial artery). The results of injuries to arteries or veins are marked, even fatal, hemorrhage, when the bleeding occurs into a large cavity; and traumatic or false aneurism, or gangrene, when the blood escapes into the tissues surrounding the wounded vessel.

FIG. 14.—Röntgenogram showing diacondylar fracture of humerus (see Figs. 15 and 16).

The symptoms of internal hemorrhage are rapidly increasing anæmia, rapid weak pulse, failing blood-pressure, pallor of the skin, thirst, sighing respiration, restlessness, collapse, and the physical signs of an abnormal accumulation of fluid in a cavity.

The symptoms caused by a massive extravasation, the so-called false aneurism, are a swelling, gradually increasing in size, which later may pulsate; absence of pulsation in the vessel distal to the injury, with coldness and anæmia of the extremity, and the presence of a murmur synchronous with the pulse. Laceration or puncture of a vein results in extensive ecchymosis and swelling, which later may, by compression of the vein, produce gangrene of the extremity below. Laceration of both artery and vein results in absence of pulse below, marked œdema of the part, dilatation of the superficial vessels, and signs of a large hæmatoma if gangrene does not occur.

The treatment of laceration or puncture of important arteries or veins consists in immediate exposure of the injured vessel under aseptic precautions and resection with end-to-end anastomosis, or, if the laceration is small, suture of the opening in the vessel. In dangerous pressure from blood or exudate without injury to a large vessel wall, immediate incisions of skin and deep fascia may prevent the occurrence of gangrene or vascular thrombosis. If thrombosis has already occurred, the vessel should be opened, the clot removed and the opening in the vessel wall closed with suture. If the thrombus is attached to an area of damaged vessel wall, this should be resected, if

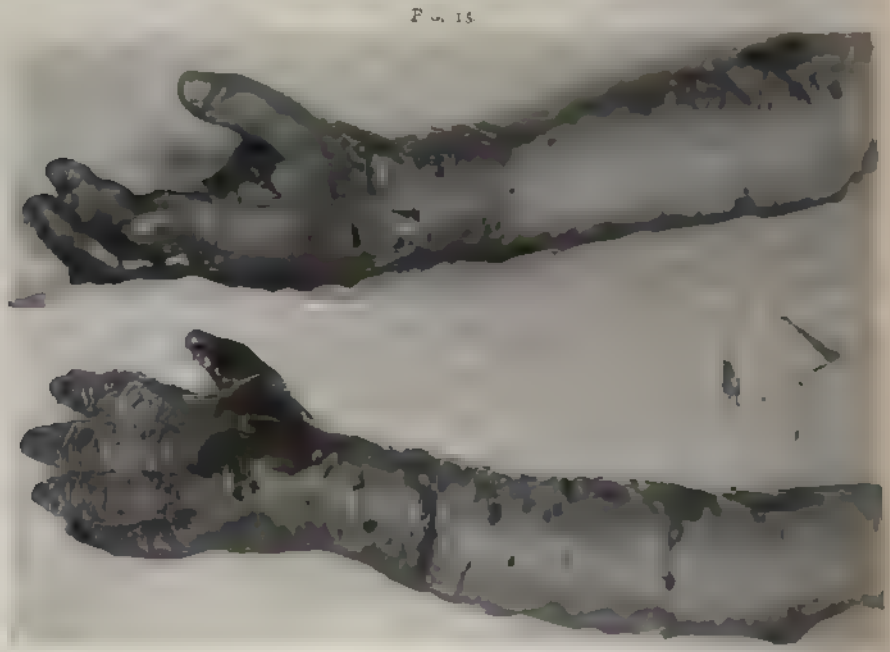

FIG. 16.

FIGS. 15 AND 16.—Moist gangrene of hand and part of forearm due to diacondylar fracture of humerus, causing injury to brachial artery. Case required amputation (see Fig. 14). (Courtesy of Dr. M. M. Franklin.)

possible, and the ends approximated by Carrell's method of anastomosis. The fragments of bone in most of these cases should be fixed in apposition, if possible, by a steel plate or other device for preventing motion.

3. INJURIES TO IMPORTANT NERVES.—Recent injuries to nerves complicating fractures are contusion, stretching, compression, laceration, and complete division. Late nerve lesions result from compression between fragments of bone, or inclusion in callus or cicatricial tissue.

The fractures in which nerve injury is most frequent are those of

the clavicle (brachial plexus), humerus (musculospiral, circumflex, and median), lower end of humerus (ulnar), radius (radial), femur (sciatic), tibia and fibula (peroneal). The symptoms of nerve injury are loss of power, loss of sensation, trophic and vasomotor changes, and changes in electrical reaction. The late symptoms are muscular wasting, cicatrices from trophic ulcers, contractures, and the presence of a neuroma at the end of the severed nerve.



FIG. 17.—Ischæmic muscular atrophy (Volkmann's contracture) (Courtesy of Dr. G. G. Davis.)

The treatment of nerve injuries associated with fractures consists of exposure of the ends of the severed nerve and their union by suture with silk. It is advisable to surround the site of nerve suture with a piece of a freshly excised vein. This prevents the formation of a cicatrix of fibrous tissue between the ends of the severed nerve. In cases where the nerve is inclosed by callus or compressed between



FIG. 18.—After operation. (Courtesy of Dr. G. G. Davis.) (See Fig. 17

fragments, the callus or bone should be cut away until the nerve is freed from pressure.

4. INJURY TO THE MUSCULAR SYSTEM.—The muscles of the part in which a fracture has occurred primarily undergo œdema and later atrophy from disuse. This condition rapidly disappears in the young with subsequent use, but it may be more or less permanent in the aged or in those fractures in which the functional result is poor. The

coincident damage to muscles, tendons, and fascial sheaths in all fractures is often neglected by surgeons. It may be of as much importance as the lesion of the bone itself. Atrophy, adhesions, and loss of function may result from the damage to the muscular structures. Massage from the beginning of treatment may be of great value. The massage must be light. Early mobilization is often valuable.

A most important secondary complication of fracture is the change which occasionally takes place in the muscles of the part, called Volkmann's contracture (Figs. 17, 18, 19, and 20). This condition, termed ischæmic atrophy, is most frequently seen involving the forearm, after

FIG. 19.—Before operation. Ischæmic muscular atrophy.
FIG. 20.—After operation. (Courtesy of Dr. G. G. Davis)

fractures of the humerus, or of the radius or ulna. The change is a dense infiltration of the muscles, followed quickly by a rapid degeneration of the muscle fibres, which is irregular in distribution. Associated changes occur in the nerves of the part, which are found to be degenerated. The cause of the condition is probably undue constriction and interference with the circulation, resulting from a too tight application of splints, perhaps improperly padded, too tight bandaging, or to the prolonged use of the tourniquet. The symptoms are primary swelling of the part distal to the fracture, with marked cyanosis and flexion of the fingers without any great pain. Removal

of the splints in twenty-four hours shows localized necrosis, generally on the flexor and extensor surfaces of the forearm and the wrist. Marked contracture of the muscles takes place with involvement of tendons and nerves, so that the final picture is one of marked atrophy and shortening of the muscles, contractures, loss of sensation at times, and loss of muscular power. Flexion at the wrist and at the phalangal joints is marked.

The preventive treatment of this condition is early removal of all constriction and massage of the part. Later these measures are unavailing and the deformity above described results. Operative treatment of the disabled limb consists in dissecting out the tendons and muscles with lengthening of the same, followed by massage and passive motion. Nerve resection and anastomosis of muscles and nerves may occasionally be of some benefit. Resection for the purpose of shortening both radius and ulna has been suggested for this condition, but its usefulness as an operative procedure is doubtful. Mechanical devices are at times necessary to keep the fingers in proper position, and at times are useful for maintaining partial function.

5. Injury to a Neighboring Joint.—At times neighboring joints are directly involved in the line of a fracture; and, aside from those fractures which involve the articular surface, there is often seen marked stiffness and œdema of the neighboring joints when the articular end of the bone is not broken. This complication is seen most frequently in the infirm, the old, and those with a rheumatic tendency. In fractures involving the joint surface, there may result a marked traumatic arthritis, with perhaps the formation of excessive callus. There then occurs not only stiffness and œdema, but also marked limitation of motion. This condition is very often permanent, and greatly limits the subsequent usefulness of the part. In many of these cases there is an atrophy of the muscles of the limb and a periarticular œdema with fixation of tendons, ligaments, and nerves in fibrous tissue, so that all the soft parts are involved in a general cicatrix.

When the line of fracture involves the adjacent joint, there is generally seen a moderate degree of limitation of motion, unless the fragments are accurately adjusted; then callus formation is slight. The presence of intra-articular callus formation is due to malapposition of the fragments. By the deformity and the deposit of callus, the joint surfaces are altered and the contour of bearing surfaces changed. The result can hardly fail to be limitation of motion.

The treatment of these conditions consists in the accurate adjustment of the fragments primarily, persistent active and passive motion, massage, and in those cases in which limitation of motion is due to serious malposition of fragments, operation.

ASSOCIATION WITH AN ADJACENT DISLOCATION.—At times fracture may be complicated by a dislocation of an adjacent joint. The combination is seen most frequently in fractures of the surgical neck of the humerus associated with dislocation at the shoulder-joint, fracture of the glenoid cavity or neck of the scapula with dislocation at the shoulder-joint, fracture of the upper end of the ulna associated with dislocation of the head of the radius, fracture of the lower end of the radius with dislocation of the lower end of the ulna, fracture of the vertebræ with dislocation, fracture of the upper end of the femur with dislocation of its head, and fracture of the pelvis associated with dislocation at the hip-joint.

The treatment of this condition may be non-operative or operative. Occasionally it is possible to reduce the dislocation by external manipulation, either before the fracture has been reduced or after the fragments have been replaced and immobilized. Generally, however, it is necessary to expose the seat of fracture by incision. Then after reduction and immobilization of the fragments, it may be possible to reduce the dislocation. At times it is necessary to expose also the seat of dislocation in order to obtain reduction. Occasionally excision of the articular fragment may be necessary.

A fracture may be associated with a previously unreduced dislocation or an ankylosed joint. When there is present a previously unreduced dislocation complicating a recent fracture, the presence of the dislocation should be disregarded unless it may seem possible to reduce it and hold the parts in their normal position by operation. Generally, the articular changes present are of such a character as to preclude the possibility of improvement, short of a total excision of the joint. In fractures complicated by ankylosis of a neighboring joint it will be most feasible to entirely disregard the presence of the ankylosis. It should, however, be borne in mind that extra precautions should be taken in immobilization, as this condition may be followed by non-union or pseudo-arthrosis at the seat of fracture.

FAT EMBOLISM.—This is a condition often described in treatises on fractures but is rarely seen, and when it does occur is usually followed by no alarming symptoms. It can readily be seen that in all fractures involving the bone-marrow there are almost necessarily small numbers of fat globules carried into the circulation. These fat globules may find their way to the brain, lungs, kidneys, or spleen. They differ, however, from the ordinary blood embolism in that the fat globules do not adhere to each other, and therefore usually do little harm except in terminal vessels of very small calibre. In the various organs where they may lodge they may produce infarcts, œdema, or, in the lung, pneumonic areas.

It is more common in closed than in open fractures, and may some-

times give rise to grave symptoms. In the brain fat globules may produce areas of cerebral softening. In the lung they may cause dyspnœa, cyanosis, and areas of dulness with râles; in the kidneys they may produce fat globules in the urine, with casts and albuminuria.

The treatment of the condition is entirely symptomatic. While the presence of fat globules in the circulation in cases of fracture is common, the fact of their producing any actual damage is questionable, and the cases of supposed death in cases of fracture, commonly ascribed to fat emboli, are very doubtful and open to question. A thorough autopsy on these cases would undoubtedly frequently show the cause of death to be other than fat emboli.

THROMBOSIS AND EMBOLISM.—In fractures of the lower extremity all the evidences of obstruction to the venous system may appear. This is particularly true in fractures of the bones of the leg, and is due to the formation of a thrombus, generally in the deep veins. This condition is rarely seen while the patient is at rest in bed, but generally is noticeable when the patient begins to be up and about. Then is seen a large, œdematous, bluish leg, resulting from obstruction. In some instances emboli are detached from the venous thrombus and are carried through the heart to the lungs and there produce lesions varying from a localized bronchitis, localized consolidation with pleurisy, to sudden death. The symptoms of these conditions are totally different. All of them, however, occur, as a rule, several weeks after the injury, and sometimes after massage of the part. The onset is sudden and in cases of sudden death there may be extensive pallor or cyanosis, difficulty in breathing, shock, a weak, rapid pulse and a rapidly fatal issue. It is very suggestive of this condition when patients develop the so-called hypostatic pneumonias in cases of fracture. In such instances it is always well to consider the possibility of pulmonary emboli. Thirty-six cases of pulmonary embolism after fracture are reported by Lotheissen, with 30 deaths. They all occurred in people past middle life, and 34 cases were closed fractures. The bones of the leg were fractured in 25 cases, the femur in 7 cases, the humerus in 3 cases and the patella in 1 case. Two cases were open, or compound, fractures.

The preventive treatment of this condition is care in the splinting of the parts, careful massage and passive motion with proper stimulation to the arterial system. In the presence of embolism the treatment is purely symptomatic. The presence of extensive pulmonic emboli is generally fatal, as shown by the above statistics.

INFECTION.—This condition is seen most frequently as a complication of open fractures. It is rarely seen in closed fractures. When it occurs in closed fractures the patients are apt to be children. The lesion begins generally in the epiphyseal end of the diaphysis. It

occurs here through deposit of bacteria in the terminal vessels at the epiphyseal line, and in addition to the symptoms of a fracture there arise symptoms of an acute osteomyelitis.

The organisms found are, as a rule, the Streptococcus pyogenes, the Staphylococcus aureus and albus or a combined infection of the two. Occasionally a more virulent form of infection is seen. Of these may be mentioned the tetanus bacilli, the Bacillus aërogenes capsulatus, the bacillus of malignant œdema. In all cases of infection the severity of the local signs depends upon the nature of the organism, the extent and character of the wound, and the general powers of resistance. The chief symptoms are redness, œdema, and increased local heat, with the presence of a foul discharge from the wound, in addition to the general symptoms of infection, viz., increase in temperature, increased pulse rate, leucocytosis, and delirium. In the malignant forms of infection the symptoms are more severe. Rapid and extensive involvement of the affected bone occurs, and at times of the neighboring joints. Gangrene is rapid and sapræmia and septicæmia very pronounced.

The treatment is antisepsis, and extensive drainage at the seat of fracture, by means of free and multiple incisions, combined with general supportive treatment. Amputation is not an unusual necessity, when this active surgical management is omitted or delayed.

Shock and Hemorrhage.—These two conditions are occasionally found complicating severe fractures. They are seen most frequently in fractures of the skull, ribs, pelvis, and femur. The two conditions are very often characterized by similar symptoms, but they should be differentiated. Shock is seen most frequently in multiple fractures accompanied by considerable bruising of the soft parts, and in patients who have been transported for a considerable distance. Hemorrhage is seen especially in fractures near large vessels and in those which communicate with visceral cavities, into which extensive hemorrhage may occur without external evidence.

Treatment of shock should consist in absolute immobilization of the fragments, general stimulation, the application of external heat, and the use of remedies applicable to shock from other injuries.

In cases of suspected, concealed, or internal hemorrhage it may be necessary to expose the seat of fracture and ligate the bleeding vessel, especially if the hemorrhage is extensive and endangering the life of the patient.

Traumatic Delirium.—This is a condition occasionally seen as a complication of fractures in the young and those who are not addicted to the use of alcohol. The condition occurs generally in persons who have been under considerable mental stress for years, and is similar in character to post-operative delirium. The chief symp-

toms of the condition are low, muttering delirium without fever. The patient's attention can at times be fixed, only to be quickly lost; the events of the past are recalled, and the subject causing mental anxiety is uppermost in the patient's mind. Refusal to take food, relaxation of the sphincters, and rapid emaciation are also symptoms occasionally seen.

The treatment of the condition is forced feeding, watching the excretions, care of the dependent parts of the body so as to prevent bed-sores, and the use of a general tonic. The prognosis in this form of delirium is usually good, but at times death follows. It is not as dangerous a complication in fractures as is alcoholic delirium.

ALCOHOLIC DELIRIUM.—The onset of delirium in patients subject to the use of alcohol is a very common and at the same time a grave occurrence. As a complication of fractures it is a condition always to be dreaded. Its symptoms consist of muscular twitchings, delirium from which the patient may be aroused at first, an increase in pulse rate, a flushed face, hallucinations, restlessness, insomnia and, finally, delirium with unconsciousness. These patients are difficult to restrain. They are liable to insist upon removing dressings and all forms of apparatus, and unless carefully watched will walk around with portions of their fracture dressings hanging from them. Even with fracture of the femur or of the bones of the leg, patients will get out of bed and attempt to walk unless restrained. Attempts at violence and self-destruction are comparatively frequent.

The onset of the delirium may be sudden or gradual. If there has been loss of blood or shock, the onset, as a rule, is sudden. In other cases its onset begins about two to four days after the injury and patients pass rapidly from the earliest symptoms to complete insomnia, and show violence. Very often in addition there occurs either sepsis or pneumonia. Death often rapidly follows.

Treatment consists in early recognition of the condition, in the use of alcoholic stimulation, chloral by mouth or rectum, forced feeding, particularly of liquids, and restraint. Great care must be taken that these patients do not injure themselves or others, and that they are frequently moved in bed to prevent hypostatic pneumonia. The back and all dependent portions of the body should receive most careful attention to obviate bed-sores, which may occur despite the patient's restlessness.

PULMONARY COMPLICATIONS.—The occurrence of pneumonia as a complication is not frequently seen, but it may develop during the first few days. Its cause is not known, but the occurrence of fat emboli may have something to do with its onset. As a rule it is not preceded by a chill; the course of the disease is rapid. It is generally lobar in type, is accompanied by high fever and muttering delirium, and a fatal result may occur within a few days.

Another form of lung complication is perhaps more frequent than the lobar pneumonia above described. It is a bilateral hypostatic involvement of the posterior aspect of the lungs, and is seen most frequently in those of advanced life. Its onset is gradual, there is no chill, and only moderate fever. The course of the disease is slow and fatal in many cases. The condition is favored by long recumbency in one position. Pathologically, it consists of extensive venous congestion of the lower lobes, and it is a very frequent sign of failure of the heart and general decline in the body functions.

The treatment consists in turning the patient frequently or otherwise changing his position, massage, and general stimulation. The prognosis of this condition is very bad.

Bronchitis is another pulmonary complication of fractures. It is seen most frequently in the aged, as a coincident disease with various forms of delirium, and may be caused by failing cardiac power or as the result of inspiration of particles of food. It is generally a diffuse condition, more pronounced posteriorly than anteriorly, and is progressive in character, generally ending in a lobular pneumonia which is fatal in a short time. Its treatment is purely symptomatic.

Cardiovascular Changes.—These consist in alterations in the heart muscle, which undergoes a fatty degeneration, and changes in the coronary vessels. There may be no evidence of myocardial or coronary change while the patient is in bed. It only becomes evident after the patient is out of bed and is characterized by precordial distress, dyspnœa, cyanosis, and later by failing compensation and occasionally by sudden death. Most of these cases are incorrectly classified as due to pulmonary emboli. Post-mortem examination reveals no evidence of pulmonary emboli, but the heart shows an increase of fat in the epicardium. The heart muscle is yellowish brown, friable and soft, and the coronary arteries are atheromatous.

The treatment in those cases which are not rapidly fatal is rest, mental and physical, and later moderate exercise and bath.

Epiphyseal Separations

Anatomy.—All bones are formed in the embryo either in membrane, or in cartilage covered by membrane. Ossification takes place beneath this membrane in all and exclusively in some, as the clavicle. The diaphysis or body of the bone has one or more primary centres of ossification. The epiphysis has one or several secondary or tertiary centres of ossification, which are united to the diaphyses for a time by epiphyseal cartilage. The epiphyses or secondary centres help to form the extremities of the long bones or the projecting processes. An apophysis is a prominent projection of bone which is not developed from an independent centre of ossification. The primary centres

appear in the diaphyses of long bones before birth, with several exceptions. The secondary centres in the epiphyses appear after birth, with the exception of the upper epiphysis of the tibia, the lower epiphysis of the femur, and the upper epiphysis of the humerus. The diaphysis is separated from the epiphyses of the long bones by an intervening layer of cartilage called the epiphyseal cartilage. Growth occurs from the centres in the diaphysis and epiphyses, accompanied by a corresponding growth of the epiphyseal cartilage. When the bone has attained its full growth, union of the diaphysis and epiphyses takes place by ossification of the epiphyseal cartilage. Bones increase in diameter through deposit of bone from the periosteum. The following rules of bony union of the diaphysis and epiphyses have been laid down by Gerrish:

"1. The extremity whose ossific centre is the first to appear is the last to unite with the shaft. Exception: the lower end of the fibula, but the upper end is vestigial.

"2. The extremity toward which runs the nutrient artery is the first to unite.

"3. The nutrient arteries run toward the elbow and away from the knee, *i.e.*, down hill, if elbow and knee are both flexed.

"4. Union of the epiphyses and diaphyses of long bones occurs from the sixteenth to the twenty-second year (occasionally twenty-fifth year, tibia) and earlier in the upper than in the lower extremity.

"5. When two or more centres of ossification occur in an epiphysis, these unite together before the epiphysis unites with the diaphysis or shaft."

THE DATE OF OSSIFICATION OF THE EPIPHYSES AND THE TIME OF UNION OF THE EPIPHYSES TO THE DIAPHYSES.—*The inferior maxilla* is formed in membrane about Meckel's cartilage. There are four to six centres of ossification. From the symphysis to the mental foramen ossification takes place in Meckel's cartilage; the condyles and angles ossify from separate centres in cartilage. The rest of the bone develops in membrane. At birth the two halves of the mandible are separated by a synchondrosis, and they do not unite until after the first year.

Hyoid Bone.—Is preformed in cartilage; there is a centre for each cornu and for each half of the body. Ossification of the body and greater cornu begins at birth, of the lesser cornu at a later period. Ossification of the synchondrosis of the body and greater cornu occurs usually after middle life. The synchondrosis of the lesser cornu seldom ankyloses.

The scapula is preformed in cartilage during fetal life; ossification occurs from two primary and five secondary centres. The primary centres are on the body and coracoid processes, which unite about the

fifteenth year. Two centres appear in the acromion at the fifteenth year, unite and join the spine at the twentieth year.

The clavicle is preformed in cartilage (prechondral tissue), and the main centre of ossification appears about the seventh week of embryonal life. It is the first bone to ossify. An epiphyseal centre appears at the sternal end about the fifteenth to eighteenth years and unites with the shaft about the twentieth year.

The sternum is preformed in cartilage; the manubrium is generally developed from a single centre, the gladiolus from four to twelve centres and the xiphoid from one centre. Ossification of the sternum begins about the fourth to sixth month of fetal life, and the xiphoid



FIG. 21.—Epiphyseal lines of upper end of right humerus, acromial process of scapula.

from the sixth to the twentieth year. Failure of union of the two halves of the sternum results in a median foramen or vertical fissure.

The ribs are preformed in cartilage and have a primary centre near the angle. Epiphyseal centres appear for the heads and tubercles after puberty, and unite with the main portions of the bone about the twenty-fifth year.

Vertebræ.—Each vertebra has three centres of ossification, one for the body, and one for each half of the vertebral arch. Ossification begins at the end of the second month of embryonal life. Accessory centres appear about the age of puberty, at the spinous and transverse processes, on the mammillary processes of the lumbar vertebral, and on the upper and lower surfaces of the vertebral bodies. These

accessory epiphyses unite with the remainder of the vertebra when growth has been completed.

The *humerus* (Figs. 21 and 22) is developed from a centre of ossification for the diaphysis, which appears during the eighth week of fetal life, and six or seven secondary centres for the extremities which appear after birth, the epiphyses being cartilaginous. During the first year the centres appear in the following order: upper epiphysis for the head, the capitellum, the greater tuberosity, the lesser tuberosity, the trochlea, the external and internal epicondyles, which

FIG. 22.—Epiphyseal lines and centre of lower end of humerus, and upper ends of radius and ulna.

appear between the tenth and twelfth years. Complete ossification and disappearance of the synchondroses from the twentieth to the twenty-second year.

Radius (Figs. 22 and 23).—The centre for the diaphysis appears in cartilage about the third fetal month, the secondary centre for the head appears about the fifth year and unites to the shaft about the fifteenth year; and a secondary centre for the lower end appears shortly before the upper one, but does not unite with the shaft until the twentieth year. Accessory nuclei appear for the tubercle and styloid process.

Ulna (Figs. 22 and 23).—The centre for the shaft occurs in cartilage about the third fetal month; the upper end of the olecranon is ossified from a secondary centre for the olecranon and another for the coronoid process, which join the shaft about the sixteenth year. There is also a secondary centre for the lower epiphysis which forms the styloid process and joins the shaft from the eighteenth to the twentieth year.

Carpal Bones (Fig. 23).—All the carpal bones ossify from a single centre and are cartilaginous at birth. The centres for the os magnum and unciform appear during the first year; and for the other bones between the third to the ninth year, with the exception of the pisiform, which does not begin to ossify till the twelfth year.

The metacarpal bones (Fig. 23) are preformed in cartilage and ossify from a diaphyseal centre for the shafts and an epiphyseal

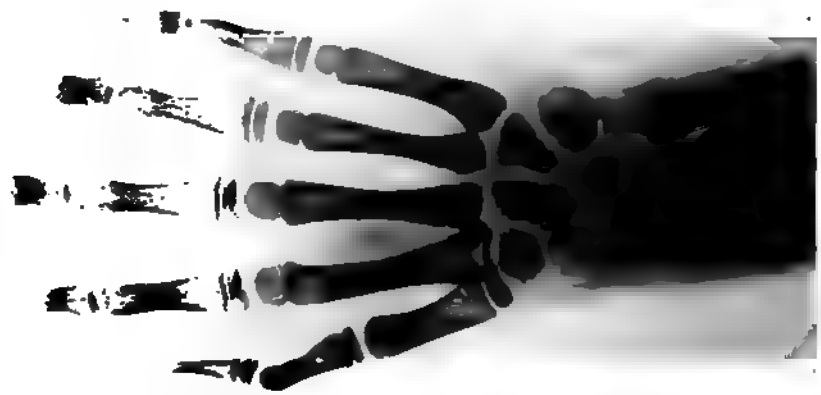

FIG. 23.—Epiphyseal lines and centres of lower ends of radius, carpal, metacarpal and phalangeal bones of hand.

centre in the head, except the so-called metacarpal bone of the thumb, which has its epiphyseal centre in the base. The diaphyseal centres appear in the ninth week of fœtal life and the epiphyseal centres appear after birth.

Phalanges (Fig. 23).—They are preformed in cartilage and their centres form in a similar manner to those of the first metacarpal; a diaphyseal centre, and an epiphyseal centre in the proximal end. The proximal phalanx ossifies first, then the middle one, and finally the distal one.

The *innominate bone* (Figs. 24 and 25) is preformed in cartilage, there being three main centres of ossification, one for the ilium, one for the ischium, and one for the pubes; the centres appearing at the third, fourth and fifth months of fetal life respectively. At birth a large part of the innominate bone is cartilaginous and remains so for some time. The three portions join by the ossification of the Y-shaped

cartilage, where they meet in the acetabulum, about the sixteenth to the twentieth year. There are, in addition, secondary centres of ossification as follows: one each for the crest of the ilium, the tuberosity of the ischium, the spine of the ischium, the symphysis pubis, the anterior inferior spine of the ilium, the spine of the pubis, and



FIG. 24.—Epiphyseal lines of part of pelvis and upper end of femur

two for the acetabulum. These epiphyses unite with the main portion of the bone about the twenty-fifth year.

Femur (Figs. 24 and 26).—This bone develops from a diaphyseal centre and two primary epiphyseal centres. The diaphyseal centre appears about the seventh week of embryonic life and the lower epiphyseal centre is generally visible at birth: the centre for the head

which includes the tubercle ossifies about the time of birth, and the centre of the lower epiphysis ossifies about the beginning of the second year. The lower epiphysis unites with the shaft about the eighteenth year and the upper epiphysis about the twenty-second year.

Fibula (Figs. 26 and 27).—The centre for the diaphysis appears about the eighth week of embryonic life; the centre for the lower epiphysis appears about the second and that for the upper epiphysis about the third or fourth year. The lower epiphysis unites with the shaft about the twentieth year and the upper one from the twenty-second to the twenty-fourth year.

FIG. 26.—Epiphyseal lines and centres of lower end of femur, patella, and ends of tibia and fibula.

Tarsal Bones (Fig. 27).—The centre for the calcaneum appears about the sixth month and that for the astragalus in about the seventh month of embryonal life; the centre for the cuboid appears at birth; the external cuneiform ossifies about the first year, the internal cuneiform the second year, and the middle cuneiform and the scaphoid from the fourth to the fifth year. The calcaneum is the only tarsal having an epiphyseal centre of ossification which appears about the tenth year and unites with the remaining part of the bone at about the fifteenth or the sixteenth year.

Metatarsal Bones (Fig. 28).—The centres of the diaphyses appear about the eighth to ninth week of fetal life and the epiphyseal centres in the third to the fourth year and unite with the diaphyses about puberty. The ossification is similar to that which takes place in the metacarpal bones.

Phalangeal Bones (Fig. 28).—Here the process of ossification is similar to that seen in the phalanges of the hand. The centres of the

diaphyses appear in about the third month of fetal life, the epiphyseal centres in about the fourth year, and union of the diaphyses and epiphyses takes place about the time of puberty.

Etiology of Epiphyseal Separation.—Epiphyseal separations may be due to violence, direct or indirect, or to muscular action.

DIRECT VIOLENCE.—This is a frequent cause of epiphyseal separations which are produced by force applied close to the epiphyseal line. Examples are: fall from a moderate height with striking of the

FIG. 27.—Epiphyseal lines and centres of lower end of tibia and fibula, and of calcaneum.

shoulder, catching an extremity in a revolving wheel, or having a wheel pass over the part, and having the part struck by a heavy object.

INDIRECT VIOLENCE.—Epiphyseal separations are produced by indirect violence by falls upon the hand, producing separations at the epiphyses in the young where fractures would be produced at the same site in the adult. Examples of separations are those at the wrist simulating Colles's fracture, separations at the elbow by falling upon the hand or by hyperflexion or extension, or catching the limb in a revolving wheel.

Muscular Action.—This is a very rare etiologic factor in epiphyseal separations. It is occasionally seen in severe muscular action, by which an epiphysis may be displaced owing to the attachments of strong muscles or ligaments. The same amount of strain in an adult would probably produce a sprain fracture or the separation of an apophysis. A good example of this is separations of the internal epicondyle.

On general principles, it may be stated that the mechanism of most separations is the same that produces fractures near joints in adults.

Occurrence of Epiphyseal Separations.—Ossification of all the epiphyseal cartilages has usually occurred before the twenty-fifth year, hence epiphyseal separations can rarely happen at a later period of life. Poland has shown that epiphyseal separations are rare before the age of four years, excepting, of course, those produced in obstetric

Fig. 28.—Epiphyseal lines and centres of metatarsal and phalyngeal bones of foot.

delivery, but are most frequently found between eleven or twelve and sixteen years.

Dependent upon the age of the patient there may be several forms of separation of the epiphyses. In early childhood the separation does not involve the diaphysis to any appreciable extent. After the age of eight or nine, nearly all epiphyseal separations are accompanied by a fracture of the diaphysis, which may be vertical or oblique, or consist of only a very small part of the cortex of the diaphysis. With the increase of age occurs a greater tendency for marked stripping off of the periosteum. In early childhood this is not marked, but in later childhood it may extend four to five inches along the shaft of the bone. The extent of this stripping is dependent upon the degree of displacement of the epiphysis and the epiphysis involved. It is greatest in separations of the lower epiphysis of the femur and of the upper epiphysis of the humerus.

Ulna (Figs. 22 and 23).—The centre for the shaft occurs in cartilage about the third fetal month; the upper end of the olecranon is ossified from a secondary centre for the olecranon and another for the coronoid process, which join the shaft about the sixteenth year. There is also a secondary centre for the lower epiphysis which forms the styloid process and joins the shaft from the eighteenth to the twentieth year.

Carpal Bones (Fig. 23).—All the carpal bones ossify from a single centre and are cartilaginous at birth. The centres for the os magnum and unciform appear during the first year; and for the other bones between the third to the ninth year, with the exception of the pisiform, which does not begin to ossify till the twelfth year.

The metacarpal bones (Fig. 23) are preformed in cartilage and ossify from a diaphyseal centre for the shafts and an epiphyseal

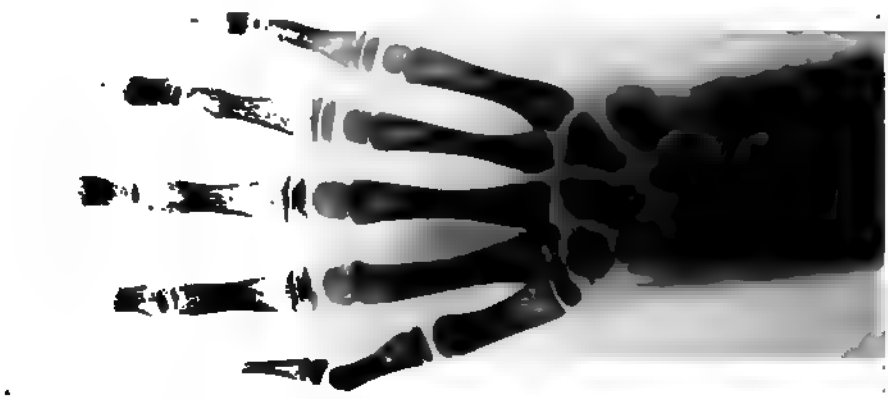

FIG. 23.—Epiphyseal lines and centres of lower ends of radius, carpal, metacarpal and phalangeal bones of hand.

centre in the head, except the so-called metacarpal bone of the thumb, which has its epiphyseal centre in the base. The diaphyseal centres appear in the ninth week of fœtal life and the epiphyseal centres appear after birth.

Phalanges (Fig. 23).—They are preformed in cartilage and their centres form in a similar manner to those of the first metacarpal; a diaphyseal centre, and an epiphyseal centre in the proximal end. The proximal phalanx ossifies first, then the middle one, and finally the distal one.

The *innominate bone* (Figs. 24 and 25) is preformed in cartilage, there being three main centres of ossification, one for the ilium, one for the ischium, and one for the pubes, the centres appearing at the third, fourth and fifth months of fetal life respectively. At birth a large part of the innominate bone is cartilaginous and remains so for some time. The three portions join by the ossification of the Y-shaped

PAIN.—This is not as great as in fractures. There is, however, generally localized tenderness on pressure over the epiphyseal line; this symptom, combined with localized swelling, is of great diagnostic value in recognizing epiphyseal separations.

ECCHYMOSIS is not as marked as in fractures. This is probably due to the fact that the vascular system involved consists of terminal vessels. When present it becomes evident about the fourth to fifth day.

Radiographic Examinations.—These are of especial value and should always be made in suspected cases. Skiagraphs should be made in several planes, as it may be that positive diagnosis is possible only by comparison of the outline of the affected bone with that of the normal side. The surgeon should particularly familiarize himself with the normal X-ray appearances of the epiphyses at all ages, if correct interpretation of these radiographic plates is to be made. Examination of the plates by transmitted light is much more satisfactory than inspection of prints. More care is required than in fractures. Very often the only abnormality to be seen will be a slight difference in outline or a loss of normal continuity of the epiphysis with the diaphysis. In other cases one may discover a fissure or a partial fracture of the metaphyseal end of the diaphysis, with displacement of the fragment along with the epiphysis; in still other cases there may be noted a stripping off of periosteum. Radiographic pictures of the normal corresponding part should be taken for comparison with the injured side.

Diagnosis.—This is made from a consideration of the patient's age, the nature and position of the injury, the site of tenderness and swelling, the characteristic displacement if any be present, the absence of normal bony crepitus, the presence of mobility in the region of the epiphyseal line, and, lastly, by radiographic examination. The last is of utmost importance in the recognition of these lesions.

Complications of Epiphyseal Separations.—These are injuries to blood-vessels, and lesions from nerves being caught between the diaphysis and the epiphysis, fracture of the diaphysis, rotation and displacement of the epiphysis, necessitating operative exposure for proper replacement, and the occasional occurrence of an open epiphyseal separation.

Sequelæ of Epiphyseal Separations.—Perfect reduction of epiphyseal separations should give perfect anatomical and functional results. It is surprising how rarely there is any interference with the subsequent growth of the bone after epiphyseal separations. While there are cases of subsequent interference with the growth of the bone (Fig. 29), this sequel seems to be rare in comparison with the great number of epiphyseal separations observed in childhood.

Treatment.—In all cases of complete or incomplete separation

Ulna (Figs. 22 and 23).—The centre for the shaft occurs in cartilage about the third fetal month; the upper end of the olecranon is ossified from a secondary centre for the olecranon and another for the coronoid process, which join the shaft about the sixteenth year. There is also a secondary centre for the lower epiphysis which forms the styloid process and joins the shaft from the eighteenth to the twentieth year.

Carpal Bones (Fig. 23).—All the carpal bones ossify from a single centre and are cartilaginous at birth. The centres for the os magnum and unciform appear during the first year; and for the other bones between the third to the ninth year, with the exception of the pisiform, which does not begin to ossify till the twelfth year.

The metacarpal bones (Fig. 23) are preformed in cartilage and ossify from a diaphyseal centre for the shafts and an epiphyseal

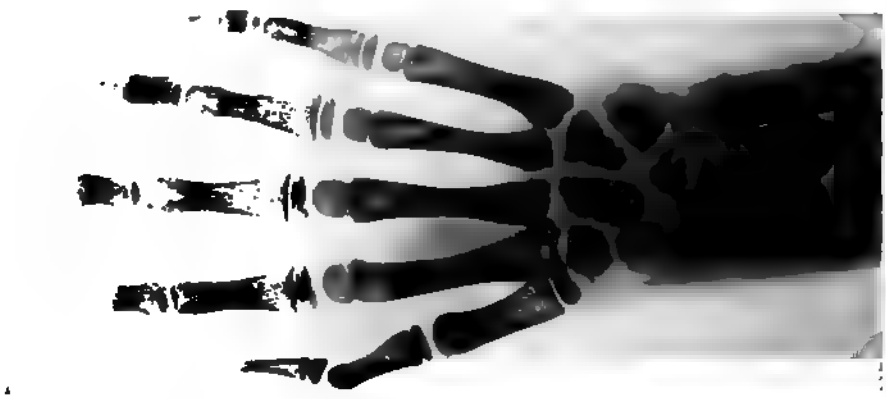

FIG. 23.—Epiphyseal lines and centres of lower ends of radius, carpal, metacarpal and phalangeal bones of hand.

centre in the head, except the so-called metacarpal bone of the thumb, which has its epiphyseal centre in the base. The diaphyseal centres appear in the ninth week of fœtal life and the epiphyseal centres appear after birth.

Phalanges (Fig. 23).—They are preformed in cartilage and their centres form in a similar manner to those of the first metacarpal: a diaphyseal centre, and an epiphyseal centre in the proximal end. The proximal phalanx ossifies first, then the middle one, and finally the distal one.

The *innominate bone* (Figs. 24 and 25) is preformed in cartilage, there being three main centres of ossification, one for the ilium, one for the ischium, and one for the pubes; the centres appearing at the third, fourth and fifth months of fetal life respectively. At birth a large part of the innominate bone is cartilaginous and remains so for some time. The three portions join by the ossification of the Y-shaped

which includes the tubercle ossifies about the time of birth, and the centre of the lower epiphysis ossifies about the beginning of the second year. The lower epiphysis unites with the shaft about the eighteenth year and the upper epiphysis about the twenty-second year.

Fibula (Figs. 26 and 27).—The centre for the diaphysis appears about the eighth week of embryonic life; the centre for the lower epiphysis appears about the second and that for the upper epiphysis about the third or fourth year. The lower epiphysis unites with the shaft about the twentieth year and the upper one from the twenty-second to the twenty-fourth year.

FIG. 26.—Epiphyseal lines and centres of lower end of femur, patella, and ends of tibia and fibula.

Tarsal Bones (Fig. 27).—The centre for the calcaneum appears about the sixth month and that for the astragalus in about the seventh month of embryonal life; the centre for the cuboid appears at birth; the external cuneiform ossifies about the first year, the internal cuneiform the second year, and the middle cuneiform and the scaphoid from the fourth to the fifth year. The calcaneum is the only tarsal having an epiphyseal centre of ossification which appears about the tenth year and unites with the remaining part of the bone at about the fifteenth or the sixteenth year.

Metatarsal Bones (Fig. 28).—The centres of the diaphyses appear about the eighth to ninth week of fetal life and the epiphyseal centres in the third to the fourth year and unite with the diaphyses about puberty. The ossification is similar to that which takes place in the metacarpal bones.

Phalangeal Bones (Fig. 28).—Here the process of ossification is similar to that seen in the phalanges of the hand. The centres of the

ankle-joints, in which there remains in a considerable number of cases a certain degree of limitation. Fractures of one of the parallel long bones are generally followed by a good result, because the other bone acts as a splint and preserves the longitudinal alignment. This, however, is not always the case, as is seen in spiral and oblique fractures of the tibia. Fractures of the spongy bones are usually followed by a certain amount of deformity, owing to the crushing and comminution of the fragments. Fractures of the small bones unite sooner than fractures of the large bones. Fractures will sometimes be followed by imperfect anatomical and functional results, notwithstanding all efforts at perfect reduction and approximation and expert supervision.

Changes in the soft parts and of the neighboring joints may influence the prognosis. Stiffness of the articulations, adhesions about joints, œdema and congestion of the parts which are increased when the dependent position is assumed, and pain aggravated by changes in the weather are some of the common sequelæ of fractures. These changes may require months for their disappearance, and in many cases are permanent. It is practically certain that to a considerable degree stiffness of joints, adhesions of tendons, œdema, and pain may be averted if, in addition to reduction and mechanical support, fractures are treated with frictions and light massage, and passive motions. While we may have perfect anatomical apposition of the fragments, the presence of these changes in the soft parts about the fracture may greatly lessen the good functional results which should be otherwise obtainable. Stiffening of neighboring joints is generally due to the simultaneous involvement of the joint structures in a sprain, to the hemorrhagic extravasation around or into the synovial sac, to the involvement of tendons in ossifying callus, to the contraction of periarticular tissue and ligaments during the time of immobilization, and to the development of excessive callus about the joint surfaces. This stiffness is most marked and most persistent in the aged and in those subject to rheumatoid arthritis. Œdema is the result of pressure upon deep veins by fragments of bone or callus or the development of a phlebitis resulting from the deposit of fibrin about the seat of fracture. Protracted immobilization of fractures in splints, infrequent examination and neglect of the care of the skin and muscles during the wearing of the splints are undoubtedly responsible for many of these sequelæ. Attention to the soft parts in the manner advocated by Lucas-Championnière and his followers will obviate many of these difficulties.

General Statistics

There are so many elements entering into the prognosis of fracture that it is difficult to give any general statistics that will cover all forms. Each case must be considered on individual grounds, and each class of fractures occurring in the same bone must be grouped. Statistics even

which includes the tubercle ossifies about the time of birth, and the centre of the lower epiphysis ossifies about the beginning of the second year. The lower epiphysis unites with the shaft about the eighteenth year and the upper epiphysis about the twenty-second year.

Fibula (Figs. 26 and 27).—The centre for the diaphysis appears about the eighth week of embryonic life; the centre for the lower epiphysis appears about the second and that for the upper epiphysis about the third or fourth year. The lower epiphysis unites with the shaft about the twentieth year and the upper one from the twenty-second to the twenty-fourth year.

FIG. 26.—Epiphyseal lines and centres of lower end of femur, patella, and ends of tibia and fibula.

Tarsal Bones (Fig. 27).—The centre for the calcaneum appears about the sixth month and that for the astragalus in about the seventh month of embryonal life; the centre for the cuboid appears at birth; the external cuneiform ossifies about the first year, the internal cuneiform the second year, and the middle cuneiform and the scaphoid from the fourth to the fifth year. The calcaneum is the only tarsal having an epiphyseal centre of ossification which appears about the tenth year and unites with the remaining part of the bone at about the fifteenth or the sixteenth year.

Metatarsal Bones (Fig. 28).—The centres of the diaphyses appear about the eighth to ninth week of fetal life and the epiphyseal centres in the third to the fourth year and unite with the diaphyses about puberty. The ossification is similar to that which takes place in the metacarpal bones.

Phalangeal Bones (Fig. 28).—Here the process of ossification is similar to that seen in the phalanges of the hand. The centres of the

obtained was 1736, and in no less than 1576 of these the functional result was also good. In other words: "If the anatomical result be good the functional result is good in 90.7 per cent. If the anatomical result be moderate or bad, the functional result is good in 380 out of 1279—*i.e.*, 29.7 per cent. If the anatomical result be bad, the functional is bad in 176 out of 330—*i.e.*, 53.3 per cent."

The comparison of the result obtained by non-operative and operative treatment was as follows:

COMPARISON OF THE RESULTS OF NON-OPERATIVE AND OPERATIVE TREATMENT

	I. Non-Operative	II. Operative		
		I. (Class A)	II. (Class B)	III. (Class C)
No. of Cases	2596	147	78	83
Good Anat. / Good Funct.	1422 = 54.3 per cent.	108 = 73.4%	32 = 41.0%	15 = 18.0%
Bad Anat. / Bad Funct.	169 = 6.5 per cent.	5 = 3.4%	8 = 10.2%	28 = 33.7%
Moderate or Bad Anat. / Good Funct.	419 = 16.1 per cent.	9 = 6.1%	15 = 19.2%	17 = 20.4%
Good Anat. / Mod. or Bad Funct.	138 = 5.3 per cent.	9 = 6.1%	6 = 7.6%	7 = 8.4%

The figures in the second and fourth lines added together give the number of cases in which a good functional result was obtained.

A just criticism of this report is that no distinction was made between the types of non-operative treatment or of the varying ability of the practitioner; while in the operative class at the date of investigation most of the operations were done by expert surgeons, and the operative cases were divided into three classes.

An attempt was made by the Committee to determine the influence of age upon the result of treatment. They found that for all practical purposes age groups might be condensed into children (0–15), and adult life (over 15). Of the non-operative cases there were 1016 under 15 years, with a good functional result in 90.8 per cent., and 1580 over 15 years, with a good functional result in 45.4 per cent. Of the operative (Class A), there were 64 cases under 15 years, with good functional result in 93.6 per cent., and 83 cases over 15 years with good functional result in 66.3 per cent.

The Committee determined that the percentage of good functional results (disregarding entirely the anatomical results) is smaller with each succeeding age group. Their analysis shows that under each age group there is a progressive depreciation of the functional result of the non-operative treatment as age advances; in other words, the older the patient the worse the result.

Attempts to determine the periods of incapacitation of the non-operative were more successful than of the operative cases, owing to

the small number of the latter studied. Of the non-operative cases under fifteen years, the number of cases in which the period of incapacitation was stated was 590, the average number of weeks of incapacitation was 14.7, and the number of cases in which incapacitation was permanent was 1. Of the non-operative cases over 15 years, the number of cases in which the period of incapacitation was stated was 1324, the average number of weeks of incapacitation was 27.6, and the number of cases in which incapacitation was permanent was 121, or 9.0 per cent. Of the operative cases (Class A) under 15 years, the number of cases in which the period of incapacitation was stated was 13, the average number of weeks of incapacitation was 12.2, and there were no cases of permanent disability. Of the operative cases (Class A) over 15 years, the number of cases in which the period of incapacitation was stated was 64, the average number of weeks of incapacitation was 27.3, and the number of cases in which incapacitation was permanent was 5, or 7.8 per cent. Of the operative cases (Class C) the number of cases in which the period of incapacitation was stated was 51, the average number of weeks of incapacitation was 76.6, and the number of cases in which incapacitation was permanent was 8, or 15.6 per cent. Of all fractures over 15 years, non-operative and operative (Class C), the number of cases was 1375, the average duration of incapacitation was 29.3 weeks and the number of cases in which incapacitation was permanent was 129 or 1.0 per cent.

The Fracture Committee of the American Surgical Association, appointed in 1912, has also prepared statistical tables and recorded opinions of value.

In 1913 it mentioned the opinion of the British Committee that the operative treatment required such special skill and experience and such facilities to prevent sepsis as made the operative method one not to be undertaken except by those in constant practice and experience in surgical procedures; and referred to its statement that the operative material available for study was so small as to make it undesirable to draw final conclusions from its statistics as to the relative value of operative and non-operative treatment.

In 1915 the American Committee reported further that the present-day results in subcutaneous (closed) and air-exposed (open), sometimes called "compound," fractures, the average time of disability and the relative value of non-blood-shedding and blood-shedding methods of treatment had been among the points investigated. The British Committee had carefully investigated and tabulated 3062 cases in studying non-operative and operative treatment. The American Committee tabulated 1745. Of these there were 1358 non-operative and 387 operated upon; 258 of the operated cases were subcutaneous (closed) fractures, 129 air exposed (open) fractures.

It found that results are best under 15 years and that treatment

without operation was generally effective in this period of life. This corresponded pretty well with the result of the British Committee.

It also determined that good anatomical restitution of a broken long bone results in better functional result than imperfect reconstruction and permits a shorter period of disability from ordinary duty; that the final result in air-exposed (open) fractures showed very little difference between non-operative and operative treatment so far as anatomical result was concerned, but functional result was better after operative measures except in such fractures of the shafts of both bones, where the reverse seemed to be true.

The average period of disability, *i.e.*, time lost from work in subcutaneous fractures was as follows:

Fractures,	shaft of humerus	14	weeks
"	head and neck of humerus	11.5	"
"	at condyles of humerus	9.0	"
"	shaft both bones of forearm	10.8	"
"	femur all sites	7.37	months
"	leg all sites	4.75	"

Dr. W. L. Estes gives the period of disability in 51 personal patients with open fractures as: femur, 13 months; leg, 6 months; upper extremity, 4 months. He does not say whether or not these were operated upon.

It seems unfortunate that the British Committee did not attempt to separate the non-operative cases into two classes: those in which the fixation by splints was a more or less prolonged immobilization, and those in which mobilization with light massage similar to the Lucas-Championnière method was adopted. One of us (Roberts) is convinced that the great defect in non-operative treatment for years past has been infrequent removal of the external fracture dressings. A consequent infrequent examination of the position of the fragments and a more or less usual neglect of attention to the soft parts by massage and mobilization have given rise to bad results. Hence has come the demand for direct fixation by metal plates introduced through operative incisions. It seems possible that American surgeons have been less attached to prolonged immobilization than the British surgeons. The Continent of Europe has perhaps been more influenced than England by the teaching of Lucas-Championnière; that prolonged immobilization alone is a mistake in the non-operative treatment of fractures. The Report of May, 1913, of the Fracture Committee of the American Surgical Association, made similar suggestion.

Treatment—General Considerations.—The ideal objective in the treatment of all fractures is an anatomical and functional cure—to restore the fragments to a normal position so far as it is possible to do so, and to give the patient the best functional result obtainable. The surgeon's object should be to secure prompt union with as little deformity as possible. Unfortunately, at times, a certain amount of de-

formity is unavoidable, on account of the situation and the nature of the fracture or of the patient's general condition. Usually bony union of the fragments is not difficult of accomplishment. Those injuries in which there is gross displacement of fragments are readily recognized; and their reduction and retention in anatomical apposition ordinarily may be readily obtained. In a fair number of instances, however, union is obtained with deformity, and interference with subsequent function results. The degree of impairment of function and the loss of earning capacity of the patient vary, not only with the variety of fracture but also with the patient's occupation. Impairment of function may be very serious in a patient whose occupation depends upon the perfect use of the part, while the same condition will have little influence in the earning capacity of another. Fractures about joints may seriously impair the earning capacity of patients whose livelihood depends upon the full use of their extremities. Impairment of function after fractures of the lower end of the radius may seriously reduce the earning capacity of musicians and artists. Bad results after fractures of the femur in the neck or above the knee, and especially after fracture of the tibia near the ankle-joint, seriously impair the earning capacity of individuals whose occupation requires marching or prolonged standing. Coxa vara, knock-knee, flatfoot, chronic arthritis are such conditions resulting in impaired function.

Not only should the radiogram be the guide to diagnosis, when practicable, but it should also be the index of treatment and its ultimate results. Perfect reduction and maintenance of proper position of fragments are at times difficult, and mere routine methods of non-operative treatment may be found inadequate. A careful study of each fracture by the attending surgeon, and proper supervision of treatment often, however, will result in better functional results than was anticipated. The tendency toward operative treatment of fractures at present much in vogue is an indication of the poor results obtained by ordinary means in inexperienced or careless hands. If the same degree of attention was given to fractures as is given to abdominal surgery, there would be better results obtained; and many obsolete methods used in the treatment of fractures, even in large hospitals, would be replaced by forms of treatment based upon an intelligent study of each case. It is not that there is needed many radical changes in treatment to-day. The fault lies in hospital chiefs delegating to assistants, and to house officers, the complete charge of fracture patients. If surgeons wish to obtain good results, it behooves them to give fractures the very best attention. The use of the X-ray has shown their shortcomings, and it is only a question of time until the public will demand more efficient treatment, better anatomical and functional results, and less incapacitation from work.

The treatment of fractures may be considered under the following heads:

1. Temporary immobilization of the fragments, transportation of the patient.

2. Reduction of the fragments.

3. Retention of the fragments: (1) without traction; (2) with traction (temporary, permanent); (3) with massage and passive motions.

4. Attention to the soft parts.

5. Functional treatment.

6. After-treatment.

TEMPORARY IMMOBILIZATION OF THE FRAGMENTS, TRANSPORTATION OF THE PATIENT.—In cases of suspected fracture it is not always necessary or wise to make an immediate diagnosis. One's efforts should be confined to temporary immobilization of the part, so that the patient may be transported to the hospital, home, or physician's office for treatment. There are many simple first aid dressings which may be applied by the ambulance surgeon or by laymen. Fractures of the clavicle and humerus may be temporarily immobilized by the use of a suitable sling and fixation to the side; fractures of bones of the forearm and hand by an anterior splint of wood with suitable padding and bandages and sling; fractures of the jaw by an occipitomental figure-of-8 (Barton) bandage; and fractures of the ribs, sternum, or costal cartilages by a circular bandage of the chest, or by a swathe of muslin or of adhesive plaster. Fractures of the pelvis should be temporarily immobilized by a tightly applied swathe of muslin or adhesive plaster around the hips; those of the femur should be supported by a posterior splint from the buttocks to the heel and by an external splint from the axilla to the sole. If splints are not obtainable, a temporary splint may be made for the thigh bone from broom handles or branches of trees and a blanket; or the patient may be transported on a board. Fractures of the lower part of the femur and of the bones of the leg may be temporarily supported in a pillow and side splints of wood. Patients with severe fractures and with fractures of the upper extremities, when the shock is great, should always be carried. Cases of fracture of the vertebræ and pelvis should be very carefully transported, in order not to increase the injury of the spinal cord, or of the internal viscera.

Special beds are convenient in the treatment of fractures requiring the recumbent position. The bed should be a narrow one and preferably high, so that the attendant may readily lift the patient and easily reach each part of his body. A firm hair mattress laid upon slats is the best. Any good mattress, without springs, which does not permit sagging may be used. The usual hospital bed may be converted into a fracture bed by placing slats underneath the mattress from the side frame. Special openings in the mattress for using a bedpan are not

necessary, if the bedpan and urinal are carefully and intelligently placed. It is important in fractures of the femur that the bedpan be not a high douche pan, but a receptacle that may be slipped under the hips without raising the buttocks much from the surface of the bed. If the patient's foot is fastened to traction apparatus, this is especially important. For cases of fracture of the vertebræ or pelvis a special air mattress is advisable so that pressure sores may be avoided as long as possible.

The sheet under the patient should be kept perfectly smooth and should have over it a rubber sheet and a narrow draw sheet; the one for protection to the full size sheet and mattress, the other to permit frequent changing without greatly disturbing the patient. During a long confinement to bed, special attention should be paid to the shoulder and sacral regions and to the heels, which are subject to pressure. These parts should be washed twice daily with alcohol containing a small amount of alum and dusted plentifully with a smooth powder. The greatest possible care should be taken to prevent "bed-sores."

Reduction of the Fragments.—After the patient has been transported to his home, to the hospital, or to the physician's office, a thorough examination of the injured part should be made. Great care should be observed in the examination of all suspected fractures. The clothing should be removed from both the injured and the corresponding uninjured region, in order to give opportunity for comparison of the anatomical landmarks. It is not necessary to cause pain in the examination of fractures. The surgeon's diagnosis should be made by inspection, by palpation, measurement, and radiography. If the clothing cannot be readily taken off, it may be cut and then removed. Before reduction is attempted all apparatus for retention should be at hand and assistants present to give help. Many fractures of the small bones may be reduced without anæsthesia. General anæsthesia, as a rule, should be used in the reduction of fractures of the long bones, in all fractures where satisfactory reduction cannot be accomplished without causing needless pain, when muscular spasm must be overcome, when fractures are complicated with other conditions, and when the radiograph shows failure of anatomical apposition of the fragments following previous attempts at reduction.

Post-mortem examination of a recent case of fracture may show quite an extensive disorganization of muscles, infiltration of the soft parts, and extravasated blood. These conditions accompanying the injury are to a great extent due to movements of the sharp fragments of bone and are not so much the result of the original traumatism itself as to failure of temporary splinting of the part during transportation, to improper handling on the part of the patient's friends, or to temporary examination by physicians. To prevent such injury the

parts should be protected by an improvised splint, and proper precautions taken during transportation to insure immobilization.

The most important object in the treatment of fractures is proper reduction. Without complete reduction, proper anatomical apposition and correct alignment of the fragments are impossible; and the subsequent treatment may be valueless so far as perfect contour and good functional results are concerned. Hence a large proportion of fractures should be reduced under general anæsthesia. Ether or perhaps nitrous oxide gas with oxygen is the preferable agent. Other general anæsthetics are, however, used. By anæsthesia the surgeon is able to overcome muscular spasm, to thoroughly avoid pain, to calm the apprehension of the patient, and to separate impaction of fragments when this is necessary for complete reduction. Moreover, interposition of soft parts may be more readily removed by manipulation, and dislocations accompanying fractures reduced. Above all else, perfect replacement of the fragments is much more likely to be obtained under general anæsthesia, while only partial reduction may be unwittingly accepted without anæsthesia. Lerda and Quénu have used cocaine or novocaine to diminish muscular spasm and pain. They inject a solution of the drug into the muscles and tendons about the fracture and if possible about the regional nerve. They also force it into a joint capsule, and into tendons and ligaments above the joint. This method to overcome muscular spasm and pain may be useful for patients where old age, defective cardiac or renal function, shock, etc., contraindicate general anæsthesia.

Time of Reduction.—As a general rule, reduction of the fragments should be performed as soon as shock has been overcome and proper facilities are at hand for retention of the fragments. In some cases immediate reduction is imperative and should be performed at once. These are injuries in which the fragments press upon or are lacerating important vessels or nerves, or in which sharp fragments are about to perforate the skin or penetrate important vessels, nerves, or viscera.

Obstacles to Reduction.—Reduction may be prevented by interposition of soft parts between fragments, rotation of small pieces of bone, piercing of muscles, tendons, and fasciæ by the sharp ends of fragments, the presence of an accompanying dislocation, impaction of fragments, extreme subfascial swelling, and muscular spasm. Associated injuries or complicating conditions, such as profound shock, hemorrhage, or approaching death may render immediate attempts at replacement unwise. When it is impracticable for any reason to immediately reduce the fragments, the reconstruction, as a rule, should not be delayed more than about a week. In the meantime efficient immobilization of the fragments, combined with extension if necessary, should be maintained.

The actual reduction of a fracture varies with the situation and variety of the lesion. No one method is applicable to all fractures. In fractures of the long bones reduction, as a rule, is accomplished by traction, counter-traction, manipulation and lateral moulding. The surgeon estimates by palpation, measurement, and comparison with the opposite side, the extent of displacement needing correction, and similarly determines the degree of reduction, alignment, and anatomical apposition which has been accomplished. As a rule, he attempts to reduce the fragments by flexion of joints to overcome muscular spasm and then tries to bring the lower fragment or fragments into proper relation with the upper by rotation, abduction, adduction, flexion and extension, combined with traction. Fractures, in which it is recognized that the proximal fragment assumes a certain position from the pull of attached muscles, are reduced by bringing the distal fragment into appropriate position. Impacted fractures may be reducible only by considerable force, which must be applied so as to break up the impaction before the readjustment is possible. Powerful bending may be required to unlock the impaction. Fractures accompanied by over-riding or lateral displacement, in which the line of fracture is serrated and transverse, may generally be reduced by traction alone. Often direct pressure and lateral traction combined with extension may be necessary to produce reduction of fragments. Rotary displacement may be corrected by proper rotation of the lower fragment. Subperiosteal, green-stick and impacted fractures are often corrected by forced flexion and extension. Fractures associated with dislocation may often be reduced by first reducing the dislocation and then the fracture.

When, for any reason, reduction cannot be accomplished and there is no contraindication to open operation, perfect reduction and coaptation of the fracture surfaces should be performed by exposure of the line of break, under thorough aseptic precautions, by men trained to do this class of surgery.

The next important feature in the treatment of fractures, after proper reduction, is the retention of the fragments in proper alignment and the prevention of subsequent deformity. To obtain perfect anatomical as well as perfect functional results should be the aim; the accomplishment of the latter, as a rule, will follow the obtaining of the former. The statistics of the British and the American Committees on Fractures show the dependence of good functional results upon perfect anatomical results; and a large percentage of poor functional results following poor anatomical results. This means, in the majority of cases, faulty reduction, inadequate retention, or lack of proper observation and care on the part of the surgeon in charge. It should, however, be borne in mind that good anatomical results should be striven for in the condition of muscle and tendons as well as in the

bone itself. After reduction has been accomplished, the form of retentive treatment will depend upon the site and variety of fractures. The retention of the fragments and the prevention of subsequent deformity may be accomplished by several means. These methods may be divided into temporary dressings, continuous or permanent dressings, fixation dressings, traction dressings, combined fixation with traction, and ambulatory dressings.

Temporary dressings are used generally to prevent suffering and to protect the soft parts from injury by sharp fragments of bone during transportation of the patient to the place of treatment. They are used also until the maximum swelling has occurred, or for the retention of fragments after reduction until such a time as a continuous or permanent dressing may be safely applied. In some fractures a form of fixation may be used as a permanent as well as a temporary dressing. These cases are mainly those in which extension is not required. Temporary dressings as a rule do not prevent recurrence of deformity.

It must be understood that permanent dressing is not meant a dressing by which the fracture is excluded for several weeks or days from the observation of the surgeon. The shutting up of broken bones in fracture apparatus for long periods is to be deprecated. It is a fruitful cause of undetected deformity, atrophy of muscles, rigidity, and ankylosis. After reduction has been obtained, there is generally no need of local applications like lead water and laudanum and similar remedies. Their efficacy is questionable and they often produce maceration of already devitalized skin and subcutaneous tissues. Immobility and the prevention of muscular spasm are therapeutic agents of far greater value than local applications. The use of the ice-bag may be of some benefit by lessening the amount of exudate. Its use, however, should be carefully watched, as it may cause areas of necrosis.

After reduction has been satisfactorily accomplished there are a few cases in which retentive apparatus is not needed. These cases are, however, rare. A greater safety against displacement of the fragments and the confidence of the patient will usually be better obtained by the use of some form of retention. The best fracture dressings are those which correct the tendency toward displacement in the individual case, preserve anatomical alignment, and prevent over-riding. The special tendency toward displacement varies in each case with the line and position of fracture and this should be recognized before the dressing is applied.

Fracture dressings may be grouped under the following heads:

(1) Those which secure fixation of the fragments by virtue of their inflexibility, and prevent angular or lateral displacement; and in which no traction is employed.

(2) Those in which strong traction with countertraction is the

principal feature upon which anatomical coaptation of fragments and their proper alignment depend.

(3) Those in which moderate traction and indirect fixation are the means of retaining efficient reduction of the fragments.

Very often there may be a combination of several features in the treatment used. The simplest methods and apparatus give the best results. The various articles used in fracture dressings are rigid splints of wood, fibre, aluminum, wire, felt, or pasteboard, applied with bandages or adhesive plaster after appropriate padding with cotton or sheet wadding, contour splints of gauze stiffened with plaster of Paris, silicate of soda, starch, or celloidin; fracture boards, and various apparatus for traction.

The following general rules apply in the application of all forms of dressings:

(1) Do not apply tight bandages next the skin of the limb.

(2) Do not apply any dressing that is too constricting in character or which does not allow for swelling to take place.

(3) Have all splints well padded and do not depend on pads to reduce a deformity. Contour splints moulded to surface are preferable.

(4) Examine every fresh fracture daily after reduction for about a week, and correct immediately any deformity that may occur. Then examinations may be made every other day for a week or so. Subsequently, twice a week will probably be often enough to inspect the uncovered region of injury.

(5) Use general anæsthesia a second time for reduction if the X-ray plates taken at right angle do not show good anatomical apposition of the fragments.

(6) It is well to have an X-ray photograph made in two planes at a right angle to each other after reduction.

(7) In fractures of the long bones, immobilize the joints above and below the seat of fracture.

(8) Splints which are not moulded to the part should be more carefully and more thickly padded with sheet wadding than moulded ones. The latter may fit so well as to practically need no padding.

(9) Many surgeons fix splints to the part directly with adhesive plaster, and do not depend upon bandages alone for keeping splints in position. Remember that adhesive plaster may cause dangerous constriction.

(10) In dressing fractures of the extremities, usually keep the fingers or toes uncovered, so that lividity, coolness, or œdema, due to improper constriction, may be noticed at once and proper measures taken to prevent harm.

(11) Before applying or re-applying a fracture dressing, the skin should be washed with soap and water and then washed with alcohol,

95 per cent. If the skin is hairy it should be shaved before the fracture is dressed.

(12) Before the retentive apparatus selected for treatment has been applied, gentle frictions and light massage, with passive mobility of joints, should be employed. This should be done at every dressing. After the first week or so the patient should be encouraged to move the joints a little at each dressing.

Splints.—The most common retentive dressings are made of wooden splints, which are appropriate strips of wood padded with wool, cotton, or sheet wadding or other soft and elastic material. One or several may be required to give rigid support to the broken bone. For small splints basswood, three-sixteenths of an inch thick, is very satisfactory. For large splints any kind of light wood may be used.

Wooden splints differ in shape and size in accordance with the function which they are to perform. They may be angular when applied to a limb so as to control the action of a joint, or straight and narrow when used for coaptation around a limb at the seat of fracture. Several narrow splints placed parallel to each other may be wrapped between layers of adhesive plaster so as to surround the limb for maintaining coaptation of fragments, while permanent traction or other apparatus may be used to prevent overlapping. The illustrations show several varieties of splints. For temporary dressings pillows or folded sheets or anything that gives rigidity with softness may be used.

Special splints of wood have been devised for use in fractures of particular bones, as internal and anterior angular and the Stromeyer splints for the upper limb, the Agnew patella splint, the fracture box for fractures of the bones of the leg, the double inclined plane, for broken shaft of the femur, the Petit elevated fracture box, the Mitteldorf triangle for the humerus, the Volkmann sliding splint for the lower extremity, and the Liston thigh splint. In addition to these there are many other ready-made splints of wood named after the surgeons who have devised them to meet the indications in various fractures. There are also many forms of carved or moulded wooden splints made in different sizes to fit various parts and to be used at all ages. Nearly all wooden splints are inferior to plastic splints made of gauze dipped in plaster-of-Paris mixture and moulded to the part before the gypsum paste has set. These "contour" splints fit and need little padding; wooden splints are inferior in this particular.

Metal Splints.—There is a great variety of metal splints in use. They are made of wire or wire gauze, aluminum, perforated zinc or tin, or other metals. The most serviceable metal splints are those made in sizes suitable for adults or children, and which are sufficiently flexible to allow the surgeon to modify their contour to fit the patient's requirements.

Moulded Splints.—These are made of leather, poroplastic felt, celluloid paper, modelling materials, and substances suitable for moulding when softened by heat or moisture. As a general rule they are made in five or six sizes, suitable for adults and children.

Plaster of Paris.—The best and a very cheap means of dressing fractures is by splints, made from plastic material for each patient by the surgeon himself. The use of plaster of Paris (gypsum) in the construction of splints or encasements for fractures, a means of fixation, is now very general. The gypsum powder should be fresh, dry, fine, and contain no particles of grit. It is made into a pasty mixture

FIG. 30.—Method of making moulded gypsum contour splints.

with water and used to stiffen, by setting, porous materials, such as crinoline or cheese-cloth. Accurately fitting splints or encasements are thus moulded to the surface of the patient. The material used for the foundation of the dressing may be cut into long strips, and the dry plaster rubbed into its meshes. These gypsum bandages are then dipped into water when required, applied to the limb longitudinally or circularly, and given time to harden. The encasement when dry and firm is split so as to be easy of removal when the surgeon wishes to examine the fracture. The moulded "contour" splints or the case fit the surface of the body and can be readily reapplied.

The best variety of plaster of Paris is dental plaster. The best support for the plaster are crinoline (which has been thoroughly

FIG. 31. FIG. 32.

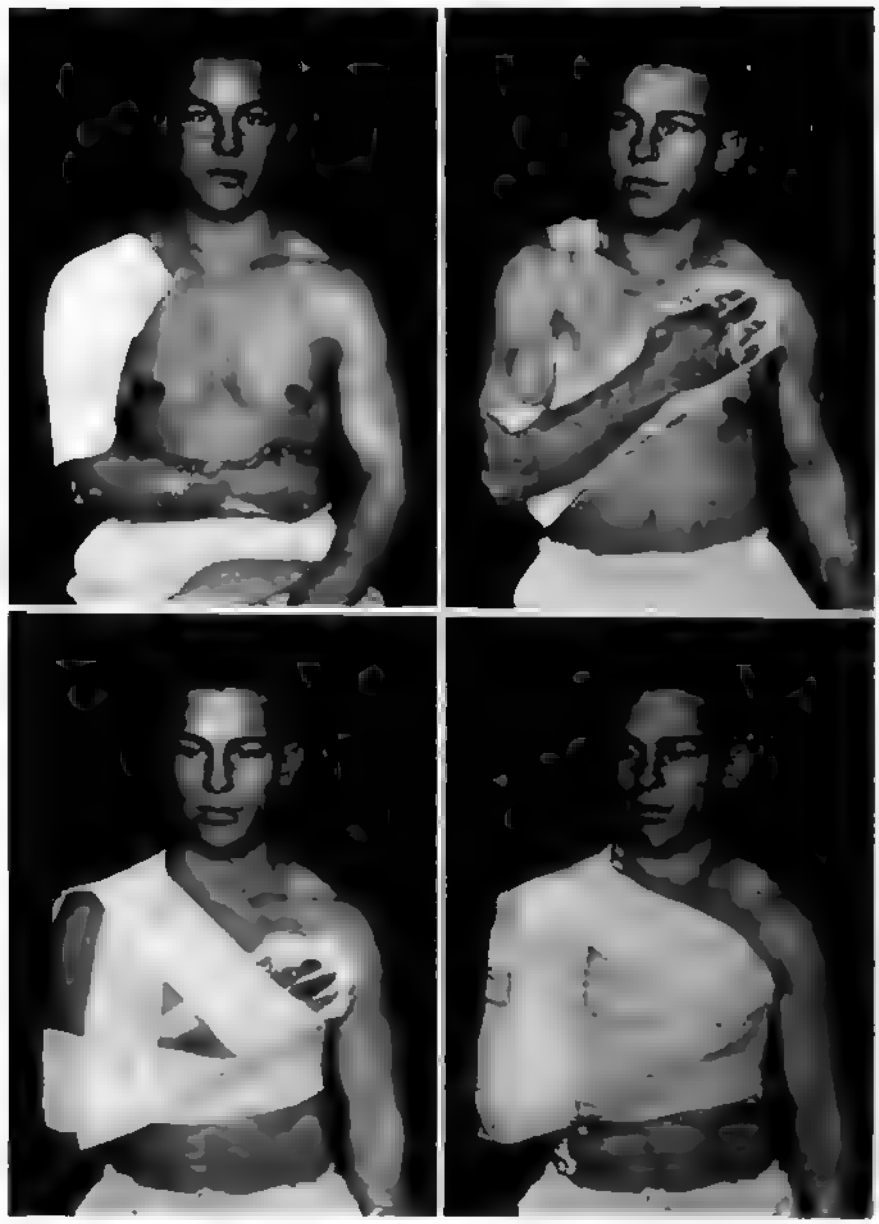

FIG. 33. FIG 34.

FIG. 31.—Moulded gypsum shoulder-cap.
FIGS. 32, 33, AND 34.—Method of using gypsum bandages in treating fracture of the clavicle.
FIG. 32.—Pad over prominent outer end of inner fragment, and separation of skin surfaces by layer of sheet-wadding.
FIG. 33.—Modified Velpeau bandage of muslin.
FIG. 34.—Gypsum bandage applied over muslin bandage giving firm fixation.

FIG. 35. FIG. 36.

FIG. 37 FIG. 38.

FIG. 35.—Gypsum case applied over flannel bandage for fracture of shafts of both bones of forearm.
FIG. 36.—Molded gypsum splint for fracture of shaft of radius or of ulna.
FIG. 37.—Anterior and posterior gypsum splints for fracture of lower end of radius.
FIG. 38.—Method of applying gypsum splints by means of a muslin bandage.

washed, rinsed, and dried), cheese-cloth, mosquito netting, or gauze of fairly large mesh. Plaster bandages may be purchased ready for use or may be made by the surgeon or his assistants. A little experience will show the proper amount of Paris plaster to be rubbed into each bandage, and also how loosely the bandage should be rolled. The plaster should be thoroughly rubbed into the meshes of the cloth, and, after being made, the bandages should be separately encased in wax paper and stored in an air-tight and moisture-proof can. Bandages should be made of various widths, the most useful being two, three, and four inches. In making large moulded plaster splints the size and

FIG. 39. FIG. 40.

FIG. 39.—Moulded gypsum splint for fracture of first metacarpal.
FIG. 40.—Circular gypsum case for fracture of carpal bones or of first metacarpal.

shape of the part to be covered may be first ascertained by making a model in paper. About ten to fifteen layers of netting should then be cut a little larger than the model and thoroughly impregnated with the powdered gypsum. These layers are laid one upon another, wet, and applied to the part. Another way is to lay the paper model on the table, cover it with twelve to fifteen layers of a plaster bandage unrolled back and forth, and while it is still wet apply it to the part (Figs. 30 45). The plaster paste may be simply poured on layers of gauze.

In using plaster-of-Paris bandages the part to which the encasing dressing is to be applied should be first protected by a layer of flannel bandage or by sheet wadding. Then a one-inch wide strip of lead.

greased and wrapped in paraffine paper, should be placed lengthwise over this layer. Above the metal the plaster bandages are applied.

FIG. 41

FIG. 42.

FIG. 41.—Method of holding lower extremity for application of circular gypsum case in the treatment of fracture of the leg. If there is spasm of calf muscles, hold knee flexed.
FIG. 42.—Finished gypsum case applied to lower thigh, leg and foot.

The dried dressing may be readily split with a knife over the lead without cutting the patient's skin. Lead tape is flexible and convenient, but is not necessary. If it is wrapped in paraffine paper before the

bandages are applied, it can be readily withdrawn after the dressing is split. Encasing gypsum dressings applied to the extremities should be cut down both sides immediately after application, on no account should a circular plaster-of-Paris bandage be applied as a primary

FIG. 43.

FIG. 44.

FIGS. 43 AND 44.—Moulded gypsum splints for fractures about the ankle-joint.

splint, unless all inflammatory swelling has occurred and is subsiding. A good rule to adopt is never to apply a circular gypsum dressing until after the fifth day unless it is cut down both sides immediately and all possible constriction is removed.

In using the dry plaster-of-Paris bandages there should be placed five or six of them in a pail of lukewarm water, which should be deep enough to cover them completely. It is not necessary to place salt or alum in the water to promote hardening of the plaster. After all air bubbles have escaped, the bandages should be gently squeezed from both ends to express the excess of water and applied without constriction. Each succeeding layer should be carefully rubbed against the one underneath; and the part should be held by one or two assistants in a corrected position, so that the plaster will set without any undue indentations, finger marks, or cracking. The rubbing in of additional plaster-of-Paris to the outside of the bandage is not advisable, because it does not increase the strength of the dressing much, but greatly adds to its weight. All bony prominences should be especially



FIG. 45.—Moulded gypsum splint for fracture of the metatarsal bones.

well padded, the fingers or toes should be left uncovered for examination, and the encasement may be split down both sides immediately after application. The two parts should then be held together by a gauze or cotton roller bandage. The thickness of the case should depend upon the part to which it is to be applied and the amount of strain that may be brought to bear upon it. Its wall may be materially strengthened without greatly increasing its weight by imbedding between its layers narrow strips of aluminum, zinc, or wood at the points where undue strain will take place. If for any reason it is deemed advisable not to cut the case immediately after its application, it may be readily cut at some future time by moistening the line of incision with warm water, vinegar, or water and hydrogen peroxide combined. The best instruments for cutting an encasement are a pocket knife, any knife with a pruning blade, scissors with serrated edges, and especially designed saws.

The best way of using plaster of Paris as a fixation dressing in open fractures is to apply it in a circular manner and, after the plaster has become firm, to cut one or more windows to give access to the site of the external wound. If this wound is very extensive and a large window is required, the plaster case may be strengthened by incorporating strips of zinc, tin, or iron along its side; or the site of the fracture may be left entirely free, and the plaster applied above and below so held by suitable metal connections or with specially designed wire splints as to support the broken bone in its anatomical relations.

At times it may be considered advisable to surround the window edges in a gypsum case used for an open, or compound, fracture with

[illegible]. The Buck's extension apparatus. Sand [illegible] an external T or Liston splint to [illegible] edge are better than sand bags.

[illegible] This may be neatly done by [illegible] the edges with a solution of rubber [illegible] and afterwards shellacking the entire case. This will [illegible] preserve the integrity [illegible]

[illegible] and encasements are that [illegible] body to which they are [illegible] obtainable in all local- [illegible] of mosquito netting, dry [illegible] ings are to be found in [illegible] The surgeon needs only [illegible] a paste made of the [illegible] surface, let them dry.

remove them, trim the edges, and he has rigid splints of proper size and shape.

Extension or Traction Dressings and Methods.—Traction, often called extension, has been used in the treatment of certain fractures for a long time. Its object is to overcome muscular spasm by exerting a longitudinal pull on the fragments, and to correct over-riding, as well as lateral and rotary deformities, due to muscular retraction. Its use in the treatment of fractures is especially well known in the treatment of fractures of the femur. It was first used by Gross in 1830, in the form of an adhesive plaster dressing with weights; and later it was popularized by Gurdon Buck, whose name has been

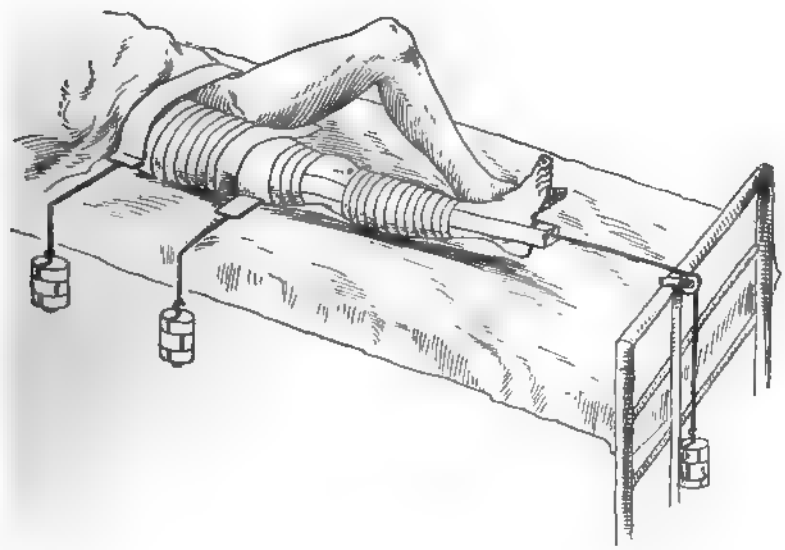

Fig. 47.—Bardenheuer's method of extension. His principles combine longitudinal, counter, transverse, and rotary traction.

given in America to this form of dressing (Fig. 46). During the last twenty-five years traction in the treatment of fractures has been developed on the continent of Europe, primarily by Von Bergmann; and in late years has been especially perfected by Bardenheuer of Cologne, by Steinmann of Berne, and by Zuppinger of Zurich. These last three authorities use methods of traction or extension differing radically in technic and application. Their methods have been extensively adopted by other European surgeons. A short description of the method is as follows:

Bardenheuer's Method (Fig. 47).—Bardenheuer claims that the principal cause of deformity in fracture is general retraction of all tissues surrounding fractures, and particularly the muscles. As a result of the blood infiltration of the soft parts, and especially the

muscle, there is a secondary tissue change of the entire exudate about the fracture, which is most marked in the muscles and results in retraction.

The ordinary method of extension overcomes only the normal muscular contraction. Bardenheuer considers that the ordinary use of weights is not sufficient, and that extension should be positive and sufficient so that not only is the normal muscular contraction overcome, but that the retracted muscles should be permanently stretched. The principles of his method consist in traction in a longitudinal direction with counter-traction, and traction in transverse, rotary, and oblique directions as required. By these various forms of extension

FIG 49.



[illegible] longitudinal, lateral, [illegible] not only good [illegible] of the fragments. [illegible] fracture of the upper [illegible] be used out- [illegible] requires careful [illegible] patient is compelled [illegible] apparatus [illegible] by simpler [illegible] and his pupils [illegible] conclude that [illegible] treatment as one would [illegible] This method

has not been popular in our American hospitals, probably because of the absolute rest in bed enforced in all cases and the careful daily supervision required by the complicated apparatus.

An important outcome of Bardenheuer's teaching has been the fuller recognition of the necessity of securing for fractures careful and frequent attention from skilled surgeons; and therefore the desirability of special wards for these injuries in hospitals. The method of dressing is less important than the conscientious care of a surgeon with mechanical instinct.

The vertical traction method suggested by Thomas Bryant, especially for children, though it is available for adults as well, or its modification, oblique traction, in appropriate cases, as shown in the illus-

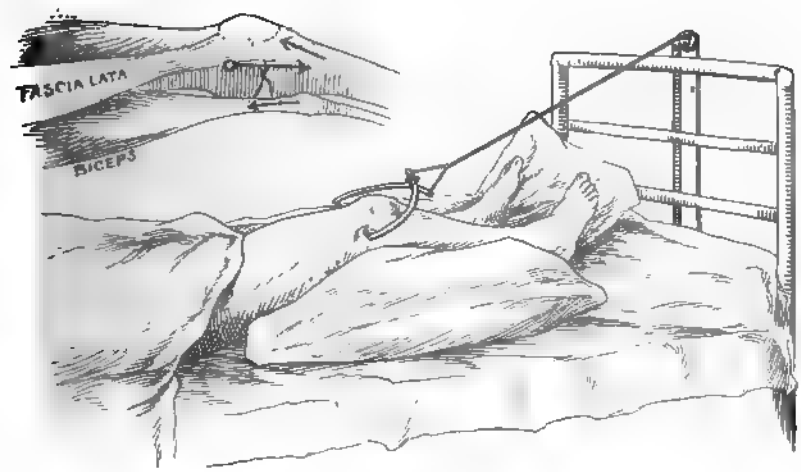

FIG. 50.—Steinmann's method of nail extension shows pin through condyles of femur and traction for fracture of shaft of femur

trations and used by one of us in fractures of femur, will often allow the rejection of complicated apparatus.

The objections to his methods are: (1) The absolute rest in bed required for nearly all fractures treated by his method of extension. (2) The constant supervision required by his various devices, many of which consist of very complicated combinations of pulleys, weights, and means of fastening the apparatus to the patient's limb. (3) The occasional relaxation of joint structures which have been reported following the use of the heavy extension weight. (4) The failure to obtain perfect anatomical results, shown by Bardenheuer's X-ray photograph. In some instances these are not as good as may be obtained with safety by direct fixation under operative treatment. With poor anatomical results it follows that functional results probably will be poor.

Steinmann's Method of Nail Extension (Figs. 50 and 51).—This method was first described by Steinmann in 1907, although it had previously been employed by Codivilla in Bologna in 1903. Steinmann claims that his method differs from that of Codivilla in that the latter uses extension by placing nails in the os calcis. Steinmann obtains traction by inserting nails in the distal fragment of the broken bone, and its application is not limited to fractures of the lower extremity.

Steinmann secures traction in fractures of the long bones by the insertion of a steel nail through the epiphyseal end of the distal fragment, and, by means of an appropriate apparatus attached to the nail, extension is made. Steinmann employs this method wherever extension is needed. He claims that there is no necessary irritation at

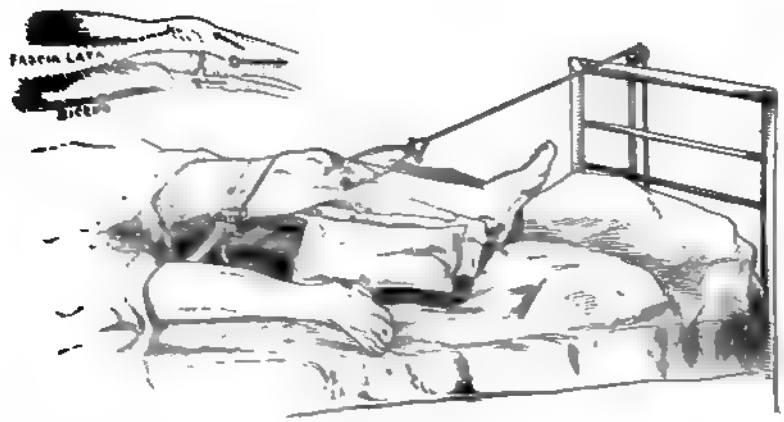

FIG. 51.—Steinmann's method of nail extension for fracture of the femur. Traction is made from a pin driven through the head of the tibia.

the points where the nails enter the skin, that no unusual precautions to prevent infection are necessary, and that less weight is necessary than that required in the extension method with adhesive plaster. He states that with the use of semi-flexion even less weight is required. Steinmann has used these nails in the os calcis for fracture of the malleoli, in the malleoli or through the tibia in fractures of the bones of the leg, in the condyles of the femur for fractures of the shafts or neck. They have also been used in fractures of the humerus and have been employed by Wilms in the reduction of congenital dislocation of the hip-joint. Various modifications of the method have been made by Wilms, Becker, Vockler, Hemmann, Anschütz, and others. Their modifications consist in changes in the form of the nail, the method of applying extension to the nails, or in the method of inserting the nails. The procedure is also of value in reducing old fractures, in delayed [illegible] in compound fractures, and as a preparatory method to the [illegible] fixation of the fragment.

The disadvantages of the method are: The possibliity of infection, by which the nails at times become loosened very rapidly, and the constant supervision. Cases of infection following its use have been reported by Anschütz, by Morian, and others. Other disadvantages are the possibility of over-correction with the formation of false joints, the possibility of gangrene of the skin at the point of insertion of the nails, and the probability of interference with the epiphyseal cartilage and subsequent growth of the bone in children.

Technic of Application of Steinmann's Nails.—Under proper sur-

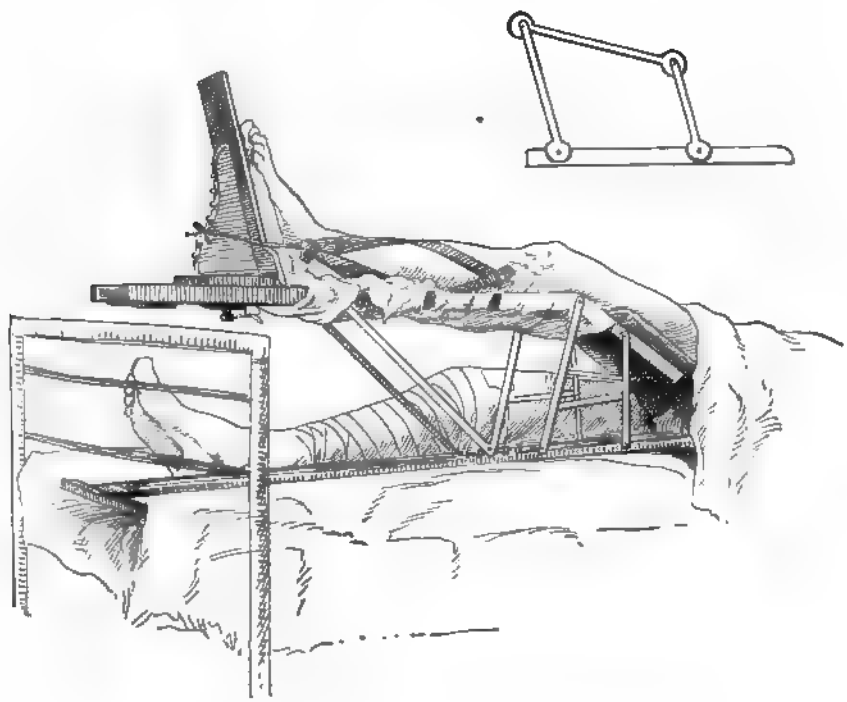

FIG. 52.—Zuppinger's method of traction and support for fracture of the femur.

gical precautions nickel-plated round steel nails are driven into each condyle in fracture of the femur in an oblique direction. At times it may be advisable to use the special drill recommended for drilling appropriate holes for these nails. To the head of these nails there is attached a special apparatus resembling an ice-tongs, and extension is applied directly to this. During the first week 25 to 30 pounds are used, and later 10 to 18 pounds Reposition of the fragments usually occurs by the sixth day, and in some cases over-correction or a complete diastasis may occur. After reduction the amount of weight may be reduced.

There is no doubt that this method is of especial value in certain

forms of fracture, where reduction and anatomical apposition cannot be obtained by other means. The objections to its use are noted above. That it is a method for hospital use alone cannot be too strongly stated. It requires constant supervision.

Zuppinger's Method of Extension (Figs. 52 and 53).—In 1898 Krönlein, before the German Surgical Congress, demonstrated a method of extension for the treatment of fractures of the thigh and leg. This method was devised by Zuppinger, and its principle depends upon an old idea first brought forward by Pott in 1768, that of producing relaxation of the displacing muscles by placing the joints involved in a position to relax the muscles. This principle of relaxa-

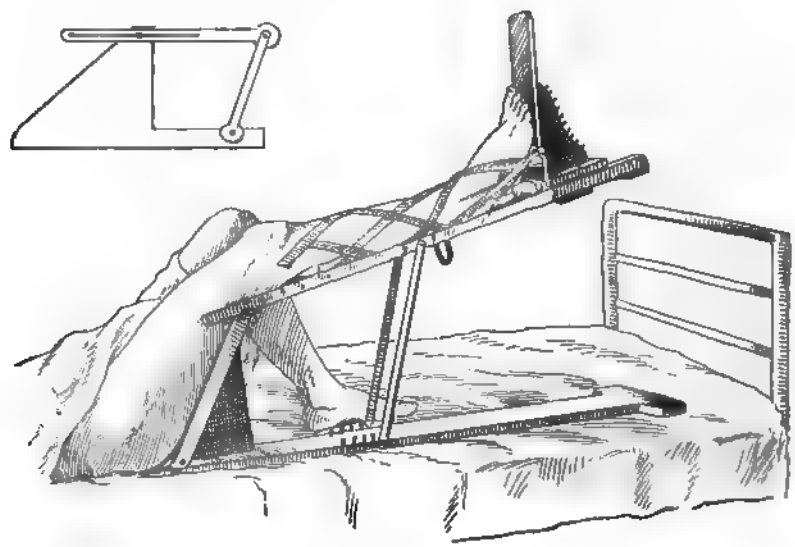

FIG. 53.—Zuppinger's method of traction and support for fracture of the bones of the leg.

tion of the muscles is also used in Smith's anterior splint and in the Hodgen splint. Zuppinger considers that the displacement of the fragments in a fracture is due to the elastic pull of muscles and that in placing the hip and knee in a position of semi-flexion almost all of this tension is relaxed and what still remains may be overcome by a slight weight. He also believes that there is considerable damage done to muscles and joints by the usual methods of weight extension, and that the period of convalescence is longer in these cases.

Zuppinger's apparatus consists of a baseboard, a groove for the thigh, a groove for the leg, a footboard with screws for adjustment, and another for regulation of the amount of flexion. Its principle is similar to Petit's fracture box. The principle is represented by the illustrations. Treatment on this principle has been carried out by a

number of the German surgeons, and excellent results have been reported by Henschen, by Wettstein, by Montadon and Vogel.

The disadvantage of this method is that of the two above described. It requires very careful supervision daily and a considerable amount of mechanical skill is required for its proper application. It is doubtful whether better results are obtained by this method than by the less complicated methods in use in America. Krönlein claims that by Zuppinger's method of extension good anatomical as well as good functional results are obtained.

OPEN (COMPOUND) FRACTURES.—The treatment of open fractures should be conservative, and in each case an endeavor should be made to give a good result with the sacrifice of the smallest amount of tissue. As a rule open fractures are seen soon after the time of injury, and occur in injuries of the limbs rather than of the trunk. They may be divided into four classes: (1) those in which there is not only great pulpefication and destruction of bone, but also crushing and devitalization of the soft parts; (2) those in which there is marked comminution of bone, moderate destruction or crushing of soft parts, no interference with the main blood supply, and a small external wound; (3) those in which there is a fairly large wound, perhaps near the joint, and in addition protrusion of one or more fragments through the wound with considerable soiling of their ends; and (4) those in which there is only a small external wound with very little soiling of the depths of the wound.

In the first class amputation is generally the only thing to do. As a rule there is interference with the main blood supply to the extremity, the soft parts are widely devitalized, and the entire wound so soiled that it is impossible to render it sufficiently aseptic to expect union. Such injuries require amputation, or should be treated as septic osteomyelitis complicated by fracture.

In the three other classes of open fracture a great deal can be done by conservative surgery. The skin should be shaved and washed with soap and water, and great care be taken not to contaminate the depths of the wound. When the surgeon feels sure that contamination has taken place the wound should be thoroughly irrigated with a 2 to 5 per cent. alcoholic solution of iodine. The wound and surrounding skin should then be cleaned with 70 per cent. alcohol, and the wound, if large, partially closed, and drainage, in the form of folded rubber tissue, introduced to its bottom. A dry sterile dressing should then be applied and the part immobilized in a plaster-of-Paris case, in which a window has been cut over the seat of drainage. Unless there is some indication of trouble, such as continued elevation of temperature, pain, or a feeling of local heat, the wound should not be dressed for several days. If there is any indication for examining the

wound it should be uncovered at once, and, if found infected, it should be freely opened for drainage, and thoroughly irrigated daily.

It is probably seldom wise to suture or plate fragments at the time of the primary dressing of an open fracture. General anæsthesia should be the rule when cleansing and reducing severe injuries, because unless the disinfection is thorough and the reduction of fragments satisfactory the convalescence will be long and the anatomical result poor. The primary dressing of an open fracture determines usually the fate of the patient. If asepsis is obtained, the injury progresses almost like a closed fracture. Otherwise prolonged suppuration is probable; and death or amputation not unlikely. If large hæmatomas are present, they may be opened. If the ends of fragments are contaminated, they should be thoroughly cleaned with antiseptics, or perhaps excised. Portions of bone with attached periosteum should be left intact. The less operative interference performed at this stage, the better. The wounds are more or less infected, and while in many cases the infecting organisms may not be virulent, in some the forms of infection are extremely so. Operative extension of the infected wound may, by opening up new paths of infection, lead to disaster. If bone suture or other methods of direct fixation have to be employed, it may be well to wait a week or more. Conservative treatment with good circulation of the part should take care of many organisms, and more perfect reduction be gained by later operation. The most frequent forms of infection are virulent strains of streptococci, staphylococci, aureus and albus, tetanus bacilli, and Bacillus aërogenes capsulatus. The European war has furnished many examples.

A very important step in the treatment of open fractures badly contaminated with street dirt may be the prophylactic use of antitetanus serum. When circumstances have prevented thorough disinfection of the wound soon after its receipt, a subcutaneous injection of 1500 to 3000 units of the serum may be given as a routine measure. Many open fractures, however, are received under conditions that make them no more likely to be infected with tetanus bacilli than other wounds. Those which have been soiled with material liable to harbor tetanus micro-organisms should be viewed with suspicion, as is the case with certain gunshot wounds.

The use of metal plates or other forms of internal fixation is not advisable at the time of primary dressing. In these cases, forms of direct fixation of the fragments to obtain anatomical alignment probably should be used only at a later period, when the pyogenic or other infection has less opportunity to exert its harmful influence and when it is evident that malunion is taking place. They should not be used in the presence of marked infection. Direct fixation of the fragments is contraindicated because of possible infection of the tissues, especially

of bone, of the length of time required, of the increased traumatism done to already devitalized tissues, and the possibility of extensive destruction of bone from stripping up of periosteum.

Important words on the treatment of open fractures are those of Rinmann, of Klauber, of W. L. Estes before American Surgical Association, and of Beavis and Souttar.

MASSAGE AND PASSIVE MOTION IN THE TREATMENT OF FRACTURES.—Recent experience in the treatment of fractures and the knowledge gained by frequent X-ray observation are making radical changes in methods of treatment, and have greatly modified many preconceived notions regarding the pathology and treatment of fractures. Surgeons are now abandoning prolonged immobilizing dressings, and in their place are using methods of treatment which allow a better circulation, less muscular compression, early careful massage, and earlier joint motion. Dressings are not so cumbersome, they are changed more frequently, the muscles are more frequently masséed, so that by the time good firm union has taken place the muscles and joints are in more or less normal condition. With infrequent dressings and prolonged immobilization, loss of muscular tone, muscular atrophy, and restriction of the normal motions of the joint and undetected deformity are quite common. Massage hastens the absorption of exudate, prevents stiffness and atrophy of muscles, and maintains a more normal condition of the circulation. Daily removal of dressings and light massage, if carefully performed, will be beneficial.

In addition, slight passive motion of the joint in proximity to the seat of fracture should be made daily. Light massage and passive motion should be started in suitable cases immediately. During the manipulations the part should be carefully held by an assistant. The motions at first should be very gentle, short in duration, without pain.

Later, when the callus has become firmer, the interval of time may be increased and the massage may be more energetic in character. At no time should the manipulations be violent enough to produce dislocation of fragments. Voluntary motions should be encouraged, and dressings may be, in many cases, so applied as to permit of muscular movement without doing any damage to the position of the fragments. In cases of fractures involving joint surfaces this early massage, and especially passive motion, are of the utmost importance. By their use the surgeon may obtain quite a wide range of motion, which would be impossible with other methods. The only danger to early massage and passive motion is displacement of fragments. This should always be borne in mind, and there are certain classes of fractures where this may be disregarded. The massage should not be the vigorous form often used by professional masseurs for other purposes. Gentleness must be its chief characteristic. The principle of early massage and

passive motion in the treatment of fractures had for its greatest exponent Lucas-Championnière. For many years he advocated these methods, and recommended the disregarding of splints to a great extent in fracture treatment. He was an earnest opponent of prolonged immobilization; and was probably led to take an extreme position, because he saw the bad functional and bad anatomical results due to it.

Early light massage, early passive and active motions, with comparatively simple external fixation apparatus, will usually give better results than the immobilization method as used by many practitioners. It is the adherence to the antiquated immobilization method without passive and active mobility which has given Lane and his followers their chief argument in favor of almost universal treatment by plates and screws.

Functional Treatment of Fractures.—By the functional treatment is meant the use of all means which will preserve the circulation, retain normal muscular tone and joint function, and help in early callus formation. It seems probable that in many instances immobilization is too severe, the use of the fixation dressing too prolonged, and proper supervision of the fracture greatly neglected. It is believed that there are many fractures which, if properly reduced, will remain in correct anatomical position with a minimum of splinting. In conjunction with shorter periods of immobilization and less cumbersome dressings, the functional recovery of the part should be perfect by the time good bony union of the fragments has occurred. This often may be accomplished by early light massage with passive and active motion. What can be done thus is seen in the treatment of the classic fracture of the lower end of the radius conducted on these lines. Complete *reduction*, fixation upon a contour splint, which does not limit voluntary flexion and extension of the fingers, combined with light massage and occasional passive as well as voluntary movements of the wrist from the beginning, and discarding the splint at the end of two and a half weeks, will seldom fail to result in five or six weeks in a good functional and anatomical cure. Deformity of the radiocarpal region after impacted fracture, in which extension and flexion of the wrist are limited, and in which there is marked abduction of the hand combined with œdema of the wrist region and stiff fingers, would be very infrequent. It is adherence to old ideas of the pathology of this injury and unscientific clinging to prolonged immobilization that give rise to the bad results so often seen.

In addition to the suggestions made above, there are other means of improving the function of the part, such as electricity and hot water bathing and in delayed union, congestive hyperæmia locally; and appropriate treatment for general conditions, such as tonics, thyroid

extract, antisyphilitic remedies in those showing a positive Wassermann reaction, with fresh air and sunlight.

The use of passive hyperæmia by means of a rubber bandage about the limb in cases of delayed union in fractures was employed by Roberts and its results published in 1898, and also by Helferich in 1887. Both, it is believed, anteceded Bier in using it in fractures, although he was using it in other conditions in 1892.

Ambulatory Treatment of Fractures.—The advisability of allowing patients to walk during the treatment of fractures of the lower extremity depends upon several factors. There are fractures in which the ambulatory method is clearly contraindicated; on the other hand, there are many, especially of the upper limb, which may be treated in this way without imperiling an expected good result. Again, there are certain cases in which the treatment of the fracture by any formal method is of secondary importance, because the danger of impending complications interrupting the recovery or ending the life of the patient is of greater moment than the securing of a good cure of the fracture. The disadvantages of the ambulant method of treatment are the difficulty of a proper application of the required dressing, and its more careful and constant supervision than when the patient is kept quiet in bed; complications arising at the seat of fracture are more frequent; it is a form of treatment not suited for the general practitioner; in many fractures it is impossible to maintain reduction of the fragments if the patient is moving about on his feet. Therefore, in these injuries, ambulatory exercise may only be used with safety at the end of several weeks, when union is becoming firm. As a subsidiary form of treatment it is often convenient, comfortable and safe.

The advantages of ambulant treatment may be summarized: Pulmonary complications are less, even in the aged; delirium tremens is not so frequent; muscular atrophy and rigidity of joints are not so great, and callus formation is very abundant and rapid. These remarks apply especially to fractures of the lower limb. It is distinctly contraindicated as a rule in fracture of the femur until at least the third week, and in fracture of the shafts of the bones of the leg until the same time has elapsed. After this time it may be used if it is possible to maintain good apposition of the fragments by an appropriate external dressing. When fractures are fixed by plates and screws, the ambulant method may be instituted earlier as a part of the management of the injury. In fractures about the ankle-joint, this form of treatment may be used from the beginning, or at least at the end of four or five days. In fractures of the humerus it may generally be used, even in cases requiring extension. About the only cases that prohibit its use are fractures of the surgical neck of the humerus requiring extension in the abducted position. In a great majority of cases not requiring extension, the best

and cheapest form of dressing will be the plaster-of-Paris case and crutches. In those cases requiring extension there are many well-recognized and appropriate forms of extension braces obtainable; and their number may be supplemented by specially constructed ones to suit the particular fracture under the surgeon's care.

Wearing the sole of the shoe of the well leg one inch higher than that on the injured limb and using long crutches will permit the patient to walk in the open air without risk of bearing weight on the seat of fracture. Keeping the foot of the unsound limb off the ground may also be secured by flexing the knee of the injured side by means of two leather straps around thigh and calf, fastened together with a short strap under the popliteal space. Then it is not necessary to raise the other shoe or lengthen the crutches. Early resumption of exercise is often neglected when easily practicable by such devices.

Functional relaxation of displacing muscles, plastic contour splints, properly applied traction, judicious mobilization and massage associated with a knowledge of anatomy, a mechanical sense and assiduous attention are the requisite therapeutic and professional elements for non-operative management of broken bones in the extremities. Simplicity in fracture dressings is of importance. If elaborate apparatus is required, the patient would probably be better served by the operative method of direct fixation at the hands of a skilled expert in surgery.

CHAPTER II

THE OPERATIVE TREATMENT OF CLOSED FRACTURES

THE treatment of fractures has not received, by the general surgeon during the past fifteen years, the attention that it deserves. Abdominal, pelvic, cranial, and thoracic surgery and their development have been of utmost interest and have occupied the time of general surgeons during these years. The subject of fractures has been neglected; the orthopædists have developed the surgery of joints, tendons, and deformities, but the profession at large has been content with the teaching of twenty years ago in regard to the treatment of fractures. Good functional results were the subject of congratulation. Proper anatomical apposition of the fragments was not considered necessary in fractures, and in many it was rarely attempted. If the patient had a fair functional result and a not too evident deformity, the anatomical position of the fragments was often disregarded. The development and perfection of radiography have shown how poor our work has been. It has taught that perfect anatomical apposition of fragments was rarely obtained, that exuberant callus was the frequent condition, that many text-book methods of treatment of certain fractures were absolutely obsolete and were at times harmful, that the lines of fracture were not always as they were thought to be, and that many supposed sprains and contusions about joints are fractures, sprain-fractures, or avulsion of tubercles and muscular attachments.

The Röntgen ray, in addition to helping us in diagnosis, is of great value in the subsequent treatment. By its use we are able to judge of the continued approximation of the fragments, of the amount of callus produced, and of the extent of union present. The use of the Röntgen ray is wise, not only in cases of suspected fracture; but the majority of sprains, so called, should be radiographed. By making this the customary rule, one not only is able to make a better and clearer diagnosis and use more intelligent treatment, but a great many supposed sprains will be found to be fractures. This is particularly so of injuries about the wrist-joint. Many fractures of the small bones, particularly of the carpals, and unsuspected sprain-fractures will be recognized. In taking radiograms of suspected fractures it is advisable to have a primary radiogram made before reduction, one immediately after reduction, and a third about one week to ten days after the time of reduction. At each X-ray examination two radiograms should be made, one at a right angle to the other, so that the existence

of a fracture and the position of the fragments will be recognized. An anteroposterior and lateral view should thus be made, when feasible.

The dangers of infection of bone in the open treatment of closed fractures have been a constant menace to surgery and have been dwelt upon in text-books for years. Yet operations on tumors of bone and exostoses, and osteotomies for osteomyelitis and periostitis have been unhesitatingly performed. That this teaching has been fallacious is shown by the results obtained to-day in all classes of bone surgery performed under the proper aseptic precautions. While infection of bone is a serious condition, it should not follow a properly performed operation in cases of fracture any more frequently than after abdominal operations or procedures on other structures.

From experience it can be stated that the cases of fracture requiring operation are comparatively few. There are certain closed fractures which always call for operative interference, and there are some cases which are followed by better anatomical and functional results by operative fracture treatment. Open operation has long been used to cure non-union, vicious union in old fractures, and in those recent cases in which failure of the usual methods of reduction has occurred or the use of approved appliances to retain the fragments of bone in apposition has resulted in failure. The cases most urgently requiring operation are those in which the deformity cannot be reduced, or, if this is possible, in which proper approximation cannot be maintained; severe open or compound fractures; compound comminuted fractures in which it is impossible to properly replace the fragments; and cases of non-union, mal-union, and exuberant callus. In many cases in which there is marked comminution of the fragments and in oblique and spiral fractures of the long bones, where reduction is impossible, operative intervention is justified. Many of the deformities, pseudo-arthroses, loss of function, and disability for work following fractures will thus be avoided. The unsightly deformities which so seriously mar the proper contour of the parts and predispose to refracture, excessive callus, and loss of function will be prevented.

Fractures complicated by severe injury to adjacent organs demand operation. Under this heading may be included fractures in which pressure is brought to bear on neighboring viscera, nerves, and blood-vessels, fractures associated with dislocations, and articular fractures. The direct results of improper approximation of fragments are exuberant callus, non-union and malunion. Nerves, blood-vessels, and tendons are liable to be involved in this excessive attempt of nature to repair the loss of bony continuity. Involvement of such structures is often seen in the neuritis, œdema, and plastic involvement of tendons and tendon sheaths following malunion. When excessive callus is formed at the seat of fractures involving joints, impairment and at

times total loss of function is the result. Excessive callus is the result of imperfect approximation and failure of accurate retention of the fragments.

Contraindications to Operative Treatment of Fractures.—These may be grouped under four headings: (1) those due to the fracture; (2) those dependent upon the patient's general condition, (3) those pertaining to the operator; and (4) those relating to the environment.

The contraindications to be found in the fracture itself are few. They are generally infection of neighboring structures, and an infected abrasion of the skin. The contraindications to operation dependent upon the patient's general condition are cardiac, renal, arteriosclerotic, and pulmonic in nature. Any serious involvement of these systems calls for the greatest care in deciding for operative intervention. Patients subject to chronic alcoholism and syphilis are poor risks for operative procedures.

The contraindications pertaining to the operator himself are very important. Operations upon bone require not only the most scrupulous aseptic care, but a great degree of manual dexterity as well as speed. The greatest source of infection following operations upon fractures are infection from without carried from the skin into devitalized structures, prolonged handling of the tissues, bruising of the soft parts, inaccuracy in apposition of fragments, mal-application of the internal fixation apparatus, the presence of dead spaces filled with oozing blood, and failure of complete hæmostasis. Anyone attempting to perform these operations must have a sound aseptic technic, marked dexterity, surgical judgment, mechanical skill, and, above all, must produce as little traumatism to the soft parts as possible. Otherwise his efforts are doomed to failure.

The contraindications from environment are several. One should perform these operations only under the very best conditions. They should not be done where aseptic methods are doubtful. They should be performed only in the best equipped aseptic operating rooms, with assistants trained in this special class of work, and there should be at hand, not only the ordinary instruments used in bone surgery, but in addition such special instruments as may be needed to manipluate fragments into place with the smallest possible amount of damage. In addition a proper mechanical apparatus should be at hand for extension.

Classification of Cases Designated for Operative Treatment.—The Committee on the Treatment of Fractures of the British Medical Association adopted the following classification in their compilation of statistics for their report. It is as follows:

(1) Those cases in which operation is decided upon at once and is performed as soon as possible (Class A).

(2) Those cases in which operation is performed on account of

failure to obtain and maintain accurate apposition by means of external mechanical appliances (Class B).

(3) Those cases in which operation is performed for non-union, for deficient union, or for faulty union, whether in progress or complete (Class C).

In addition to these classes there are those cases of fracture which are treated by non-operative methods, but in which there are subsidiary operations required. These operations consist of tenotomies, osteotomies, excision of joints, removal of callus or projecting fragments, freeing of nerves. These cases cannot be classified with the above.

Indications that Call for Operation.—The results desired in the operative treatment of all fractures are: proper reduction and approximation of the ends of the fragments; the prevention of subsequent deformity; the retention of alignment of the fragments; the prevention of pseudo-arthrosis, non-union, mal-union and deformity; the retention of muscular tone and normal joint movements above and below the seat of fracture.

Many conditions prevent the accurate adjustment of the fragments in fracture of the long bones. They may not only prevent reduction, but are often the cause of delayed union, neuritis, œdema, paralysis, muscular atrophy, loss of function, and at times absolute incapacity. The most frequent obstacles to the complete reduction of the fragments and their permanent retention are: muscular spasm; the interposition of soft parts, as muscles, tendons, nerves, blood-vessels and fascia; infiltration of the surrounding tissues; the piercing of adjacent muscles and fascia by the sharp ends of the fragments; the interlocking of fragments caused by the primary violence; the shortening due to the over-riding of the fragments; rotation of a detached fragment; the difficulty of preserving the anatomical apposition until some form of external fixed dressing has been applied.

Muscular spasm, infiltration of the soft parts, and interlocking of the fragments may be overcome by general anesthesia, manipulation and traction. Repeated gentle massage will frequently lessen greatly the spasm and infiltration. The interposition of the soft parts between the fragments may be removed by careful manipulation and traction. One should be extremely careful not to leave any of the soft parts between fragments as these may result in non-union and actual pseudo-arthrosis. The shortening due to overriding of the fragments may at times be difficult to overcome. In most fractures it can be overcome by traction and counter-traction properly applied, under ether, or by continuous traction applied for several days and aided by gentle massage, or by tenotomy.

In cases of several weeks' or months' standing, mechanical methods necessary for the correction of the over-riding, unless carefully applied and adjusted, may cause marked injury to the soft parts at their points of application. The traction and counter-traction are to be made after exposure of the fracture by the incision. Manual traction is generally inadequate. There are various forms of traction apparatus in use. The compound pulley with clove hitch or Levis plate, is sufficient, but special tables are made. Accurate adjustment of the fractured ends requires, in addition to traction and counter-traction, some form of clamp or forceps. The most feasible are those devised by Lane, Sherman, Lowman, and Lambotte. Various forms of levers are also necessary in getting accurate adjustment.

Time of Operation.—*Class A.*—In certain fractures in which it is known from experience that proper reduction and retention cannot be obtained by non-operative means, it is advisable after preliminary radiographic examination to operate immediately, provided the patient can be assured of an aseptic procedure, is free from grave organic disease, and has had no appreciable shock at the time of the accident, or, if so, has recovered. Spiral and oblique fractures of the tibia, supracondylar fractures of the femur, fractures of the shaft of the femur at the junction of the upper and middle thirds, fractures of the olecranon, patella, calcaneum, with separation of the fragments, are instances. A good index of the amount of shock present is the pulse, blood-pressure, and temperature. By immediate operation reduction of the fragments can be more readily accomplished, blood clots evacuated, infiltration of the soft parts, the formation of fibrous tissue between the fractured ends, and recurrent pain from muscular spasm avoided, and accurate approximation of the fragments accomplished without the necessity of resection with consequent shortening. Union will probably result by primary healing. If, however, the patient has not been seen for several days after the accident, or if the resulting shock or other circumstances prohibited immediate interference, the best results are probably accomplished by not operating until about the sixth or seventh day. This allows the circulation to be re-established, the infiltration to disappear, and the tissues to regain tone, so that the increased traumatism of the operation and possible infection may be readily combated by the forces of nature. In this way the risk of infection is reduced to a minimum.

Class B.—Operations performed on fractures in which there has been failure to obtain and maintain accurate apposition by external mechanical appliances should depend upon several factors. In these fractures there are certain types in which is obtained a fair functional, but a poor anatomical result without operation. Examples are occasional oblique fractures of the tibia, fractures of the clavicle, of the

surgical neck of the humerus, of the shaft of the femur, of the shaft of the radius and ulna combined or separate. In these injuries operation should be performed, when by repeated radiographic examination

FIG. 54.—This figure illustrates the control of the leg in plating fractures, or applying gypsum encasement, using Dr. Hawley's table.

FIG. 55.—Flexion and abduction of the thigh in subtrochanteric fractures of the femur with or without counter-pressure on the upper fragment. Useful in applying gypsum case or reducing fragments

it is shown that the anatomical adjustment of the fragments is so poor that bad functional results with possible incapacity for work are bound to follow.

Class C.—In non union, deficient union, or faulty union the time of operation is dependent upon several factors. The patient's general

health should be improved and local efforts made to promote union in cases of non-union or deficient union. Very often sufficient time has not been allowed for firm union to be complete. Delay in firm union may be due to some general disease; in such cases the condition should be corrected. After all efforts have failed, operation should be performed. In faulty union operation may be performed any time, although it is advisable not to delay too long on account of the secondary shortening of the muscles and the readjustment of neighboring joints and bones to the new lines of support which gradually develop.

Surgical tables are a good form of traction apparatus to reduce the fracture, and maintain immobilization during operation and while the external gypsum case is being applied. They are expensive and only available in hospitals, as a rule. Compound pulleys or manual traction and counter traction will usually suffice.

Fig. 56.—Patient with the legs in extreme abduction, the Whitman position for the treatment of fracture of the neck of the femur. Hawley table.

Technic of Operation in Closed Fractures.—There are many methods of procedure in use for the reduction and anatomic approximation of fragments. The technic of exposing the fractured ends of the bones is practically the same no matter what form of internal fixation is used. The technic may de divided into the following stages: preparatory treatment; reduction and approximation without internal fixation; reduction and approximation with internal fixation.

The preparatory treatment consists in a thorough general physical examination to detect, and the adoption of means to cure or modify, any pulmonic, cardiac, arteriosclerotic, or renal lesions, and the giving of a cleansing enema, if an early operation is determined upon. When the time has been selected, the patient should be given a cathartic. The local treatment consists in shaving the entire extremity, or the region of the fracture, followed by a thorough cleansing of the part with green soap, sterile water, and 70 per cent. alcohol the day before operation, the day of operation cleansing with benzine and painting with tincture of iodine.

The operation should be performed under general anæsthesia. The use of the tourniquet or Esmarch bandage is not advisable, though its advantages might be considerable during the operation by giving a bloodless field. The post-operative bleeding usual after its use is undesirable, and is liable to promote wound infection. A large incision should be used and all bleeding controlled as it arises. The incision

FIG. 57.—Support and traction of the left arm with counter-traction by a wide sling around the body. This position is used for operations on the humerus. Hawley table.

FIG. 58.—Traction with Kirschner wire and Lewis's plate during operative fixation of oblique femoral fracture.

should be sufficiently large to permit thorough inspection of the fractured ends and protrusion of the fragments if deemed necessary. A line of approach to the seat of fracture should be selected which will not injure important structures. The muscles should be separated in their intermuscular planes, when possible, and if not, in a direction parallel to the course of their fibres; nerves and blood-vessels should be carefully avoided. The periosteum should not be stripped away from the bone, if it can be averted, and loose fragments generally

should not be removed; all bleeding should be controlled, and blood clots removed by gauze sponges; intervening structures should be carefully disengaged from the rough ends of fragments and placed in their normal relations, torn structures should be sutured with catgut, if deemed necessary.

FIG. 59. Fixation with two wire sutures of aluminum opposite planes.

REPAIR WITHOUT INTERNAL FIXATION.—It may be found feasible after reduction to maintain approximation without any means of internal fixation. Such cases are very few unless there is marked separation of the fractured ends or a parallel bone for partial support. If the operation is performed shortly after injury, it may then be found possible, by moderate manipulation, or by angulation of the fragments out of the wound, to bring the fractured ends in apposition and lock them together without the use of additional means of support. Great care must be taken, however, to maintain the corrected position of the parts until the external splint is applied.

REPAIR WITH INTERNAL FIXATION.—While, in a considerable number of operative cases, entirely satisfactory retention may be maintained without the use of internal means of fixation, the majority of cases require it. Various mechanical appliances for fixation have been used for holding the fragments in apposition.

FIG. 60. FIG. 61.



FIG. 60.—Low fracture of surgical neck of right humerus. Upper end of lower fragment is pulled upward by deltoid muscle.

FIG. 61.—Application of Lane plate in low fracture of surgical neck of right humerus. (See Fig. 60.)

They may be divided into six classes: absorbable suture, Straus catgut mat; fascial tubes; non-absorbable sutures, as thread, silver and

FIG. 74. Subtrochanteric fracture of left femur. Impossible to maintain reduction of fragm by non-operative measures. Shows application of Lane plate, perfect anatomical apposition of f ments and fairly firm union six weeks after operation. Functional result perfect.

FIG. 75. A—Lowman's bone clamp for adjusting plate.
B—Pierce's bone screw holder and screw driver.
C—Sherman's metal-workers tap screws.

Fig. 76.

Fig. 77

FIG. 78. FIG. 79

FIGS. 78 AND 79.—Transverse fracture of shaft of femur. Application of Sherman plate. Perfect functional and anatomical result.

muscles and should not be superficially placed. The parts should be held securely and carefully until some form of external dressing is applied. The best method of external dressing is a plaster-of-Paris encasement which should be split down each side immediately after

Fig. 80.—Oblique fracture of shaft of left femur; moderate overlapping of fragments.
Fig. 81.—Oblique fracture of shaft of left femur, application of Sherman plate.

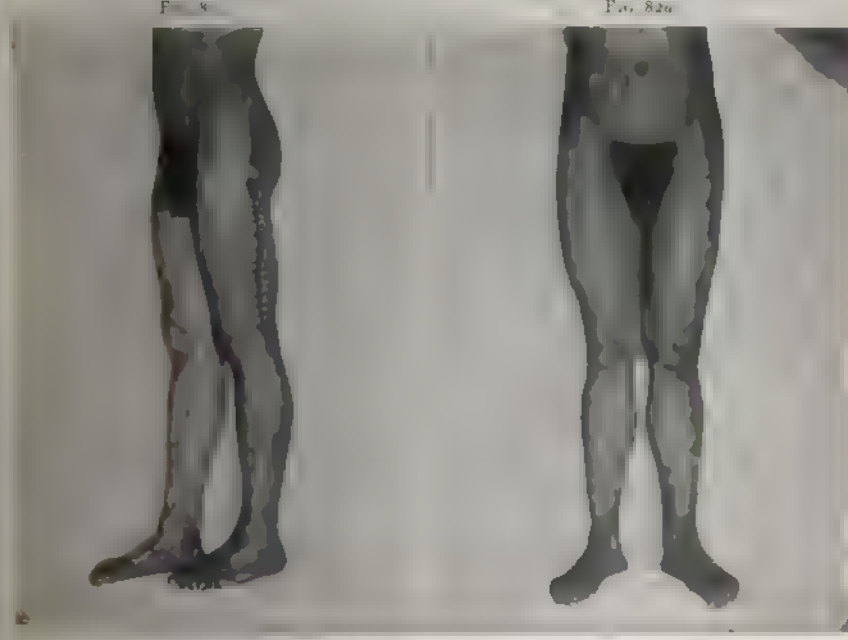

Fig. 82.—Photograph taken at the end of 8 weeks after operation. Note absence of shortening and perfect alignment.
Fig. 82a.—Frontview of same patient as shown in Fig. 82 taken at same time.

Fig. 83.



Fig. 84.

Figs. 83 and 84.—Separation of lower epiphysis of femur. Difficulty in maintaining reduction of fracture. Apposition secured by means of silver-wire suture.

Fig. 85.

Fig. 86.

Figs. 85 and 86.—[illegible] fracture of [illegible]. Anatomical apposition maintained by use of Sherman plate and screws. Photograph shows result. Good shortening.

Fig. 87. Fig. 88



Fig. 89. Fig. 90.

Figs. 87 and 88.—Comminuted fractures of tibia and fibula. Anteroposterior and lateral views.
Figs. 89 and 90.—Application of Lane plate and screws followed by moderate necrosis of ends of fragments (see Figs. 87 and 88).

Fig. 91



Fig. 92.



Figs. 91 and 92.—Lane plate and screws removed, beginning union. (See preceding figures.)

Fig. 93.

Fig. 94.

Figs. 93 and 94.—Photographs showing final results. No shortening, good function. (See preceding figures.)

FIG. 97. FIG. 98.

FIGS. 95 AND 96.—Oblique fractures of shafts of tibia and fibula. Over-riding of fragments and shortening.

FIGS. 97 AND 98.—Application of Lane plate and screws to tibia. Perfect anatomical apposition of fragments of tibia. (See Figs. 95 and 96.)

application, so that the wound may be inspected, if necessary, and massage and passive motion given.

Operations which are performed on account of failure to obtain and maintain accurate apposition by means of external mechanical appliances are now to be considered. Failure to obtain and maintain accurate apposition of the fragments may be due to interposition of soft parts, to the nature of the fracture itself, to muscular action, or to faulty methods of immobilization. These cases are best treated by a primary period of extension for several days in order to overcome the muscular contraction. The only difficulty in operations of this class is that of proper approximation without resection of the ends of the fragments. This, however, may be overcome by manipulation of the frag-

FIG. 99. FIG. 100.

FIGS. 99 AND 100.—Final result in fracture of tibia and fibula after application of Lane plate and screws. No shortening, perfect anatomical and functional results. (See preceding figures.)

ments or by angulating them out of the wound and after locking them forcing them into the wound while extension is made. The ends of the fragments should be carefully freed of portions of muscular tissue, granulations, and callus. The technic otherwise does not vary from that of operations performed immediately after the injury.

Those cases in which operation is performed for non-union, or faulty union, are more difficult to treat on account of the presence of secondary shortening and over-riding of the fragments, muscular contractures, the greater time required for the operation, and the necessity of reconstructive procedure on the ends of the fragments. Martin has shown that there is a rapid and at times a faint fall of blood-pressure with resulting shock from traction alone. This is particularly so

in operations for delayed or faulty union of the femur in which traction is necessary. Careful observation of the pulse and blood-pressure should be made in these cases, while forcible traction is being used.

Constitutional diseases play but a small part in the prevention of union. Examination in such a condition not infrequently shows the fractured ends to be separated and the intervening space filled by muscles or fibrous tissue. The ends of the bone generally over-ride and are smooth, and a condition of pseudo-arthrosis may be present. The technic of operation varies somewhat from that used in recent

FIG. 101. FIG. 102.



FIGS. 101 AND 102.—Open oblique fractures of tibia and fibula. Fireman had leg caught in truck.

fracture cases. An extensive armamentarium is necessary to properly operate, and the use of efficient tools is the chief means of lessening the resulting possible infection by providing for a short operation with little traumatism. Here again one should guard against shock from prolonged traction. The pulse and blood-pressure should be carefully watched. All fragments of callus, and all muscular, fascial and fibrous tissue should be removed from between the fragments. These objects may be the cause of failure of union, and their removal with proper fixation of the fragments will do much to ensure union. In old standing cases of ununited fracture and mal-union (Figs. 101–110), it is

FIG. 103. FIG. 104.



FIGS. 103 AND 104.—Result obtained after reduction and immobilization in gypsum case. Note moderate deformity and posterior angulation at seat of fracture. Röntgenograms at end of six weeks. (See Figs. 101 and 102.)

FIG. 105. FIG. 106.



FIGS. 105 AND 106.—Osteotomy for malunion (see Figs. 101 to 103). Good anatomical and perfect functional results.

necessary to resect the end of the fragments beyond the sclerosed area until the bone-marrow may be seen. In some of these cases it is necessary to remove large masses of exuberant callus in order to approximate the ends of the fragments. Plating is not always necessary. There is no doubt that the presence of a foreign body the size of a metal plate often retards osteogenesis, and in many cases in which plates are used the resulting delayed union is due to this fact.

Of great importance in the operative treatment of fractures is the proper approximation and retention until some form of external splinting is applied. Change in the line of the distal fragments will often

FIG. 107. FIG. 108.



FIGS. 107 AND 108.—Closed fracture of shaft of the tibia, followed by an acute suppurative osteomyelitis. Shaft of tibia removed. Upper portion of tibia has regenerated. Lower portion as shown between two arrows consists of half of first metatarsal bone used as a graft made by Dr. F. T. Stewart. No union between portions of new bone.

produce such strain upon some of the screws as to pull them out entirely and in some cases to even fracture the plate. The vanadium plate and screws, devised by Sherman, overcome, to a considerable extent, these drawbacks to the use of plates. The best form of external splinting is a carefully applied casing of plaster-of-Paris. This should be cut down each side so that massage and passive motion may be instituted within ten days. At the end of a few weeks a patient with a fractured tibia or femur may be allowed up on crutches, if the external casing gives proper support, and weight-bearing on bone is prevented.

Dr. F. H. Albee has had valuable results from the use of bone

grafts in the operative treatment of recent fractures in which reduction cannot be obtained without exposure of the ends of the fragments. He uses a long strip of bone cut from the patient's tibia, and inserts it in a groove cut in the ends of the fragments so as to act as an autogenous splint. He has devised special instruments for removing the transplant or graft from the normal tibia and for cutting the groove in the fractured bone, which make his procedure a rapid, neat, and satisfactory

FIG. 109. FIG. 110.

FIGS. 109 AND 110.—Photographs of Figs. 107 and 108 showing shortening, deformity, and muscular atrophy.

one (Fig. 111). He also has special instruments for cutting the bone graft into pegs or dowels and for boring holes in the bone to be repaired for the insertion of kangaroo tendon sutures or, in certain cases, the bone pegs. The parallel or twin saws, the drills, and the instruments for making the nails or dowels are driven by an electric current. The Albee operation is particularly valuable in ununited fractures, because it not only holds the resected ends of the fragments in correct

alignment, but furnishes osteogenetic cells which aid greatly in the development of ossific union. His method may be used without his complicated and extensive tools, but their use lessens the time of operation and makes the result a neater looking one. Chisels, ordinary drills, osteotomes, and saws of various kinds will accomplish the same result in the hands of any surgeon with usual manipulative skill.

The inlay graft (Fig. 112), as he calls it, is inserted after the fracture has been exposed by a free incision and the ends of the fragments cleared from surrounding soft parts. Excision of the ends, if necessary, otherwise simple manipulation with moulding, is used to overcome deformity. When the freshened ends of an ununited frac-

FIG. 111a.

FIG. 111b.

FIGS. 111a AND 111b. (a) Albee's electric twin saw used in removing transplant from tibia and for cutting groove in the fractured bone. (b) Albee dowel cutter.

ture or the bare ends of a recent fracture are in proper apposition, a gutter is made with the twin saws one-third to one-half inch in width. If the fracture is an ununited one, this gutter should run well beyond the sclerosed fracture ends. In the tibia, for example, the parallel cuts should extend into one fragment for a distance of about five inches; into the other about two and a half inches. The strips of bone between the parallel saw cuts, which go down to the medullary canal, are removed by dividing the bone at the ends with a small osteotome or circular motor saw. The short strip is laid aside and the long one returned into the gutter so as to cross the break between the two fragments of bone, making a splice or inlaid splint. Placing

the bony strip in this position leaves a short gap between the end of the gutter and the end of the inlay in the fragment of bone from which the longer piece was taken. This unfilled portion of the channel is necessarily the exact length of the piece of bone which has been laid aside. This strip can be pushed into the gutter in order to reconstruct that portion.

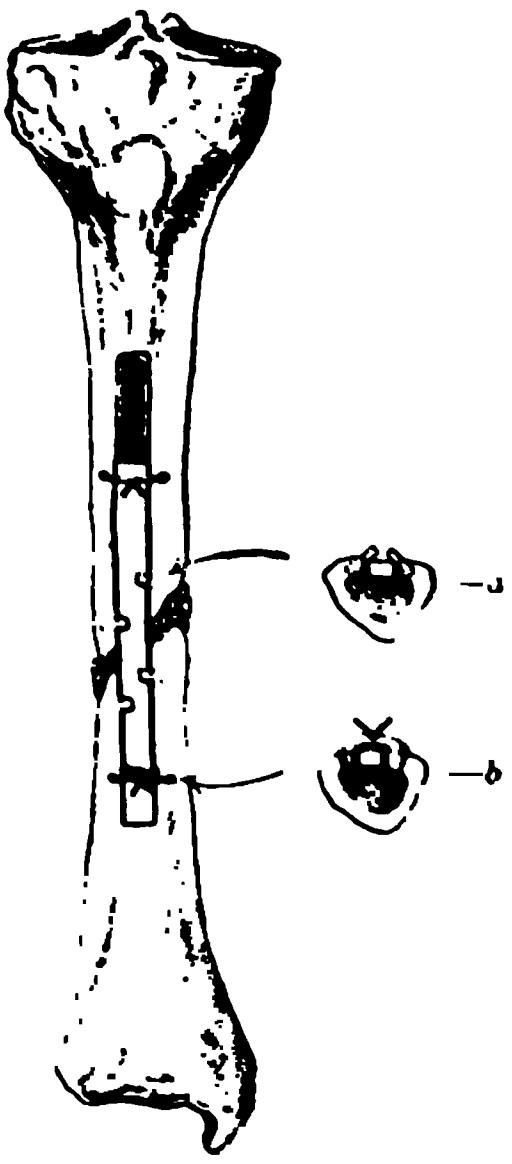

Fig. 113.—Albee's method [illegible] bone graft [illegible] fracture. Graft has been cut from upper fragment and a groove cut in lower fragment. The inlay graft is then placed in position as shown and held in place either by [illegible] as shown in the [illegible] sutures as shown.

Such reposition is not necessary if the surgeon thinks that he needs it to cut into nails or pegs for fastening other fragments of the same injury. The inlay is held in place by kangaroo tendon sutures, passed through holes drilled in the sides of the gutter and carried under the inlay and the ends tied over the inlay so as to force it down and hold it deeply in contact with the floor of the gutter. Four or five of these sutures are sufficient. Small chips of bone, taken from resected ends or from clean fragments removed in preparing the ends for operation, are distributed about the seat of fracture if there are vacancies to be filled by new bone.

When an old ununited fracture is to be treated by the inlay method, the graft is taken from a healthy tibia of the patient. The width and length should be similar to the one cut out of a recent fracture to fix the same. Live bone pegs, or bone dowels, may be made from pieces taken in a similar manner. The inlay graft has for its only function the maintenance of apposition and alignment, and it should not be expected to take the place of external support necessary to prevent accidental displacement from muscular movement or the handling of the patient by nurses. A gypsum dressing is applied after the soft parts have been sutured without drainage and appropriately dressed. Instead of using grafts with parallel sides cut with twin saws, Dr. Albee thinks that in some cases, particularly in fresh fractures, it is preferable to use a single saw and cut the transplant with converging sides going down to the marrow cavity. This gives a graft long and with wedge-shaped sides, cut down to the marrow canal. In making pegs of live bone Dr. Albee prefers the cortical bone taken from the lower third of the tibia, because it is stronger. Such pegs or dowels can be used for fractures of the neck of the femur and, being living tissue, are probably much better than the ivory or dead bone dowels or pegs used by other surgeons years ago. Albee does not care particularly in using bone grafts whether the periosteum

FIG. 113. FIG. 114.



FIGS. 113 AND 114.—Open ununited fractures of tibia and fibula. Note great over-riding of fragments, with deformity and shortening.

FIG. 115 FIG. 116

FIGS. 115 AND 116.—Iliac bone graft in place in tibia. Note alignment of fragments with absence of deformity, except shortening. Single arrows point to site from which graft was taken and double arrows show two views the graft slipped down into place (see Figs. 113 and 114). (Courtesy of Dr. Morris Booth Miller and Dr. George G. Ross. Operated by Dr. Albee.)

is removed or left attached to the graft. The value of living bone is much greater in these plastic reconstructions of bones than that of foreign materials. A centre of osteogenetic activity is provided by the insertion of the living bone from the patient's tissues.

The time has probably arrived when the relative values of the bloodless and the blood-shedding routine treatment of fractures may be settled. Robert Jones, of Liverpool, was of the opinion a few years ago that simply improvement in the customary non-operative treatment of fractures would markedly increase its percentage of good results. Campiche, of San Francisco, has recently expressed his belief that bloodless surgery will probably, in competent hands, give excellent anatomical and functional cures in 90 per cent. of cases.

The British Fracture Committee concluded, in 1912, that a considerable proportion of failures of operative treatment arose from infection, a possibility even with the best technic, and that the operative method required special skill, experience and equipment; that although functional cure may be good with an indifferent anatomical result, the most certain way to obtain a good functional result is to secure a good anatomical curve; that no method not definitely promising a good anatomical result should be the chosen method of treatment; that the direct mortality of blood-shedding treatment was so small in competent hands as not to furnish a sufficient reason for its rejection, and that to insure its best result it should be adopted as soon after accident as possible.

In 1913 the American Surgical Association Fracture Committe formulated these conclusions: That practitioners not trained in surgery as a specialty should adopt a routine non-operative method mi way between prolonged immobilization on the one hand and t mobilization method of Lucas-Championnière or the traction meth of Bardenheuer on the other; and that the watchwords for this cl should be anæsthesia, plastic splints or traction, frequent inspect fractures, early mobility, and delay in weight-bearing. That trai surgeons restricted by moderate efficiency and facility, either pers or hospital, probably should adopt a routine of less prolonged mobilization than heretofore, or of traction with frictions, early massage and mobilization for the usual run of fractures, and that should restrict operative treatment to fractures known to be espe done or found to be so after a few days' study.

Dunmire's answer to the question, What should be th for the skilled surgical expert with adequate fac little real difference in morbidity or mortality v less or a bloodless method for obtaining ideal cure, provided that he personally do fracture, early and after-treatment, and

time at which the patient shall resume his original occupation, and provided he abandons the prolonged immobilization and accompanying negligence so customary in recent years on the part of many having the care of fracture cases in hospital wards.

The American Surgical Association's Fracture Committee reported in June, 1915, that its belief: that in non-operative management of fractures there is no method or splint universally applicable nor has any given splint or apparatus proved its superiority; that traction methods are most frequently unskillfully employed, and with too little weight, as a rule, used, that counter traction is generally required, and that the gauge of the proper weight is the amount necessary to overcome the shortening; that plaster encasements and moulded splints are especially useful after the fracture has been satisfactorily reduced; that fractures should be reduced immediately after injury if it is possible to obtain and apply at that time proper retaining appliances; that anæsthesia should be employed, as a rule, to facilitate reduction and prevent pain; that neither the non-operative nor the operative method is to be recommended exclusively; that the operative method, when adopted, should be employed early, and should, for closed fractures, be undertaken only by experienced surgeons thoroughly equipped by training and with proper instruments and apparatus.

CHAPTER III

FRACTURES OF THE CRANIUM

General Considerations.—In many fractures of the skull the fracture is of secondary importance and the treatment is directed more to improvement of the associated injury of the cranial contents than to the fracture itself. Fractures of the skull may be entirely limited to the locality of the fracturing force without any injury to the cranial contents. On the other hand there may be fractures in which there is little if any injury at the site of the fracturing force, but there may be extensive damage done to the brain and its membranes.

The contents of the three fossæ at the base of the brain may be enumerated as follows:

Anterior cerebral fossa: frontal lobes; olfactory nerves.

Middle cerebral fossa: temporosphenoidal lobes; cavernous sinuses; internal carotid arteries; optic nerves; motor oculi nerves; trochlear nerves; trigeminal nerves; abducent nerves.

Posterior cerebral fossa: cerebellum; occipital lobes; lateral sinuses; seventh, eighth, ninth, tenth, eleventh and twelfth nerves.

Skull—Anatomy.—The skull is the bony covering of the brain and the container of the mouth and the organs of hearing, seeing, and smelling. It is divided into the bones of the cranium and the bones of the face (Fig. 117). The cranial bones are the frontal, the parietal, the temporal, the occipital, the sphenoid, and the ethmoid. The bones of the face are two superior maxilla, two malar, two nasal, two palate, two lachrymal, two inferior turbinated, one vomer, and one inferior maxilla.

The cranium encloses the brain, membranes, and blood-vessels, and may be divided into the vault and the base.

The principal landmarks of the skull (Fig. 118) may be briefly enumerated: *Sutures:* Frontal suture, between the two frontal bones, obliterated early in life; sagittal suture, separating the two parietal bones; coronal suture, separating the parietal and the frontal bones; the lambdoid suture, separating the parietal and the occipital bones. The glabella, the flat surface above the root of the nose; the bregma, the junction of the coronal and sagittal sutures which is the position of the anterior fontanelle in infancy. The lambda is the junction of the sagittal and lambdoid sutures, and is the position of the posterior fontanelle in infancy. The pterion, the junction of the anterior inferior angle of the parietal, the frontal, the temporal and the greater wing of the sphenoid bone; its location is almost one and a half inches behind the external angular process of the frontal bone and about the

same distance above the zygoma. The inion, or external occipital protuberance, may be palpated in the median line posteriorly at the junction of the head and neck. This point marks the position of the torcular Herophili, or the junction of the superior longitudinal, the straight, the occipital, and the two lateral sinuses.

The course of the frontal and sagittal sutures corresponds to a line drawn from the root of the nose (glabella) backwards in the median line to the external occipital protuberance (inion), and marks the position of the superior longitudinal sinus and the longitudinal fissure of the cerebrum.

The mastoid process can be readily palpated behind the ear. About

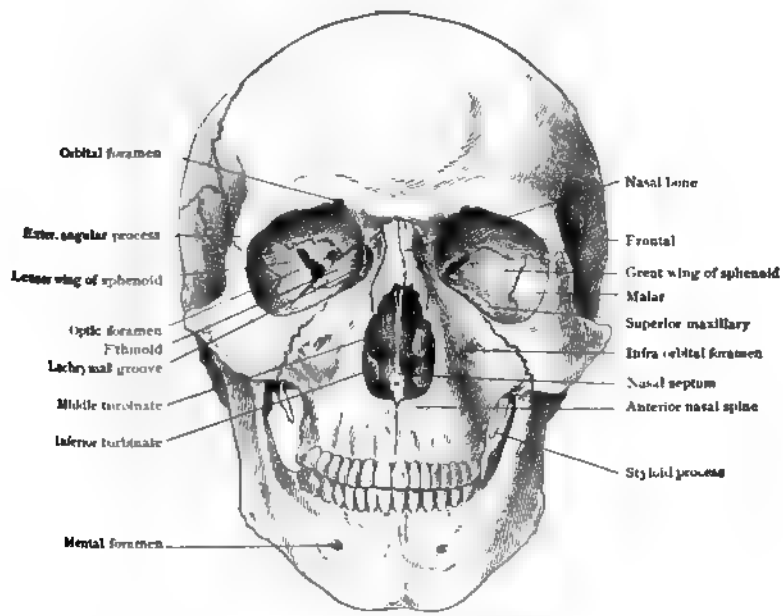

FIG. 117.—Front view of skull (Piersol).

half an inch above and three-quarters of an inch posterior to the tip of the mastoid process is the junction of the lambdoid and squamous sutures, the asterion. The position of the horizontal portion of the lateral sinus is represented by a line drawn from the external occipital protuberance to a point one inch above the external auditory meatus. The course of the sigmoid of the lateral sinus may be represented by a line drawn from the termination of the horizontal portion of the lateral sinus to the top of the mastoid process. The middle meningeal artery, a branch of the internal maxillary artery, enters the cranial cavity through the foramen spinosum. It occupies the groove in the greater wing of the sphenoid bone and divides into the anterior and the posterior branches. The anterior branch crosses the great wing of the

sphenoid and enters the groove in the anterior inferior angle of the parietal bone. During a part of its course this groove is converted into a canal. The anterior branch continues through this canal, runs upward near and parallel to the coronal suture towards the longitudinal sinus, and it at times is accompanied by the sphenoparietal sinus in a part of its course. The smaller posterior branch crosses the squamous portion of the temporal bone and continues along the line of junction of the squamous and petrous portions of the temporal bone to the posterior inferior angle of the parietal bone, to divide into its final branches. On account of its position in the groove of the great wing of the sphenoid and also in the groove and canal of the parietal bone

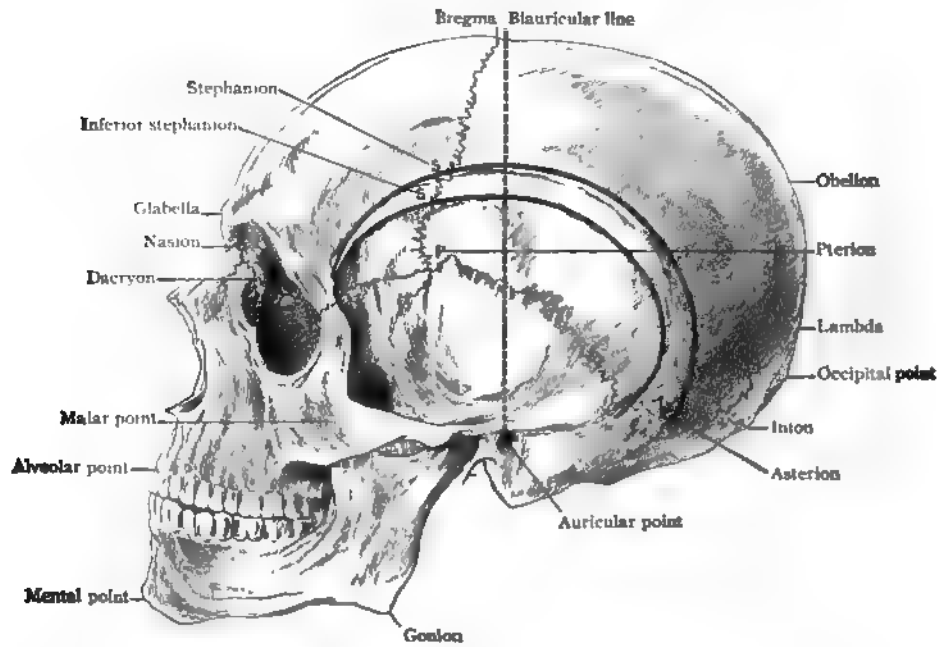

FIG. 118.—Lateral view of skull (Piersol).

and its course through the foramen spinosum, it readily can be seen how fractures in this region may open the vessel, either from alteration in the shape of the canal or foramen or by spicules of bone piercing its coats. The large hemorrhages external to the dura occasionally found in such arterial lacerations are accounted for by the looseness with which the dura is attached to the cranium at this position. Most of the cerebral symptoms seen in fracture in this position are motor in character, because the intracranial bleeding from a torn middle meningeal artery compresses the brain in its motor area.

The principal fissures of the cerebrum are the longitudinal, the sylvian, the Rolandic and the parieto-occipital.

The nasion or the nasofrontal suture, and the temporal ridge marking the upper attachment of the temporal fascia and muscle, are topographical points of the cranium easily located (Figs. 119*a* and *b*). The external angular process is the outer extremity of the frontal bone where it articulates with the malar bone. The stephanion is the point where the temporal ridge crosses the coronal suture.

The lower level of the brain may be approximately determined by a line drawn horizontally across the frontal region through the upper part of the glabella. This line should be continued from the external angular process of the frontal bone through the preauricular fossa to the external occipital protuberance. The cerebellum will be found between the latter portion of this line and a line drawn from the mastoid process to the inion.

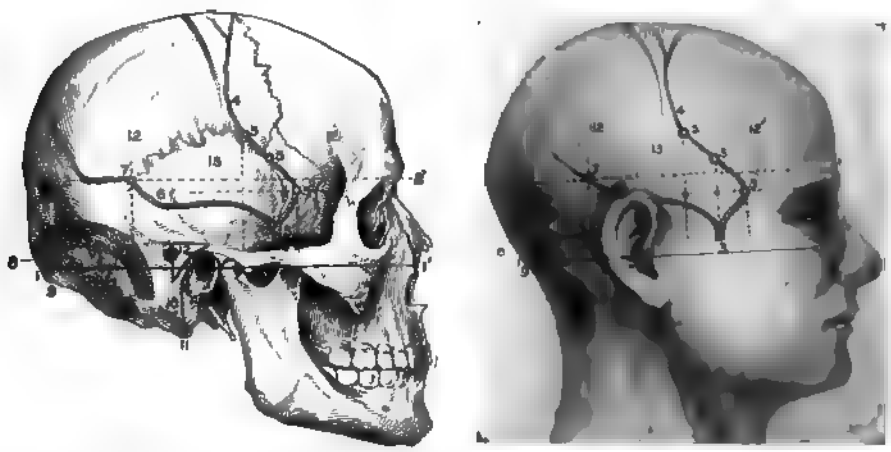

FIG. 119, *a* and *b*.—Craniocerebral localization: 1–1′, Reid's base line; 2–2′, supra-orbital line; 3, middle meningeal artery; 4, anterior branch, 5, the sites for trephining for the anterior branch, 6, the posterior branch, 7, the site for trephining for the posterior branch; 8, the lateral sinus, 9, the inion; 10, the mastoid process, 11, the facial nerve, 12, the temporal crests, 13, the temporal fossa. (Modified after Rawling.)

The base of the cranium (Fig. 120) may be divided into three fossæ: the anterior, the middle, and the posterior. In fracture of the base involving the anterior fossa, blood may enter the orbit and produce a subconjunctival ecchymosis, or in conjunction with cerebrospinal fluid it may escape from the anterior nares or posterior nares. The blood-producing subconjunctival ecchymosis may come from rupture of the meningeal vessels, the ophthalmic artery or vein, or the outer anterior or posterior ethmoid vessels. Bleeding from the nose may be indication of rupture of the nasal vessels. Hemorrhage may also occur in the nose through rupture of the meningeal vessels in fracture of the cribriform plate of the ethmoid. Hemorrhage about the eyelids and subcutaneous tissue of the orbit may be the result of a blow from the outside and not as result of fracture of the cranium. In fracture

of the middle cerebral fossa blood and cerebrospinal fluid may escape from the ear. For this to occur there must be a laceration of the arachnoid, dura mater, mucous membrane of the wall of the tympanum, and the tympanic membrane, in addition to fracture of the base of the skull. Fracture of the middle fossa may involve the sphenoid or basilar process of the occipital bone and produce bleeding into the mouth. It may also cause an accumulation of blood posterior to the pharynx. In fractures involving the posterior cerebral fossa bleeding may show in the posterior triangle of the neck

The cranium varies in density and rigidity in different parts and in

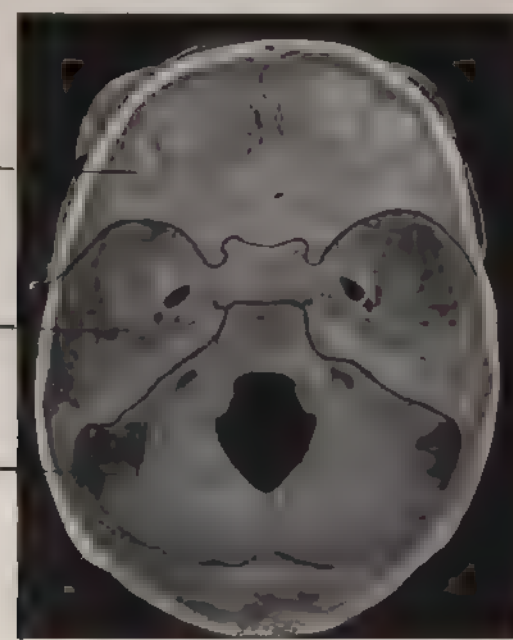

FIG. 120.—The inner surface of the base of the skull, showing the limits of the anterior, the middle and the posterior fossæ.

different individuals. In speaking of fractures of the "cranium," the word "skull" is often used rather inaccurately for cranium. This use is so common that it has been employed in these pages quite frequently. The cranium derives its rigidity and strength from its shape, the thickness of the bone entering into its formation, and from the presence of thickened bone in certain places, which forms buttresses running from the base to the vault. The vault of the skull is strong, not only on account of its shape, but also on account of the presence of the two tables separated by diploic tissue. The diploe is most abundant in the frontal, parietal, and upper occipital regions. These regions are unusually strong in contrast with the squamotemporal and cerebellar regions, in which there is very little diploic tissue. In the base certain

areas are strengthened by buttress-like thickenings, which extend upwards from the crista galli, from the external angular process, from the auditory region, and from the occipital protuberance. Parts intervening between these buttresses are the weak areas at the base. The elasticity of the skull may be demonstrated by letting it fall upon the floor; it does not immediately remain at rest like an unelastic body, but makes several bounds like a baseball or an ivory sphere.

Frequency of Fractures of the Skull.—From a study of 8560 fractures von Bruns found 292, or 3.4 per cent., fractures of the skull. Chudowsky, from a study of 2366 cases of fractures from the surgical clinic of Buda-Pesth, found 90, or 3.8 per cent., cases of fracture of the cranium; 52.2 per cent. were fractures of the vault of the cranium, and 47.7 per cent. were fractures of the base. The fractures of the vault were closed in 32.6 per cent. and open in 67.3 per cent. The site of the fractures were as follows: frontal region, 44 per cent.; parietal region, 40 per cent.; temporal region, 40 per cent.; and occipital region, 2 per cent. The etiology of the fractures was as follows: by falls, 50 per cent.; by blows or kicks, 35 per cent.; by being run over, 9.2 per cent. Sixty per cent. of the fractures occurred between the ages of twenty and forty years, and nine times more frequently in men than in women. H. Plagemann has compiled the statistics of fractures from the Rostock clinic as follows: In 1106 cases there were 31 cases of fracture of the skull, or 2.8 per cent.; in 1165 cases there were 34 cases of fracture of the skull, or 3.07 per cent.; and in 1393 cases there were 59 cases of fracture of the skull, or 4.23 per cent. Of these 59 cases there were 3 between one and ten years; 11 between eleven and twenty years; 16 between twenty-one and thirty years; 11 between thirty-one and forty years; 6 between forty-one and fifty years; 6 between fifty-one and sixty years; 6 between sixty-one and seventy years.

Etiology.—Fractures of the cranium are the result of direct or indirect violence acting upon the skull; and the resulting lesion depends in a great measure upon the site to which the violence is applied, its character, and the method of injury. The lesion may consist, if only the vault of the skull is involved, in a fracture of the outer table, of both the outer and the inner tables, or rarely of the inner table alone. About two-thirds of fractures of the vault are complicated by lines of fracture extending to the base of the skull. Fractures may be classified as fissures, comminuted, diastasis of sutures, depressed, perforated, elevated, and gunshot.

Fissured Fractures (Figs. 121, 122, 123, 124 and 125).—This variety is generally seen as a single line of fracture with very little if any inequality of the two edges of the bone forming the line of separation. They are most commonly seen at the base of the skull and are the result of either bending or bursting forces. The fissure may in-

FIG. 121. FIG. 122





FIG. 121.—[illegible] transverse fracture of the vault. The fracture may be traced from the squamous portion of the left temporal region through the parietals crossing the sagittal suture close to the occipital bone into which the fracture passes behind the temporal bone. Patient fell upon sidewalk, symptoms of compression resulted and death occurred in 12 hours. A clot of blood displaced the dura mater under the parietal bones. (Mutter Museum, No. 1151.37.)

FIG. 122.—Skull. Fracture of the base. In this instance there is no evidence of a point in the frontal region where the blow was received, no fracture is however visible at this situation. The occipital bone is seen to be fractured into three fragments, the line of fracture diverges from a point immediately below the superior curved line a little to the right of the ligamentum nuchæ, from this point one line passes upward to the superior angle of the bone, another obliquely outward to the left mastoid process, the third nearly to the right stylo-[illegible] process. (Mutter Museum, No. 1151.64.)

FIG. 123.—Skull. [illegible] fracture of the right temporal and parietal bones. Recent. The line of fracture passes from the anterior border of the squamous portion of the right temporal bone horizontally backward through the posterior portion of the right parietal to the occipital bone near the superior angle. (Mutter Museum, No. 1151.64.)

volve several bones, and the split may run in a straight line irrespective of the direction of sutures. While the fissure generally occurs as a single crack, it may be forked or have a multiple character. Some-

FIG. 124.—Röntgenogram showing fissured fracture of cranium. Line of fracture extends antero-posteriorly in vault with supplementary lines extending into posterior fossa at base. Child one year of age, fell from the arms of grandfather while being carried.



FIG. 125.—Fissured fracture of vault of skull, occipital region.

FIG. 126.—Comminuted fracture of skull, fronta. region.

FIG. 127.

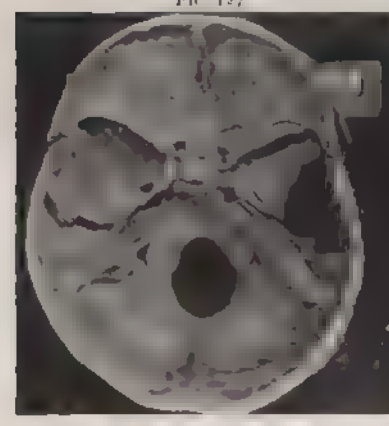

FIG. 128.

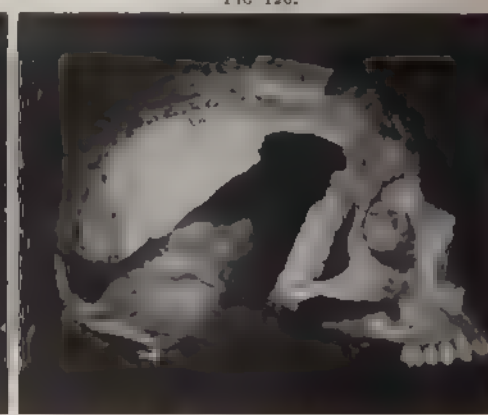

FIG. [illegible]—Skull, lower half, fracture of the base. Recent. The fracture extensive, passing from the right temporal bone through the sella turcica to the left temporal. On the right side the greater wing of the sphenoid is fractured on its extremity, the lesser wing through the median line and the body transversely in the posterior portion of the sella turcica, then the fracture passes just anterior to the left auditory canal and through the squamous portion to the upper border of the temporal bone. (Mutter Museum. No. 1151 [illegible].)

FIG. 128.—Skull, extensive fracture involving the right parietal, frontal, temporal, occipital and sphenoid bones. Woman struck with a pole of an axe while asleep. (Mutter Museum. No. 1151 [illegible].)

times it is impossible to recognize a fissured fracture during life on account of the symmetry of its edges. At times if the fracture is compound portions of hair or clothing may be caught and held between its edges. It is doubtful whether a fissured fracture may be detected by percussion alone or combined with auscultation. Fissured fractures may occur alone or in combination with depressed or gunshot fractures of the skull.

Comminuted fractures (Figs. 126–132) are usually the result of direct violence applied over a small area, and occur most frequently in the vault of the skull. They are characteristic of fractures by bending. They may involve a very small area or be distributed over a large surface. The fragmentation may consist of two or many pieces.

FIG. 129.

FIG. 130

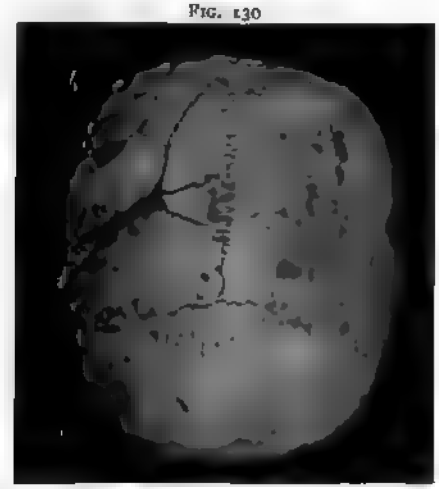

FIGS. 129 and 130.—Calvaria. Fracture of the right parietal bone. The line of fracture extends upward from the base to the vault, involving the right parietal and a portion of the left parietal. This above will how the line of fracture is not affected by the sutures. (Mutter Museum, Brinton Collection.)

Fractures by diastasis (Fig. 133) are a modification of a fissure or comminuted fracture, in which the line of separation is deflected along that of a suture. Necessarily it is seen during early or adolescent life, before the adjacent bones forming suture lines have ankylosed. In later life the condition cannot be truly described as a diastasis, because the sutures have ossified. Lines of fracture, however, may occur along these ossified sutures in conjunction with fissured or comminuted fractures.

Depressed Fractures (Figs. 134–137).—There are three varieties of uncomplicated depressed fracture: Fractures involving the outer table alone, the so-called pond and gutter fractures, and fractures involving both tables of the skull. These varieties of depressed fracture are the result of direct violence applied to the vault of the skull over a

small area, and are usually due to blows with a heavy instrument like a hammer or by the impact of an object falling from a height.

Fractures involving only the inner table of the cranium occur also. These are produced by a circumscribed blow applied to an elastic skull, when the force applied is not great enough to produce depression of both tables. This form of fracture is very rare. Depressed fractures have peripheral depressions, when one portion of the fragment that is driven in is attached to the intact bone, and the other slopes toward the centre of the depressed area and central depressions when the entire depressed fragment is below the level of the intact bone.

Perforated fractures (Figs. 138 and 139) are the result of blows upon either the vault or base of the skull with a blunt instrument, or with a sharp weapon, such as tools, bayonet, and hatchet, applied with sufficient force to penetrate the skull. As a rule all perforating fractures are associated with depression, comminution of fragments, and severe cranial injury. Fragments of bone may be driven deeply into the brain. Perforating fractures obviously are open fractures. Gunshot fractures are usually perforating fractures.

Elevated fractures of the cranium are rare and are seen mainly in military life. They result generally from sabre cuts, and may involve either the outer table alone or both tables together.

Gunshot fractures are a variety of perforating fractures, but they deserve some special consideration. The form of fracture and the extent of injury to the intracranial organs due to the missile depend upon several factors. The lesion produced is dependent upon the nature, size, and velocity of the bullet, the angle of impact, and particularly upon the distance from which the bullet is fired. Von Bergmann states that with the modern, hard shell, high velocity bullet at short range the skull cap, together with the scalp covering it, is torn off; at a range of 50 metres there is a wound of entrance and one of exit, the scalp is preserved, and the skull held together, although the latter was broken into many fragments. At 100 metres there is less destruction of the skull; and the lines of fracture are arranged radially, in part encircling the bullet holes like a bending and bursting fracture. The diameter of the wound of exit is about 20–30 mm. At 800 to 1200 metres the fissuring encircling the bullet

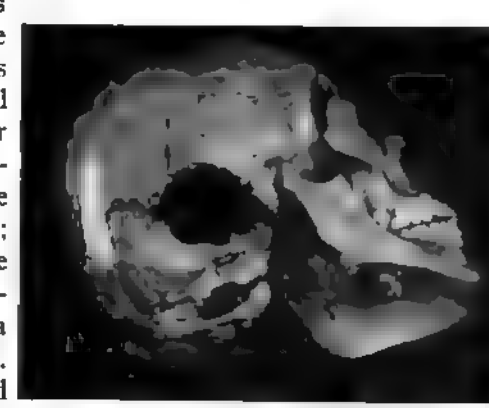

FIG. 133.—Skull; fracture of the superior angle of the occipital bone with fracture of both temporal bones in horizontal line separating the squamous from the mastoid portions and passing through the auditory canals. (Mütter Museum, No. 1151 21.)

FIG. 134.—Röntgenogram showing depressed comminuted fracture of skull parietal region

FIG. 135a



FIG. 135b

FIG. 135 *a* and *b*.—Calvarium fracture of the right parietal, compound comminuted and depressed. The injury was from a sling-shot received immediately above the temporal bone. There are no radiating fissures, but there is depression of a portion of the parietal immediately over the temporal bone, the area is greater in the inner table than the outer table. Trephining was performed immediately. There were symptoms of compression. Death occurred in two days. (Mutter Museum, No. 1151-35.)

FIG. 136.

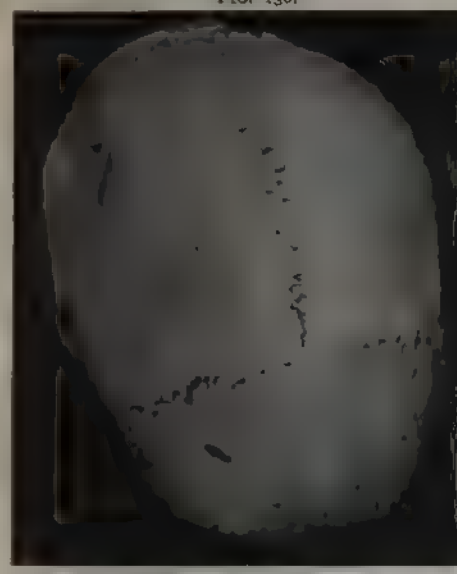

FIG. 137

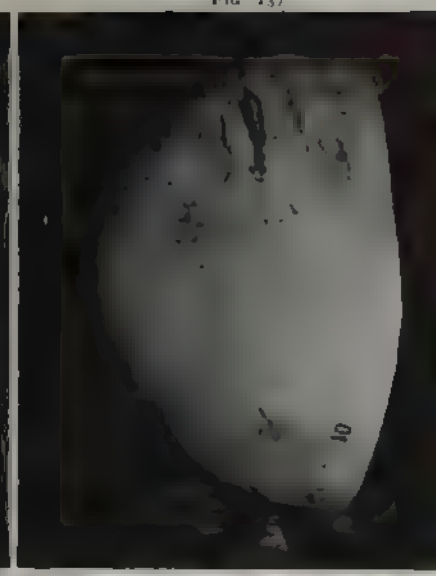

FIG. 136.—Calvarium. Depression of the right parietal. In the posterior portion of the right parietal there is a circular depression having a diameter of from 4 to 5 cm. and a depth of 7 cm. A corresponding depression is seen on the inner side. Evidence of fracture is seen. (Mütter Museum, No. 1151.14.)

FIG. 137.—Calvarium. depressed fracture of the left parietal bone 5.5 cm. long in the left parietal zone parallel to the interparietal suture. The fracture was probably made by a single blow of a a sharp instrument. Both tables involved. (Mütter Museum, No. 1151.11.)

FIG. 138



FIG. 139

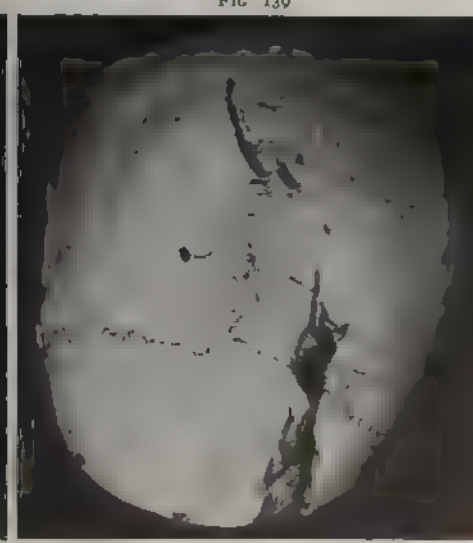

FIG. 138.—Anterior half of calvarium. Punctured fracture at three points with depression of the compact tables. Boy 16 years, fell upon a large wheel covered with spikes of polished iron 9 cm. long sharp at the points and 6 mm. at the base. It was practically a revolving comb for disentangling hemp. The boy was impaled on the hooks and it required two men to release him. Symptoms of meningitis and later tetanus developed and boy died at end of ten days. (Mutter Museum, No. 1151.10.)

FIG. 139.—Calvarium. fracture of left frontal and both parietals. Recent. The fracture evidently was made by a saw. There is an opening 13 cm. long of irregular shape situated in the left frontal and parietal bones. (Mutter Museum, No. 1151.09.)

holes disappears, and only radial fissures are present. At 1600 metres these latter disappear, except that there is one fissure connecting the wound of entrance with the wound of exit. This latter disappears at 1800 to 2400 metres, and the wounds of entrance and exit are clean-cut bullet holes. At 2700 metres the skull is not perforated, the bullet remaining in the brain. The above experiments were made with a hard lead, steel, mantled bullet, fired from a small calibre arm and had an initial velocity of 2000 feet per second. The lesions of the bone are complicated by and intensified by that of the brain itself. It has been shown by v. Coler that there is an explosive action upon the brain proportionate to the distance from which the bullet is fired. These changes

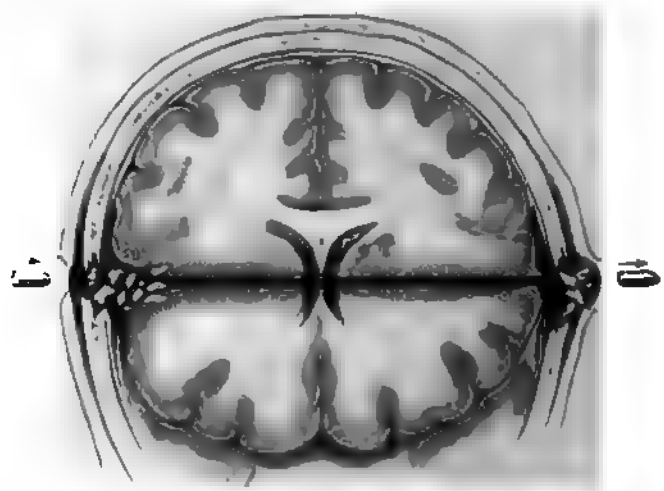

FIG. 140.—Diagrammatic illustration showing effects of a perforating bullet wound of skull and brain. (Modified after Rawling.)

range from total removal of the brain from the shattered skull in short distances to simple perforations at long distances, and finally to simple concussion when the bullet does not penetrate the skull at all. The results produced by the pistol bullet at short range are more or less similar to those produced by the modern high velocity bullet fired from a rifle at long range, according to v. Bruns. Depending upon the angle of impact, there may be perforated, gutter, and depressed fractures of varying degrees.

The wound of the skull is more or less dependent upon the size and shape of the bullet. The composition of the bullet and the fact of it having a hard steel jacket or not will greatly influence the resultant bone lesion. Bullets having a soft nose, the so-called dum-dum bullet, have an explosive action.

The wound of entrance shows changes in the internal table similar to that of the external table at the point of exit, influenced, of course, by the projectile having passed through the brain. The bullet may have somersaulted, and the wound of exit may be made by the blunt rear end of the bullet. Ordinarily the wound of exit has the edges everted, portions of bone may be found in the scalp, and the wound is larger than that of entrance (Fig. 140).

FIG. 141 FIG. 142

FIG. 141. Gunshot wounds of head with fractures of skull. Shows two wounds of entrance. First is close range with powder marks surrounding it; second, close range with actual contact and extensive gas wound which has caused two extensive rips in the skin. (Courtesy of Dr. Wm. S. Wadsworth.)

FIG. 142. Shows the base of the brain case with two probes indicating direction of bullets. One passed into middle fossa, caused a number of lines of fracture in anterior and middle fossa, indicated by marks. The other passed backward, caused extensive bleeding, and caused a general group of fractures in the left occipital region. (Courtesy of Dr. Wm. S. Wadsworth.)

Of utmost importance in gunshot fractures of the skull is the injury to the brain (Figs. 141 and 142). These changes vary from a single track, with points of entrance and exit, with extravasation in neighboring areas, to a condition in which the brain resembles a hemorrhagic pulp. The latter condition is the result of close range bullet wounds, in which the disintegrating and pulpefying of the brain is produced by the expansile effect of the bullet and is accompanied by hemorrhage

into the ventricles and meninges. The condition is invariably fatal.

Hans Brun, from a study of 470 cases of fracture of the skull during 20 years at the Cantonal Hospital in Zürich says that 60 per cent. are the result of falls from a height, about one-half involve the base often alone, and that 70 to 75 per cent. of fractures of the vault are accompanied by fractures of the base. Fractures of the vault are, according to this writer, more often open than closed and occur with equal frequency in the frontal, parietal, and temporal regions, being rare in the occipital region. Fractures of the base are most common in the middle fossa.

Fractures of the Vault of the Cranium.—Fractures of the vault of the skull may be the result of violence applied directly to the vault or may be due to the extension of a fracture of the base. Fractures of the vault are complicated by fractures of the base in about two-thirds of cases. Fractures of the vault are often open, and, when so, are more liable to limitation to the vault. Fractures of the vault depend upon the site of the application of the force, the direction of the force, and the degree of violence used. Most fractures of the vault are by direct violence, and those of the base by indirect violence. Exceptions to the latter are gunshot wounds of the base through the mouth or orbit. Fractures of the vault may be confused with hæmatoma of the scalp, in which depression of the skull may be considered. Hæmatoma may be recognized by the disappearance of the ring on deep, firm pressure, the bluntness and smoothness of outline, by the fluctuation and softness of its centre, and by the minor degree of cerebral disturbance. If in doubt and there are symptoms of compression, the surgeon should treat hæmatoma as a depressed fracture.

Fractures of the Base of the Cranium.—Fractures of the base of the skull are usually the result of indirect violence, applied from the vault and transmitted to the base; or of direct violence. Gunshot and other perforating wounds of the mouth or orbit, the driving upward of the condyles of the inferior maxilla against the socket by a blow upon the chin (Fig. 143), a blow upon the nose, a fall upon the feet or buttocks with transmission of the force through the spinal column, may cause fracture of the base of the cranium in the anterior, middle, or posterior fossa, as the case may be.

Mechanism of Fractures at the Base.—The mechanism of fractures of the skull differs from that of all other fractures. This is due to a number of factors, the principal of these being the hollowness, shape, and elasticity of the skull. Many theories have been given from time to time to account for the types, locations, and varieties of fractures produced, especially in those involving the base of the skull, and physical laws have been deduced to account for the pet theories of each exponent. Many clinical and experimental investigations have

been carried on from time to time, directed toward a solving of the elementary principles of basal fractures. Notable investigations have been carried on by Teevan, Aran, von Wahl, Rauber, von Bruns, von Bergmann, Rawling, Kocher, Messner, Hermann, and others. Of these the most important theories are as follows:

ARAN'S THEORY OF IRRADIATION was that fractures of the base are due to extension from a fracture of the vault and that the lines of fracture follow the shortest anatomical route to the base. It presupposes the co-existence of vault and basal fractures. The theory was modified after observations made by v. Bruns upon the elastic properties

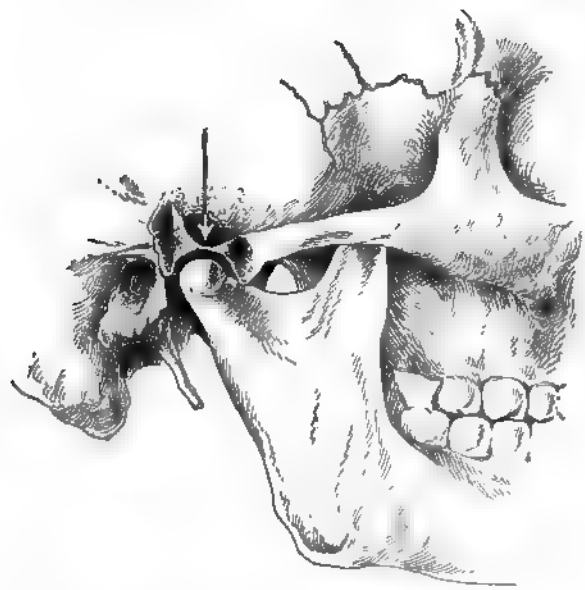

FIG. 143.—Illustrates possibility of fracture of the base of the skull by transmitted force applied to the lower jaw through the condyle, on account of the thinness of the glenoid fossa (marked by arrow). The posterior part of the zygomatic process has been removed for clearness of demonstration.

of the cranium. The conclusion was that these fractures are the result of changes in form, and that the lines of fracture occur along the line of least cohesive resistance toward the pole of impact. This theory has received the support of Messner, Hermann, and von Wahl.

THE BURSTING THEORY.—This is founded upon the elastic and cohesive properties of bone. Compression of one pole of the cranium toward the other produces a diminution in the diameter of the axis with bulging of the other diameters, most marked at a right angle to the line of pressure. When this bulging exceeds the normal elasticity and cohesiveness of bone, a fracture occurs, the line of fracture depending upon various factors. When the fracture occurs on a line

parallel to the line of the compressing force the cranium breaks along the convexity and a bursting fracture is produced; when the line of fracture is at right angles to the compressing force the lesion is termed a compression fracture. Rawling takes exception to these theories on the grounds that they are based upon experimental fractures produced by compressing the head of a cadaver in a tight-fitting box; that cases of bilateral compression are of infrequent occurrence; and that the great majority of basal fractures are the result of blows applied directly at the level of the base or of violent forward propulsion of the body, the head coming in contact with the resisting object. The cranium, he contends, cannot be regarded as a sphere, because it forms only about two-thirds of a sphere, and does not possess requisite elasticity to account for fracture by this means.

THE CONTRECOUP THEORIES were first propounded by the French surgeons, and though one or other has been accepted by many, they are doubtless mechanically unsatisfactory explanations. One of the theories based on the contrecoup doctrine is that, through molecular oscillation, there are waves of vibration sent from the point of impact to the opposite pole and that these radiating waves meeting produce a local lesion, although they are of sufficient force to produce a fracture at the point of impact. Other theories are that, through the influence of hydrostatic pressure carried through the brain and cerebrospinal fluid, the bone is fractured at a point opposite that of impact.

RAWLING'S THEORY OF DIRECT VIOLENCE.—From an investigation of over 300 cases of basal fracture Rawling has obtained the following results: In about 30 per cent. of cases it was possible to show that the fractures of the base were direct extensions from fractures of the vault (Aran's theory of irradiation). In about 5 per cent., the fracture resulted from falls upon the buttocks and from blows applied to the angle of the jaw. In over 60 per cent. of cases the fractures were the result of direct violence applied at or near the basic level, the line of fracture passing across the base in the general line of the applied force. He also considered that all blows applied at or near the basic level tends "primarily to involve the weaker area, the base, passing secondarily upward on to the vault."

Rawling's rules with respect to the probable line of transbasal fracture from a study of over 300 cases are:

"Probable resultant basic fracture varying with the direction, etc., of the applied force: (1) Force applied to the median frontal region (Fig. 144). The fracture passes backward from the perpendicular plate of the ethmoid, thence between the optic foramina to the body of the sphenoid. The fracture diverges to the opposite side, and, tearing off the posterior clinoid process, passes along the petro-occipital suture to the jugular foramen, being then continued on the other side

of that foramen along the masto-occipital suture, and again to the vault.

"(2) Force applied to the lateral frontal region, in the situation of the external angular frontal process (Fig. 145). The fracture passes along the anterior fossa towards the sphenoidal fissure, tearing away the anterior clinoid process, and again comminutes the roof of the sphenoidal sinus. Progressing onwards with or without fracturing the posterior clinoid process, the fracture passes either along the anterior part of the petrous bone at its junction with the greater wing of the sphenoid towards the opposite middle and external ears, or

FIG. 144. FIG. 145.

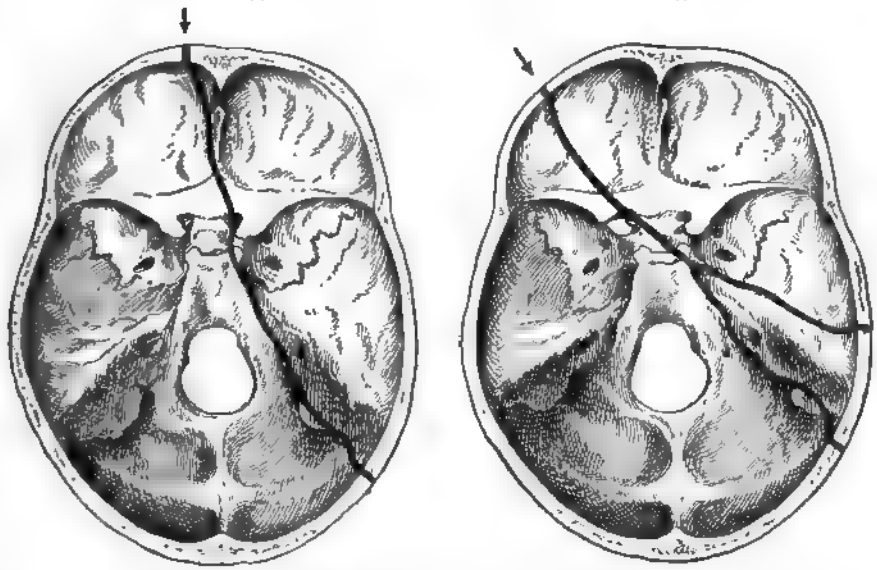

FIG. 144.—Line of fracture of base, from force applied to the median frontal region. (After Rawling.)
FIG. 145.—Line of fracture of base, from force applied to the lateral frontal region, near the external angular frontal process. (After Rawling.)

along the petro-occipital suture to the jugular foramen, and is continued along the masto-occipital suture as in the previous case.

"(3) Force applied to the region of the external ear (Fig. 146). The fracture passes across the roof of the bony auditory meatus towards the junction of the anterior and inner walls of the middle ear, the membrane undergoing a variable amount of destruction and displacement. The fracture is then continued across the tegmen tympani, and, after following the petrosphenoidal suture reaches the foramen lacerum medium, being again continued on the opposite side of that foramen to the sphenoidal body. Thence it pursues one of two courses. Most commonly the fracture passes backwards obliquely to the opposite middle and external ears, following a course similar to that already indicated.

"(4) Force applied to the mastoid region (Fig. 147). The fracture follows the occipitomastoid suture to the jugular foramen, and is again continued to the opposite side of that foramen along the petro-occipital suture towards the apex of the petrous bone. It then passes across the sphenoidal body to the sphenoidal fissure of the opposite side, and so across the anterior fossa. It is especially common in this particular variety of fracture to find fissures diverging from the region of the sphenoidal sinus forwards towards the cribriform plate of the ethmoid, these fissures usually passing between the optic foramina.

"This fracture is also peculiar in that, when the degree of separation along the occipitomastoid suture is excessive, there is special

FIG. 146. FIG. 147.

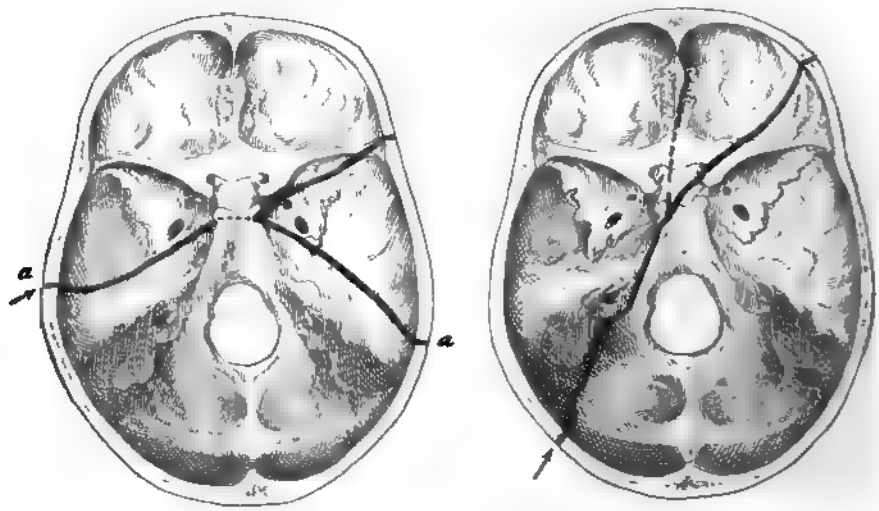

FIG. 146.—Lines of fracture of base, from force applied in the region of the external ear. a–a, the "typical" basic fracture. (After Rawling.)
FIG. 147.—Line of fracture of the base, from force applied in the region of the mastoid. (After Rawling.)

liability to a tearing of the lateral sinus wall as the sinus begins to turn downwards and inwards.

"(5) Force applied to the lateral occipital region (Fig. 148). The fracture passes across the thin cerebellar fossa and strikes the foramen magnum immediately behind the condyle. Starting again from a similar point on the opposite side of the foramen, the fracture passes outwards to the jugular foramen. Two courses are now possible: the fracture either runs outwards across the body of the petrous, 'external' to the internal auditory meatus, and, cutting across the facial nerve in the region of the geniculate ganglion, finally terminates in the roof of the middle ear, or else passes along the petro-occipital suture to the foramen lacerum medium, the sphenoidal fissure, and the anterior fossa as in the previous case.

"(6) Force applied to the posterior occipital region (Fig. 149). The resultant fracture varies according to the direction of the applied force. A force which is applied to the transverse axis of the skull results in a fracture, which, on reaching the posterior margin of the foramen magnum, is continued again on the opposite side of the foramen along the dorsum ephippii. When the force is more oblique in direction, as is usually the case, the fracture traverses the thin cerebellar fossa to the outer margin of the jugular foramen, and then follows one of the two courses indicated in the previous case.

" More commonly the fracture cuts across the petrous bone."

Fig. 148. Fig. 149.

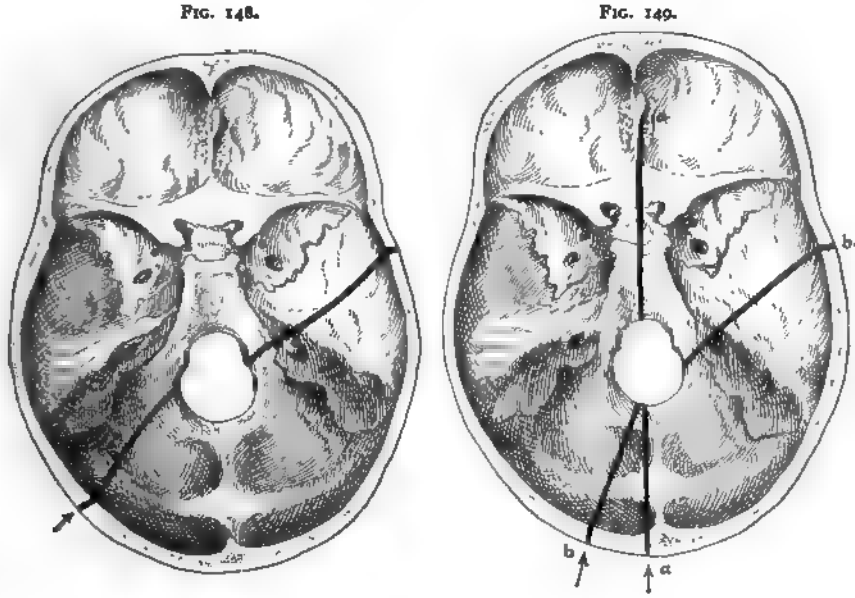

Fig. 148.—Line of fracture of the base, from force applied to the lateral occipital region. (After Rawling.)

Fig. 149.—Lines of fracture of the base from force applied to the posterior occipital region. (After Rawling.)

Symptoms of Fracture of Vault of Cranium.—As a rule the subjective symptoms are of little use in arriving at a diagnosis of suspected fracture of the skull. Fracture may show no special symptoms different from those associated with various forms of intracranial injury.

Fractures of the vault without intracranial lesions are at times very difficult to diagnose. This is especially true in those which are unaccompanied by wounds of the scalp. When there is a circumscribed fracture of the vault there is generally a scalp wound through which the skull may be directly examined and a proper diagnosis made. In these patients a digital examination should be made after thoroughly

cleansing the wound; if necessary the wound should be enlarged for the purpose. Fissured, depressed, comminuted, and perforated fractures may thus readily be recognized. In closed fractures the diagnosis may be obscured by the coincidence of a subaponeurotic or subpericranial hæmatoma. The differential diagnosis of these two conditions is not always easy without exploration. It is justifiable to incise the scalp for diagnostic purposes, whenever there are symptoms pointing to probable depression of fragments or localized intracranial injury, or when the character of the traumatism makes it likely that the bone may be broken. An aseptic incision of the scalp is practically without danger; but an undiscovered fracture, particularly of the punctured kind, may lead to secondary epilepsy or other serious sequel. When there is doubt as to the treatment to be pursued because the existence of fracture is not established, it is wise to incise the scalp for exploration. In intracranial injury the symptoms may be due to the occurrence of cerebral laceration, or cerebral pressure from fragments or from blood clots resulting from damage to the middle meningeal artery or other vessels. In addition there may be fixed pain in certain regions, symptoms of compression as shown by combined or partial paralysis of the opposite side of the body, late evidence of encephalitis, or suppuration. The symptoms of cerebral concussion, cerebral irritation, and cerebral compression will be referred to briefly later.

All fractures of the vault should be radiographed in several different directions and the diagnosis of a fracture may be facilitated by this means. When radiography is not available the surgeon should not allow the patient to suffer because he is too timid to cut down upon the injured region. It is proper to open the scalp to examine the bone, and to trephine the bone to examine the brain. Delay from doubt may be more risky by far than aseptic operation for exploration. This means that aseptic procedures are often necessary for diagnostic and therapeutic purposes.

Symptoms of Fracture of the Base of the Skull.—The principal symptoms of fracture of the base of the skull are hemorrhage, the escape of cerebrospinal fluid, or of brain matter, the exit of air from the air sinuses into the surrounding tissues, disturbance of cranial nerves, pupillary changes, and temperature changes.

Most of the symptoms may be grouped in relation to fractures involving one or more of the fossæ of the skull.

Anterior Fossa.—Hemorrhage from the nose or mouth is generally present in fracture of the anterior fossa involving the cribriform plate of the ethmoid. Nasal hemorrhage is observed when there is associated hemorrhage into the subarachnoid space. Orbital hemorrhage, causing proptosis, has its origin in a fracture associated with injury to the cavernous sinus or internal carotid artery, in a fracture

of the orbital walls and laceration of the ethmoidal vessels, or in a fracture of the sphenoidal body complicated by a fistula between the cavernous sinus and internal carotid artery. Palpebral, peripalpebral and subconjunctival hemorrhage is not always diagnostic of fracture involving the anterior fossa. It may, however, be present in fracture involving the perpendicular plate of the frontal or the cribriform plate of the ethmoid bone.

Fleming reported twelve cases of fracture of the skull, eleven of them being fractures of the base, and in all of these there was retinal hemorrhage.

Middle Fossa.—Hemorrhage may occur from the mouth or ear. This is possible because most fractures of the middle fossa involve the external auditory canal, the inner and anterior walls of the middle ear, the membrana tympani. The blood escaping from the ear may be derived from the vessels of the lining membrane of the external and middle ears, from the tympanic vessels, from the lateral sinus, or from the middle meningeal artery. Profuse and long-continued hemorrhage from the external ear generally means injury to the lateral sinus or middle meningeal artery (Figs. 150 and 151).

Crandon and Wilson give the following statistics in reference to hemorrhage from the ears, nose and mouth, and mortality in fractures involving the middle fossa:

Hemorrhage from the ear.....	281	170	111	39 per cent.
Hemorrhage from both ears.....	47	16	31	66 per cent.
Hemorrhage from the nose.....	44	17	27	61 per cent.
Hemorrhage from the mouth.....	168	73	93	33 per cent.

Dwight has shown from a study of 146 cases of fractures of the skull, studied at autopsy, that in 69 per cent. of cases of fracture of the middle fossa there was bleeding from the ear, and that in 29 per cent. of cases there was an associated laceration of the middle meningeal artery.

Hemorrhage from the mouth may have its source in lacerations of the sphenoidal or pharyngeal vessels, or from the internal carotid artery or cavernous sinus, complicating fractures of the sphenoid body and laceration of the pharyngeal wall.

Hemorrhage in the temporal region is generally seen in fracture involving the temporal fossa, the blood being either confined to the mporal region, forming a temporal hæmatoma, or it may be diffused roughout the subaponeurotic space.

Posterior Fossa.—Hemorrhage in fracture of this fossa is often in appearing, and is frequently confined to the subtentorial region; he discoloration does not involve the soft parts, the hemorrhage make itself evident as a boggy ecchymotic area diffused over the rior surface of the scalp, the neck, and the mastoid region.

A flow of cerebrospinal fluid may take place from the nose, mouth, or ears, and is generally diagnostic of fracture of the base of the skull, associated with rupture of the overlying dura and arachnoid membranes. The source of the fluid is the subarachnoid spaces. Crandon and Wilson reported 27 instances in which escape of cerebrospinal fluid was present out of 530 cases. Phelps found 13 in a series of 286 cases of fracture of the base; and Anna Heer recorded 58 cases of fracture of the base, in 27 of which there was an escape of cerebrospinal fluid from the ear and in 2 from the nose.

Fractures involving the anterior fossa may be associated with the escape of cerebrospinal fluid from the nose, in which case there is

FIG. 150

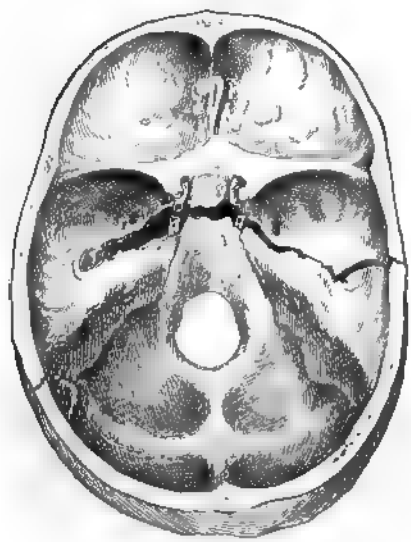

FIG. 151.

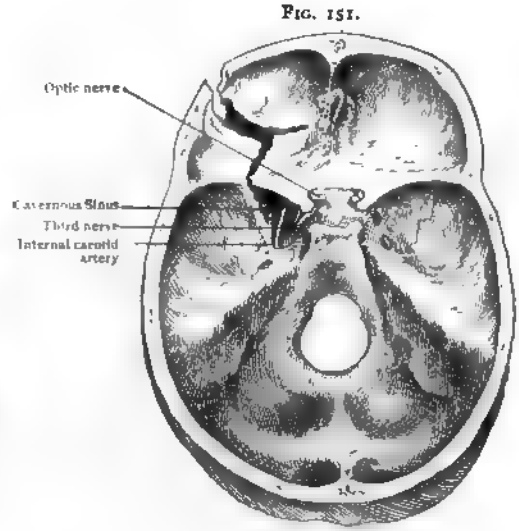

FIG. 150.—Fracture of the base with laceration of the carotid arteries. (After Rawling.)
FIG. 151.—Fracture of the base with laceration of the cavernous sinus. (After Rawling.)

generally a fracture of the cribriform plate of the ethmoid. The escape of cerebrospinal fluid from the nose, mouth, or ears may be seen in fractures involving the middle fossa. The presence of fluid flowing from the external auditory meatus generally means fracture of the middle fossa. Rawling is of the opinion that the escape of cerebrospinal fluid is an infrequent symptom of fracture of the middle fossa; but states that fractures, originating in the posterior fossa, may cut across the petrous portion of the temporal bone in such a manner as to sever the seventh nerve and to tear the dural and arachnoid prolongations of that nerve. In such lesions there will be a discharge of cerebrospinal fluid from the ear, if the tympanic membrane is ruptured; but if there is no injury to this membrane, the escape of cerebrospinal

fluid will take place from the nose or nasopharynx by means of the Eustachian tube.

The escape of cerebrospinal fluid may begin immediately after the injury and may be very profuse. von Bergmann states that in some cases there may be from 150 to 200 grammes collected in twenty-four hours, and Stimson refers to a case in which 63 ounces were collected in four and one-half days. Sir W. MacCormac reports a case in which 10 pints escaped within five hours. The cerebrospinal fluid escaping from the nose, mouth, or ears should be of the same chemical character as that found normally in the subarachnoid spaces. It should be alkaline in reaction, contain a trace of albumin, be rich in sodium chloride, and should show a trace of a reducing substance allied to pyrocatechin. The escape of cerebrospinal fluid from the nose, mouth, or ears may be contaminated with normal discharges from these orifices, and render the tests noted valueless. Generally the fluid is at first blood-stained. Other sources of error are seen in the escape of a fluid which is highly albuminous and contains no chlorides, which has its origin from the large perilymph spaces of the labyrinth, the liquor cotunnii. Another source of error is a serous discharge from the mucous membrane of the ear or nose, which can be differentiated from cerebrospinal fluid by its chemical characteristics. Inflammatory discharges from these two surfaces may also be profuse and lead to error, or be the sources of contamination. The serum from extravasated blood may lead to error. In this instance it is not very profuse, is reddish, albuminous, and does not appear immediately after the injury.

The escape of brain tissue is of very rare occurrence. Rawling has observed one case of escape of brain tissue from the nose and one from the ear in a series of 300 cases. Its presence is a positive sign of fracture of the skull and also of laceration of the dura and arachnoid. There is generally considerable comminution of bone, such as occurs in crushing injuries. In a case of one of the authors, in which the head was injured in an elevator accident, there was subsequent discharge of brain tissue from the nose. The post-mortem examination showed extensive comminuted fracture of the base involving the cribriform plate of the ethmoid. The escape of brain tissue from the external auditory meatus necessitates a fracture involving the superior wall of the auditory canal, rupture of the tympanic membrane, and also of the dura and arachnoid.

Emphysema of the surrounding soft parts may take place when the line of fracture involves the frontal, ethmoidal, mastoid, or sphenoidal sinuses, and there is a sudden increase of intrasinal air pressure. This condition is seen most frequently after fracture of the frontal bone

involving the frontal sinus, very rarely after fracture involving the sphenoid bone and mastoid process. The emphysema may be circumscribed or it may be diffused. It is circumscribed when the overlying pericranium is not torn, and it may be diffuse when the pericranium is torn. At times the emphysema in fracture involving the frontal sinus may spread over the face, neck and chest; in fracture involving the mastoid region it may spread through the subaponeurotic space to the scalp and the cellular tissue of the neck. Its presence is readily determined by palpation, which reveals the peculiar crackling. It does not always appear immediately after injury. It may be made to increase by sneezing and forcible breathing efforts; the location of the primary swelling is generally indicative of the source of the air.

Involvement of cranial nerves may be the result of fractures of the base of the skull in which the line of fracture invades the canals through which the nerves make their exit from the skull, of laceration from a detached fragment of bone, or of compression by bone or blood clot (Fig. 152). The disturbance of nerve function may be due to laceration without fracture or to an injury at the central origin of the nerve, to general intracranial pressure. The involvement of nerves is apt to be immediate. A secondary form of paralysis may occur due to inflammatory changes, pyogenic in character, along the nerve trunk. This may be followed by grave results owing to infection at the base of the brain.

Injuries to nerves are frequently observed to occur in groups: the seventh, eighth and sixth; the fifth and third; the ninth, tenth and eleventh. From the character of the paralysis one can frequently determine the situation of the fracture. The facial and the abducens nerves are most frequently involved in fractures of the base.

Fractures of the anterior fossa may involve the *olfactory* nerve, as in fracture of the cribriform plate of the ethmoid. Disturbance of the *optic nerve* function is generally due to compression or crushing of nerves by a displaced clinoid process, rarely by fracture through the optic foramen, and occasionally by hemorrhage into sheath of nerve. Cullen reports 17 cases of compression of optic nerve from fragments near the optic foramen; Holder reports fracture of bones forming foramen in 53 of 86 cases of fracture in this region. Involvement of the *ophthalmic division* of the trifacial generally is the result of hemorrhage into sheath of nerve; of the *nasal nerve* suggests fracture of the cribriform plate; of the *supratrochlear* and *supraorbital branches* indicates fracture of vertical plate of frontal bone. The oculomotor and trochlear nerves are rarely injured, but may be affected through hemor-

c extravasation. Fracture of the middle fossa may involve the

ry and mandibular divisions of the trifacial but is very rarely

seen, requiring fracture of the walls of the foramen ovale and foramen rotundum. Involvement of the abducens points to fracture of the dorsum ephippii or to hemorrhagic infiltration of nerve sheaths. Schröder observed 58 cases of abducens paralysis in fracture of the base, 48 immediately following the injury. Irritation, paresis or palsy of the *facial* suggests fracture of petrous bone at the external or internal auditory meatus. When a nerve is cut across in the region of the ganglion the paralysis is permanent; in hemorrhagic infiltration of nerve sheaths, paralysis is not permanent. Involvement of the *auditory* occurs in fracture of the petrous bone extending from the internal ear through the labyrinth, tympanic cavity and roof of the auditory canal. It is generally accompanied by paralysis of the facial nerve and the

FIG. 152.

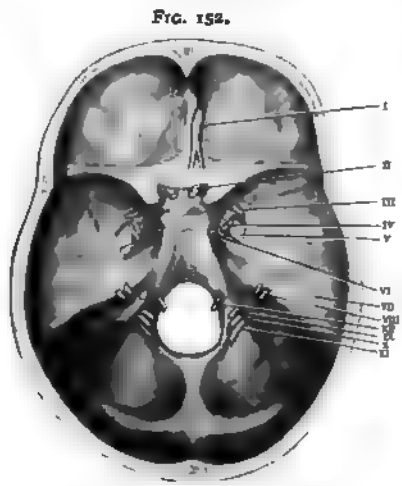

FIG. 153.

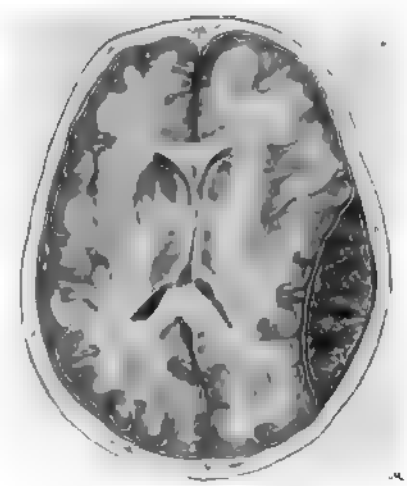

FIG. 152.—Shows position of cranial nerves and their liability to laceration in various fractures at the base of the skull. The numbers are the names of the nerves.

FIG. 153.—Cerebral pressure from an extradural clot from hemorrhage from the posterior branch of the middle meningeal artery. (After Rawling).

lesion is permanent. Kohler observed paralysis of the facial nerve 22 times in 48 cases of fracture of the base of the skull. Anna Heer records paralysis of the facial nerve 10 times in 11 cases of injury of cranial nerves, and paralysis of the acoustic nerve 9 times in 58 cases of fracture of the base of the skull.

Fractures of the posterior fossa may involve the facial and auditory nerve by fracture of the outer angle of the jugular foramen and petrous bone. The *glossopharyngeal, pneumogastric, and spinal accessory* nerves are seldom injured on account of the rarity of fracture at the jugular foramen and of the protection afforded by their dural sheaths. Intracranial injury to these nerves is either by bullets or by fracture of the jugular foramen. The *hypoglossal* is rarely injured intracranially.

A case is reported by Stierlein of paralysis of the hypoglossal with the pneumogastric nerve; and a case is recorded by von Bergmann of paralysis of the hypoglossal with the spinal accessory nerve.

Intracranial Hemorrhage.—Intracranial hemorrhage may arise from injury to the following vessels: the middle meningeal artery and its accompanying veins; the internal carotid artery; the sinuses of the brain, the principal of which are the superior longitudinal, the lateral, the transverse, the cavernous and the torcular Herophili, and the pia arachnoid vessels.

Injury to the middle meningeal artery may be produced by penetrating wounds, by depressed fractures of the cranium, by fractures extending from the base, and as a result of the various traumatisms which produce fracture of the skull. It occurs most frequently in conjunction with comminuted fractures of the temporal region. Cases have been reported in which an apparently trivial blow has resulted in laceration of the artery without injury to the bone.

From the injury to the artery hemorrhage takes place, and may be extradural (Fig. 153), subdural or both. As a rule the bleeding is extradural; but when the dura is torn, the extravasation may occur in both places at the same time. The blood escapes under a pressure of 80 to 100 mm. of mercury, and hemorrhage continues until the extravasation produces such intracranial pressure that the blood-pressure is equalized, until a thrombus forms, or until death occurs from cerebral compression. The extravasation may amount to from 4 to 8 ounces. Krönlein divides the resulting hæmatomas into diffused and circumscribed. The former may extend over one-half of the brain; the latter is subdivided into three varieties dependent upon the part of the artery injured (Fig. 154): anterior hæmatoma ("frontotemporal"), middle hæmatoma ("temperoparietal"), and posterior hæmatoma ("parieto-occipital"). The anterior is due to rupture of the anterior division of the anterior branch of the artery and is very rare, the middle is due to rupture of the trunk or both principal branches of the artery and is most common, and the posterior is due to rupture of the posterior principal branch of the artery and is very rare. Rawling states that hemorrhage from the middle meningeal artery was found in 20 per cent. of all the cases of fracture of the skull studied, and that in 45 per cent. of the cases the middle fossa was involved. Dwight found in 149 cases of fracture of the skull observed at autopsy that there was middle meningeal hemorrhage in 49 cases (29 per cent.), while Nichols reported the same condition in 11 cases out of 32 autopsies of fracture of the skull (34 per cent.).

The diagnosis of hemorrhage depends in a great measure upon her there is an external exit to the bleeding. If this exists the

diagnosis may readily be made. When, however, there is no external bleeding, there are cardinal symptoms on which our diagnosis may be based.

A free interval.—The interval between the time of injury and the onset of symptoms varies. It depends upon the extent of injury, the size of the vessel, the presence or absence of a depressed fracture of the vault, and the extent and severity of the cerebral concussion with its period of unconsciousness. There is, however, as a general rule a

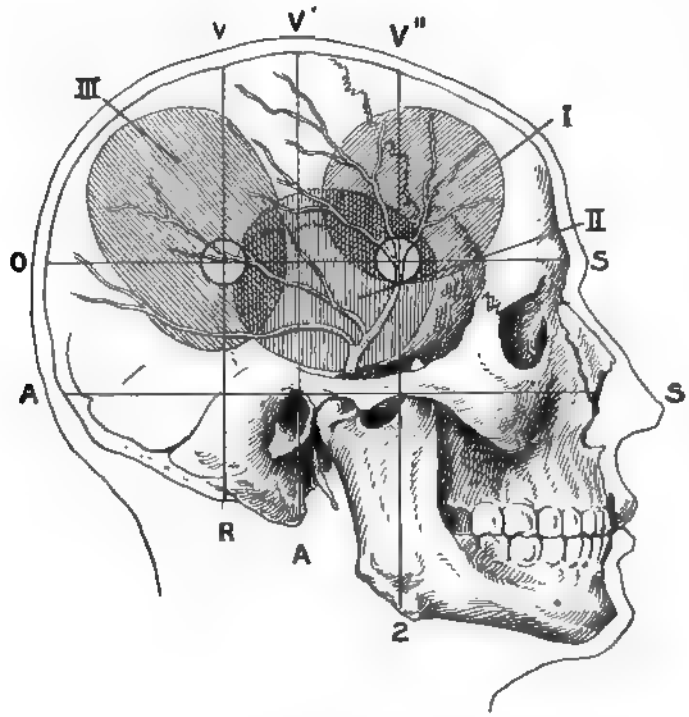

FIG. 154.—Krönlein's method for points of election for trephining in meningeal hemorrhage. The three usual areas of extravasation of blood are shown I, II, III. *S–O*, supra-orbital line; *S–A*, auriculo orbital line; *V–R*, vertical retromastoid line; *V'–A*, vertical auricular line, *V''* 2, vertical zygomatic line. The large circles show the points at which trephining should be performed to ligate the anterior and the posterior branches of the middle meningeal artery.

lucid interval following a primary period of unconsciousness before the unconsciousness of compression occurs.

Changes in the pulse.—Of great importance is the gradual change in the character and rate of the pulse. At first there is an increase of tension with slowing of the pulse-rate due to intracranial pressure, the vagus centre in the medulla being stimulated, so that the pulse may go as low as 30 to 40 per minute and the *blood-pressure* rise, reaching 200 to 250 mm. of mercury. Later, from long-continued and increasing pressure, the vagus centre becomes exhausted and the pulse changes

markedly in character, the blood-pressure drops, the pulse becomes irregular and rapid, and may reach 180 per minute.

Respiratory changes.—These consist in changes from the superficial respiration of cerebral concussion to the slow, labored, stertorous breathing of cerebral compression. This is due to pressure upon the respiratory centre in the medulla. Later the breathing becomes Cheyne-Stokes in character. Hemiplegia is dependent upon areas of pressure over the centres of the brain innervating the parts affected. The extent, character and part affected are entirely dependent upon the location, degree of hemorrhage, and region affected. The resulting symptoms of pressure may consist in twitchings, convulsions, spasticity, or paralysis of the muscles of the face, and of the upper and lower extremities of the side opposite to the lesion. For the various theories of collateral hemiplegia one should read the works of Jedderhouse, Oppenheim, and Artner.

Eye Changes.—Experimental compression has shown that at the beginning of pressure the pupil of the side affected is contracted, that with increase of pressure and during the stage of coma the pupils are dilated, the pupil of the side affected being greatly dilated and immobile. von Bergmann found in 70 cases of rupture of the middle meningeal artery with pupillary changes, that both pupils were widely dilated in 39 cases, both were markedly contracted in 7, there was dilatation of the pupil of the same side as the hemorrhage in 20, and dilatation of the pupil of the opposite side in 4. Gubler coincides with the same conclusions. Rawling, in a study of his cases, found that the pupils were equal in 46 per cent. of cases, that the pupils were contracted on the affected side in 36 per cent. of cases, and that they were dilated on the affected side in 18 per cent. of cases. He considers that the alterations in the size of the pupil are of doubtful significance in the diagnosis of hemorrhage from the middle meningeal artery, and that the so-called Hutchinson pupil, the pupil on the affected side being dilated, due to direct compression of the third nerve from extravasated blood, is rarely observed. Ophthalmoscopic examination showed, as a rule, the presence of œdema of the disk, and dilatation of the retinal veins with contraction of the arteries.

Hemorrhages from the intracranial sinuses are usually the result of penetrating wounds, or are due to extensive fracture with comminution. The hemorrhage may take place from the superior longitudinal or lateral sinus or the torcular Herophili at the vault and at the base from the cavernous sinus. The hemorrhage diffuses rapidly throughout the subdural space, but the symptoms of such venous bleeding with compression are not as definite as in compression resulting from middle meningeal hemorrhage. In the latter, symptoms of rapid compression are evident; these point to the nature of the lesion when as-

sociated with a proper site and nature of the traumatism, and with the character of external bleeding if any, especially if blood-corpuscles be present in the cerebrospinal fluid obtained by lumbar puncture.

Proarachnoid hemorrhage is more localized than that observed in lacerations of intracranial sinuses, which is generally diffuse subdural extravasation. A localized form of subdural hemorrhage, or hæmatocele, is the result of bleeding from torn proarachnoid vessels, due to localized laceration and contusion of the cortex. The vascular injury, while not severe enough to lead to direct symptoms of compression, causes vague, indefinite symptoms such as photophobia, headache, insomnia, irritability, and slight temperature changes; later, after a lucid interval of from a week to a month, symptoms of compression may occur. If the lesion involves the frontoparietal region, aphasia, nervous irritability, paralysis of the face, arm or leg centres may develop, and later, as the hemorrhage increases and cerebral compression becomes greater, paralysis and coma may result. This is a very important form of intracranial hemorrhage, and one that is not recognized as often as it should be. Patients with such head injury often present signs of cerebral irritation, which does not progress for a week or more, and after observation for that period they are considered convalescent. Shortly afterwards, however, death may occur from an increase in the size of the hemorrhage and the resultant compression.

Intracranial hemorrhage from the internal carotid artery is very rare. This artery may, however, be ruptured in severe fractures of the middle fossa, from penetrating wounds of the skull and bullet wounds. The rarity of intracranial injury of the cerebral portion of the carotid is possibly due to the amount of freedom of motion which is permitted it. When complete laceration of the artery occurs, the resulting hemorrhage is so severe that death is almost instantaneous on account of the accompanying lesions of the bone and the facility with which external bleeding occurs. In two cases reported by Rawling, death was instantaneous, while Marchant reports a case of a man injured by a sabre blow who lived sixteen days.

Injury to the Brain.—The most important complications of fracture of the skull are injuries to the brain itself. While all fractures of the skull are not accompanied by injury to the brain, and severe injury may exist without fracture, it can be well understood that severe fractures of the skull are generally accompanied by considerable cerebral injury. The various lesions affecting the brain are concussion, contusions, cerebral irritation, and compression. Of the above complications of fracture of the skull, compression due to hemorrhage and to depressed fracture have been considered. Concussion and contusion will be briefly alluded to, but for a more detailed consideration the reader is referred to special works dealing with these conditions.

Cerebral Concussion.—Many theories have been advanced to account for a train of cerebral symptoms, of which the chief one may be said to be a primary period of unconsciousness, which is generally designated as cerebral concussion. This may be described as an acute cerebral anæmia and sudden inhibition of the vasomotor centre leading to a sudden fall in blood-pressure. That concussion in this mild degree may exist without subcortical lesion or laceration of brain tissue or blood-vessels is evident, and that in some cases a fatal result may ensue from this alone is evident from the reports of autopsies at which no demonstrable lesion, microscopic or macroscopic, could be detected. Other cases may show focal areas of hemorrhage and contusion. As a result of the varying theories as to the pathological change present in this condition, two schools have been established:

That concussion may exist without extravasation or laceration of brain tissue (von Bergmann), and that concussion is represented pathologically by a condition of minute contusions scattered throughout the brain tissue and that molecular changes take place in the nerve cells (Kocher).

Symptoms of Concussion.—Sudden loss of consciousness accompanied by a fall of blood-pressure, subnormal temperature, general pallor, and moisture of the skin follow the receipt of the trauma. This state is followed by a stage of reaction, in which consciousness returns, the temperature rises, the face and the skin generally become hot, moist and suffused, the blood-pressure rises, and there results headache, restlessness, and even delirium. In the more severe cases the period of unconsciousness may be prolonged and the patient pass into a state of coma with all the evidences of severe intracranial pressure due to cerebral œdema. In this latter class of cases, the extracranial vessels are dilated, there is marked increase of cerebrospinal fluid and generalized cerebral œdema, more marked at the base. Rawling refers to a fatal case of concussion in which at operation the surface of the cortex was obscured by an œdematous pia-arachnoid one-quarter of an inch in depth. In the mild cases of concussion the pupils are equal in reaction to light, the patient may be aroused by supra-orbital pressure, the pulse is rapid (110–120), the blood-pressure lowered, and the temperature subnormal. There may be temporary loss of control of bladder and rectum, but the superficial and deep reflexes are not abolished. With reaction the patient slowly returns to consciousness, the pulse decreases in rate, the blood-pressure increases, the pupillary reflexes return, vomiting may take place, the temperature may go above normal, and there is a period of headache and symptoms pointing generally to increased intracranial tension, the result, in all probability, of cerebral œdema.

The Relationship of Temperature Changes to Head Injuries.—This subject has been of great interest for many years and many facts have been gathered on the subject by Broca, Banti, Guyon, Wolsham, Rawling, and others. The most important facts have been deduced by Rawling from the observation of over 300 head cases in which accurate records of temperature were made and the patients carefully observed during their illness. He presents the following deductions:

"(1) That, for a variable period of time after the injury, the temperature is always subnormal—sometimes so low that it cannot be registered. This is the period of shock (Fig. 155).

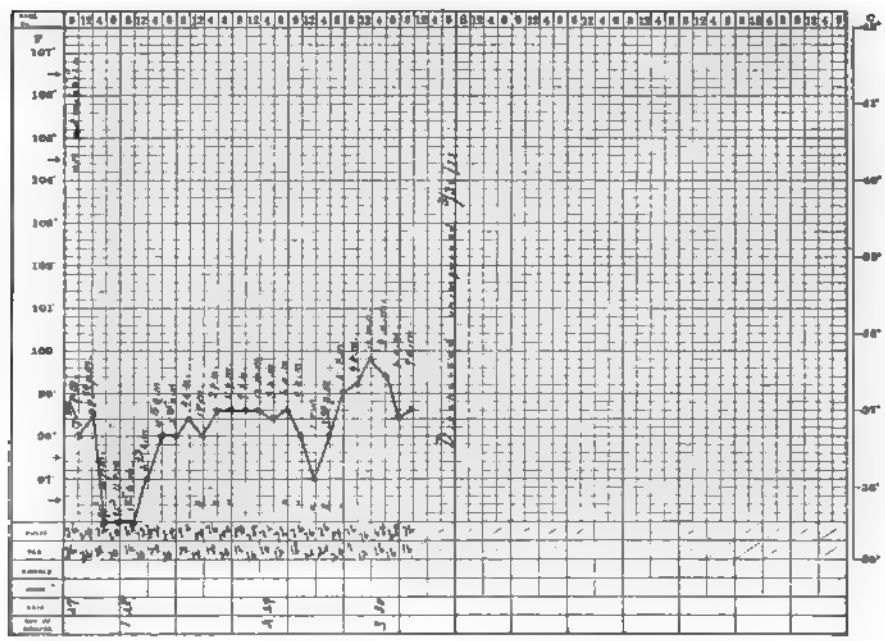

FIG. 155.—Temperature chart showing primary shock in fracture of base with subsequent rise to normal.

"(2) That the patient may die in this state of shock, but that, if he lives, reaction takes place and the temperature rises (Fig. 156).

"(3) That this rise in temperature is, in fatal cases, rapid and progressive. In one case the temperature rose 6° in seven hours, in another 8° in four hours. Death occurs when the temperature is at its highest. The thermometer may register as high as 106°, and even more when taken in the rectum (Fig. 157).

"(4) That the temperature may rise to a moderate height, and there become stationary. This is the crisis of the case. A subsequent fall in temperature generally indicates recovery, a further rise usually points to a fatal termination (Figs. 158 and 159).

"(5) That the rise of temperature is independent of any special osseous lesion, since similar changes are observed in fractures of the vault and in fractures of the base.

"(6) That lacerations of the brain are present in the majority of cases in which marked temperature changes are observed, but that the changes in temperature are totally independent of any special regional brain injury (Fig. 160)."

Cerebral contusion is the result of external violence applied to the skull and transmitted by the latter, producing varying degrees of injury to the brain substance, from mere bruising to laceration, and showing clinically all the evidences of cerebral irritation. The injury

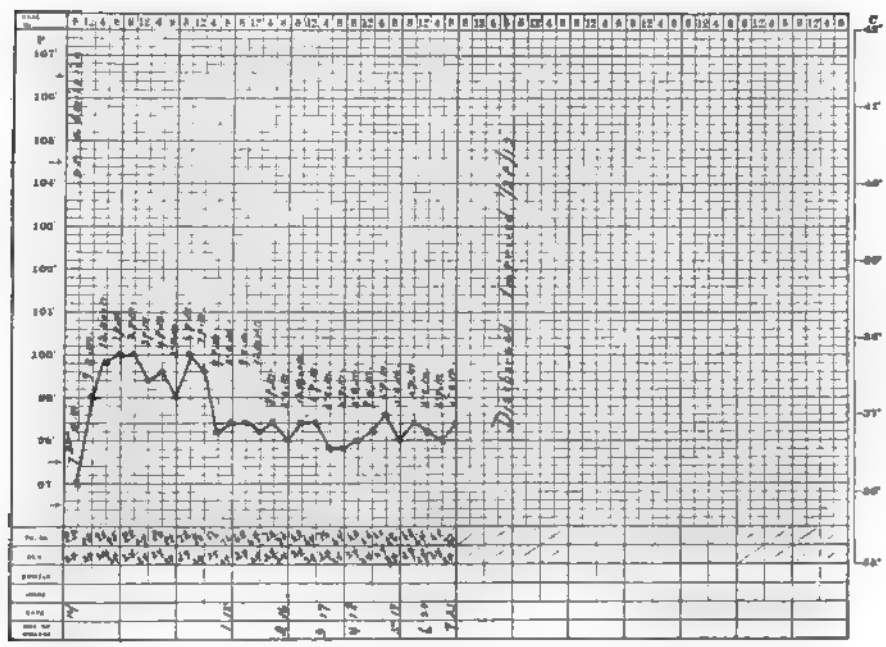

FIG. 156.—Temperature chart showing primary shock in fracture of base with subsequent rise and later return to normal.

may consist of laceration of the pia-arachnoid vessels, or of minute bruises, diffuse lacerations, or even macroscopic destruction of brain tissue. There may be only small areas of hemorrhage, but the injury may involve areas of the brain the size of an egg, or include one or more lobes. Contusions are most apt to involve the cortex, and that of the base more often than that of the vault. The pons, crura cerebri, cerebellum, and medulla are rarely involved. The most frequent sites of injury are the frontal and the temporosphenoidal regions. Krönlein considers that the accompanying contusion of the brain generally is due to the inflicting force and is most severe at the poles of the line

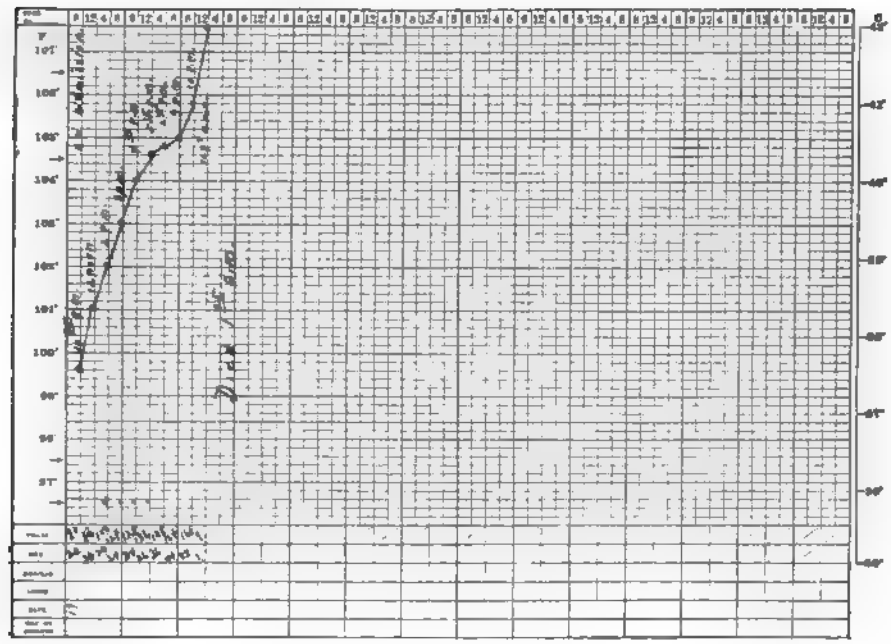

FIG. 157—Temperature chart showing rapid and progressive rise of temperature in fracture of the base, followed by death fourteen hours after admission.

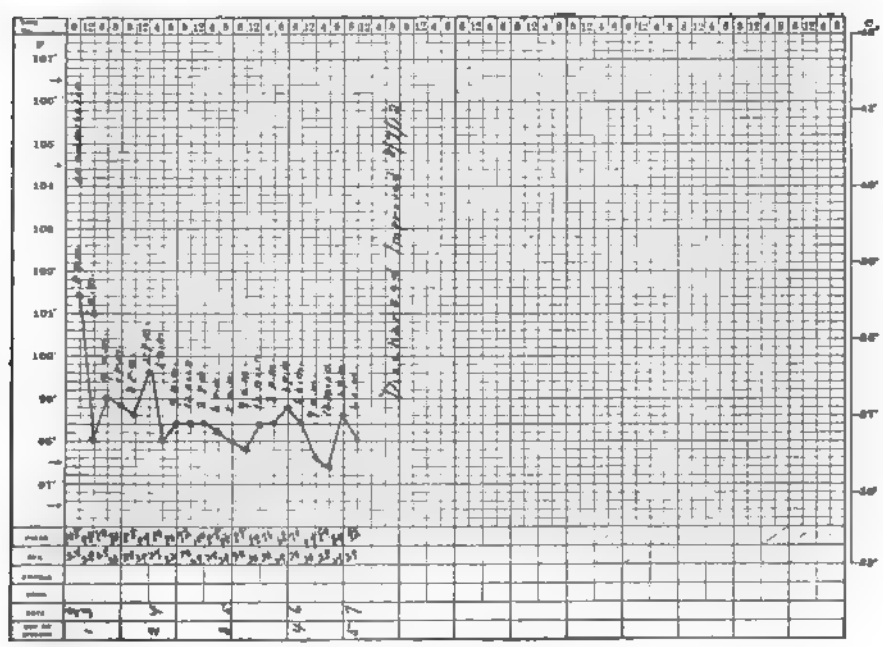

FIG. 158.—Chart showing moderate elevation of temperature, which remains stationary, followed by recovery.

of force. Hence it happens that in longitudinal fractures of the base the frontal lobe of the cerebrum and the lobes of the cerebellum are injured; in transverse fractures the two temporal lobes are contused; and in oblique breaks the frontal lobe of one hemisphere and the parietal lobe of the other hemisphere suffer damage. Deviations from this rule are due to the irregularities of the cranial base and of the brain substance itself. In localized comminuted fractures of the vault, the contused area is immediately beneath the area involved. Multiplicity of lesions are explained by the semi-fluid brain consistency and known hydrodynamic laws. In addition to the injury of the brain itself there is frequently laceration of the meninges with hemorrhage into, be-

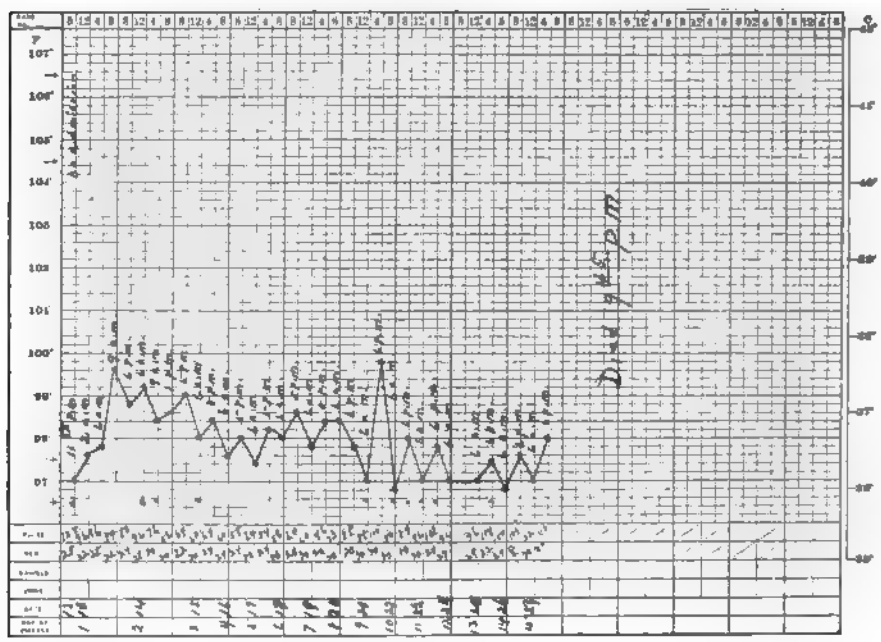

FIG. 159.—Temperature chart showing moderate rise followed by fall to below normal, ending fatally

tween, or outside the brain membranes. Hemorrhage may be supradural, subarachnoid, or subpial, depending upon the meninges lacerated and the degree and extent of laceration of the meningeal membrane's vessels.

Symptoms of Contusion.—Very frequently contusion of the brain is accompanied by symptoms of concussion and followed by those of compression so that perfect differentiation is impossible. Often the lesions are multiple and the clinical picture becomes obscure, because the symptoms of contusion indefinitely merge into those of compression from accompanying hemorrhage. On the other hand, there may be rather extensive lesions of the brain tissue and injury to the meninges

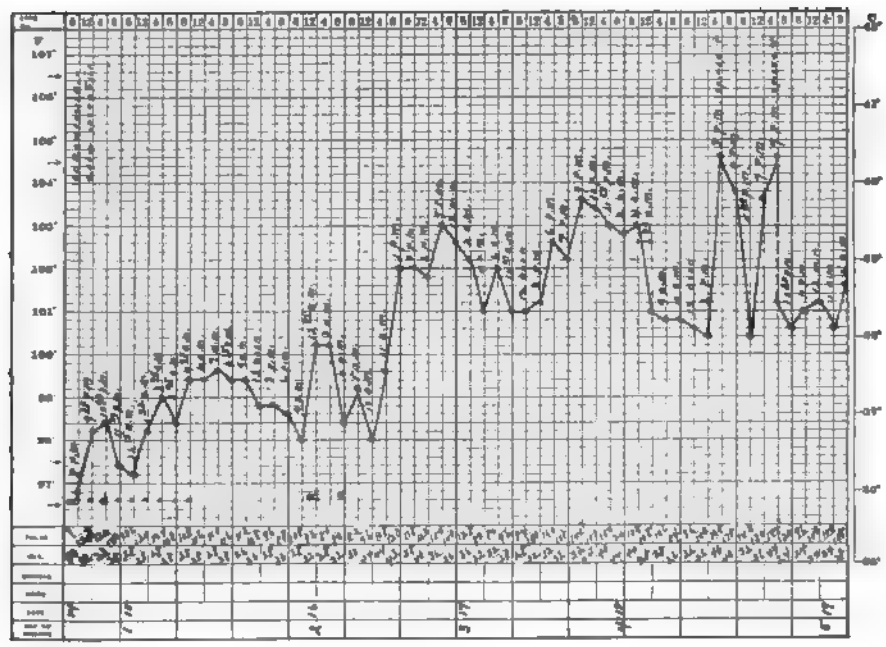

FIG. 160 *A*.

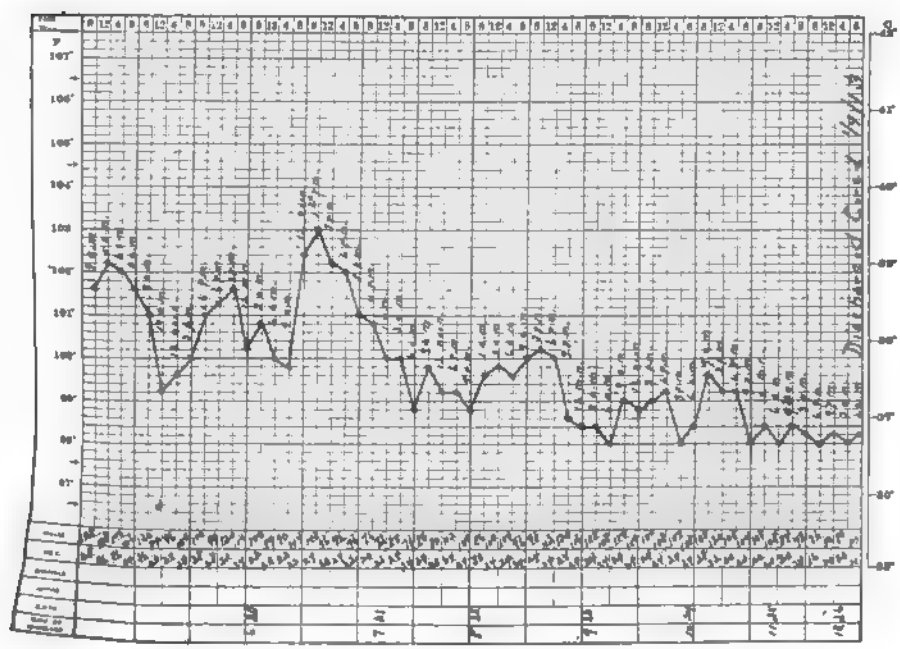

FIG. 160 *B*.

FIG. 160.—Temperature chart in a case of fracture of the base and marked laceration of the brain, showing variable temperature changes ending in ultimate recovery

without any definite localizing symptoms. Again, the symptoms of cerebral contusion may be similar to those of a purulent encephalitis or meningitis.

As a rule there is an initial stage of unconsciousness due to concussion, which may rapidly pass and give place to symptoms of cerebral irritation. The chief symptoms of the latter condition are a rapid increase of blood-pressure, shown by high tension, fairly rapid pulse, marked mental irritation, and occasionally violence requiring restraint. The patient resists efforts to draw open the eyes, pupillary and retinal examinations are impossible, headache is severe, restlessness is extreme, he generally lies on his side with legs drawn up, there may be involuntary passage of urine and fæces, the temperature is above normal, and the skin is hot and dry. Lumbar puncture generally shows blood in the cerebrospinal fluid. The symptoms of contusion are very pronounced, convalescence is prolonged, and patients complain for a long time of headache, mental irritability, and at times of depression. The mental character may alter and the end result may be traumatic neurasthenia, traumatic cephalalgia, or epilepsy.

The primary state of contusion may be followed by that of compression—acute when due to rapid hemorrhage, delayed when due to slow hemorrhage, to abscess, to subdural hæmatocele, or to tumor formation.

Diagnosis of Fracture of the Skull.—Fractures of the Vault. —In closed depressed fractures of the vault the diagnosis may be made from the character of the depression felt by palpation, the nature of the injury, and the symptoms of intracranial complication. Linear fractures may at times be recognized by the tenderness over the line of fracture or, as suggested by von Bergmann, by the changed percussion note, if there is any gaping of the fissures. Differentiation of depressed fracture from subaponeurotic extravasation should be carefully made by the peculiar feel to infiltrated area of the latter, which may be indented with moderate pressure. In open fractures, depressed and comminuted conditions may readily be recognized. Linear fractures may be diagnosed by oozing, which may be seen issuing between the walls of the fissure, by the slight unevenness of their edges, and by the presence of a fissure not at the site of a suture.

Fractures of the Base.—In fractures involving the base of the skull, the diagnosis is made more from the symptoms of the injury to the intracranial contents than upon any possible evidence obtained by observation of the fracture itself. Fractures of the base are determined by the evidences of hemorrhage, intra- and extracranial, the escape of cerebrospinal fluid, the escape of brain matter, localized or diffuse emphysema due to rupture of the air-containing sinuses, the involvement of cranial nerves, the development of cerebral œdema, purulent encephalitis and meningitis, the presence of blood in the cerebro-

spinal fluid obtained by lumbar puncture, and by the complicating symptoms of cerebral concussion, contusion, or compression. Radiography may be of extreme value, and a study of X-ray plates taken in two planes should be a routine practice in doubtful cases when possible.

Differential Diagnosis of Coma Due to Head Injury from Other Forms of Unconsciousness.—While it may be possible to readily diagnose traumatic coma from a history of the accident and the various evidences of injury present, the surgeon at times is unable to obtain any history or to notice at first glance evidence of injury. In these cases the coma due to concussion, contusion, and compression should be differentiated from that which occurs in alcoholism, in apoplexy, in opium poisoning, in uræmia, in epilepsy, and in diabetes. A correct diagnosis in many cases can be made only after a thorough examination of the patient. This examination should begin at the head and include the entire body. In fracture of the skull there may be evidence of external injury to the vault, in the frontal, temporoparietal, or occipital regions, or at the level of the base of the brain. Bleeding from the nose, mouth, or ears, or the escape of cerebrospinal fluid or brain tissue will clear up the diagnosis. The presence of blood in the cerebrospinal fluid obtained by lumbar puncture is also suggestive of fracture at the base combined with intracranial hemorrhage. Palsies from intracranial injury to nerves are suggestive of fracture at the base. There may, of course, be prior disease of the viscera, leading to unconsciousness, in addition to the injury which is suspected to be its cause. Lumbar puncture should not be recklessly employed.

The presence of old scars or fresh injuries to the tongue is suggestive of epilepsy. In uræmia there is a sweetish odor to the breath, in diabetes the odor is typical of acetone, and in alcoholism the peculiar stale odor of liquor is noticeable. In apoplexy, compression, and trauma there may be facial palsies. In opium poisoning, diabetes and concussion the face is pale, peaceful, and the breathing quiet. In compression, apoplexy, uræmia and alcoholism the face is congested and the breathing is stertorous. In apoplexy and injury there may be unilateral paralysis of the extremities, limited to upper or lower or both, combined with exaggerated reflexes, while in alcoholism resistance to movement is marked. Convulsions suggest uræmia, epilepsy, or injury. Examination of the urine with the presence of albuminuria and casts points to uræmia, while in diabetes the urine contains sugar and possibly acetone, diacetic and β-oxybutyric acids. Examination of the eyes is very important. The presence of paralysis of ocular muscles points to injury or apoplexy, while the presence of subconjunctival and palpebral hemorrhage points to injury. In uncomplicated fractures of the base there are no pupillary or disk changes. When accompanied by concussion the pupils are equal, dilated, and

react to light; in contusion the pupils may be unequal, dilated, or contracted, and generally fail to react to light; but in cerebral compression they may be equal or unequal, dilated, and do not react to light. In apoplexy the pupils are generally unequal, dilated, and do not react to light, and in hemorrhage into the pons the pupils are pin-pointed. In diabetes and epilepsy the pupils are equal, sluggish, and react to light. In opium poisoning the pupils are contracted, equal, and do not react to light. In uræmia the pupils are dilated and react to light slowly. In alcoholism the pupils are generally normal; but in extreme stages of alcoholism they are usually dilated and fail to react to light. Examination of the fundus in these varying conditions may show distinctive changes, such as retinal hemorrhage in trauma and in arteriosclerosis, the characteristics of optic neuritis in uræmia and diabetes, and choked disk in pressure from cerebral abscess or intracranial tumor.

Examination of the pulse will give valuable information. The presence of atheromatous arteries will suggest apoplexy; a high tension, slow pulse with relatively high blood-pressure, will suggest uræmia, compression, and apoplexy. The presence of a very slow full pulse may be indicative of alcoholism, although the pulse in this latter condition is variable. In concussion and contusion of the brain the pulse may be rapid, weak, and accompanied by low blood-pressure.

The temperature shows marked variation in these conditions. In uræmia, concussion, opium poisoning, and epilepsy the temperature is normal or subnormal. In apoplexy, contusion, compression, and alcoholism the temperature is generally above normal, while in hemorrhage into the pons there is hyperpyrexia as a rule.

Prognosis.—Here again the question of results is dependent upon the accompanying lesion to the intracranial structure rather than upon the degree of injury to the cranium itself. Extensive fracture of the cranium unaccompanied by lesion of the intracranial contents may have a very favorable prognosis, whereas a small fissured fracture accompanying a small lesion of the pons or medulla is liable to have a sudden fatal termination. The two accompanying conditions most frequently seen in fractures of the skull that greatly determine the prognosis are infection and hemorrhage. The infections through fracture of the skull generally act through open wounds of the scalp and are usually streptococcic, staphylococcic, or tetanic in nature. Infections reaching the cranial contents may gain entrance through the accessory sinuses of the nose, the nasopharynx or external auditory meatus, and generally pneumococcic in character. Fractures of the base are more serious complications than fractures at the vault, on account of the nature of the violence causing basal fractures, the mechanism of their production, and the greater liability to injury of

the important structures situated at the base of the brain. Among secondary complications may be mentioned meningitis, abscess, and localized hæmatoma. An injury apparently insignificant may prove to be fatal on account of the resulting meningitis or abscess.

Hemorrhage is probably the most important complication of fractures. As stated above, this may be small in amount, but if it takes place in the pons or medulla death occurs very rapidly. In other cases the hemorrhage may be progressive until symptoms of compression arise and is followed by death unless operative relief is given. Intracranial hemorrhage taking place in the presence of laceration of the dura with free exit from the brain-case to the outside does not, as a rule, produce death from pressure of the bleeding. Minute hemorrhages accompanied by marked œdema may cause compression, coma, and death.

In depressed, comminuted fractures of the vault, death may occur on account of compression due to depression of fragments and hemorrhage, but depressed fragments may be present and cause no symptoms at all.

Battle, from a study of 168 cases of fracture of the cranium, places the mortality at 32 per cent. Crandon and Wilson, from a series of 530 cases, give a mortality of 44 per cent. Rawling states that of those fractures purely or mainly basic observed by him, 116 recovered and 89 died, a mortality of 44 per cent. In a primary fracture of the vault Rawling gives the following statistics based on a study of 88 cases observed at St. Bartholomew's Hospital from 1900 to 1906:

Under the age of five	8 lived and 2 died.	Mortality, 20 per cent.
Under the age of ten	2 lived and 3 died.	Mortality, 60 per cent.
Under the age of fifteen	6 lived and 0 died.	Mortality, 0 per cent.
Under the age of twenty	10 lived and 3 died.	Mortality, 23 per cent.
Under the age of thirty	9 lived and 1 died.	Mortality, 10 per cent.
Under the age of forty	16 lived and 9 died.	Mortality, 36 per cent.
Under the age of fifty	3 lived and 7 died.	Mortality, 70 per cent.
Under the age of sixty	2 lived and 1 died.	Mortality, 33 per cent.
Over the age of sixty	3 lived and 3 died.	Mortality, 50 per cent.
	59 lived and 29 died.	Mortality, 37 per cent.

The mortality also varies according to the fossa involved in fractures of the base of the skull. Rawling considered that fracture of the middle fossa presents the greatest dangers. This fossa is involved with great frequency in fractures of the base; and the injuries are dangerous on account of the avenues of possible infection leading into it from the nasopharynx and the ear. The hemorrhages which may occur in fracture involving this fossa are from the middle meningeal and internal carotid arteries and cavernous sinus and are always grave. Leonard Hill, however, considers that involvement of the posterior

fossa is the most dangerous on account of the fact that the main vital centres are situated in the region of the fourth ventricle and that any increase in intracranial pressure exerts its effect most rapidly when the lesion is situated beneath the tentorium cerebelli.

Burkhard records 42 recoveries in 43 cases of uncomplicated fractures of the skull, and Wagner records only two deaths among 83 recent compound fractures of the skull. von Bergmann considers that patients suffering with fracture of the skull who are not killed instantly are in the greatest degree of danger during the first twenty-four to forty-eight hours. Wagner records 23 cases surviving this period in which only one death occurred.

In regard to prognosis, Rawling considers that all cases of head injury may be grouped into four classes, dependent upon the temperature changes as follows (Fig. 155–160).

"*Group* 1. The temperature, at first subnormal, undergoes a rapid and progressive rise. Prognosis most unfavorable.

"*Group* 2. The temperature, at first subnormal, rises gradually to 101° or 102° and there 'marks time.' This hesitancy marks the crisis of the case, further elevation indicating a fatal result, whilst a fall offers every hope of recovery.

"*Group* 3. The temperature, at first subnormal, rises to normal and remains at that level. Prognosis very favorable.

"*Group* 4. The temperature, at first subnormal, remains subnormal. The condition of shock persists, and the prognosis is most unfavorable."

Not only does Rawling consider the temperature chart as of invaluable help in the prognosis, but it is also a guide in the treatment of the case. This will be referred to later under treatment.

Eguchi states that from 1.3 to 4.7 per cent. of all skull injuries admitted to the reserve hospitals of Japan during the Russo-Japanese War were followed by traumatic epilepsy. In these, injuries to the bone and dura mater produced irritation of the brain. The shortest period from the day of injury to the beginning of the epilepsy was 3 days; the longest was 442 days, the average 161 days. Operation gave good results in Eguchi's cases. A cure was obtained in 11 cases, or 90.9 per cent., and no results in 1 case, or 9.1 per cent. Death followed operation in this case from the rupture of an aneurism.

A. C. Burnham reports the following statistics based upon the observation of thirty-five cases of compound fractures of the base of the skull treated at the Presbyterian Hospital, New York. Cases which were surely basal fractures, but in which there was some doubt as to the diagnosis of compound fracture, were not included in this report. Of these 35 patients 14 died and 21 recovered, a general mortality of 40 per cent. Six patients died during the first forty-eight

hours, all in primary shock as a result of the injury. Eight patients died after the third and before the fourteenth day, after having partially or wholly recovered from the initial shock of the accident. Of these 8 patients 5 died of meningitis. The causes of death and the day on which it occurred in the fatal cases are as follows: 5 died of meningitis—on the fourth 2, on the sixth 2, and 1 on the thirteenth day, respectively. Two patients died of bronchopneumonia on the fourth day. One patient died on the tenth day after secondary hemorrhage and operation. It can readily be seen from the above figures that even in those patients surviving from the initial shock following compound fracture of the base of the skull, the mortality (in this series 25.5 per cent.) is high.

Treatment.—The treatment of fractures of the cranium must depend upon whether the fracture is of the vault or of the base; closed or open; depressed, comminuted, fissured, or punctured; associated or not with concussion, contusion, intracranial hemorrhage, or œdema; or is open to infection at the base through the nose, pharynx, or ear. When the fracture is of the vault or base and unaccompanied by any intracranial lesions, the rules of treatment are very simple. When complications exist the treatment depends upon the character, severity, and degree of injury to intracranial contents and the avenues of possible infection. In fracture of the vault the indications for operative intervention are usually distinct and clear-cut. It is generally performed for depression of fragment or hemorrhage from the middle meningeal artery or longitudinal sinus; in fractures of the base our indications for operation are not dependent so much upon the injury to the cranium itself, but rather upon critical intracranial complications.

General Lines of Treatment.—In all closed fractures of the vault or base one should adopt some rational form of general treatment. Operation should only be considered when there is some well-defined indication for the operative procedure or a degree of uncertainty making exploratory incision wise. Then it should be performed with the hope of giving the patient a chance for immediate recovery or as a means of preventing remote effects of head injuries, such as traumatic neurasthenia, chronic cephalalgia, and epilepsy.

The surgeon should be guided by the general condition of the patient, the character of the injury, the location of the fracture, the presence or absence of intracranial complications, the blood-pressure, the character of the pulse, the respiration, and the degree and depth of coma present.

The patient should be placed in bed, in a room alone if possible; and have a competent and intelligent attendant to record the temperature, pulse and respiration every hour, to observe changes in the pa-

tient's condition, and to note the development of consciousness, coma, convulsions, paralyses, etc. The head should be shaved, an ice-cap applied and the patient given a cathartic, if possible; if he is unconscious, the lower bowel should be emptied by a cleansing enema and the bladder evacuated by catheter. In cases in which there is a possibility of infection of the meninges occurring, the patient should be given 10–20 grains of hexamethylenamine three times a day. This drug should be continued for a period of three to four weeks, or until all danger of meningeal infection has passed. This medication follows the advice of Crowe and Cushing as a prophylactic measure against the development of infection of the meninges. They believe that hexamethylenamine given by the mouth appears in the cerebrospinal fluid in from thirty minutes to one hour after ingestion of the drug, and that its use exercises a decidedly inhibitory effect on the development and extension of meningeal infections.

When the temperature remains subnormal for a time, the patient should lie with the head low and be surrounded with hot-water bottles and covered with blankets. In severe cases of shock, with subnormal temperature and low blood-pressure, it may be advisable to bandage the extremities and overcome the vasomotor depression by hypodermic injection of atropin, 1/100 grain; by the intravenous injection of normal saline solution, or by stimulating enemata such as the following: salt solution 2 ounces, black coffee 2 ounces, brandy 1 ounce, tincture of digitalis 1 drachm, to be repeated in two hours if necessary. This treatment is advisable only in those extreme cases in which marked shock is present, because there is considerable risk in over-stimulation should there be laceration of intracranial vessels. It must be remembered, however, that patients in marked shock will die, and that very quickly, unless stimulated.

In cases where the shock has been overcome and there is a progressive rise in temperature, and in those in which there is a progressive rise in temperature from the beginning, not due to active stimulation, and in which all the symptoms point to compression without any localizing signs, the treatment should be entirely different. Then, instead of stimulating the patient, the surgeon's efforts should be directed toward reducing intracranial pressure. There are several ways of reducing this pressure: venesection, lumbar puncture, and decompression operations on the skull in the cerebellar or intermusculotemporal regions.

Venesection.—The treatment of intracranial compression due to hemorrhage by venesection has advocates and opponents. Its use as a means of reducing arterial pressure is therefore not established. von Bergmann, Hill, and Rawling consider that it is of great value,

while Falkenheim, Naunyn, and Cushing are not in favor of it, except early in a very few selected cases, in which there is an abundant reserve on the part of the vasomotor centre. Our experience has shown that it has been of use when employed in early cases, but that in late cases in which the vasomotor centre is exhausted it is useless. The blood may be withdrawn from any of the superficial veins of the body, the safest and most readily accessible being the median basilic, external jugular, and the long saphenous veins. About ten to thirty ounces may be withdrawn under aseptic precautions. The quantity should be governed by the fall of blood-pressure to nearly normal.

LUMBAR PUNCTURE.—As a diagnostic procedure, lumbar puncture probably has its use; but as a means of relieving intracranial pressure it is doubtful whether it does good. It may lead to dangerous and fatal results by intracranial pressure forcing the medulla and the edge of the cerebellum into the foramen magnum, after the support of the cerebrospinal fluid has been removed by lumbar puncture. However, the procedure has many advocates. Quinn records seven cases of fracture of the skull "cured" by means of lumbar puncture. In one of the cases the procedure was performed eight times.

DECOMPRESSION.—Cerebellar decompression is rarely a justifiable procedure in cases of diffuse intracranial injuries, and the good results to be obtained by this procedure are questionable. The intermusculotemporal decompression operation advised by Cushing has been followed by brilliant results, especially in the hands of its originator. The advantages claimed for this procedure are that it is done in the middle fossa—a region where most lesions at the base occur—exposure of the middle meningeal artery is obtained, approach to the region occupied by the temporosphenoidal lobe—where most frequent contusions of the brain occur—is gained, dependent drainage is obtained with ease, and the drainage so obtained occurs through the split temporal muscle rather than through the scalp alone. This position secures good drainage and is not likely to be followed by hernia cerebri.

Fractures of the Vault.—In closed fissured fractures of the vault without intracranial injury the treatment should consist of rest and observation. It is difficult to determine that such a fracture is present. Most fractures of the vault are, however, either depressed, comminuted or compound, and here the treatment will differ. Operative intervention is advisable in all depressed fractures, punctured fractures, fractures complicated by intracranial hemorrhage, and as an exploratory measure when the condition of the bone is uncertain. Fractures associated with only a mild degree of concussion require no active treatment beyond rest in bed and treating the symptoms of concussion as they arise, unless there is reason, from the character of the trauma, to

think that the inner table may be splintered. When there is a marked degree of concussion present, more active measures are required. With subnormal temperature, stimulation is indicated until reaction occurs. When associated with suspected cerebral contusion, the patient should be kept in a darkened room, and sedatives are required. In addition, some moderate form of restraint may be wise. An ice-cap should be applied to the head, and morphine and atropine are indicated until the restlessness disappears. As cerebral contusion is associated with more or less laceration of the brain substance, the patient should be under a long period of observation and restrained from too great activity, physical and mental.

In depressed or comminuted fracture of the vault, with or without symptoms of compression, and in obscure fissured fracture, operative interference is advisable. By this means alone is one able to elevate depressed fragments, determine the presence of depression of fragments of the inner table alone, and also prevent many of the remote effects of brain injury.

Operative Procedures for Fracture of the Vault.—The scalp should be shaved, thoroughly washed with soap and water, alcohol and ether. A rubber band or scalp tourniquet is applied around the head above the ears and a scalp flap made according to the location and extent of comminution or depression of fragments. The pericranium is stripped away from the involved area, and often it is possible with a suitable bone elevator to lift up depressed or comminuted fragments. If this is not possible, a trephine opening may be made at the edge of depression and the fragments elevated after the removal of a button of bone (Figs. 161-164). The centre pin of the trephine should be placed on solid bone, and the crown of the trephine should overlap the margin of the fracture so as to permit the elevator to be used. Exposure of the dura should be carefully made, lacerations should be carefully investigated, and examination made for the presence of fragments in the brain substance and for extra- or subdural hemorrhage. The dura should either be incised or the laceration in the dura, if one is present, should be enlarged, when the brain is believed to be damaged. Otherwise the dura need not be disturbed. Detached bone fragments should not be replaced unless the brain is thought to be uninjured and the wound is sterile. After trephining or other operation on the the fragments may at times be replaced, if to get a bony closure of the opening in- ilaginous membrane which otherwise is s a thin shaving of bone may be cut and laid over the hole like a lid. These ondary operation if postponement is

considered wiser than immediate plastic closure. After all fragments in the brain substance have been removed and hemorrhage controlled,

FIG. 161.—Method of trephining with the Hudson instruments. After exposure of the site of fracture the skull may be opened at the site of depression.

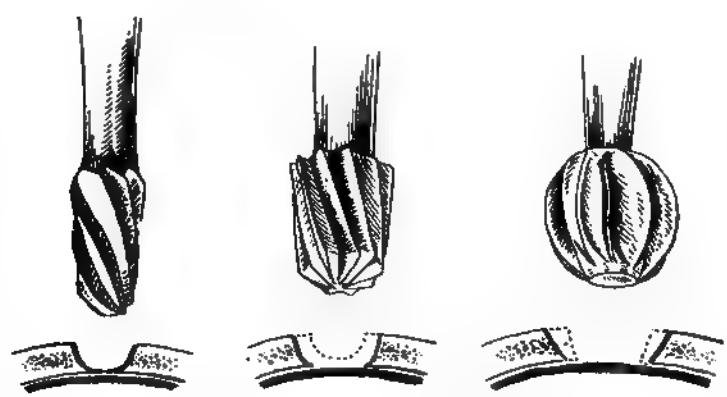

FIG. 162.—Hudson's trephine bits, showing the use of the spiral perforator, the spiral follower, and the enlarging burr. (After Rawling.)

the wound of the dura should be closed with interrupted sutures of fine catgut, and the skin flap closed with interrupted sutures of silkworm gut without drainage.



In open compound fractures the scalp should be shaved, thoroughly scrubbed with soap and water, alcohol and ether. The edges of the wound should then be trimmed with a pair of scissors and the entire wound irrigated with a 2 per cent solution of iodine in alcohol. The wound should then be enlarged for inspection of the seat of fracture, and the same general lines of treatment followed as in simple fractures. Drainage will depend upon the character of the wound, the general condition of the patient, and the degree of contamination. When in doubt do not drain.

Fractures of the Base of the Skull.—In simple fractures of the

FIG. 165.—Showing method of exposure of anterior and posterior branches of the middle meningeal artery at the points of election. (Modified after Rawling.)

base of the skull without intracranial complications, the treatment should be symptomatic. The prognosis and treatment depend entirely upon the kind and degree of the accompanying lesions. The same general principles given above should be carried out. Of especial gravity are hemorrhage, with the escape of cerebrospinal fluid or brain tissue from the nose, mouth, or ear, the possibility of infection being very great; and intracranial hemorrhage producing compression of the brain. In hemorrhage from the nose, mouth, or ears, or when there is discharge of cerebrospinal fluid from these orifices, syringing of the nose, mouth, or ears is strongly contraindicated. The nose or ears should be kept clean by means of swab of cotton soaked in boric acid

solution. Under no condition should these cavities be packed with gauze. The syringing is liable to force organisms from these cavities to the meninges and thereby produce infection, and packing of these orifices is unwise because the escape of blood lessens the degree of compression of the brain, especially when hemorrhage is profuse.

Intracranial Hemorrhage.—As middle meningeal hemorrhage usually produces compression of the brain and unless relieved causes eventually coma and death, the expectant form of treatment is hazardous and should not be followed. So soon as symptoms of this form of hemorrhage are presented, immediate operation is indicated. Various methods of approach have been suggested. Perhaps the one most universally followed is that of Krönlein. The principal thing to be borne in mind is the location of the middle meningeal artery. The main artery runs across the middle of the temporal fossa; it divides into its branches at the pterion, which is about two fingers' breadth above the zygoma and a thumb's breadth behind the vertical (sphenofrontal) process of the malar bone (Vogt's rule). Vogt advises placing the point of the trephine at the insertion of these two points. Krönlein describes an anterior and a posterior point of election for trephining as follows (Fig. 154): A line is drawn through the supraorbital ridge backward, parallel with the horizontal line of the skull, which is a line through the external auditory opening and inferior orbital ridge. Both points of election for trephining should be on this line (Fig. 165), the anterior one 3 or 4 cm. behind the zygomatic process of the frontal bone, the posterior one at the intersection of the given line with a vertical line passing immediately behind the mastoid process. Circumscribed hæmatoma of the fronto-temporal and temporoparietal regions may be reached through the anterior opening and the parieto-occipital variety of blood clot through the posterior opening. Krause advises exploration through an osteoplastic flap similar to the one he uses for the Gasserian ganglion excision. Cushing recommends an approach by means of the intermusculotemporal operation. Whichever method of approach is used, the opening should be enlarged (Fig. 166) with craniectomy forceps, after removing the button of bone, until sufficient exposure is obtained. The source of the extravasation can readily be determined by removal of the clot with a flat spoon and irrigation of the cavity with salt solution. The bleeding point may be secured and the hemorrhage checked by one of the following methods: by ligature, on both sides of the bleeding point; by torsion of the vessel; by gauze plugging; by occlusion of the artery by crushing the bony groove in which the vessel lies; by plugging the foramen spinosum with a bone or wooden plugs or paraffin; by ligature of the common or external carotid arteries.

Cushing considers that 90 per cent. of cases of meningeal hemorrhage prove fatal, if unrelieved surgically, 60 per cent. of them dying within the first twenty-four hours. Of the cases operated upon 67 per cent. recovered. Wiesmann states that of 143 cases treated under the expectant treatment, 131 died and 12 recovered. Of 167 fatal cases not less than 60, more than one-third, died during the first twenty-four hours.

The cause of death in those dying within twenty-four hours is probably paralysis of the heart and respiration from pressure on their centres in the medulla. In patients living several days or weeks and then dying, the cause of death is probably a generalized œdema.

FIG. 166.—Showing method of enlarging trephining openings at points of election to reach the anterior and posterior branches of the middle meningeal artery. (Modified after Rawling.)

von Bergmann reports 110 operative cases with 74 recoveries and 36 deaths, a mortality of 32.27 per cent.; Blake, 42 cases submitted to operation with only 3 deaths, and Duchain, 27 operative cases with only 6 deaths.

Hemorrhage from rupture of intracranial sinuses demands immediate operation. As a general rule these injuries are associated with either open, depressed, or punctured fractures of the skull, and a diffuse subdural hemorrhage results. In such instances, the wound, if the fracture is compound, should be enlarged under thorough asepsis; and if a closed fracture is present the method of procedure should be to expose the bone by an incision. Depressed fragments should be

FIG. 167.—Trephine opening for subdural hemorrhage. Opening has been made with a Hudson trephine. (Modified after Rawling.)

FIG. 168.—Enlargement of trephine opening with rongeur forceps and incision of dura. (Modified after Rawling.)

FIG. 169.—After washing out subdural clot, a rubber tube drain is inserted and the dura closed by interrupted sutures about the drain. The end of the latter is carried through the temporal fascia and skin. (Modified after Rawling)

FIG. 170.—Shows suture of the temporal muscle by interrupted sutures of catgut, and partial closure of the temporal fascia. The fascia is sutured and the skin closed with interrupted sutures. (Modified after Rawling)

elevated, detached fragments removed, the opening in the cranium enlarged if necessary with craniectomy forceps, so that sufficient exposure of the involved sinus be obtained for working purposes. If possible, the laceration of the sinus is to be closed by interrupted sutures of fine silk, or by a lateral ligature; or both of the bleeding ends of the sinus should be ligated with silk. If this is impossible, the hemorrhage may generally be controlled by compressing the sinus with sterile gauze packing; the wound in the scalp is to be closed except at the point of drainage. Luys reports 42 cases of injury to the sinuses, of which 20 were followed by good results from operative interference.

Hemorrhage from the cranial portion of the internal carotid artery is followed by death so quickly that operative intervention is generally impossible.

In subdural localized hemorrhage, which is generally from injury to the pia-arachnoid vessels and laceration of the cortex, the symptoms of hemorrhage and the development of pressure symptoms are delayed from several days to a week or more. Upon the development of localizing symptoms of pressure, operative interference is demanded. Under aseptic precautions, and with a scalp tourniquet, a flap is raised, the cranium trephined, and the dura exposed. The membrane will be found to be blue, nonpulsatile, and bulging. The dura should be incised, the clot removed with a spoon, and the cavity cleansed by irrigation with warm normal salt solution. Afterwards the opening in the dura should be closed with catgut or silk suture, excepting at the lower portion, where a rubber tissue drain should be placed and the scalp wound sutured, except at the point of drainage. The drain should be removed at the end of forty-eight hours (Figs. 167–170).

Bowen, to whom we are indebted for a most complete monograph on this subject, reports 72 cases, as follows:

Class A.—Subdural hemorrhage without serious injury to brain: 36 cases; 22 recovered after operation; 14 died—11 without and 3 after operation.

Class B.—Subdural hemorrhage with serious brain injury: 36 cases; 6 recovered after operation; 30 died—10 without and 20 after operation.

Summary of Treatment of Cranial Fractures

Closed fissured fractures.....	1. No evident depression, no brain symptoms.....	No operation
	2. No evident depression, with brain symptoms.....	Incise scalp and open skull
	3. With evident depression, no brain symptoms.....	Incise and probably open skull
	4. With evident depression, with brain symptoms.....	Incise and open skull

Closed comminuted fractures.	5. No evident depression, no brain symptoms	Incise scalp and probably open skull
	6. No evident depression, with brain symptoms	Incise and open skull
	7. With evident depression, no brain symptoms	Incise and open skull
	8. With evident depression, with brain symptoms	Incise and open skull
Open fissured fractures	9. No evident depression, no brain symptoms	No operation but treat wound
	10. No evident depression, with brain symptoms	Open skull
	11. With evident depression, no brain symptoms	Open skull
	12. With evident depression, with brain symptoms	Open skull
Open comminuted fractures.	13. No evident depression, no brain symptoms	Probably open skull
	14. No evident depression, with brain symptoms	Open skull
	15. With evident depression, no brain symptoms	Open skull
	16. With evident depression, with brain symptoms	Open skull
Punctured and gunshot fractures	17. In all cases	Open skull

Treat all cases as incipient encephalitis, and if primary operation decided upon as necessary, do not delay more than a few hours.

CHAPTER IV

FRACTURES OF THE BONES OF THE FACE

Anatomy.—Anatomically the bones of the face comprise the two nasal bones, the two lachrymal bones, one vomer, the two inferior turbinated bones, the two superior maxillæ, the two palate bones, the two malar, one inferior maxilla, and one hyoid bone. On account of the close relation with each other individual fractures of facial bones are generally limited to the nasal, the superior maxilla, the malar, and the inferior maxilla. Fractures involving the other facial bones are either in conjunction with the bones of the cranium, or are associated with fractures of the nasal or superior maxilla.

Fractures of the bones of the face are usually caused by severe direct violence and the result is generally fracture of several bones. This is particularly seen in fractures of the nasal bones and of the

FIG. 171.

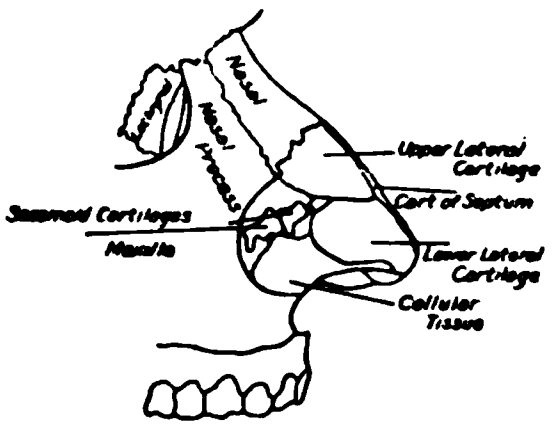

FIG. 172.

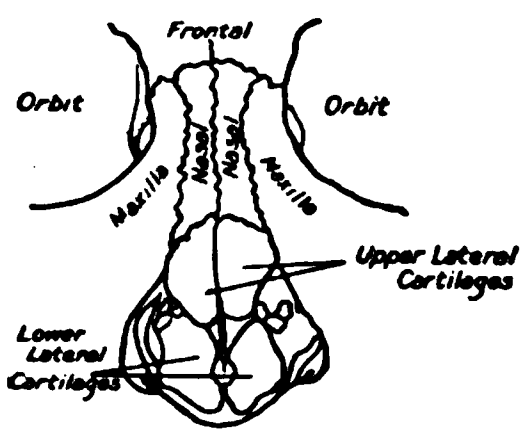

FIG. 173.

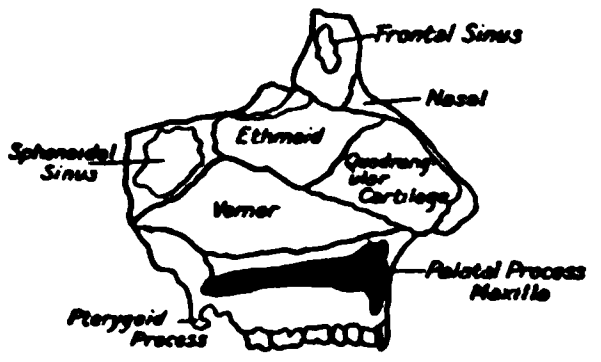

FIG. 171.—Diagram of side of nose showing relations of bones and cartilages.
FIG. 172.—Diagram of the bones and cartilages of the nose, anterior view.
FIG. 173.—Diagram of the septum of the nose. From Roberts's Surgery of Face.

superior maxillary. In fracture of the nasal bone the nasal spine of the frontal, the nasal process of the superior maxillary, the ethmoid and the vomer may also be involved. In fracture of the superior maxillary, the malar, the nasal, lachrymal, and palate bones may also be fractured. Owing to the great vascularity of the part and the character of the bone, union generally takes place rapidly with the formation of a small amount of callus, and deformities are frequent unless early reduction of the fragments is performed.

FRACTURES OF THE NASAL BONES.

Anatomy.—The nasal bones (Figs. 171–173) are two flattened triangular-shaped bones which unite in the median line to form the bridge of the nose. They articulate above with the nasal portion of the frontal with the frontal process of the maxillary. In addition there are five nasal cartilages, two upper and two lower lateral and the triangular nasal septum.

Fractures of the nasal bones may involve the nasal processes of



A B C

FIG. 174.—(A) Fracture of nasal bones and nasal process of left maxilla. Both nasal bones were fractured near lower end and a small piece was detached from the anterior margin of the left maxilla. Great deflection of front part of ethmoid and middle of septum to left. (B) Fracture of nasal bones and nasal process of right maxilla. Fracture of both nasal bones transversely at middle. Union with deformity consisting of deflection of nasal bones to the left. (C) Fracture and dislocation of nasal bones. Transverse fracture of both nasal bones near the middle. Union without much displacement.

FIG. 175 FIG. 176



FIGS. 175 AND 176.—Photographs showing depressed healed fractures of right frontal, malar, superior maxilla, and nasal bones. Injured by a fall of coal while working in the coal mines three years previously. Lateral and anterior views.

the frontal and superior maxillary, the cartilaginous septum, the lateral cartilages of the nose, the perpendicular plate of the ethmoid, the vomer and lachrymal bones. Fractures of the nose are generally comminuted, often compound through a tear of the nasal mucous membrane.

The cartilages and bones, forming the framework of the nose, are united with each other and with their neighbors by sutures at which normally there is no motion. If dislocation occur between a bone of the nose and an adjoining bone or cartilage, the rupture of the suture line is similar to a fracture of bony tissue.

Fractures of the nasal bones (Figs. 174–179) are due to direct violence. The displacement of fragments is primarily due to the force and direction of the fracturing force, and secondary displacement may be due to handling, blowing of the nose, and sneezing. Displacement is never produced or made recurrent by attached muscles.

FIG. 177.—Photograph showing profile of case of fracture of nasal bones with depression of fragments. Fracture produced by direct violence while turning a handspring.

The most common forms of fracture are: A transverse lesion near the middle in which the lower fragment is driven backwards at an angle with the upper fragment. In this fracture the quadrangular cartilage may receive the force of the blow, and be drawn backward with the lower portion of the nasal bone which has been broken off. As a result the cartilage may be fractured, bent, or dislocated from its attachment to the upper border of the vomer; or its lower anterior angle may be torn loose from the membranous portion of the septum, or from its connection with the maxillary bones at the anterior end of the vomer.

Fractures in which the comminuted fragments are driven directly backward so as to lie behind the nasal processes of the maxillary bones. Instead of a fracture, or coincident with the fracture, a luxation may occur between the nasal bone and the nasal process of the maxilla; or the nasal bones, while remaining attached to each other in the medium line, may be dislocated and occupy a somewhat similar relation to one or both maxillæ.

Fractures produced by a blow upon the side of the nose. In these cases the nasal bones may be luxated together, the outer edge of the nasal bone on the side of the injury being driven under the border of the maxillary process, while the outer edge of the other nasal bone is displaced on top of the maxillary process. In severe injuries the nasal

processes of the superior maxillary bone may be fractured as well as the nasal bones themselves.

The frontal bone and the horizontal plate of the ethmoid bone may be involved in severe fractures of the nose in such a way that the fragments are driven into the cranial cavity. Impaction is usual in these cases. The frontal sinus is very likely to be opened, and meningitis may develop as a result of infection. The cribriform or horizontal plate of the ethmoid is not likely to be fractured when the force injuring the nose spends its strength upon the lower third of the nasal bones. It is the perpendicular plate of the ethmoid bone that then bears the brunt of the injury.

FIG. 178 FIG. 179.

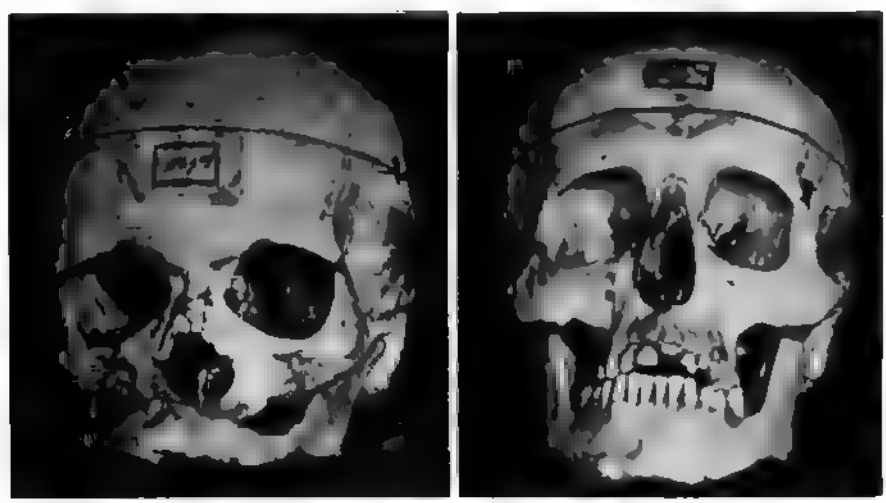

FIG. 178.—Skull; old fracture of nasal bones and left zygoma. The nasal bones were fractured in the middle and have united with decided depression of the nose. The nasal septum is deviated strongly to the left. The left zygoma was fractured at the summit of the arch but has united. (Mütter Museum, No. 1169.09)

FIG. 179.—Skull, fracture of the nasal bones, union. The bones are fractured transversely at the middle and have united with a decided deflection to the left The vomer is extremely displaced to he right. (Mütter Museum, No. 1169.06.)

Fractures from force applied to the upper border of the nasal bridge generally involve the ethmoid, while in those cases in which the force is received upon the lower part of the nose the quadrangular cartilage of the septum and the vomer are most apt to be injured, the line of fracture is perhaps more frequently horizontal in its general direction than vertical, and a luxation of the cartilage from the vomer is more common than from the ethmoid. In many instances, however, the fracture is associated with dislocation of the cartilage from the vomer or the ethmoid bones, and may assume more or less the character of a triangular fracture-dislocation. The fragments of the cartilage or of bone and cartilage may over-ride, so that the line of the

bridge of the nose shows a marked depression in the region of the lateral cartilages.

The lateral cartilages, which form the lower portion of the bridge of the nose, may be dislocated from the lower border of the nasal bones and from each other.

Methods of Examination.—The rapid swelling which accompanies these fractures of the nose soon obscures deformity in its framework, and causes many fractures and luxations to be overlooked. Anæsthesia with nitrous oxide or ether should be employed, if a careful examination cannot be made without great pain. Local anæsthesia with novocaine and adrenalin may be sufficient. Reflected light from a head mirror is essential in all cases because persistent obstruction to respiration from unreduced septal injuries may lead to mouth breathing and its attendant sequelæ. Saddle-nose, bent nose, twisted nose, and occlusion are frequent witnesses of unrecognized and untreated fractures of the nasal bones.

Symptoms.—Rapid swelling of the soft parts, bleeding from the interior of the nose, deformity, external and internal crepitus when fragments are not impacted, and preternatural mobility of parts of the nose are the more important of the early symptoms of fractures. Of the later symptoms may be mentioned subconjunctival ecchymosis, subcutaneous hemorrhage in soft tissues of nose and cheeks, and emphysema of eyelids and cheeks, indicating involvement of the accessory sinuses in the lines of fracture. Epiphora or imperfect drainage of tears from the eye to the lower nasal meatus is presumptive evidence that the nasal duct has been obstructed by swelling of its lining mucous membrane, or by distortion of its bony wall by reason of associated fracture of the maxilla, or by complete laceration of the duct in association with fracture. The external forms of deformity may consist in flattening or depression of the bridge of the nose, broadening of the nasal arch as well as flattening, and lateral deviation with or without angularity. Dislocation of the lateral cartilage from the lower margin of the nasal bone produces a hollow in the dorsum of the nose near the junction of the middle and lower thirds. Deviations of the cartilaginous and bony septum may accompany fracture of the nasal bones. One or both nostrils may be obstructed by an oblique position of a septal fragment.

Diagnosis.—The diagnosis of fractures of the nasal bones may be made by careful examination, particularly through the anterior nares with the aid of a speculum and good light, eliciting some of the above symptoms. External deformity is generally present. Deviation of the nasal septum may or may not be present. The principal form of deviation of the septum seen in conjunction with fracture of the nasal bones is a lateral displacement of the tip, and the most common form

of fracture is a horizontal one producing a gutter-like deformity in a horizontal plane. A triangular fracture-dislocation may cause a V-shaped piece of the septum to be driven backwards with the point toward the pharynx.

Complications.—The complications of nasal fractures are prolonged suppuration in compound comminuted fractures, followed by abscess of the soft parts and periostitis, perichondritis of bone or cartilage; involvement of the frontal sinus in the line of fracture, producing emphysema of the subcutaneous tissues; extension of the

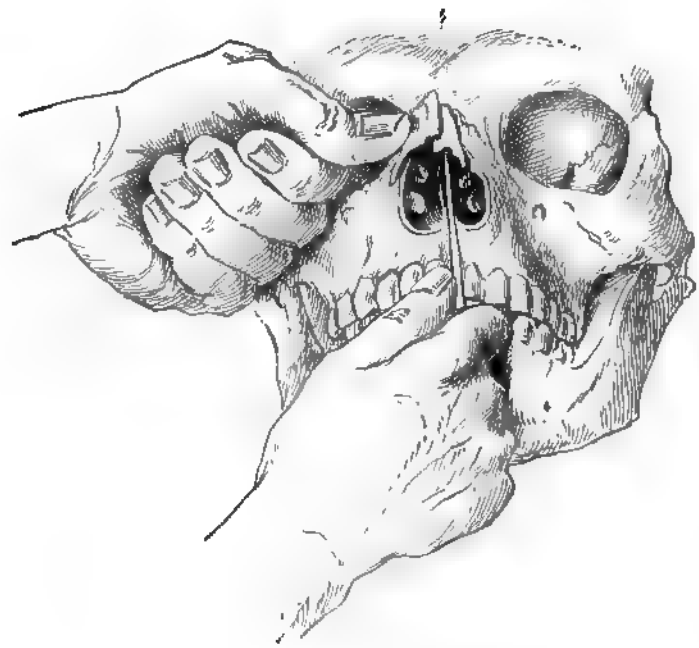

FIG. 180.—Mosher's method of reducing with thumb and elevator, fracture dislocation of nasal bones, when right nasal bone over-rides maxillary process and left is depressed and caught under its fellow and under the left maxilla.

line of fracture to the anterior fossa of the skull with accompanying osteocranial injury or meningitis; involvement of the cartilaginous or bony septum resulting in marked deviation; involvement of the lachrymal duct due to the line of fracture involving the nasal process of the superior maxilla with resulting epiphora.

Prognosis.—Union generally takes place in two to two and a half weeks.

Treatment.—It is essential that all recent fractures of the nasal bones be promptly and skilfully treated so that deformity from unreduced or carelessly replaced tissues may be averted. Injuries which are insignificant, so far as danger to life is concerned, may leave dis-

tortions of the outline of the nose or obstructions to breathing of great importance. Cosmetic reasons, therefore, and the necessity of having unobstructed nasal ventilation and breathing, especially in children, should stimulate medical attendants to give attention to nasal injuries. The proper development of the accessory sinuses and the associated contour of the jaws and other parts of the face depend upon free nasal ventilation in early childhood.

Recent Fractures.—The character of the injury and the form of displacement are to be determined by palpation of the exterior with the fingers, assisted by a rigid slender instrument within the nose for counter-pressure. Elevation and restoration of the depressed or displaced fragments of the osseous arch of the nose may best be accomplished by introducing a narrow steel instrument into the nostril. This

FIG. 181. FIG. 182.

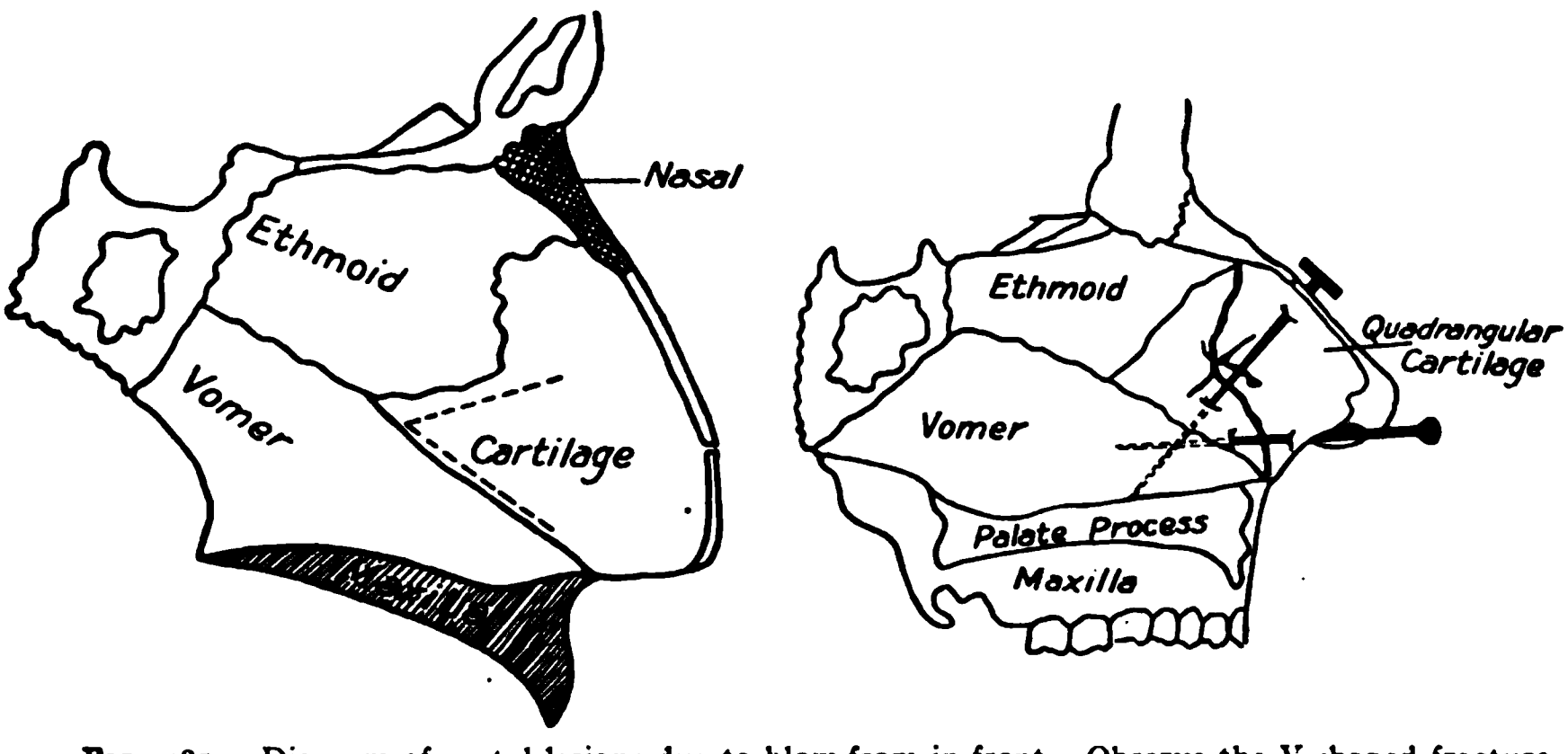

FIG. 181.—Diagram of septal lesions due to blow from in front. Observe the V-shaped fracture-dislocation of quadrangular cartilage and the overlapping of the V on the vomer. There may be a dislocation from both ethmoid and vomer or partly a fracture and partly a dislocation.

FIG. 182.—Roberts's use of pins to hold fragments of fractured septal cartilage in corrected position. One pin is thrust through the dorsum, the other is inserted into the nostril.

steel rod must be narrow enough to go to the top of the space between the nasal bone, the ethmoid plate, and the nasal process of the maxilla. By thrusting upward under the nasal bone and by proper manipulation externally, the surgeon can generally mould the displaced fragments into place (Fig. 180). Considerable force may at times be necessary to separate impacted fragments.

Displacement of the nasal septum may be restored after careful examination by means of a forceps with flap-wide blades. The septum is grasped by the introduction of a blade into each nostril, and the displaced portion pulled forward and its posterior end tilted upward by depression of the handles of the forceps. These manipulations, combined with lateral movements, will restore usually the line of the nasal bridge from forehead to the tip of the nose, and replace the obstructing

fragment of cartilage or bone into the middle of the cavity of the nose. If some time has elapsed since the injury, so that partial union of the displaced fragments has occurred, strong lateral movements with the forceps will generally be necessary to break up the fibro-osseous union and permit reposition.

The corrected position of the nasal bones, lateral cartilages, and septal structures is to be maintained by internal splints, by nasal pins, or by external pads attached to forehead bands. The last are seldom necessary and generally accomplish very little. There is usually little or no tendency to recurrence of displacement of fragment after proper reposition, unless the patient handles his nose or blows it violently. When such a tendency exists because of great comminution, the parts may be retained in place by filling the internasal space with gauze packing, or preferably by tubular nasal splints. Occasionally pins may be used to hold fragments in position (Figs. 181 and 182). Their use, however, is not advocated, except in a few well-selected cases. Their disadvantages are the presence of an open wound and the resultant scar at the site of the pin-holes. These objections are, however, not serious, if the pins and punctures are made aseptic.

Old Unreduced Fractures.—These cases call for osteotomy and re-fracture with readjustment. Division of cartilage and bone may be performed through small external incisions or through puncture wounds of the mucous membrane. After osteotomy and re-fracture have been performed and readjustment completed, the external wound may be closed with collodion dressings. Internasal splints should be used to maintain reduction. In saddle-back deformities of the nose due to fracture, the normal external contour may be gained by the use of subcutaneous injections of paraffin. This material is injected with a syringe having a piston driven by a screw attachment and needle of large calibre. It may be injected when in a fluid state from heat and moulded into a proper contour. The cooling causes solidification and the new nasal outline is permanent.

Lateral deformities involving the cartilaginous and bony bridge are as a rule accompanied by deviations of the cartilaginous and bony septum with occlusion of one or both nostrils. In these cases the prominence of the septum should be removed through a submucous resection to a point a quarter of an inch from the top of the cartilaginous bridge. If the lateral cartilages are displaced, their position is corrected by intranasal operations. The nasal bones are then chiselled loose and returned to their normal position. In all these cases proper internal retentive apparatus should be used for at least four to seven days and the nasal cavities should be kept as clean as possible by douching.

CHAPTER V

FRACTURES OF THE MALAR BONE

Anatomy.—The malar bone has three surfaces,—the facial, the posterior, and the orbital,—and articulates with the frontal, sphenoid, and the temporal bones; and has two processes, the frontosphenoidal and the temporal.

Surface Markings.—The malar bone forms the prominence on the cheek. Its external surface may be readily palpated, and where it extends backward can be felt the prominent zygomatic arch. Above this is situated the temporal fossa in which can be plainly felt the movement of the temporal muscle during mastication, and pulsation of the anterior branch of the temporal artery.

Fractures of the malar bone are the result of direct violence—either from without, as that of a blow or a fall upon a blunt object, or from within, as in a fall upon a stick held within the mouth. Isolated fractures of the malar bone are rare. They are seen usually in conjunction with fractures of the superior maxilla or of the frontal bone. The severe forms are accompanied by cerebral concussion and occasionally by an extension of the line of fracture to the base of the skull. Fractures of the malar bone may involve the orbit or the antrum of Highmore.

Methods of Examination.—This is best accomplished by having the patient seated upon a chair. The surgeon standing back of him palpates the malar bones with his two hands at the same time (Fig. 183). Any irregularities or depressions will be readily detected. The entire external surface, the inferior surface, the zygomatic process, the malar portion of the orbital margin, the frontal process, may be readily examined.

Varieties of Fracture.—Fractures of the malar bone may involve the body or its processes. Those of the body are of various degrees, depending upon the direction and degree of the fracturing force (Figs. 184 and 185). They form the greatest number of fractures of this bone. The external surface is crushed inward toward the maxillary sinus, and the fracture generally involves the superior maxilla. Fractures of the zygomatic arch (Fig. 186) alone are rare, and are generally due to external direct violence, although they may result from force transd through a stick held in the mouth. The fragments are usually d in the direction of the fracturing force. The fragments may ard and so produce pressure upon the coronoid process illa or the tendons of the temporal muscle, making r jaw difficult or impossible. Separation of the

entire malar bone from the remaining portion of the facial skeleton occurs, but true suture disjunction is very rare. In these cases the lines of fracture are near the suture lines and generally involve the



FIG. 183.—Method of palpation of malar bones. Any irregularities or depressions will be readily detected.

FIG. 184.



FIG. 185.

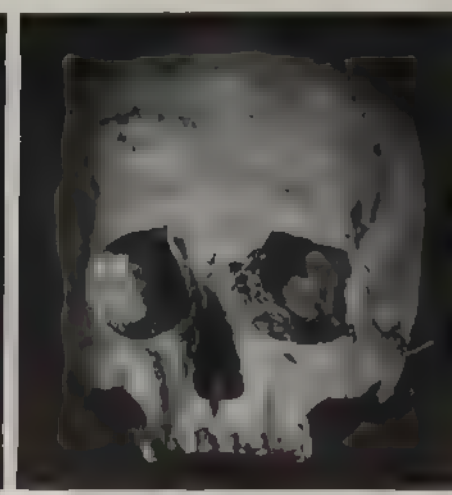

FIG. 184.—Lower half of skull. Fracture of the left malar union. The bone was fractured close to its junction with the superior maxillary. Union has occurred incomplete inferiorly and marked by a spicule at the margin of the orbit pointing toward the nose. (Mutter Museum, No. 1169-98.)

FIG. 185.—Skull. Old fracture of the nasal and left malar bones. The fracture occurred close to the upper border of the nasal bones and from the orbital margin of the malar toward the inferior angle. The deformity of the nasal fracture consists of a decided depression on the left side in which the internal angular process of the left frontal has shared. There is a fissure in the malar and slight exostosis on the orbital margin. From a sabre cut. (Mutter Museum, No. 1169-10.)

processes of the frontal, temporal, and superior maxillary bones, combined with fracture of the zygoma. Fracture with dislocation and displacement of the entire bone into the maxillary sinus is possible. For

this rare injury the fracturing force must be great; and the entire bone, together with the zygoma, may be forced into the maxillary sinus. Fractures with dislocation of the bone into the orbit or into the sphenomaxillary fossa have occurred. The last three varieties of fracture are rare, are the result of great violence, are generally accompanied by fractures of other of the facial bones, and the line of fracture frequently involves the base of the skull.

Symptoms.—These injuries are recognized by the deformity, the irregularity of outline, and crepitus. There is flattening of the cheek to the outside and below the orbit. In addition there is generally subconjunctival ecchymosis and occasionally protrusion of the eyeball. Mobility as bad as crepitus may occasionally be discovered. Of the rarer symptoms there may be areas of anæsthesia corresponding to the distribution of the superior maxillary nerve, which may be injured when the line of fracture extends into the floor of the orbit. The bleeding from the nose, due to laceration of the mucous membrane of the antrum, difficulty in movements of the lower jaw, due to pressure of fragments of the zygomatic arch upon the masseter muscle and coronoid process of the inferior maxilla, or fracture of the latter in conjunction with fracture of the zygomatic arch are occasional evidences of the fracture.

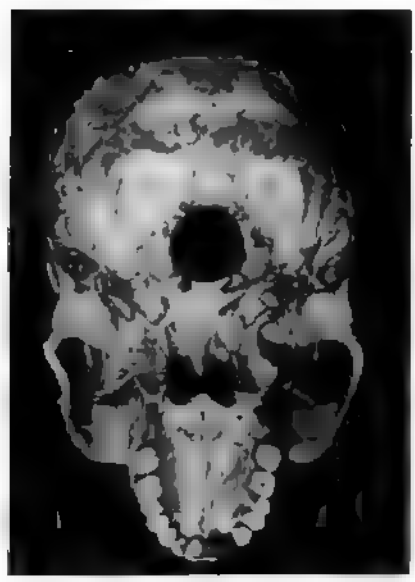

FIG. 186.—Skull; fracture of left malar. The left malar was fractured obliquely, downwards and forwards, near the zygoma. Union has occurred with slight depressions of the zygomatic arch. (Mütter Museum, No. 1169.20.)

Diagnosis.—The diagnosis of fracture of the malar bone may best be determined by deformity. Mobility and crepitus are rare. Deformity is generally masked by swelling. If one, however, carefully palpate the two sides of the face at the same time, the change in facial contour may be discovered; and if in addition to slight flattening of the body of the malar bone there is subconjunctival ecchymosis, bleeding from the nose, or localized swelling, one may pretty safely conclude that there is a fracture. Radiography may confirm the diagnosis. Fracture of the zygoma may be readily recognized by the presence of swelling of the soft parts, the evident depression of the arch, and the limitation of motion of the lower jaw.

Complications.—Of these the most important are injury to the superior maxillary nerve, contusion or destruction of the bulb or optic

nerve, seen in extensive dislocations of the entire malar bone into the orbit, and fracture of the anterior cerebral fossa in extensive communicating fractures.

Prognosis.—This is generally good unless there is laceration of the superior maxillary or optic nerves or an extension of the fracture lines into the base of the skull. These fractures heal very rapidly with the formation of little callus, hence reposition of fragments should be made as soon as possible. Otherwise varying degrees of flattening of the face over the malar bone and zygomatic arch will remain as permanent disfigurements.

FIG. 187.

FIG. 188.

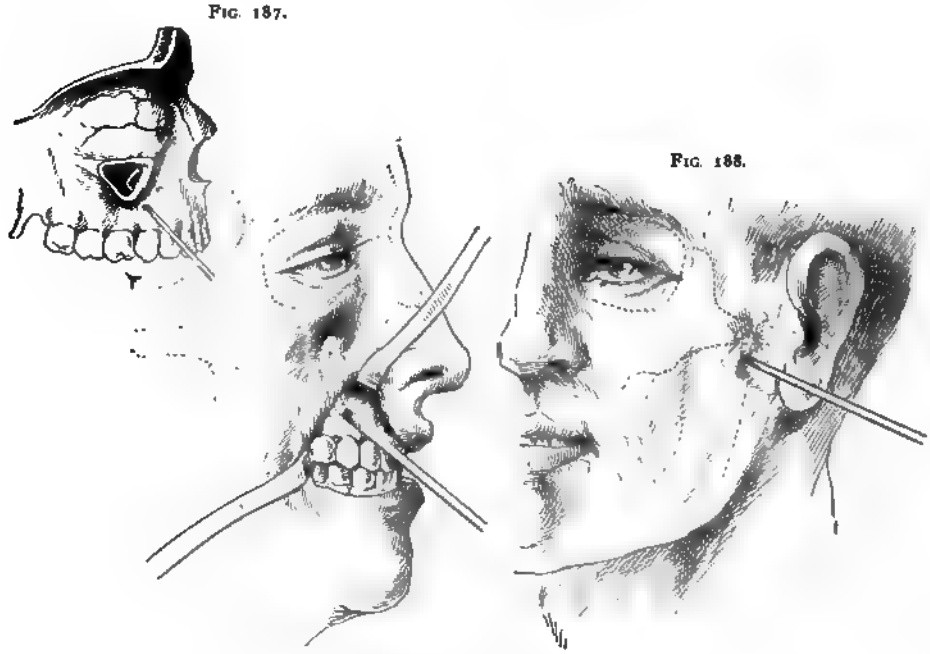

FIG. 187.—Lothrop's method of reduction of depressed and comminuted fractures of the malar and superior maxilla.
FIG. 188.—Matas's method of reduction of a depressed fracture of the zygomatic arch. (See Fig 187)

Treatment.—In many cases it is difficult to obtain complete replacement of fragments. In fracture of the zygoma it is possible to elevate depressed fragments by means of an incision through the skin and direct elevation. In fractures of the body of the bone this method is not so feasible, as it may be impossible to maintain reduction of the fragments. Depression of the body of the bone down into the antrum of Highmore may be corrected by the method devised by Hamilton and also by Howard A. Lothrop (Fig. 187). This consists in making an incision through the mucous membrane of the canine fossa of the superior maxilla, breaking through into the antrum with

a sharp chisel, and elevating the depressed fragments by means of a curved steel instrument. A 21 F. urethral sound is ideal. After thorough elevation, packing the antrum with a strip of gauze is a wise procedure. This is left in place for five days; then the antrum is irrigated with warm boric acid solution for several days. After removing the gauze it will be found that sufficient union has taken place to hold the fragments in their corrected position.

Sometimes the body of the fractured bone may be drawn forward into position by making small incisions above and below and grasping its edges by a pair of forceps shaped like the tongs used for carrying blocks of ice. In old fractures of the malar bone with deformity, it is generally impossible to correct the depression except by subcutaneous injection of paraffin, or the transplantation of a ball of fatty tissue, which may be cut from the abdominal wall.

Depressed fractures of the zygomatic arch may be reduced by the method of Matas (Fig. 188), which consists in introducing a hook through a small punctured wound below the arch and pulling the displaced fragment outward, or by an elevator introduced through a quarter-inch incision above the arch.

CHAPTER VI

FRACTURES OF THE SUPERIOR MAXILLA

Anatomy.—The superior maxilla occupies the middle of the face, and helps to form the floor of the orbit, the roof of the mouth, and a considerable portion of the nasal fossæ. It consists of a body and four processes: the frontal or nasal process, the zygomatic process, the palatine process, and the alveolar process. The body contains a large sinus, the maxillary sinus or antrum of Highmore, and has four surfaces: the anterior, the orbital, the infratemporal, and the nasal.

Surface Markings.—The anterior surface can be readily palpated as well as the palatine process and nasal surface.

Fractures of the superior maxilla are frequently accompanied by fracture of the malar, nasal, lachrymal, or palate bones. The injury is rare and apt to be due to violence acting directly upon the bone, such as a blow, a fall upon the face, the kick of a horse, the extraction of teeth, and gunshot wounds. This method of production is the cause of the injury being frequently an open fracture. Indirect violence, through transmitted force as seen in fractures of the malar or nasal bones, may occasionally cause the superior maxilla to be broken.

Methods of Examination.—The outline of the body and the various processes of the superior maxilla may be readily palpated. Its fracture can be readily determined, especially if an anæsthetic is used.

Fractures of the superior maxilla may be classified as follows:

Partial fracture of the alveolar process, the palatine vault, the nasal process, the maxillary sinus walls.

Gross fractures are intermaxillary separation or disjunction, horizontal fractures of three types, separation of the entire alveolar process, double horizontal fracture of A. Guérin, and craniofacial disjunction.

Perforating fractures, generally of the hard palate and floor of the orbit, the result of gunshot and penetrating wounds through the mouth.

Fractures of the body, frequently comminuted, may involve the antrum of Highmore. They are also seen in conjunction with fractures of the malar or nasal bones.

Fractures of the alveolar process are due to direct violence, as a blow or a fall upon the face, or to the unskilful extraction of teeth.

Definite fracture lines according to the direction of the force have been ascertained in fractures of the superior maxilla by the recent investigations of A. Guérin: A transverse fracture runs backward into the pterygoid process almost 1 cm. below the malar bone on both sides and is the result of a severe blow from before backward below the nostrils in the median line or somewhat to the side. There may

be entire displacement of the vault of the mouth with the alveolar processes posteriorly. The pterygoid processes are fractured at the level of the lower border of the pterygoid maxillary fissure. Fissuring of the palate bones from before backward may also take place. If the fracturing force is lateral and corresponds to the level of the palate, the above form of fracture results, and if the direction of the force is sagittal there is always a fracture of the pterygoid processes in addition. When the fracturing force is lateral and oblique from above downward, the alveolar process is detached and also a portion of the body of the bone, depending upon the level of the fracturing force. When the fracturing force is from below upward there may be fissures surrounding the malar bone; and when the force is severe and bilateral there may be detachment of the entire median portion of the bony face, with extension of the fracture lines from the nasal apertures toward the orbits. Fissure fractures of the palate may also be present. A severe blow received from a broad surface acting upon the superior maxillary and malar bones may cause complete detachment of the facial bones from the skull proper. This form of injury has been observed by Dr. Kelly in the case of an elevator accident.

Symptoms.—The symptoms of fracture of the superior maxilla are in great degree dependent upon severity of injury. The principal symptoms are swelling, ecchymoses, asymmetry, crepitus and mobility of fragments. Many of these fractures may be compound into the nasal or oral cavities and communicate with the antrum of Highmore. Lacerations of the mucous membrane of the latter may lead to emphysema of subcutaneous tissues. A careful inspection of the nasal and oral cavities should be made. At times a general anæsthetic will be necessary.

In severe injuries the lines of fracture may extend into the base of the skull and there may be coincident injury to the intracranial contents.

Complications.—Compression or laceration of the lachrymal duct, injury to the superior maxillary nerve, injury to the orbital contents, meningitis, hemorrhage, periostitis, necrosis of bone, are occasional complications of maxillary fracture.

Diagnosis.—Examination of the surface of the face, the interior of the nose and mouth will disclose the nature of the fracture. If there is no displacement of fragments, examination may detect the source of the hemorrhage and the possible tear in the mucous membrane. Fractures of the body will show some irregularity of surface contour. Fractures of the alveolar process will be determined by crepitus, mobility, and irregularity in the outline of the teeth. Em-

of the subcutaneous tissues points to injury involving the

evere injuries, the diagnosis is evident from the asym-

nd mobility of the fragments, although it may be

mine the full extent of the line of fracture, or the

existence of involvement of the base of the skull unless symptoms of intracranial injury develop.

Prognosis.—In uncomplicated cases union of the fragments generally takes place in three or four weeks without the formation of much callus and with little deformity. Severe neuralgia may persist for a long time from involvement of branches of the superior maxillary nerve in the callus, and epiphora may persist due to obliteration of the lachrymal duct. Necrosis of bone is rare because of the abundant blood supply, and even portions that are detached may unite. On this account all portions of bone necessary for the contour of the face and alveolar process should be preserved if possible. Displacement of fragments, unless it be extreme, is seldom noticeable after healing takes place, unless the nasal bones are also fractured, in which event deformity of the nose may be permanent.

Treatment.—In treatment of these fractures loose teeth should be left in place, as they frequently become permanently fixed again. Many disjunctions are readily reduced but difficult to keep in place; union generally results with a certain degree of deformity. This may be prevented in some cases by cutting down of fracture and suturing fragments with chromicized catgut, or using nails or screws for direct fixation.

Loose fragments of bone should not be removed primarily because repair may take place without necrosis. In all open fractures into the mouth, nose, or maxillary sinus, thorough cleanliness should be observed. Frequent douching of the nose is then desirable, and some form of mild antiseptic solution, as a gargle should be used. Tartar should be removed from the teeth, which should be kept as clean as possible. In some fractures retention of the fragments may be secured after reduction by the use of interdental splints of vulcanite or metal. Very often it is possible to maintain reduction by means of the Angle, Hammond or Gunning splint. Several other forms of retention apparatus, notably that of Goffre and Gräfe, have in addition to a splint surrounding the upper jaw a metal attachment running to a hood over the head. This apparatus is hard to keep in place, and unless great care is maintained is easily displaced and may cause the patient marked discomfort. When possible these patients should be placed in the hands of a skilled oral or dental surgeon, who is able to apply the proper form of interdental splint. During the three to four weeks that closure of the mouth is required, liquid food is introduced through the crevices between the teeth, or by a tube passed between the alveolar arch and the cheek back to the last molar tooth.

When the fracture involves anterior and lateral portions of the antrum of Highmore, an accompanying fracture of malar bone is present with depression of the superior maxillary and malar bones inward. Reduction is best accomplished by the method of Lothrop (Fig. 187).

CHAPTER VII

FRACTURES OF THE MANDIBLE

Anatomy.—The inferior maxilla, or mandible (Fig. 189), is the only bone of the skull connected with the others by a joint. It is composed of a body and two rami. The body is horseshoe in shape, from the posterior extremities of which ascend the two rami. In fact the bone may be considered as a union of two symmetrical halves, which form the framework of the lower part of the face. The body has a base, or inferior portion, and an alveolar portion containing the alveolar border. On the anterior external surface is the mental protuberance, and at each side of this near the base the mental tubercles. Above and external to the mental tubercles are the mental foramina.

The external surface also presents an oblique line extending downward from the coronoid process of each ramus. The internal surface

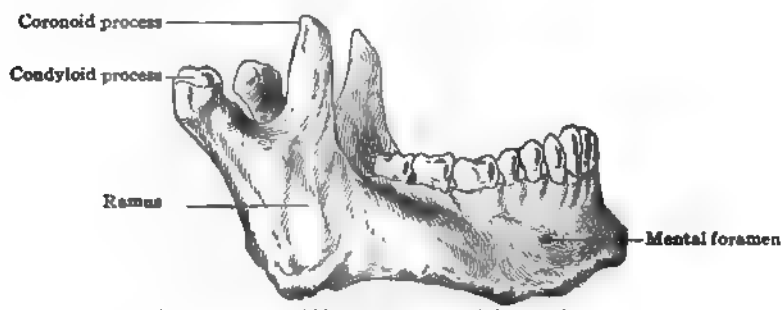

FIG. 189.—Mandible, outer aspect. (Piersol's Anatomy.)

of the body presents the digastric fossa, the mental spine, the mylohyoid line, the mylohyoid groove and the mandibular foramina. Extending upward from the posterior extremities of the body are the rami, at the beginning of which on each side is the angle of the inferior maxilla. At the summit of the rami are the condyloid process, the notch of the mandible, and the coronoid process.

Surface Markings.—The entire inferior maxilla can be readily palpated externally, and internally also by a finger in the mouth. The prominent anterior part, the symphysis mentis, the ridges or alveolar jugæ, the edge of the masseter muscles, the angle, and the coronoid process may be felt, and the examiner can fairly well outline the tempero-maxillary articulation.

Statistics.—Fractures of the inferior maxilla are more frequent than of the superior maxilla. They are rare in childhood and old age,

and most frequently occur between the third and fourth decennium.

In 1722 fractures, Lente found 66 (3.19 per cent.) in the inferior maxilla, the fracture occurring ten times more frequently in men than in women. In children mandibular fractures were seldom observed. The combined statistics collected by von Bleichsteiner, comprising 156 cases of fracture of the lower jaw, showed that 56 occurred in the third

FIG. 190.—Fracture of mandible through symphysis.

and only 7 in the first ten years of life. Of Gurlt's 143 reported cases 80 were single, 49 double, and in 14 there were three or more lines of fracture. Of the 80 single fractures, 5 involved the alveolar processes, in 25 the line of fracture involved the median line, the region of the incisor teeth in 22, the region of the molar teeth in 15, posterior to the teeth in 8, and the condylar process in 5 instances. In 35 double fractures in which the line of fracture is described, both sides of the bone

were involved in 20 instances, generally at corresponding points; in 8 cases one side alone was involved, and in the remaining 7 cases the median line was involved in one of the fracture lines.

Etiology.—Fractures of the mandible are usually the result of a blow with the fist, a kick, a fall upon the chin, gunshot injuries, or the faulty extraction of teeth. The last form of violence rarely results in a direct transverse fracture, but generally in a tearing off of a portion of the alveolar process. Most fractures are the result of direct violence. A few rare forms of fracture may be the result of indirect violence, as by coughing, a tearing off of the coronoid process by violent contracture of the temporal muscle, or a compression of the jaw from side to side, accompanying a lateral compression fracture of the skull. The site of fracture in the last instance occurs near the point of greatest flexion—the symphysis. Fracture of the neck of the condyloid process from a blow on the chin is also an example of indirect violence. Bilateral fracture of the inferior maxilla is uncommon, although multiple fractures are fairly frequent. Hamilton states that they form about one-third of all cases. Comminuted fractures are rare. Open, the so-called compound, fractures are very frequent, because the adherent gum overlying the seat of fracture is generally torn. Fractures are rare through the symphysis.

FIG. 191.—Mandible; old fracture of the body; union. The line of fracture is midway between the symphysis and the right inferior dental foramen. Union occurred without deformity, but with a deficiency at the alveolar border which exposes the root of the right incisors. (Mütter Museum, No. 1169.14).

Varieties.—Fractures of the horizontal portion are generally open, and of the ramus usually closed. The site of fracture depends upon the position of the trauma, the manner in which the blow was received, and the presence of any weak point in the bone. The following are the usual sites of fracture:

Fracture Through the Symphysis (Figs. 190 and 191).—This is very rare. If comminuted, a portion of the bone may be drawn backward by the geniohyoid and geniohyoglossus and at times the digastric muscles, and cause symptoms of suffocation. The line of fracture if single is generally vertical.

Fractures at or near the mental foramen (Figs. 192 and 193), in the region of the canine tooth, are more frequent than those of

the median line. The line of fracture is generally oblique. This is a weak part of the bone, which is strong behind this point on account of the beginning of the hylohyoid ridge and the protection afforded by the masseter muscle. Depending upon the line of fracture, certain displacements occur. When the line of fracture runs forward and downward and from within out, very little if any displacement occurs. When its direction is downward and backward, the anterior portion

FIG. 102. Fracture of mandible near mental foramen.

is depressed by the geniohyoglossus, geniohyoid, mylohyoid, digastric, and platysma muscles, and the posterior portion is elevated by the temporal, masseter, buccinator, and internal pterygoid muscles. If the fracture is double, the displacement of the anterior fragment is marked. When the line of fracture runs backward from above downward and backward from within out, the posterior fragment is drawn inward by the internal pterygoid and mylohyoid muscles, and the anterior fragment is drawn upward by the action of the internal pterygoid of the opposite side.

Fracture through the molar region (Figs. 194 and 195) is not uncommon. Here there is very slight displacement of fragments, due to the firm attachment of the masseter and internal pterygoid muscles. Injury to the vessels and nerves running in the inferior dental canal are disagreeable symptoms which may complicate fractures in this region.

Fractures through the Angle (Figs. 196 and 197).—A small number of fractures occur here. There is generally slight displacement upward and forward of the ramus due to the pull of the masseter and internal pterygoid muscles with a backward and downward displacement of the body.

Fractures through the ramus (Fig. 198) are extremely rare, because of the protection afforded by the attached muscles. The line of fracture is generally oblique from in front and above downward and backward. Dislocation of fragments is rare unless the fracture is bilateral or complicated by a luxation of the condyloid process of the opposite side. Generally the fragments are held in apposition by the masseter and pterygoid muscles.

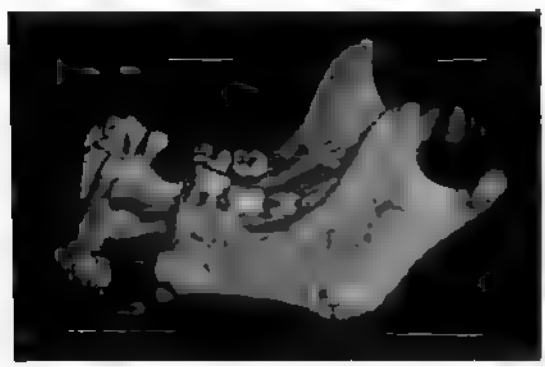

FIG. 193.—Inferior maxilla; ununited fracture. The fracture occurred through the left mental foramen; failing to unite, the bone is thickened at the seat of fracture and the opposing edges are rough. (Mütter Museum, No. 1169.13).

Fracture through the condyloid process (Figs. 199–202) is generally at the neck, is comparatively frequent, and is difficult to treat. Roe reports 6 out of 41 cases of fracture of the lower jaw. The displacement in this form is characteristic. The chin and jaw are pulled toward the injured side, especially by the internal pterygoid muscle of the opposite side. This lesion is differentiated from dislocation of the jaw by the fact that in the latter the chin will point toward the normal side. In bilateral fracture of the condyloid processes the entire lower jaw will be pushed upward and backward and the lower teeth will be displaced behind the upper teeth.

Fracture through the coronoid process are extremely rare. Moderate displacement of the upper fragment occurs on account of the pull of the temporal muscle. These fractures are generally the result of direct violence and often are accompanied by fractures of the malar and superior maxilla or base of the skull.

Fractures of the alveolar process (Fig. 203) are comparatively

FIG. 194. Fracture of mandible through body.

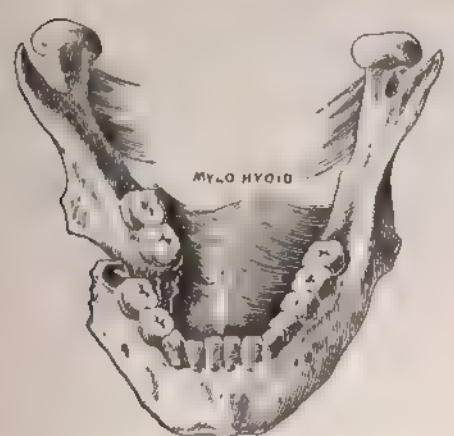

FIG. 195.—Fracture of mandible, malar region, showing type of displacement of fragments.

frequent. They are generally produced in the faulty extraction of teeth, or by a blow upon the teeth.

Method of Examination.—Examination is accomplished by the insertion of the index-finger into the mouth while the other fingers, upon the chin, seize the lower fragment, and the other hand steadies the upper fragment (Fig. 204). By manipulation, displacement of fragments may be recognized and crepitus may be elicited. It is, however,

FIG. 196.—Fracture of mandible, through angle.

unnecessary to do this in all cases. Simple inspection of the gums in fractures of the body will generally show laceration of submucous hemorrhage, and mal-alignment of or looseness of the teeth.

Symptoms.—The symptoms of a fracture of the inferior maxilla are well marked in fracture of the body and generally obscure in fractures of the ascending ramus. The displacement, crepitus, and unnatural mobility in fracture are easily detected, but one should bear in

mind the possibility of mal-positions of the teeth from irregular development and irruption. Pain is a most constant symptom in fracture



FIG. 197.—Fracture of mandible through molar region, showing typical displacement of fragments. The ramus is pulled upward, forward, and inward by the masseter, temporal, and internal pterygoid while the body is displaced downward.

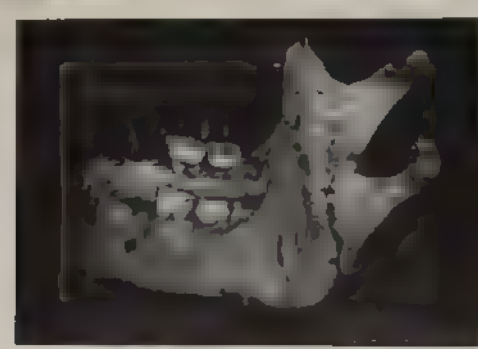

FIG. 198.—Inferior maxilla, oblique fracture of the ramus, ununited. The left ramus was fractured obliquely in a line running from the sigmoid notch near the coronoid process downward toward the angle of the bone. (Mutter Museum, No. 1169 21.)

of the jaw. It is increased by talking and deglutition, and profuse salivation is generally present. This increase of saliva and mucus is

largely relative, the excess being due to the want of proper control of the fluids within the mouth. These fluids may be mixed with blood, due to the fact that many of these fractures are open. Examination will often disclose a tear of the mucous membrane or a submucous ecchymosis, and irregularity of the teeth without proper articulation of the upper and lower rows. In fractures without displacement, crepitus, or mal-alignment of teeth, the only symptoms present may be swelling, local tenderness and pain, and inability to freely move the lower jaw. In fractures of the neck of the condyle there is generally a slight depression in front of the external auditory meatus, and on



FIG. 199.—Fracture of mandible through neck of condyle. Boy was struck on side of jaw by falling rock. Arrow points to displaced condyle.

movement of the jaw the condyle does not follow its normal range of motion. Other late symptoms of fracture are fetor from decomposing food, pus and other secretions, abscess about necrosed fragments of bone, fistulous tracts and ulcerations of the mucous membrane; and in occasional instances marked general debility due to the swallowing of foul secretions and deprivation of nutritious food.

Complications.—The complications of fracture of the inferior maxilla may be divided into those due to traumatism and those due to infection. The complications due to traumatism are the immediate and the delayed. The *immediate* are severe laceration of face and lips, hemorrhage from laceration of the soft parts and occasional rupture

of an artery Coyler reports a case in which a traumatic aneurism developed, necessitating ligation of the common carotid. Additional immediate complications are dislocation associated with fracture, dislo-

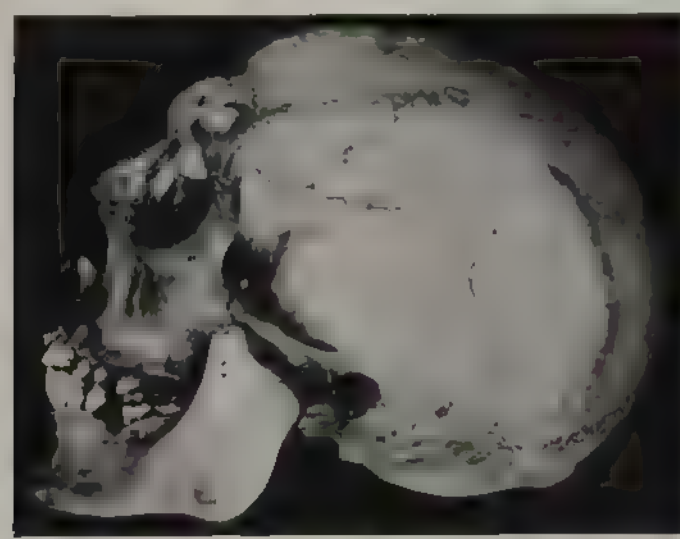

FIG. 200.—Side view showing the condyloid process "bent" in and forward to almost a right angle with the ramus, the head resting in the pterygomaxillary fossa. (Courtesy Dr. M. H. Cryer.)

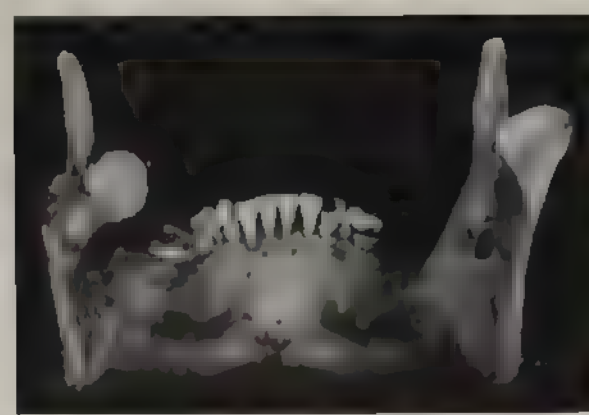

FIG. 201.—Posterior view of mandible showing a united fracture of the neck of the left condyle. This position is typical for this class of fractures. Through the action of the external pterygoid muscle the position of the head of the condyle sometimes interferes with the function of the mandibular nerve and vessels. The illustration also shows that there has been another fracture between the canine tooth and the second incisor, passing through the bone. (Courtesy Dr. M. H. Cryer.)

cation and fracture of the teeth, laceration or compression of the inferior dental nerve, fracture of the base of the skull and cerebral concussion. The *delayed* complications are involvement of the inferior dental nerve in callus, delayed or non union of the fragments, and union

of fragments, in such a position that correct articulation of the upper and lower teeth is not possible.

Of the complications due to infection, the most frequent and important is necrosis of the ends of the fragments. This condition may lead to delayed union, or pseudo-arthrosis, to abscess, salivary fistula, septicæmia and pyæmia. Stomatitis is also a frequent complication.

Diagnosis.—The diagnosis of fracture of the mandible is, as a rule, made without difficulty. In condylar fracture diagnosis may be difficult. Usually crepitus may be obtained, and this, combined with the history of violence, local tenderness on pressure, the presence of a

FIG. 202. FIG. 203

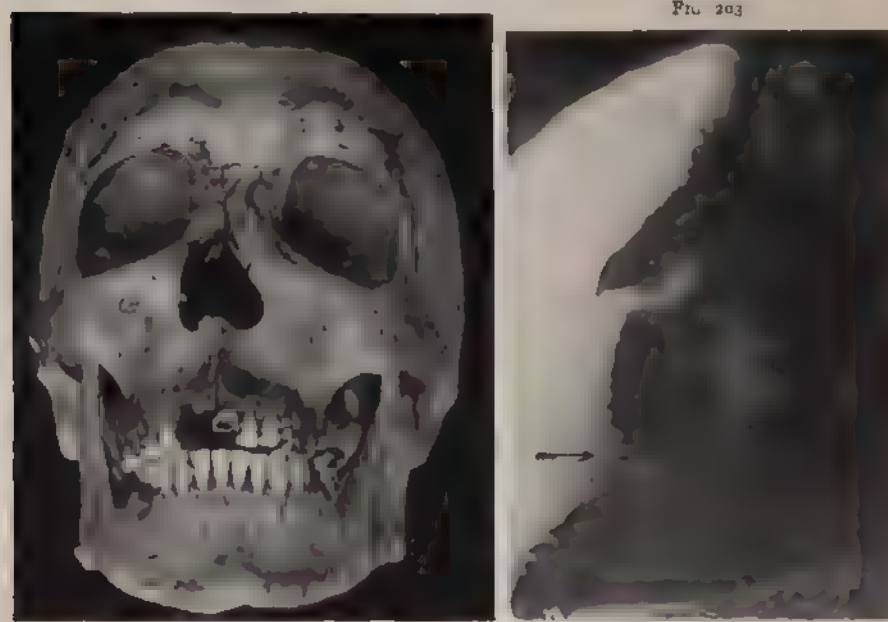

FIG. 202.—An anterior view of the same skull. The left condyle is seen in the left pterygomaxillary fossa. (Courtesy Dr. M. H. Cryer.)
FIG. 203.—Fracture of mandible through base of anterior part of alveolar process.

depression anterior to the external meatus, and the failure of the condyle to follow the movements of the lower jaw on motion of the latter, will generally clear up the diagnosis. In most of the instances the diagnosis may be made from deformity, pain on motion, chewing or talking, crepitus, profuse salivation often streaked with blood, laceration of the mucosa, and localized pain on pressure or motion. Fractures of the coronoid process can only be suspected clinically by local tenderness on pressure inside the mouth and pain on motion. Crepitus may or may not be elicited. Radiograms will solve most cases with great readiness.

Prognosis.—Union of uncomplicated fractures without laceration of the mucous membrane generally occurs within from five to six weeks. The prognosis, even in bad cases, is ultimately good. Extensive and severe open fractures are often followed by surprisingly good results. In open comminuted fractures delayed union may result for a time, but eventually union takes place after the discharge of sequestra. Pseudo-arthrosis is rare. Norris reports only two cases of non-union in 150 fractures; and the statistics of Muhlenberg and Berenger-Feraud show that they form only 2 per cent. of all pseudo-arthroses observed. Many of the disturbances referable to the inferior dental nerve are temporary. The presence of severe neuralgia, anæsthesia and paralysis are generally due to the presence of a blood clot pressing

FIG. 304.—Method of determining crepitus and abnormal mobility of fragments in fracture of the mandible

upon the inferior dental nerve, rather than to any actual lacerations or bony compression of the nerve. When pressure is produced by bony fragments it is generally in fractures posterior to the mental foramen. In prolonged symptoms of compression, relief may be obtained by operative exposure of the nerve. Fractures of the condyloid process may be followed by ankylosis of the temperomaxillary joints. In fractures of the coronoid process fibrous union is the rule, and there is generally no interference with subsequent mastication.

Treatment.—In the treatment of fractures of the inferior maxilla, two points should be carefully considered. First, the proper reduction and retention of the fragments, and, second, the care of the mouth. Failure of union in fractures of the inferior maxilla may frequently

be traced to the lack of proper oral asepsis. In all cases our primary consideration should be avoidance of a stomatitis with its resulting sepsis and necrosis. This is particularly important, as nearly all fractures are open. The utmost care should therefore be used to disinfect the mouth and keep it clean. Thorough irrigation with a mild antiseptic solution should be performed after each meal.

Reduction of the fragments by pressure of the fingers on the teeth is usually easy, though occasionally comminuted fragments or displaced teeth may cause interlocking and require removal before correct apposition is obtainable. Teeth which are simply loosened should not be removed unless they prevent proper reduction. Care should be taken to maintain the "bite"—the normal relation of the upper and

FIG. 205. FIG. 206.



FIG. 205.—Moulded felt chin splint padded with several layers of sheet-wadding.
FIG. 206.—Application of occipitomental roller bandage to hold chin splint in place in fracture of the mandible.

the lower teeth. Union in most cases is fairly firm at the end of three weeks, and very little retentive apparatus is required after the fourth week. Reduction in fractures of the condyle may generally be obtained by following the suggestion of Ribes, which consists in first pulling the jaw forward and then pressing the condyle from within outward by the finger placed upon the upper, lateral wall of the pharynx. Reduction in all other cases is generally easy.

While reduction is simple, as a rule, its maintenance is often difficult or impossible. In many cases the simplest measures will retain the fragments in their proper position. The various methods of maintaining reduction may be grouped as follows: External dressings; combined external and internal dressings or splints; internal splints; and wiring or some other method of direct fixation.

External Splints.—The simplest form of external dressing is the Barton bandage of the occiput and chin; or moulded chin splint (Figs. 205 and 206), or a Lewis metal chin splint held in place with an occipitomental roller bandage or a four-tailed bandage.

These dressings are useful as temporary dressings during the manufacture of an interdental splint, but as a permanent dressing, in the presence of any marked tendency toward displacement of fragments, they are not satisfactory.

The objections to their use are the necessity of tight bandaging of the lower to the upper jaw, which entirely prevents mastication, and the tendency to displacement of fragments which is not overcome. In certain cases, notably oblique fractures in the region of the mental foramen, the external pressure produced by them may tend to increase the displacement.

FIG. 207. FIG. 208.

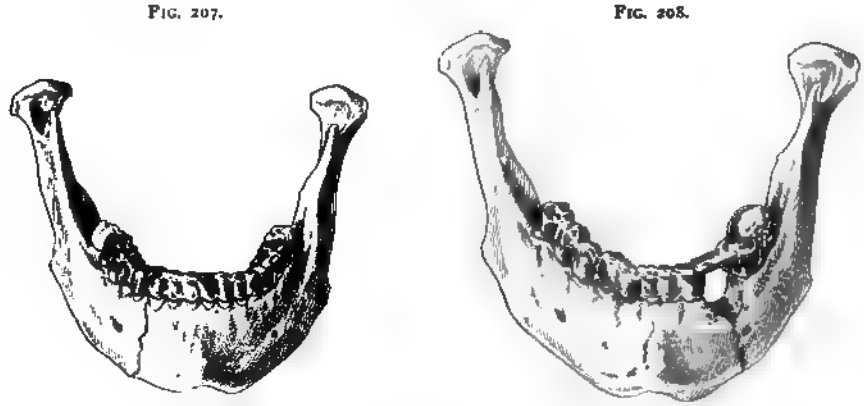

FIG. 207.—A fracture of the mandible, showing interdental splint in position. (Courtesy of Dr. M. H. Cryer.)

FIG. 208.—An interdental splint holding the mandible together where a pathological separation of bone occurred, causing the loss of a complete section of bone. New bone filled in the parts, leaving no disfigurement or shortening of the jaw. (Courtesy of Dr. M. H. Cryer.)

Two splints are in use which cause fixation of the fragments by means of vulcanite interdental splints and an external figure-of-8 bandage. These two splints are known as the Gunning and the Hern modification of the same. The Gunning splint consists of two rounded vulcanite caps for the upper and lower teeth joined together by supports. These caps are filled with gutta-percha. After insertion of the splint the jaw is fixed between it and a figure-of-8 bandage.

The Hern modification of the above consists of a vulcanite cap covering the teeth and the alveolar border of the inferior maxilla. Blocks or pillars are built upon the upper surface of the splint; these contain indentations corresponding to the upper teeth. The recesses of the vulcanite contain gutta-percha for articulation with the upper teeth. The splint is applied like the Gunning and is held in place by a

skull and chin cap, with connecting bands of elastic to produce constant pressure.

Interdental Splints and Dressings.—Of the various methods of interdental splinting, the most notable and practical are those of Hammond, Angle, Payne, Sauer, Hohl, Schauber, Schellhorn and Neder.

The simplest forms of interdental splints are the Hammond, Angle, and Payne. The Hammond splint is made by bending soft iron wire and moulding it as accurately as possible to a model taken previously. The wire is fitted to the lingual and buccal sides of the teeth, the ends being soldered together. If necessary, the wire may be fitted directly to the teeth. When the splint has been made, the fragments are

FIG. 209. FIG. 210.

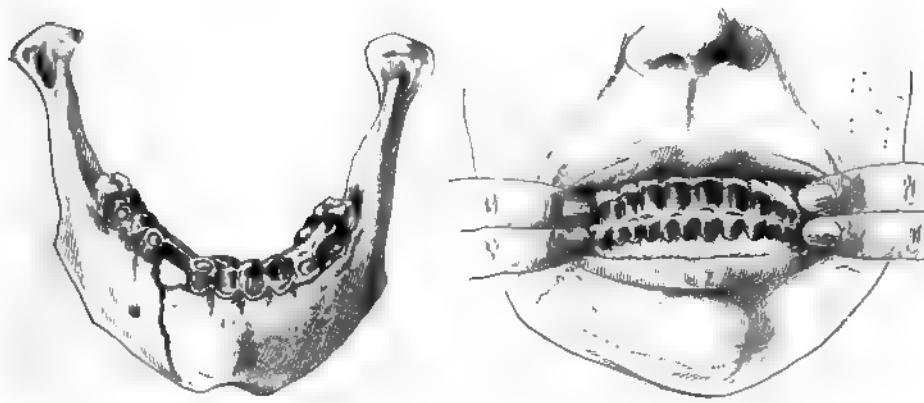

FIG. 209.—An interdental splint used in case of a compound fracture of the mandible. At first the parts were wired together with bad results; the wire was removed and a splint was cemented in position. In six weeks time the parts had united. (Courtesy of Dr. M. H. Cryer.)

FIG. 210.—Two compound fractures at the angles of the mandible treated by a mandibulomaxillary splint, consisting of two interdental splints, upper and lower, soldered together and cemented so that the teeth are held together in their normal position. Although there is no hold of the rami by the splints they will adjust themselves to the other end of the bone. (Courtesy of Dr. M. H. Cryer.)

reduced, the splint placed in position, and the teeth fixed to the splint by means of ordinary iron or silver wire. When there are a number of teeth present those close to the seat of fracture should not be bound. After the end of a week the wires should be tightened. The splint devised by Claude Martin, of Lyons, is a modification of the above and consists of three silver wires approximately the form of the dental arch, and which are connected to each other at intervals by transverse wires, and is held to the teeth by means of silk thread. The Angle splint consists of encircling bands of metal applied to several approximating upper and lower teeth. These bands are adjusted to the individual teeth, are tightened, and the outer surface of each band has a small projection to which wires are attached, joining the upper and lower bands and holding fast the upper and lower teeth. The Payne

splint is made of a silver wire framework fitted to the necks of the upper and lower teeth on the labial and lingual aspects, the wire being carried around the arch as far as it is necessary. The ends of each half of the framework are soldered together and at several intervals transverse bars are fixed. The two arches are united by rods on the labial and lingual sides and the splint ligatured to the teeth by means of fine silver wire. The advantages of this splint are that the fragments are



FIG. 211.—Roentgenogram showing method of suture of fragments in fracture of the mandible with silver wire.

held in good position, the teeth and mouth can be readily cleansed, and the condition of the jaw observed.

The two most useful forms of splints for fracture of the mandible are the interdental splint and the mandibulomaxillary splint. These are made of aluminum or gold. The interdental splint (Figs. 207–209) is made to fit the crowns of all the lower teeth at each side of the seat of fracture, after reduction of the fragments, the splint is cemented in place, and the use of this splint allows of opening and closing the

mouth for inspection. The mandibulomaxillary splint (Fig. 210) is made of aluminum or gold. It is made to fit the crowns of all of the upper and lower teeth, and after reduction of the fragments it is cemented to the teeth. It does not allow of opening and closing of the mouth, and does not allow of mastication. It is particularly useful in double fracture of the mandible.

Another useful form of interdental splint is one made of aluminum, which fits the crowns of the teeth at each side of the seat of fracture and allows opening and closing the mouth for inspection.

Suture of the fragments with silver wire or silver-plated copper wire has been used rather extensively at times. The cases in which this form of retention is indicated are limited. Various methods of using wire are in vogue. Perhaps the simplest is to drill holes in each fragment, at least one-fourth of an inch away from the seat of fracture. The hole in the depressed fragment should be drilled at a lower level than the one in the other fragment, so that in tightening the wire there is a lifting tendency and a great resistance to recurrence of deformity. After introducing the wire the fragments of bone should be drawn together, the wire twisted and cut, and the sharp cut ends covered by a small piece of rubber tubing (Fig. 211). Screws or steel plates may be used in a manner similar to that employed in fixation of bones of the extremities. They are, however, rarely used.

In difficult cases of fracture of the lower jaw with displacement of fragments, the aid of a competent dental surgeon should be secured in the preparation and application of a suitable interdental splint. Fractures at certain positions require various forms of splinting. Metal splints of aluminum are undoubtedly the best for fractures of the body or alveolar process. The Hammond splint and the aluminum moulded splint are undoubtedly two of the best for fractures in this region. Fractures about the angle may be treated by an outside gutta-percha splint so made as to pass backward and thus support this angle. This splint can be kept in position by a Barton bandage. Fractures of the ascending ramus, condyle, or coronoid process are best treated by the method of Angle, or, if this is impracticable, fixation may be obtained by external dressings, as the Barton or four-tailed bandage.



CHAPTER VIII

FRACTURES OF THE HYOID BONE

Anatomy.—The hyoid (Fig. 212) or lingual bone is a small horse-shoe-shaped bone situated at the base of the tongue between the chin and the thyroid cartilage. It consists of a body, two greater cornua, and two lesser cornua. The body has a concave posterior surface directed backward and downward toward the epiglottis. The greater cornua are tapering processes arising from the sides of the body, are directed upward and backward, and end in a small bulbous tubercle to which the thyrohyoid ligaments are attached. They may be connected to the body by either bony tissue or fibrocartilage. The lesser cornua arise from the bases of the greater cornua, extend upward and back-

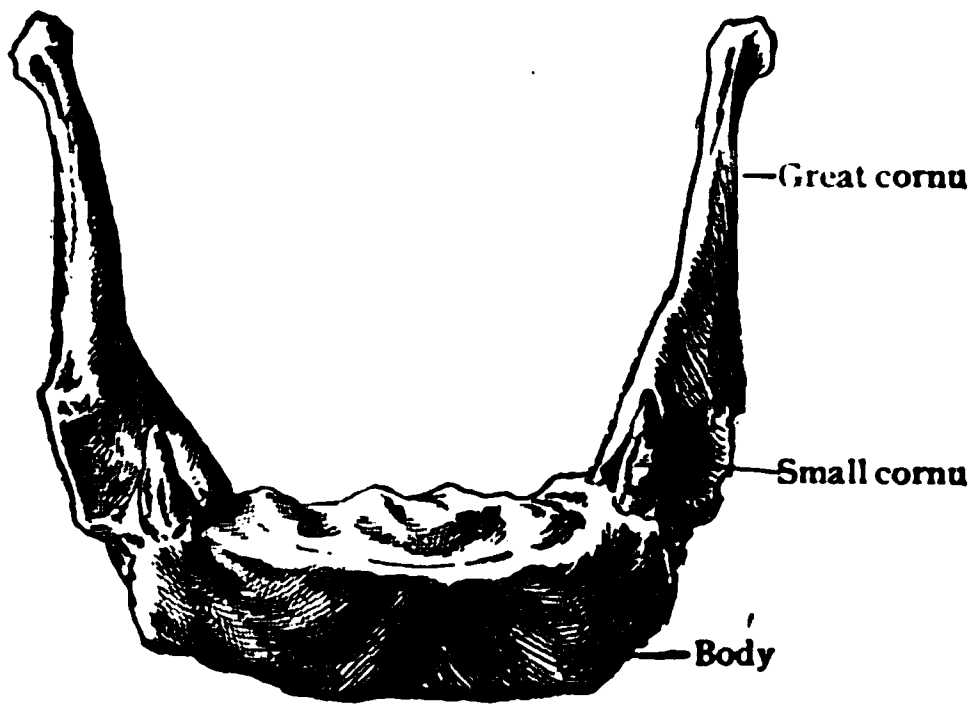

FIG. 212.—The hyoid bone, anterior view. (Piersol's Anatomy.)

ward, are at times cartilaginous, are shorter than the greater cornua, and are connected with the styloid processes of the temporal bones by the stylohyoid ligament.

Surface Markings.—The hyoid bone may be palpated throughout. Its position is directly behind the chin. The greater cornu is the landmark for the location of the origins of the superior thyroid, lingual, and facial arteries.

Statistics.—Gurlt's collected statistics of 27 cases showed in 21 cases fractures of the bone alone, and in the remaining cases there were associated fractures of the thyroid or cricoid cartilage or of the trachea. Of the 13 collected cases reported by Gibbs, 7 followed strangulation, 3 were the result of a blow or a fall, and 3 were due to muscular action.

Etiology.—Fractures of the hyoid, owing to its sheltered position, its elasticity and mobility, are extremely rare. Fractures are usually

the result of direct violence as from a blow or fall, pressure of the rope in hanging, or grasping the throat (Fig. 213) as in homicidal assaults. It has been broken as the result of muscular action. In fractures due to direct violence the break usually occurs near the junction of the greater horn. Those of the body itself are usually the result of a blow or a kick. Fractures of the lesser horn are extremely rare. In hyoid fracture there is generally considerable displacement of the fragments; and the injury may be associated with fracture of the laryngeal cartilages.

Symptoms.—The symptoms are localized pain, tenderness, and swelling in the region of the hyoid, pain on opening the mouth or on



FIG. 213.—Fracture of the hyoid bone. Occurred during the extraction of a molar tooth while the patient was under nitrous oxide anæsthesia. The dentist pressed on the hyoid bone with his hand. Patient complained of hoarseness, but there was no œdema present.

protruding the tongue, painful deglutition, difficulty in talking, dyspnœa, occasional œdema of the larynx with its accompanying symptoms, local ecchymosis, crepitus, abnormal mobility and displacement of fragments, and if the mucous membrane of the pharynx is lacerated, bleeding from the mouth. Sometimes the displaced fragment may be readily felt with the finger in the pharynx. Coughing, with paroxysms of choking or asphyxia, may follow attempts at swallowing or protruding the tongue.

...plications.—The complications of fracture of the hyoid are

accompanying injuries to the laryngeal cartilages, hemorrhage from pharyngeal vessels, œdema of the larynx, abscess, and necrosis of fragments.

Diagnosis.—The diagnosis can usually be made from the history of injury, the presence of crepitus, displacement of fragments, dyspnœa, and dysphagia.

Prognosis.—Simple, uncomplicated fracture of the hyoid should not be followed by untoward results. In the presence of laryngeal complications death may result from œdema of the glottis.

Treatment.—Reduction of displaced fragments is as readily accomplished as retention in their normal position is difficult. Replacement can generally be made by manipulation with a finger in the pharynx, combined with external pressure. The fragments may be retained in fair approximation by immobilization of the head and neck by extension and sand pillows, or by means of a stiff collar. Dyspnœa with development of œdema of the larynx will necessitate low tracheotomy, and dysphagia may necessitate the use of a stomach tube. Union of fragments in a deformed position or non-union may require excision of the displaced fragment.

CHAPTER IX

FRACTURES OF THE CARTILAGES OF THE LARYNX AND TRACHEA

Anatomy.—The larynx is in relation above with the hyoid bone, below with the trachea, and is opposite to the lower three cervical vertebræ. It is formed of three single cartilages, the thyroid, the cricoid and the epiglottis, and three or four pairs of smaller cartilages called the arytenoid, the corniculate, the cuneiform and the cartilagines triticeæ.

The thyroid is the largest of the laryngeal cartilages and is situated above the cricoid cartilage. It presents on each side an ala, and in the centre a notch formed by the union of the two alæ. On the posterior border of each surface there arise the superior and inferior cornua.

The cricoid is the lowest of the cartilages of the larynx and resembles a signet ring. It is connected with the thyroid by the crico-hyoid ligaments. The other cartilages are unimportant in relation to fractures.

Fractures of the Trachea—Anatomy.—The trachea or windpipe is situated in the anterior lower part of the neck. It lies in front of the œsophagus and extends downward from the lower border of the larynx to its termination in the bronchi, which is from the level of the sixth cervical to that of the fifth thoracic vertebra. It is formed by sixteen to twenty cartilaginous rings, which are open posteriorly for about one-third to one-fifth of their diameter and are joined to one another by the annular ligaments.

Surface Markings.—The thyroid cartilage of the larynx forms the so-called "Adam's apple," in the anterior part of the neck below the hyoid bone. It is most prominent in males, is entirely cartilaginous; and its body, borders and cornua can be readily palpated. The cricoid cartilage lies immediately below the thyroid cartilage, is seal-ring in shape, and can be readily felt with the fingers.

The trachea is situated just below the cricoid cartilage, and about one to one and a half inches of its upper end may be examined with the fingers. On marked extension of the neck another inch may be palpated. The rings of the second, third, and fourth cartilages are generally covered by the isthmus of the thyroid gland. The portion just above the sternum is situated rather deeply on account of the recession of the upper cervical and thoracic vertebræ.

Statistics.—Fractures of the larynx and trachea, owing to the exposed position of the larynx, are more frequent than fracture of the

hyoid bone. Hoffmann, who collected statistics of 145 cases, shows that in 122, in which the cause was given, 84 were the result of accident, 36 were due to suicidal attempt or homicidal violence, and 2 were the result of undue muscular action, such as coughing and blowing. Remer reports one case of fracture in 201 cases of hanging examined; and Hoffmann and Lesser found 16 cases of fracture in 50 cases of suicidal hanging. The collected statistics of 67 cases reported by Stimson showed isolated fracture of the thyroid in 24 cases with 18 deaths; of the cricoid in 11 cases with 11 deaths; of the thyroid and hyoid, 5 cases with 3 deaths; of the thyroid and cricoid, 9 cases with 9 deaths; of the thyroid, cricoid and hyoid, 2 cases with 2 deaths; of the thyroid, cricoid and trachea, 4 cases; of the cricoid and trachea, 2 cases with 2 deaths; with the cricoid, trachea and hyoid, 1 case with 1 death; of the larynx, 7 cases with 3 deaths; and of the trachea alone, 4 cases with 3 deaths. Hoffmann's recent statistics as to the sexual distribution shows that there were 64 men and 9 women; and of 54 of these cases 1 occurred during the first ten years, 9 during the second ten years, 10 during the third ten years, 15 during the fourth ten years, 9 during the fifth ten years, 7 during the sixth ten years, and 3 during the seventh ten years. In regard to the site of fracture, Hoffmann's statistics of 124 cases show that the thyroid cartilage was the seat of fracture 63 times, the cricoid cartilage 17 times, the arytenoid cartilage once, and in 43 instances there were fractures of several cartilages or of the hyoid and larynx.

Etiology.—The causes of fractures of the cartilages of the larynx and trachea are blows, falls, hanging, homicidal throttling, muscular action, and incised and gunshot wounds. Fractures are generally produced by lateral compression or by anterior pressure directed backward toward the vertebral column. Fractures of the thyroid are usually vertical near the median line, if produced by lateral pressure; the lines of fracture, however, may be longitudinal, irregular, comminuted, or transverse. Fracture of the cricoid is generally bilateral, and a single fracture in the median line is rare. Fractures of the arytenoids are generally seen in conjunction with fractures of other cartilages.

Fractures of the trachea are extremely rare and often they go unrecognized before death. Brigel has reported 33 cases and Hoffmann has added 12 more cases. The causes of fractures of the trachea are generally the same as those of fracture of the larynx. In addition may be mentioned over-stretching of the trachea, and compression of the upper part of the chest. In Hoffmann's reported statistics children were affected in 13 cases, and in 17 cases the fractures were associated with fracture of the larynx or of the hyoid, and there were complicating injuries of the ribs or sternum in 19 cases.

Symptoms.—The symptoms of fracture of the cartilages of the larynx are deformity, abnormal mobility, cartilage crepitus accompanied by a convulsive cough, alteration in or loss of voice, dyspnœa, dysphagia, often blood-streaked sputum, and in many cases emphysema extending over the neck, face and trunk. Interference with respiration may not be pronounced at first, but it is generally progressive, so that after a time here are stridor, cyanosis, marked dyspnœa and the development of a rapid pulse and all evidences of respiratory failure. The interference of respiration may be due to œdema of or hemorrhage into the mucous membrane, dislocation of fragments, or the closure of the calibre of the larynx or trachea by cellular emphysema. In severe cases death may be due to suffocation from subcutaneous hemorrhage, to free bleeding into the larynx, or to inflammatory or emphysematous swelling.

In fractures of the trachea the subjective symptoms differ little from those seen in fractures of the larynx. There may be, in addition, however, gurgling and tracheal râles, and marked dyspnœa in the beginning. The classical symptoms of fracture, crepitus and abnormal mobility, are generally impossible of demonstration.

Complications.—The complications of fracture of the cartilages of the larynx and trachea are œdema and intra- and perilaryngeal and tracheal hemorrhage.

Diagnosis.—The diagnosis of fractures of the cartilages of the larynx can generally be made by the history of the case, the evidences of external injury, and the results of laryngoscopic examination. In the early stages there may be œdema, or hemorrhagic extravasation, circumscribed or diffuse, discovered by laryngoscopic examination. If these conditions are excessive it may be impossible to make a thorough examination.

In fractures of the trachea the diagnosis will be determined largely by the presence of associated injuries to the larynx and the intrathoracic symptoms of compression.

Prognosis.—In all fractures of the cartilages of the larynx and trachea the prognosis is very grave, although not so grave as formerly was supposed. This is shown by the statistics of Hoffmann. Of the 75 reported cases prior to 1879 there were 16 recoveries and 59 deaths; of the 70 cases since that year there were 40 recoveries and 26 deaths. In many of the fatal cases death may occur soon after the accident, but it may be delayed for several days. Death in nearly all cases is due to œdema of the glottis, to the displacement of fragments, to the inspiration of blood, to mediastinal emphysema, or to secondary hemorrhage. Other causes of death are septicæmia and aspiration pneumonia.

Treatment.—The primary indication in treatment of laryngeal [illegible] is to maintain a free current of air to and from the lungs.

For this purpose tracheotomy is necessary in a large majority of cases. If there is any evidence of œdema of the glottis or intralaryngeal hemorrhage, or a tendency to displacement of fragments, or to dyspnœa or emphysema, a tracheotomy should be performed. The onset of partial or complete obstruction may be very sudden, and unless measures are at hand to promptly perform a tracheotomy, death will occur before relief can be given. Some authorities even go so far as to state that a tracheotomy should be performed as soon as a diagnosis has been made. If, however, there are no distressing symptoms, if the patient is in a hospital and has the constant attendance of a surgeon with all the necessary instruments at hand, a tracheotomy may be delayed. In addition to the above procedure one should endeavor to keep the patient quiet, replacing fragments when possible, keeping the parts aseptic, and preventing subsequent hemorrhage. We do not recommend the division of the larynx in the median line and the packing of the larynx with gauze as advised by Wagner, or the use of a glass cannula as recommended by Mikulicz. The performance of tracheotomy and use of opiates should be the primary course of treatment. Later indications for surgical intervention should be met as they arise. In fractures of the trachea, tracheotomy is always indicated and a tube large enough to go beyond the seat of fracture should be used.

CHAPTER X

FRACTURES OF THE VERTEBRÆ

Anatomy.—The vertebral or spinal column (Fig. 214), composed of a series of vertebræ, is the central part of the skeleton, and is in the median line posteriorly. It supports the head above, the ribs on each side, and, through the latter, the upper extremities. It transmits the weight of the body through the pelvic bones to the lower extremities. It surrounds the spinal cord and affords exits for the spinal nerves. The vertebral column consists of from 32 to 35 vertebræ; of these 24 are true vertebræ, and 8 to 11 false vertebræ. The true vertebræ may be divided as follows: 7 cervical, 12 dorsal or thoracic, and 5 lumbar vertebræ. The false vertebræ vary in number and form two bones, the sacrum and the coccyx. The typical vertebra is composed of a body, a neural arch behind, forming with the body the spinal foramen, and a number of processes. The neural arch is formed by two halves, and consists of two pedicles and two laminæ which support seven processes, four articular, two transverse and one spinous. The first and second cervical vertebræ differ from the remaining true vertebræ. The atlas or first cervical vertebra has no body or spinous process, is formed of a ventral and dorsal arch and two lateral masses. The body may be represented by the odontoid process of the axis. The axis or second cervical vertebra is characterized by a large, strong body and a large process arising from the superior surface of the body called the odontoid process. The atlas rotates around this process as a pivot and with it the head also rotates.

The sacrum is formed early in life of five segments, which later become fused to form one bone, the os sacrum. It articulates above with the fifth lumbar vertebra, below with the coccyx, and laterally with the two innominate or hip-bones, forming with the last the pelvic girdle.

The coccyx is composed of from three to five rudimentary vertebræ, fused together and tapering from above downward. In early life, especially in the female, they may be movable upon one another and upon the sacrum. Later in life, the joints between the coccygeal elements themselves and that between the first part of the coccyx and the sacrum become ankylosed.

On viewing the spinal column laterally, it will be noted that there are four curves. In the cervical and lumbar regions the curves are convex forward, in the thoracic and sacral regions the curves are convex backward. The thoracic and sacral curves are primary, are found in the embryo, and are for the accommodation of the thoracic and pelvic viscera. The cervical and lumbar curves, being compensatory,

are secondary and are developed later in life. The weakest part of the vertebral column is at the junction of the second and third cervical vertebræ. The vertebræ most subject to fracture, however, are from the tenth thoracic to the second lumbar vertebræ. This is because at that point the fixed thoracic part meets the most movable part of the lumbar region, great leverage takes place, and the lateral processes are not so marked as above and below.

FIG. 214.—Adult spine lateral view. (Piersol's Anatomy).

The vertebral column is completed by its ligamentous attachments and by the intervertebral disks situated between the bodies of the vertebræ. The ligaments are: The anterior longitudinal ligament, which begins at the pharyngeal tubercle at the base of the skull and terminates on the anterior surface of the sacrum. It is firmly attached to the anterior surface of the bodies of the vertebræ and intimately connected with the intervertebral fibrocartilages and laterally with the periosteum of the bodies.

The posterior longitudinal ligament begins at the second cervical vertebra and terminates in the sacral canal. It is attached to the posterior surfaces of the bodies of the vertebræ.

The second group of ligaments connect adjoining vertebræ to each other, and may be divided into those connecting the arches and those joining the processes. They are the following: ligamenta flava between the vertebral arches; intertransverse ligaments, connecting the transverse processes of the vertebræ; interspinous ligaments, connecting the spinous processes of contiguous vertebræ; supraspinous ligaments connecting the apices of the spinous processes; ligamentum nuchæ running from the spinous process of the seventh cervical vertebra to the external occipital protuberance.

The articulation of the sacrum with the coccyx is formed by the anterior sacrococcygeal, the lateral sacrococcygeal, the posterior coccygeal, the superficial posterior sacrococcygeal and deep sacrococcygeal ligaments.

One of the most important ligaments of the spinal column is the transverse ligament of the atlas which divides the spinal foramen of the atlas in two portions, surrounding the odontoid process of the axis posteriorly and allowing space behind for the spinal cord.

Surface Markings.—Extending in the middle line of the back from the skull downward to the sacrum there is a furrow, well marked in muscular individuals. Above it is called the nuchal furrow, below the spinal furrow. The spinous processes may be felt at the bottom of this furrow from the atlas to the sacrum. In thin persons there is no furrow, but a ridge running down the centre of the back due to the successive spinous processes. The dorsal and lumbar spines are more readily palpable on marked flexion of the spine. Normally there are four anteroposterior curves—the cervical and lumbar are convex forward, the thoracic and sacral are concave forward. Normally there are no lateral curves to the spinal column. The position of the posterior superior spine of the ilium on each side of the lumbar region of

FIG. 215.

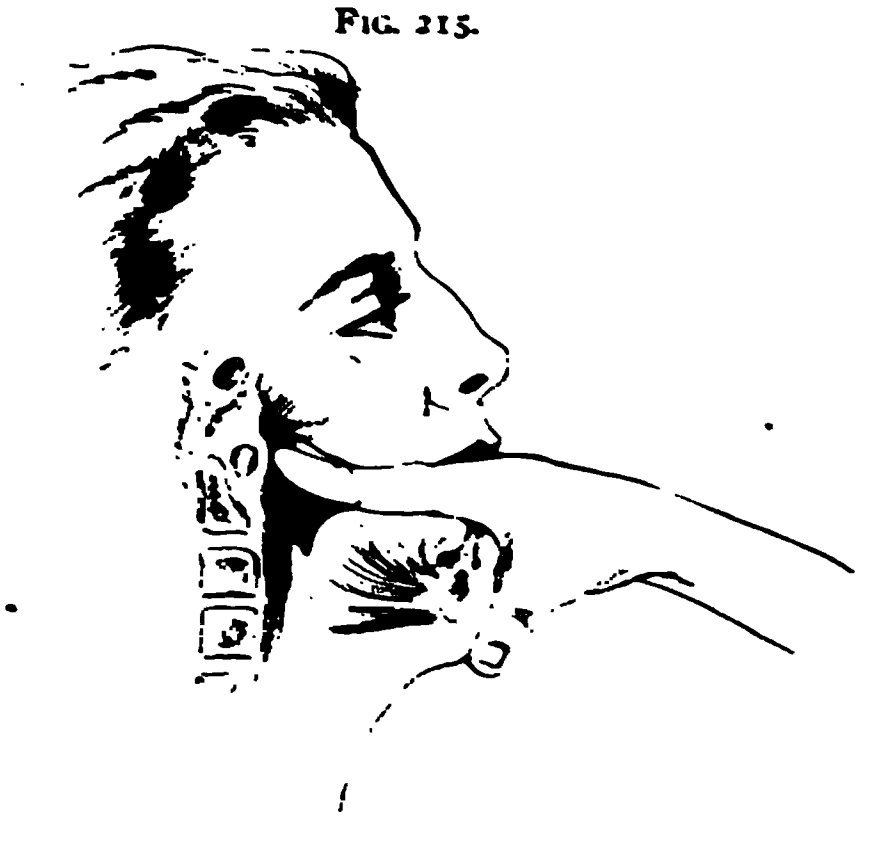

FIG. 216.



FIGS. 215 AND 216.—Method of palpation through the mouth of the anterior surface of the bodies of the upper cervical vertebræ. (Modified after Cotton.)

the back is marked by a depression at a point just above and external to the third sacral vertebra. The spines of the vertebræ may be used in locating various structures. The bodies of the first four cervical vertebræ may be palpated through the mouth (Figs. 215 and 216), and the bodies of the lumber vertebræ may be palpated through the abdomen in very thin or emaciated individuals, and the coccyx through the anus (Fig. 217).

Statistics.—Berghausen, in a study of 130 cases of fracture of the spine, found the following to be the percentage of the vertebræ affected: cervical, third, 7 per cent.; cervical, sixth, 8 per cent.; dorsal, fourth and fifth, 9.5 per cent.; dorsal, tenth and eleventh, 11 per cent.; dorsal, twelfth, 25 per cent.; lumbar, first, 14 per cent. Ménard, in a study of 385 cases of fracture of the vertebræ, gives the location

of the fracture as follows: first dorsal, 12 cases; second dorsal, 10 cases; third dorsal, 8 cases; fourth dorsal, 9 cases; fifth dorsal, 15 cases; sixth dorsal, 10 cases; seventh dorsal, 10 cases; eighth dorsal, 20 cases; ninth dorsal, 25 cases; tenth dorsal, 32 cases; eleventh dorsal, 37 cases; twelfth dorsal, 80 cases; first lumbar, 78 cases; second lumbar, 23 cases; third lumbar, 6 cases; fourth lumbar, 7 cases; and fifth lumbar, 1 case.

Etiology.—Fractures of the spine are observed generally in men, in adult life, and especially in those whose occupation exposes them to such injuries as produce fracture of the vertebræ. Women are rarely affected, no cases of children under sixteen years have been found by us, and it is rarely seen in those of advanced life. Fractures are the result of direct or indirect force and rarely of muscular action. The most frequent cause of vertebral fracture is an indirect force which tends to produce hyperextension or hyperflexion of the spine's normal curves, most frequently hyperflexion. Such traumatism occurs in a fall upon the head or shoulders, a fall from a height upon the buttocks, a crush under a weight falling from above upon the head or shoulders, or being jammed under a low arch when sitting on a car or wagon. Fracture results because the limit of flexion or extension has been exceeded and the bony segments are crushed or lacerated by the force. The fracture in such instances usually occurs where a movable portion of the spine joins a more rigid portion, because it is at this point that the sudden check to movement occurs. Hence, clinical experience shows that fractures of the vertebræ are most frequent near the dorsolumbar junction and in the vicinity of the cervicodorsal region.

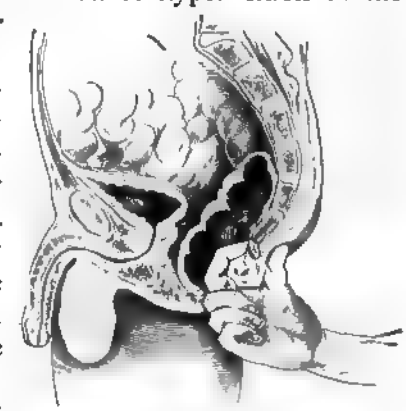

FIG. 217.—Method of palpation of the coccyx through the anus. (Modified after Cotton.)

Fractures occurring from direct violence are generally due to the striking of the back upon a projecting object, or to a falling object striking the back while the patient is stooping over. Fractures by muscular action are rare, but cases have been recorded in which this has occurred, as in diving. Most fractures received in diving are due to impact of the head on the bottom in shallow waters acting as do falls on the head or shoulders. The sudden throwing back of the head in order to avoid a shallow bottom has been ascribed as sufficient to cause fracture with dislocation of the cervical vertebræ. Wrestling has been the cause of spinal fracture or dislocation by over-flexion or over-extension at the hands of an opponent.

The bodies of the vertebræ seem to be involved more frequently in the lower than in the upper region, while the arches are more frequently fractured in the cervical region than elsewhere. Fracture of the spinous processes occurs most often in the dorsal region. The lines of fracture and the number of vertebræ involved depend upon the direction and the degree of the force.

Fracture is often accompanied by dislocation, and in many cases the two conditions are indistinguishable except at autopsy. Fracture of two or more vertebræ is common in the cervical and upper dorsal regions, less common in the lower dorsal and rare in the lumbar region.

FIG. 218. FIG. 219.

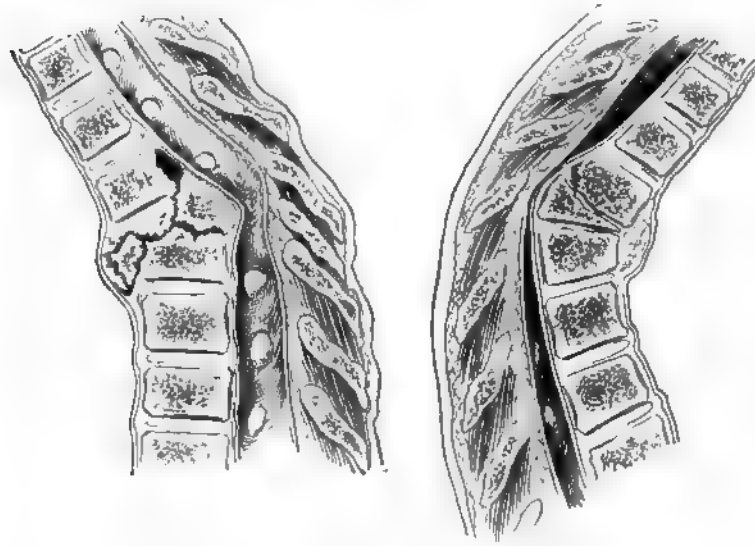

FIG. 218.—Compression fracture of the body of the fourth dorsal vertebra (Kocher).
FIG. 219.—Fracture-dislocation of the fourth and fifth dorsal vertebræ (Kocher).

Varieties of Fracture.—Kocher describes the following varieties of vertebral fracture: isolated fracture of the bodies; isolated fracture of arches, spinous processes and transverse processes; and fracture-dislocations.

Isolated Fracture of the Bodies of the Vertebræ (Figs. 218–224). —These fractures are always the result of compression. They are produced by a force acting in the long axis of the spine, in those portions of the column which have a supporting function, namely, the anterior column of the vertebral bodies, the intervertebral disks, and the double column of articular processes. When a compressing force is acting in the longitudinal axes of the spine, there results, first, shortening of the articulation processes behind, flexion and compression of the vertebral bodies and intervertebral disks until the limit

of their elasticity is reached, when compression fracture of the bodies of the vertebræ occurs, and, in addition, fractures of the intervertebral disks. Compression fractures are found most often where the flexibility of the spine is the least. In the cervical region flexibility is the greatest and in the dorsal and upper lumbar regions it is very limited. In the region where flexibility is greatest the intervertebral disks are found to be relatively thickest in comparison with the thickness of the vertebral bodies. The relative thickness of the disks is greatest in the cervical region; and the thickness of both bodies and disks increases from above downward. Compression fractures of the bodies of the

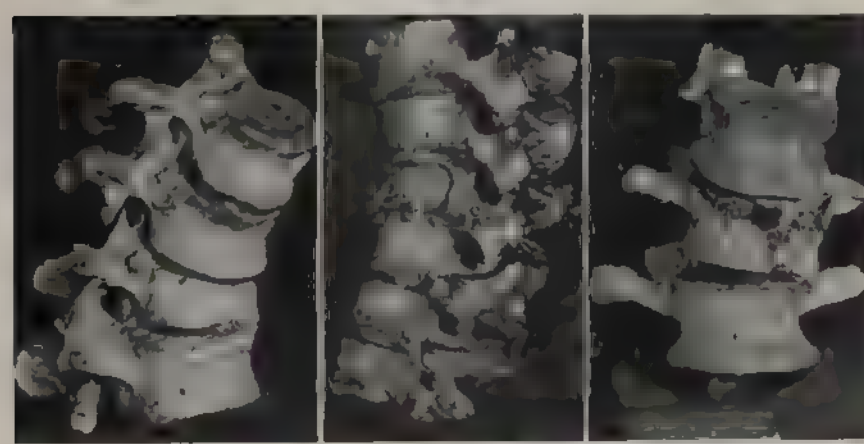

FIG. 220. FIG. 221 FIG. 222

FIG. 220. Last three dorsal and first lumbar vertebræ. Fracture of the body of the twelfth dorsal. The body of the twelfth dorsal is crushed by pressure from above. The anterior border of the superior articulating surface is destroyed. From a man who was crushed by the fall of a bank of earth. The man died instantly upon being turned upon his face in the hospital. (Mütter Museum, No. 1188 30.)

FIG. 221. Ninth, tenth, eleventh and twelfth dorsal and first two lumbar vertebræ. Fracture of the last dorsal. Recent. The first lumbar is fractured by force vertically applied. The compact tissue of the body is forced forward and outward in sections, vertical fissures being seen at four places. The vertebral canal has been exposed on the left side and shows a fracture of the right lamina. (Mütter Museum, No. 1188 40.)

FIG. 222. Eleventh and twelfth dorsal and first lumbar vertebræ. Vertical facture of the twelfth dorsal and crescentic fracture of the upper and anterior lip of the first lumbar. Recent. The last dorsal is severely crushed. On the left the body is fissured transversely at the middle. The vertical force has fractured the first lumbar vertebra at the anterior margin. The patient did not survive the accident long. (Mütter Museum, No. 1188 20.)

vertebræ are most frequently seen in the dorsal and upper lumbar regions, and least frequently seen in the upper third of the dorsal and lower lumbar regions. Kocher found, in a study of 23 isolated fractures of the bodies of the vertebræ, that the lesion had occurred from the eighth to the twelfth dorsal vertebra, 11 times, and the lumbar vertebræ, 7 times; and that the twelfth dorsal and first lumbar vertebræ were involved 5 times.

In compression fractures of the bodies of the vertebræ, the bodies of one or more vertebræ are compressed or flattened out, the shape of the body is changed by the compressing force to a wedge-shaped

mass, the crushed portion of the body becomes more dense, and as the vertical diameter is diminished, the horizontal diameter is increased. In other less typical cases, fragments may be broken out of the upper anterior edge of the body, and are produced by the upward pressure of the anterior lower margin of the compressing vertebræ (anterior wedge fragments). In addition there is sometimes a crushing out posteriorly into the vertebral canal of fragments of bone (posterior wedge fragments). If the violence is severe or prolonged, dislocation of the articular processes may occur as a result of the compression and hyperflexion. In addition to the bony lesions there may be fracture



FIG. 223.—Old compression fracture of bodies of second, third and fourth cervical vertebræ. Woman, twenty-eight years of age, fell down, striking head, ten years previously.

of the intervertebral disks, and rupture of the posterior longitudinal ligament.

When flexion is combined with abduction, the crushing of the body may take place on one side more than on the other. As a result of the compression of the vertebræ there is a tilting up of the spinous process of the vertebræ above, so that there is a kyphosis produced in the dorsal region and obliteration of the curves in the lumbar region. When more than one vertebral body is involved, the kyphosis may be more marked or more rounded.

Isolated Fractures of the Arches, Spinous Processes and Transverse Processes of the Vertebræ (Figs. 225–228).—These fractures

are rare and when seen are generally the result of great direct violence, or are accompanied by dislocation.

Fractures by muscular action are rare, although a fracture of a spinous process the result of muscular action has been reported by Terrier. Fractures of the arches are generally the result of direct violence applied to the spinous processes; and the lamella of one or both sides may be fractured. The loose fragments may be driven into the cord or cause considerable pressure upon it. A fracturing force severe enough to fracture the arch may produce injury to several



FIG. 224.—Fracture of body of fifth cervical vertebra. Patient injured while turning a handspring, landing on head instead of on hands.

adjoining arches. Fractures of the arches are more common in the cervical region, and the atlas and axis are the vertebræ most frequently involved.

Isolated fractures of the spinous or transverse processes are most frequently seen in the dorsal region and are the result of direct violence. The separated process may be displaced anteriorly between two vertebræ and into the cord, although this condition is rare because the detached ligaments and muscles usually prevent any considerable displacement.

Fig. 225.

Fig. 226.

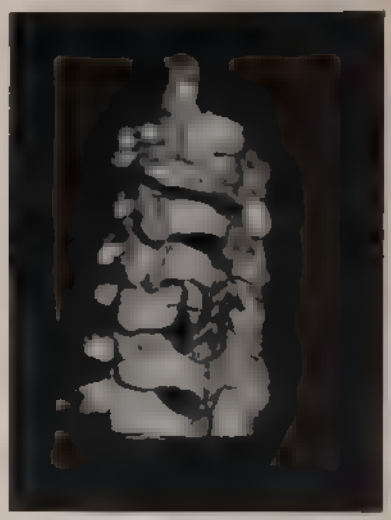

Fig. 225.—Diagram to show types of isolated fracture of the arches, spinous and transverse processes of the vertebræ.

Fig. 226.—Six lower cervical vertebræ. Fracture of the left lamina and pedicle of the fourth and of the laminæ of the fifth cervical vertebræ. Recent. The fracture of the fourth vertebra passes through the lamina through the articular surface and through the pedicle. The fifth vertebra is fractured through both laminæ, completely detaching the spinous process. A boat carrier, a man aged thirty-two years, fell on the round of a ladder. Death occurred six hours after the accident. Both respiration and heart action were laborred. The phrenic nerve was pressed on by a clot of blood; and the spinal cord at the level of the fourth cervical vertebra appeared congested. (Mütter Museum No. 1188.)

Fig. 227.

Fig. 228.



Fig. 227.—Compression fracture of fourth and fifth cervical vertebræ.
Fig. 228.—Fracture of lateral processes of the fifth and sixth cervical vertebræ, left side.

Fracture-Dislocation of the Vertebræ (Figs. 229–233).—Dislocation with fracture of the vertebræ occurs in many forms. In an exaggerated compression fracture of the body of a vertebra associated with dislocation, the compressed vertebra becomes wedge-shaped, the upper surface slanting, and dislocation of the above vertebra may take place downward and forward. This injury is generally produced by compression from above downward, combined with flexion. In dislocation combined with a diagonal fracture, the line of fracture may involve either the lower posterior portion of the dislocated vertebra, so that a portion of the fractured and dislocated body remains in its normal position, or it may involve not only the dislocated

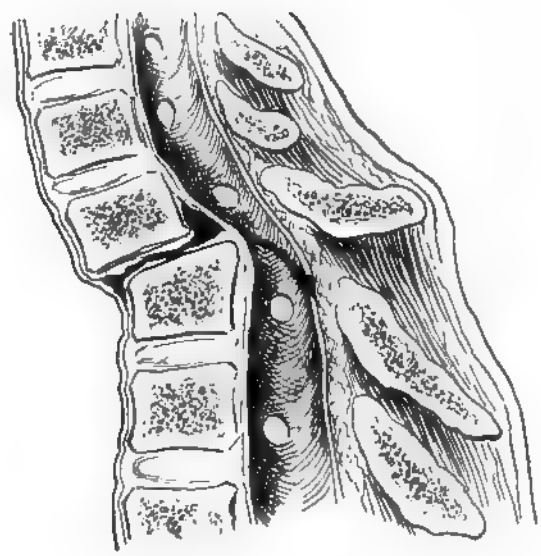

FIG. 229.—Dislocation of sixth cervical vertebra (Kocher).

vertebra, but also the anterior superior portion of the vertebra below, in which case the fragment of the lower vertebra is carried forward and downward along with the dislocated vertebræ and a part of the intervertebral disk. In this injury the line of fracture involves two vertebræ and extends from behind and above downward and forward: The displacement in fracture-dislocations is so great at times that the dislocated vertebra lies on the anterior surface of the vertebra below. Dislocation of the upper vertebra forward and downward, combined with fracture of the articular processes, sometimes takes place. This condition so closely resembles an ordinary forward dislocation without fracture that it is almost impossible to differentiate it clinically except by examination with X-rays.

Atypical deviations of the three mentioned forms of fracture-dislocation are very rare. Kocher describes two cases in which there were unilateral joint dislocations associated with fracture of the body in a downward and outward direction. Complete dislocation backward combined with fracture due to hyperextension of the neck has been reported; and Kocher and Wagner-Stolper mention cases of backward dislocation with fracture in the dorsal region.

Kocher believes that there are three forms of force operating in

FIG. 230.

FIG. 231.

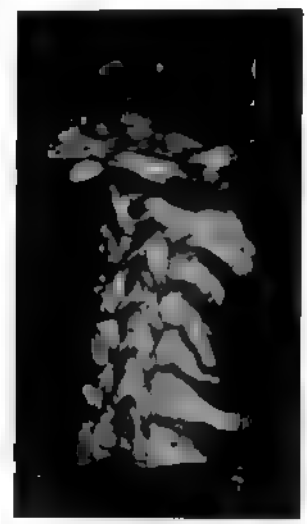

FIG. 230.—The lower dorsal and four upper lumbar vertebræ with portions of the three lower ribs of both sides. Fracture of the twelfth dorsal and first lumbar vertebræ. Partial repair. The bodies of the two fractured vertebræ are compressed and have coalesced. The intervertebral disk between them has disappeared, and pressure has forced these vertebræ backwards, so as to obliterate the vertebral canal. The loss of substance anteriorly has allowed the column above to bend forwards 40 degrees. The vertebral column is fixed in this position by permanent callus. (Mütter Museum, No. 1188.10.)

FIG. 231. Cervical vertebræ, luxation of the atlas. The atlas has left its articulation with the axis and their axes vary 45 degrees. The transverse ligament and the ligament binding the first two vertebræ at the posterior portion of the canal were subjected to great violence. Removed from the body of a man who committed suicide by hanging. While recovering from an attack of *mania a potu*, he used a silk handkerchief around his neck and standing by a gas-pipe had, after attaching handkerchief, jumped up. He was found suspended by the neck, with his feet on the floor. Death ensued immediately. The spinal cord was completely severed. (Mütter Museum, No. 1187.)

these fracture-dislocations: compressions from above downward, hyperflexion, and direct force. To produce the injury, one or all of them may be acting. He considers that this accounts for the relative frequency of dislocation with diagonal fractures in the dorsal region, because compression acting upon a normally flexed portion of the spine increases the flexion. They are rare in the lower dorsal and lumbar region on account of the normal lordosis, whereas isolated compression fractures of the bodies of the vertebræ and dislocation-compression fractures are more common in this region.

Of especial importance are the fracture-dislocations occurring in the two upper cervical vertebræ. Fractures of the atlas may occur in its anterior or posterior arches, with or without dislocation of the anterior fragment and the head. Displacement generally takes place in all cases and is always forward. In fracture of the odontoid process of the axis, the process may be carried forward with the atlas if the

FIG. 232.—Fracture-dislocation of fourth cervical vertebra. Symptoms: referred pain to base of neck, right side, some limitation of motion. No evidence of pressure symptoms. Recovery.

transverse ligament is not ruptured. Symptoms of pressure upon the cord do not take place unless dislocation occurs. These symptoms may be deferred for months, as in the six cases reported by Coste, Küster and Phillips.

Wood-Jones from an examination of five sets of vertebræ obtained from bodies the result of judicial hanging, in which the knot was

placed a little to the left of the chin, *i.e.*, a submental knot, has found a fracture-dislocation of the axis vertebra, consisting in a separation of the arch of the vertebra from the body. In these cases the odontoid process played no part in producing death, but the posterior arch of the axis was broken clean off and remained fixed to the third vertebra, while the atlas, the odontoid process, and anterior arch of the axis remained fixed to the skull. This lesion is produced by the violent jerk

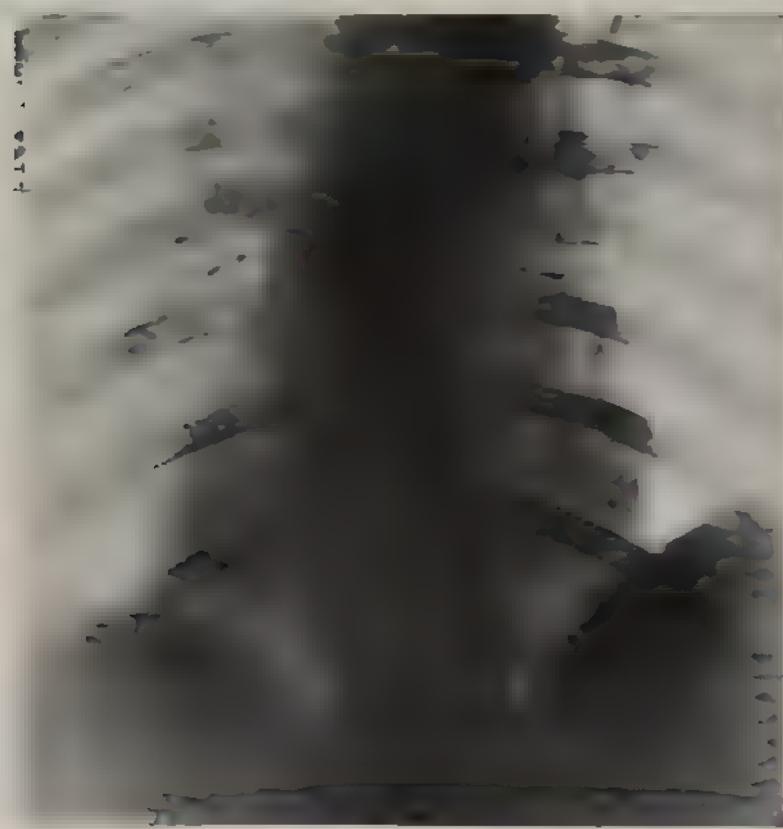

FIG. 233.—Fracture-dislocation of bodies of eighth and ninth thoracic vertebræ.

which throws the man's head suddenly backward and produces a fracture of the axis. In this series death was instantaneous, as the spinal cord was cleanly severed.

The usual form of dislocation fracture of the upper cervical vertebræ is due generally to a fall upon the head or the falling of a weight upon the head while the neck is in a flexed position. Direct violence in the back of the neck may rarely be the etiologic factor.

Symptoms.—Fractures of the vertebræ derive their chief importance from the damage done to the spinal cord and nerve-trunks, which

so often accompanies them. The spinal column may be said to have as functions: support to the trunk, upper extremities, and head; flexion, extension and rotation; and protection to the spinal cord which is essential to life and health. The symptoms may therefore be divided into *those associated with the fracture itself,* and *those due to injury to the spinal cord and nerve roots.* In addition there are certain special symptoms which may attend fractures at different levels.

The symptoms associated with the fracture itself may be described as follows:

SHOCK.—There is frequently a certain degree of shock present for a time after the accident. Intelligence is, however, unimpaired, except, perhaps, during the initial stage of shock.

DEFORMITY.—There is often in vertebral fractures no noticeable deformity. In most cases, however, there is deformity present. This is dependent upon the site of fracture, upon the form of fracture and also upon the presence or absence of dislocation. In fractures in the cervical and lumbar regions the normal concavity is decreased, obliterated, or replaced by a kyphosis, while in the dorsal region the normal convexity may be increased or sharply accentuated at or near the seat of fracture. The most common type of deformity in the latter region is a marked kyphosis, caused by the spine of the vertebra above the one fractured, or if associated with a dislocation by the vertebra broken. An obliteration of the normal cervical or lumbar concavity or an accentuation of the dorsal convexity in cases of fracture usually points to a compression fracture alone or to a diagonal fracture of one or two vertebræ with or without a dislocation. The site of injury may be recognized by the prominence of the spinous processes. In fracture-dislocations of the upper four cervical vertebræ the deformity may best be recognized by palpation through the pharynx. In isolated fractures of the spinous or transverse processes or arches, there may be no deformity unless the fracture is accompanied by a dislocation of fragments. In this case there may be lateral deviation of the spinous processes.

MUSCULAR SPASM.—The muscles about the seat of fracture are generally at first in a state of rigidity, and attempts at movement usually increase this rigidity, so that fixation of the neck or back occurs at the seat of injury.

PAIN.—This is generally present at the seat of fracture. It is increased by movement, active or passive, and by local pressure. It may be absent.

SWELLING.—Near the seat of fracture there may be found some swelling and after a few days this may be accompanied by ecchymosis. These symptoms are, however, variable.

MOBILITY.—Unusual mobility may be observed at times, especially in fractures of the cervical region, and occasionally movable regions may become more or less immobile, due to spastic contracture of the muscles at the seat of fracture or because of the interlocking of dislocated fragments.

CREPITUS.—This may be present, absent, or only discernible by the patient. In fractures of the spinous process, crepitus can generally be readily elicited. In other forms of fracture, movements to obtain crepitus should not be attempted, as such motions may further increase the dislocation of fragments and cause injury to the spinal cord.

Symptoms Due to Injury of the Spinal Cord and Nerve-roots.—Of far greater importance than the damage to the vertebræ themselves is the injury to the spinal cord and nerve-roots. These lesions may be the result of the fracture or dislocation of the vertebræ, of puncture by fragments, of hemorrhage about or into the spinal cord or nerve-roots, of effusion about the cord, and later of pressure from callus formation or degenerative changes in the cord itself. The symptoms are dependent upon the extent and position of the injury. The symptoms present generally indicate the height and nature of the lesion (Fig. 234). The important symptoms may be grouped under disturbances of motion, of sensation, of reflexes, and vasomotor and trophic changes. The posture assumed by the patient in bed is often of great importance.

POSTURE OF PATIENT IN BED.—The posture of the patient in bed after injury to the spinal cord varies with the location of the injury. This is due to the fact that the muscles controlled at or below the lesion will be paralyzed, and those controlled by the cells just above the lesion will be in a state of contraction due to the irritation into which their motor centres are thrown. If two centres of opposing action are involved, the stronger will be the predominant one, so that a position once assumed will be fixed and cannot be overcome involuntarily. The positions assumed in various lesions are as follows:

Fifth Cervical Segment.—All motion is impossible, the arms are extended and relaxed.

Sixth Cervical Segment.—Arms abducted, forearms supinated, wrists and fingers paralyzed (Fig. 235).

Seventh Cervical Segment.—Forearms partially flexed, lie upon the body, hands pronated. Voluntary movements at wrist impossible; movements of shoulder and elbow can be made (Fig. 236).

First Dorsal Segment.—Hands in position resemble a claw (***main en griffe***); shoulders and elbows freely movable.

Second to Twelfth Dorsal Segments.—Paralysis of lower extremities, no tendency to foot-drop, moderate resistance of the lower limbs to passive motion, tendon reflexes are exaggerated and muscles mod-

erately rigid, unless there is complete destruction of the cord, when the muscles will be relaxed and tendon reflexes lost.

Entire Lumbar Segments.—Thighs, legs and feet extended, and voluntary movement impossible.

Lower Half of Lumbar Segments.—Thighs drawn up, legs flexed, unable to straighten legs or lift foot.

FIG. 235.

FIG. 236.

FIG. 235.—Position in lesion of spine between the fifth and sixth cervical vertebræ. The elbows are fixed and [illegible] (After Thorburn.) FIG. 236.—Position in lesion of the sixth and seventh cervical vertebræ. The centre for the [illegible] (After [illegible])

Sacral Segments.—Feet in extended position [illegible] unable to move feet or ankles, thighs and knees may be voluntarily moved.

MOTOR PARALYSIS.—In injury to the spinal cord due to fractures or dislocations, the cord may be partially or completely severed. When only partial lesions are present, the symptoms will be entirely different from those manifested in complete disintegration of the cord. When there is a complete transverse division or destruction of the cord, there is complete paralysis below the level of the lesion, the limbs will

be relaxed and flaccid, the paralysis symmetrical on both sides, and there will be complete loss of all tendon reflexes. In partial lesions of the cord there may be total paralysis below the level of the injury, with a condition of rigidity of the lower limbs and an increase of the tendon reflexes. When the cord sustains damage on one side only, hemiplegia of that side occurs. When the injury is bilateral, paraplegia occurs, and when the nerve-roots only are involved, the paraplegia is limited to

Fig. 237 Fig. 238.

Fig. 237.—Anæsthesia resulting from a lesion of the fifth cervical segment (Starr).
Fig. 238.—Area of anæsthesia in a lesion involving the sixth cervical segment on the right and the fifth cervical segment on the left. (After Starr.)

the muscles supplied by those nerves. The degree of paralysis may increase as the cord becomes involved in secondary degenerative processes extending upwards, or it may diminish as the pathological process in the cord improves.

In locating a fracture by the height of the paralysis, it should be recollected that the nerve-roots and branches run obliquely downward within the vertebral canal and do not escape at the intervertebral opening corresponding to their points of origin from the medulla. The

diagram (Fig. 234) of Dejerine shows the usual relation between the various segments of the cord, the points of exit of the nerve-roots and spines and bodies of the vertebræ.

Sensory Paralysis. The degree and character of sensory paralysis are dependent upon the presence of complete transverse lesions, of partial lesions, and of injury to nerve-roots. Any destruction of the sensory areas in the cord will be followed by the loss of sensation—anæsthesia—which may be divided into tactile anæsthesia, analgesia,

Fig. 239. Fig. 240.

Fig. 239. Anæsthesia produced by a lesion of the seventh cervical segment. Hyperæsthesia is shown by dotted area. (After Herter.)

Fig. 240. Anæsthesia produced by a lesion of the first dorsal segment. Hyperæsthesia is shown by dotted area. (After Bruns.)

thermo-anæsthesia and loss of muscular sense or imperfect co-ordination. Lesions of sensory roots will involve all of these sensory phenomena, whereas lesions of the cord itself, owing to the different courses pursued by the sensory nerve-fibres, make it possible for one form of sensation to be lost, while others are preserved. This accounts for the irregularity of distribution of the various forms of anæsthesia in partial lesions of the cord (Figs. 237–256).

In complete transverse lesions of the cord there is complete transverse anæsthesia of the body below the segment which is destroyed.

The location of the lesion in the cord may be accurately determined by localizing the area of anæsthesia. It must be remembered that the exit of the nerve-roots takes place, not at their points of emergence from the cord, but at a lower level as shown in Figs 243 and 244. Chipault gives the following rules for determining the relation of the segments to the spinous processes of the vertebræ: "In the cervical

FIG 241. FIG 242.

FIG. 241.—Areas of anæsthesia in fracture of the spine involving the sixth and seventh cervical vertebræ. The lesion is just below the centre for the subscapular muscle. (After Thorburn.)
FIG. 242.—Right-sided anæsthesia due to lesion of the fifth cervical segment, and left-sided anæsthesia due to a lesion of the first dorsal segment. Note the distribution of the anæsthesia on the inner surface of the left arm. (After Wichmann.)

region add one to the number of the vertebræ, and this will give the segment opposite to it. In the upper dorsal region add two; from the sixth to the eleventh dorsal vertebræ add three. The lower part of the eleventh dorsal spinous process and the space below it are opposite to the lower three lumbar segments. The twelfth dorsal spinous process and the surface below it are opposite the sacral segments."

The spinal cord terminates at the lower surface of the first lumbar

vertebra. The remaining part of the spinal canal is occupied by the cauda equina.

Cushing, in commenting upon the fact that lesions are found at a higher level than the area of anæsthesia, states that: "This is explained by the investigations of Sherrington, who found that the cutaneous area belonging to each spinal segment so overlaps those of the neighboring segments, and that the cutaneous branches of the posterior primary division of the spinal nerves anastomose so freely with each

FIG. 243. FIG. 244.

FIGS. 243 AND 244. Anæsthesia produced by a lesion of the eleventh dorsal segment. Anterior and posterior views. After Wichmann.)

other, that in no instance does a single segment or root wholly supply a given area of skin (or a single muscle as well), but at least three (and Bruns says five) of them participate. Hence the upper border of anæsthesia points to a lesion of the next higher, or perhaps the second higher, segment than that represented by the level of anæsthesia. As the zone or area supplied by the upper of the affected segments is also supplied by the segment, or perhaps the two segments above it, this is not anæsthetic, but may be the seat of dimin-

ished or uncertain sensations or hyperæsthesia. The lowest level of the intraspinal lesion corresponds to the highest level of the sensory disturbance."

In complete lesions of the cord there may be irregular areas of anæsthesia, and there may be diminished sensation or hyperæsthesia. In addition there may be darting pains felt in the limbs when the partially paralyzed extremities are moved. The occurrence of such pains is, under some circumstances, a sign of returning innervation, and, therefore, a sign of improvement. In partial lesions the area of anæsthesia may be oblique, indicating an oblique lesion of the cord or a localized injury due to the pressure of fragments of bone.

Above the area of anæsthesia there is generally hyperæsthesia, while between the two there may be analgesia and thermal anæsthesia. This is due to the distribution of nerve-centres and often to the presence of a hemorrhage within the cord, to a subsequent inflammatory process that may intensify the disintegration, or to the formation of an extensive cicatrix. In unilateral lesions it will usually be found that there are tactile anæsthesia, analgesia, thermoanalgesia on the side of the body opposite the lesion, together with some hyperæsthesia of all of these sensations on the same side of the body as the lesion.

FIG. 245.—Area of anæsthesia following injury to the seventh dorsal segment. The area is higher posteriorly, as shown. (After Wichmann.)

DISTURBANCES OF REFLEXES.—This is a symptom of very great importance in injury to the spinal cord. The majority of the reflexes are known to have mechanisms in the spinal cord. These reflexes may be classified as:

The Deep or Tendon Reflexes.—A loss of tendon reflex implies a destruction of sensory nerves, or of sensory reflex fibres in the cord, or of the motor mechanism. If it is possible to exclude a lesion of a nerve-trunk, the loss of a reflex implies a lesion of the spinal cord. The knee-jerk is lost in complete transverse lesions, and is diminished in partial lesions and in lesions of the second, third and fourth lumbar

segments. The complete loss of the knee-jerk is generally a positive indication of complete destruction of the cord, and the persistence of its absence is always very significant of complete destruction. The knee-jerk may be exaggerated in partial lesions and in recovery from the lesions of hæmatomyelia. Ankle-clonus usually accompanies exaggeration of the patellar reflex. The plantar reflex is lost in lesions involving the upper three sacral segments, and in lesions above these

FIG. 246. FIG. 247.

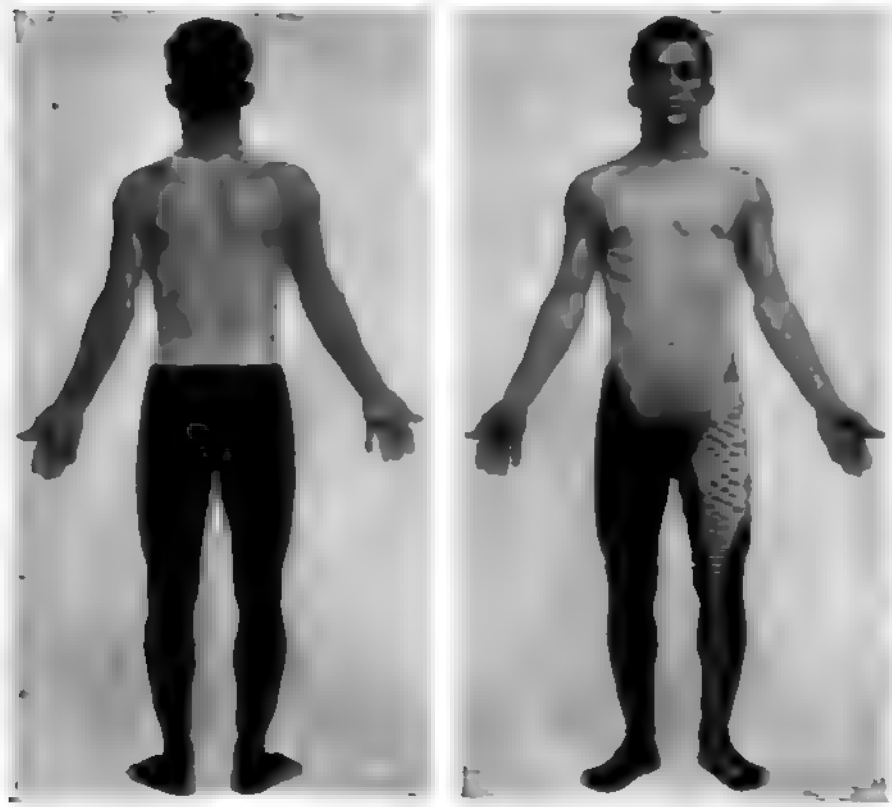

FIGS. 246 AND 247.—Area of anæsthesia produced by a lesion of the lower two lumbar segments on the left side and of the entire lumbar segment of the right side. Anterior and posterior views. After Starr and McBurney.

levels it is reversed and altered to the Babinski reflex. This latter generally is an indication of a lesion of the lateral column of the cord or in the motor tract.

The Superficial or Cutaneous Reflexes.—These are of such variable occurrence that their absence is of very little significance. The presence of these reflexes demonstrates that the reflex arc upon which it [illegible]. The superficial reflexes of most value [illegible], and plantar.

The Reflex Mechanisms Governing the Bladder and Rectum.—The centres controlling the mechanism of the bladder and rectum are located in the fourth and fifth sacral segment of the spinal cord Retention of urine is one of the most frequent symptoms of injury to the cord. It is due to paralysis of the detrusor urinæ muscle. In some cases the distention of the bladder overcomes the constrictive action of the sphincters and true incontinence occurs. In most cases, however, the incontinence is one of retention. In a few recorded cases rupture of the bladder has resulted on account of the strong constrictive action of the sphincter. In some cases there is a constant

FIG. 248. FIG. 249.

FIGS. 248 AND 249.—Anæsthesia following a lesion of the fifth lumbar segment. (After Eulenberg.)

dribbling of urine without distention. In cases in which catheterization has to be frequently performed, there usually results a cystitis with probably a subsequent pyelitis and nephritis. It is almost impossible to catheterize through months of life and not produce a cystitis, even though great care as to asepsis is given the withdrawal of urine.

In lesions of the cervical and dorsal segments tympanitic disten-

tion of the abdomen takes place with coincident constipation. This is later replaced by incontinence of fæces. The incontinence of fæces takes place without the sensation of having a bowel movement; control is absent, due to paralysis of the anal sphincter; when the stools are semi-liquid continuous evacuations are the rule. When the stools are formed, evacuation of the rectum may have to be accomplished by digital manipulation. Disturbance in the action of the bladder and rectum takes place in lesions at various levels and is not indicative of lesions of any particular segments.

Fig. [illegible]

Priapism is a common accompaniment of injury of the cord. It generally appears within the first forty-eight hours after the injury, and may last several weeks. As a rule it disappears within a week. It is seen most frequently in fractures of the dorsal and upper lumbar vertebræ. It seems to diminish in frequency as the injury occurs lower in the vertebral column, and is never seen in fractures below the second lumbar vertebra. Introduction of the catheter to relieve a distended bladder may produce an increase of the erection or cause a partial erection of none was previously present; seminal emissions are very rare.

[illegible] Trophic changes [illegible] fractures and [illegible] The presence of [illegible] control of nutritive changes has [illegible] known, however, [illegible] result from [illegible] segments. [illegible] generally accompanied by [illegible] disturbances. [illegible] trophic changes are [illegible] titis. The atrophy of muscles [illegible] use. This atrophy is most noticeable [illegible] Bed-sores occur most rapidly when there [illegible]

lieved by changes in position of the patient. They occur most frequently over the sacrum, over the great trochanters, upon the outer surface of the knees, and upon the heels, in other words, at the spots subject to continuous pressure while lying in bed. Their occurrence may be minimized by frequent changes in position, scrupulous cleanliness, bathing the skin and dusting it with such powders as zinc stearate, local rubbing with alcohol and alum, and by the substitution of the air- or water-bed for the ordinary mattress. Cystitis occurs rapidly after the introduction and continued use of the catheter. While it is doubtless true that the cystitis is due to the introduction of bacteria by the catheterization, the cystitis probably would not appear so soon in

FIG. 251 FIG. 252.

FIGS. 251 AND 252.—Show area of anæsthesia in fracture involving the fourth lumbar segment. (After Wichmann.)

normal bladders. Catheterization should be entrusted only to those attendants who realize the necessity for absolute cleanliness and conscientious asepsis.

The vasomotor disturbances are the result of angioparalysis or an angiospasm. In angioparalysis the arterioles dilate, the capillaries become distended with blood, and the parts are congested; clinically there is marked redness of the cutaneous or mucous surfaces. In angiospasm the arterioles are in a state of irritation or spasm; there is less blood to the part, the capillaries are constricted, and the parts are pale or blue, and have usually a mottled appearance. The vasomotor changes are controlled by the vasomotor nerves, which are a part of

the sympathetic system. In angioparalysis there is usually a local elevation of temperature, but in angiospasm the local temperature is subnormal.

Symptoms Associated with Lesions of Various Segments.—UPPER FOUR CERVICAL VERTEBRÆ.—Death may be sudden, from involvement of the vital centres in the medulla or from lesions of the centres of the phrenic nerves and consequent paralysis of respiration. Deformity

FIG. 253. FIG. 254.

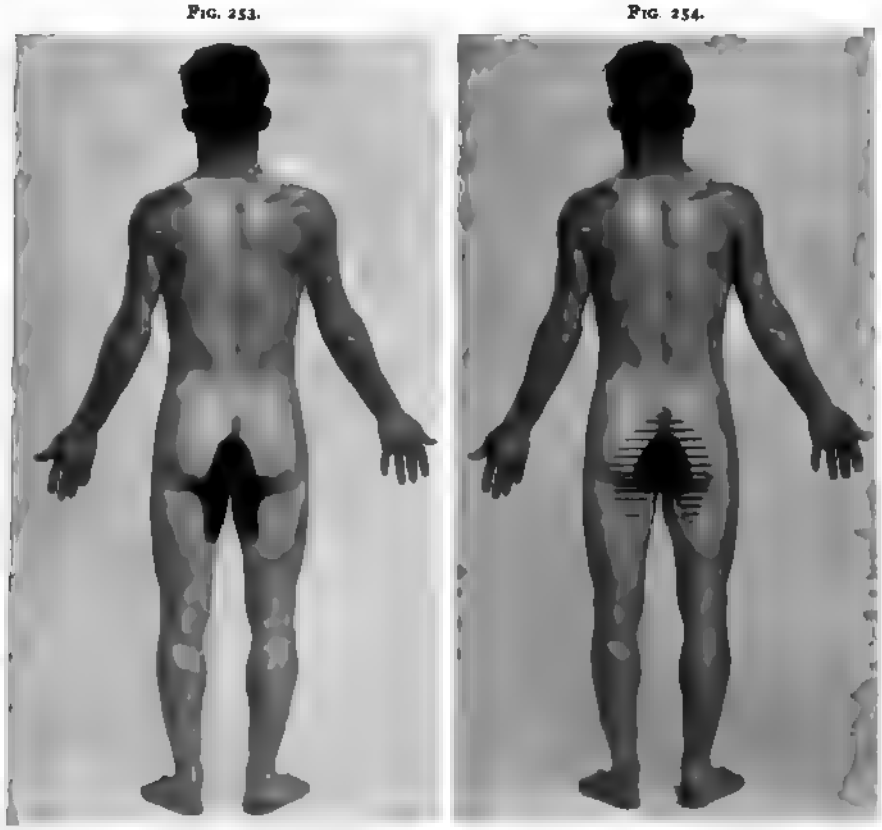

FIG. 253.—Anæsthesia following a lesion of the second sacral segment. (After Oppenheim, Huber and Starr.)

FIG. 254.—Anæsthesia following a lesion of the third sacral segment. (After Oppenheim, Huber and Starr.)

may be demonstrated by palpation of the posterior wall of the pharynx. In those cases which do not immediately die, there is usually a rapid pulse, low blood-pressure, high or subnormal temperature, pain along the course of the occipital nerves, pain on moving the head, which is held rigid, and sudden death may result from the manipulations during examination of the parts or from a slight jarring of the bed.

LOWER THREE CERVICAL AND FIRST DORSAL VERTEBRÆ.—Frac-

ture or dislocation of these vertebræ is the result of hyperflexion of the cervical spine, and a lesion of the cervical enlargement of the medulla may be produced. The symptoms of lesions involving the upper part of the cervical enlargement of the cord are to be differentiated from those seen in lesions of the lower part of the cervical enlargement.

Upper Part of Cervical Enlargement.—Pulse rapid, temperature high, blood-pressure high, paralysis of arms which are relaxed at the

FIG 255. FIG 256.

FIG. 255 Anæsthesia following a lesion of the fourth sacral segment. (After Oppenheim, Huber and Starr.)

FIG. 256 Anæsthesia due to compression of the cauda equina. (After Starr and Lloyd.)

patient's sides, anæsthesia below the deltoid area and over the shoulder-joint, pain in neck and shoulders, paralysis and exaggerated reflexes of lower extremities, retention of urine, paralysis of rectum, priapism, respiration diaphragmatic, trophic changes are rapid, unusual sweating of the entire body, and death within ten days or two weeks and often sooner.

Lower Part of Cervical Enlargement.—The position of the upper

extremities is more or less characteristic. There is partial paralysis of the arms, which generally are abducted, the forearms flexed, the hands resting on the chest. The position is due to absence of paralysis of the shoulder muscles and flexors of the forearms. The anæsthesia is more marked on the inner side of the arms and forearms and is total in the hands; it also affects the body, its upper limits being about the level of the nipples; above this there is hyperæsthesia, which extends to the outer surface of the shoulders and arms. There is paralysis of the body and lower extremities. The reflexes of the legs may be absent at first and later exaggerated. Pain is present in the outer surfaces of the shoulders, arms, and forearms. Priapism, retention of urine, and paralysis of the rectum are also present. When the lesion affects the first dorsal segment, there may be oculopupillary paralysis, contraction of the pupil, narrowing of the palpebral fissure, and retraction of the eyeball.

Dorsal Vertebræ.—In injury of the dorsal segments of the cord there will be paralysis of the abdominal and back muscles and of the lower extremities. Paralysis of bladder and rectum occurs, and anæsthesia about the trunk with an area of hyperæsthesia above it. The level of the anæsthesia is an indication of the site of the cord injury. Sherrington has shown that the level of the anæsthesia is not on a level with the lesion of the cord, but that it is from three to four inches below the level of the lesion. This is due to the overlapping or anastomosis of the sensory nerve filaments, and to the circumstance that the intercostal nerves of one segment supply the skin directly related to two or at times three adjacent segments of the cord. In addition the sensory fibres entering the cord ascend to two higher segments before terminating. Starr reports a case in which there was a lesion of the eighth dorsal segment in a fracture of the sixth dorsal vertebra, and the line of anæsthesia corresponded to the distribution of the tenth dorsal nerve, being three inches below the level of the injury. The area of hyperæsthesia above that of anæsthesia is due to the fact that centres above the segment injured are in a state of irritation.

In those cases in which there is not complete destruction of the cord, the patients often refer to this area of hyperæsthesia all sensations coming up from the legs. Starr considers that this symptom is of value in differentiating complete from partial lesions of the cord.

A combination of symptoms is occasionally present in lesions of one-half of the cord in the dorsal region to which has often been given the name of Brown-Séquard paralysis. These symptoms may, however, be present in unilateral lesions at other levels. The symptoms are: (*a*) on the side of the lesion: paralysis with rigidity, increased tendon reflexes, temporary elevation of temperature, diminished muscular sense in the leg, hyperæsthesia to touch, temperature and pain up

to the level of the lesion, a narrow zone of anæsthesia about the body to touch, temperature and pain; (*b*) on the side opposite to the lesion: absence of paralysis, slight increase of reflexes, anæsthesia to touch, temperature, and pain up to a line passing about the body about an inch lower than the zone of anæsthesia on the side of the lesion.

LOWER TWO DORSAL AND UPPER LUMBAR VERTEBRÆ.—Injuries to these vertebræ, as a rule, involve the lumbar enlargement of the cord. The lesion may involve the upper or lower part of the lumbar enlargement, or it may be limited to the conus terminalis or the lower three sacral segments.

Complete Transverse Lesion of the Upper Part of the Lumbar Enlargement.—Total paralysis of abdominal and thigh muscles, with flaccidity and atrophy, reaction of degeneration and a loss of superficial and deep reflexes, paralysis without atrophy or reaction of degeneration in muscles of legs and feet, the legs lie extended and flaccid, loss of bladder and rectal control, girdle sensations and anæsthesia as high as Poupart's ligament, and failure of contraction of abdominal muscles on compression of testicle (Kocher's reflex). When the lesion does not involve the upper two lumbar segments there may be an area of hyperæsthesia on the front of the thigh and anæsthesia may be confined to the area corresponding to the lumber segment below these two. Recovery, if it occurs, is attended with permanent paralysis of the thighs.

Complete Transverse Lesion of the Lower Part of the Lumbar Enlargement.—Paralysis is limited to the legs below the knees, and at times only the peronei group of muscles and feet are involved, atrophy of these muscles and reaction of degeneration, loss of bladder and rectal control due to relaxation of both sphincters; anæsthesia is generally limited to the posterior and outer aspect of the thigh, and outer part of the leg and foot, and, as Starr has noted, it may be limited to peculiar areas; the thighs and legs are flexed, the knee-jerks may or may not be present; ankle-clonus and toe-reflex are absent, and testicular sensation is preserved. Recovery in these cases makes locomotion possible, by application of suitable apparatus to hold the knees and ankles stiff and the use of crutches, because the thigh muscles are not paralyzed.

Lesions of the Conus Terminalis.—Loss of bladder and rectal control, loss of sexual power, and anæsthesia limited to the region of the anus and posterior part of the scrotum in the male and posterior half of the labia and perineum in the female; or the area of anæsthesia may be heart-shaped over the region of the sacrum.

LOWER FOUR LUMBAR VERTEBRÆ OF THE SACRUM.—Fracture of these vertebræ may produce compression of the cauda equina. The symptoms of these lesions may be similar to those of injuries of the

spinal cord itself, because the cauda equina is composed of nerve-roots coming from the lumbar enlargement. Fractures in this region do not always give the same symptoms of a complete transverse lesion of the lumbar enlargement, since many of the nerve-roots may escape injury. These nerve-roots have the power of regeneration. The symptoms are loss of bladder and rectal control, anæsthesia in a heart-shaped area over the sacral region, buttocks or posterior portion of the genital regions. The symptoms may show unequal distribution. Complete recovery is possible, by operation, after these injuries. Fractures may produce intense pain, radiating along the course of the nerves injured when the lesion is partial and the nerves are lacerated: the location of the pain may be on a higher level than the anæsthesia and is often a guide to the seat of fracture. These pains are generally referred to the peripheral termination of the compressed or lacerated nerves.

While the symptoms detailed above are those seen in complete transverse lesions at various levels, it is probable that in partial lesions the symptoms will be asymmetrical. The areas of anæsthesia and the extent of paralysis may vary on the two sides of the body, and the degree of paralysis and the height of anæsthesia may increase on account of an increasing area of degeneration or the spreading of a hemorrhage around or into the cord.

Hemorrhage in the Dura and Spinal Cord.—The blood may be extradural; it may be subdural (hæmatorrachis), or it may be in the substance of the spinal cord (hæmatomyelia). The symptoms of subdural hemorrhage are not always definite. They generally consist of pain, sharp and paroxysmal in character, along the spine and at times referred to the course of the nerve-trunks. These pains may be accompanied by muscular spasm, opisthotonos, convulsions and paraplegia, or by an irregular distribution of the paralysis. The paralysis rarely is sudden in onset, in most cases becomes complete after from four to six days, and persists for a period of several weeks to two months, when it gradually disappears. The suddenness of the onset of the symptoms is dependent upon the size of the vessel injured. Lumbar puncture will disclose hemorrhage into the spinal fluid. The source of the hemorrhage is usually from the venous plexus about the cord, and the amount of the hemorrhage is dependent upon the size of the vessel injured and its location. Injury to a vessel high up in the spinal canal probably will be accompanied by considerable hemorrhage, and which will be greater in amount than from vessels injured at a lower level.

The Symptoms of Hemorrhage Into the Spinal Cord Itself.—The usual site is in the region of the fourth, fifth and sixth cervical vertebræ and is considered by Thorburn to be due to hyperflexion of the

spine in this region. When the hemorrhage takes place in the white substance of the cord there occurs paraplegia below the segment involved. When a hemorrhage takes place in the gray substance of the cord there is partial wasting of muscles and anæsthesia of the upper extremities with loss of some reflexes. The onset of the symptoms is sudden, the prognosis often fatal, and in the cases in which recovery takes place there is always muscular weakness due to the destruction of the motor neurons.

Diagnosis.—It is not always easy to make a positive diagnosis of fracture of the vertebræ. In isolated fracture of the spinous or transverse processes without symptoms pointing to compression of the spinal cord, the diagnosis may be uncertain. Generally, however, there will be local pain and tenderness on pressure, some irregularity of the spines of the vertebræ affected, swelling of the soft parts, late ecchymosis and possibly the late appearance of symptoms of compression of the cord from pressure by a hæmatoma or exuberant callus. Crepitus and deformity, if they exist, are important points in diagnosis.

In fractures of the vertebræ accompanied by lesions of the spinal cord, it is often impossible to determine the extent of the fracture from the cord symptoms. The symptoms of injury to the cord may be slight in severe fractures, and vice versa. It may also be impossible to determine the extent of the cord injury at once; several days must elapse in some cases for the surgeon to be able to fully estimate the degree of injury and to determine whether the lesion is complete or partial. The patient should be radiographed as soon as possible, and the extent of fracture and the degree of displacement of fragments determined. In fracture associated with injury to the spinal cord, the important facts to be determined are the level of the cord lesion and the extent of compression or destruction of the cord that has occurred. The level of the lesion of the cord may be determined by comparing the muscles paralyzed and the levels of anæsthesia with the tables (Fig. 234). These show the relation of the segments of the injured cord, and of the roots and exits of the spinal nerves to the spinal vertebræ, the location for sensibility and motion, the segmental localization of the automatic centres and the superficial and deep reflexes of the spinal cord.

The determination of the degree of the lesion of the spinal cord is not always possible. When there is any sensation in the parts below the lesion, such as pain, tingling, numbness, and when change in position of the extremities or distention of the bladder is noticeable, the probabilities are that the lesion is not complete. When anæsthesia is apparently complete below the lesion, it is sometimes possible to cause sensation by deep picking with a needle; in these cases the sensation may be referred to the area of hyperæsthesia above that of anæsthesia.

This is not possible if the lesion is complete. If the lesion is total the patella reflex is permanently lost, the paralysis of the legs is flaccid, no rigidity is present on passive motion, and the line of anæsthesia is sharply defined. In partial lesions the tendon reflexes may be primarily lost, but they later return and may become exaggerated. In complete lesions the superficial and deep reflexes are lost, there are greater trophic and vasomotor changes, priapism is present, and there is complete loss of bladder and rectal control.

Prognosis.—In fracture of the vertebræ unaccompanied by injury to the spinal cord, the prognosis should be favorable not only for life, but also for ultimate restoration of health. The rarity of such condition without injury to the spinal cord is well known. In isolated fractures of the spinous or transverse processes, and in compression fractures of the body of the vertebræ of moderate degree without cord injury, the prognosis will depend upon the subsequent development of excessive callus, which may produce pressure, or upon the amount of angulation produced by the compression of the body of the vertebræ.

The prognosis of fractures of the vertebræ accompanied by injury to the spinal cord is not very favorable. It will depend in great measure upon the severity of the symptoms presented and the degree of the spinal cord lesion. Many patients die from myelitis, exhaustion of bed-sores and cystitis. Patients do at times recover, but usually with considerable disability from loss of power in the legs and imperfect control of the bladder and rectum. The lower the seat of fracture the better the chance of recovery, both as to life and function. In cases which finally prove fatal, life is the more prolonged as the site of fracture descends the spinal column. Repair of the spinal cord never occurs, and there is never any restoration of continuity of its nerve-fibres possible. The seat of the lesion is replaced by scar tissue. Lesions involving the spinal nerve-roots are capable of complete recovery and regeneration of nerve-tissue. These statements should be carefully considered when the radiograph shows the presence of bony pressure combined with symptoms of complete destruction of the cord. In partial lesions where the spinal cord is only slightly involved, or where only one or two motor or sensory tracts are involved, partial restoration of function may follow the operative relief of pressure. In cases in which the spinal lesion is an extra- or subdural hemorrhage or a bleeding into the cord itself, restoration of function will generally occur to a greater or less degree. Occasionally it may be complete. On this account great care should be taken to save the patient's strength, and particular attention should be given to the bladder and rectum and to the prevention of pressure sores.

Statistics.—Burrell reported 244 cases of fracture of the vertebræ with a mortality of 64.5 per cent. In the cervical region the mortality

was 85.7 per cent.; in the upper dorsal, 76.7 per cent.; in the lower dorsal, 56.1 per cent.; and in the lumbar region 50 per cent. Of the 35.5 per cent. of recoveries, 62.2 per cent. were useful, and 37.8 per cent. were useless. It may be stated that in a number of Burrell's third series there were no cord symptoms, so that the mortality of 48 of these cases was only 37.5 per cent.

STATISTICS

Lloyd, Samuel — Operated Cases

Cervical region:	Immediate operation	Later operation
Deaths	21	2
Recovery		2
Improved	2	1
Not improved		4
Subsequent death	4	3
	27	12

Lumbar region:	Immediate operation	Later operation
Deaths	4	4
Recovery	1	6
Improved		6
Not improved	1	6
Subsequent death		2
	6	22

Dorsal region:		
Deaths	23	5
Recovery	4	10
Improved	9	18
Not improved	6	16
Subsequent death	7	16
	49	65

Sacral region:		
Deaths		
Recovery		1
Improved		3
Not improved		
Subsequent death		
		4

Of these 185 operations there were only 12 improvements by immediate operation, and of the total there were only 24 recoveries and 40 improvements. The number of recoveries in 82 immediate operations was 5. With late operation there were 19 recoveries in 113 operations. The author states that from various statistics and from his own experience the immediate mortality is not small, and the recoveries without operation far exceed those with operation.

Chipault, in 1894, published the results of 167 patients operated upon for fractures of the vertebræ; of these 12 recovered and 24 improved.

Thorburn reported the results of 56 cases operated upon as follows: 38 deaths, 67.8 per cent.; 18 recovered from the injury; 2 recovered from cord symptoms; 16 showed little improvement.

John C. Oliver reports 57 fractures and dislocation of the vertebræ, 50 of which developed nerve symptoms, and 7 showed no special injury. Of these 57 cases the involved areas were as follows: cervical region, 23; dorsal, 18; lumbar, 10; dorsolumbar, 2; 4 cases not specified; deaths, 39 (68 per cent.). Of the 23 cervical cases, 22 died (95 per cent.). Of the 18 dorsal cases, 10 died (55 per cent.); 5 were discharged as improved and 3 as cured; recoveries 16.6 per cent. Of the

10 lumbar cases, 6 died, 1 was improved, and 3 remained unimproved, and there were no complete recoveries. Of the 2 dorsolumbar cases, 1 death (50 per cent.). Of the 4 in which the location was not specified, 2 died (50 per cent.). Only 50 of the cases showed nerve symptoms and 41 died (82 per cent. mortality). Of the 50 cases 8 were operated on; 6 died (75 per cent.); 2 were unchanged. Of the 8 operated on: cervical, 4—4 deaths (100 per cent.); dorsal, 2—1 death, 1 unchanged (50 per cent.); lumbar, 2—1 death, 1 unchanged (50 per cent.). Non-operated cases: mortality, cervical, 94.8 per cent.; dorsal, 72 per cent.; dorsolumbar, 50 per cent.; lumbar, 55.5 per cent.

Treatment.—All cases of suspected fracture of the vertebræ should be handled very carefully to prevent the production or the increasing of displacement of fragments and consequent injury of the spinal cord. The patient should be transported, examined, and moved about in bed with the greatest caution. Movements made to determine the presence of crepitus should be avoided.

Treatment will depend in a great measure upon the site of fracture, the portion of the vertebræ fractured, and the presence or absence of injury to the spinal cord. In fractures of the spinous process, laminæ or arches without symptoms of pressure on the spinal cord or displacement of the fragments, the treatment should consist in immobilization of the parts with a well-fitting plaster-of-Paris case. In compression fractures of the bodies of the vertebræ, in dislocation fractures without symptoms of injury to the cord, and in those cases in which there is deformity present at the seat of fracture, reduction of the fragments should be attempted by traction, combined with hyperextension and, after reduction, by the application of a plaster-of-Paris case. Hyperflexion is best obtained by horizontal suspension of the prone patient upon a suitable strip of stout muslin, and when the proper degree of hyperextension has been attained the plaster case should be applied.

When a complete transverse lesion of the cord is present, the expectant form of treatment must as a rule be followed. When there are symptoms of injury to the spinal cord, whether the patient is subjected to operative intervention or not, he should be placed upon an air- or water-bed. Every effort should be made to prevent the occurrence of pressure sores, and great care should be taken to keep the sheets dry, clean, free of wrinkles and bread crumbs. As soon as the sheet becomes moist, either from urine or fæces, it should be changed. The back, thighs, legs, and feet should be rubbed twice a day with alcohol and alum, and, if necessary, additional air rings may be placed under the sacrum and heels. When a pressure sore has developed, it should be kept dry and clean by the use of alcohol, dusting powders and dry dressings. All sloughs should be cut away as they develop. The

development of a cystitis usually follows the catheterization necessitated in retention due to paralysis. This is favored by the vasomotor and trophic changes which take place in the bladder walls as an accompaniment of the paralysis. If possible, catheterization should not be performed, but the urine should be allowed to overflow into a suitable urinal. In those cases which require catheterization, the bladder should be irrigated twice daily with boric acid solution (2 to 5 per cent.), and a small quantity of this solution should be left in the bladder. When cystitis develops, more frequent irrigations may be used. In all cases the patient should be given internally hexamethylenamin, 7 grains, three times daily. Suprapubic cystostomy for drainage is not recommended. Great care should be taken to keep the patients dry and clean after each movement of the bowels. As a rule the bowel movements are semi-liquid and frequent. It may be necessary to cleanse the rectum by means of enemata or at times to empty it, because of impaction, by means of a spoon. Tympanites may be lessened by the use of ice-bags, hot-water bottles, steeps, and eserin, 1/50 grains hypodermically.

Operative Treatment.—Indications for and against operative treatment:

(1) Operation is contraindicated in the presence of shock, or when high or subnormal temperature, and rapid pulse or respiration are present.

(2) When there is evidence of complete transverse destruction of the cord.

(3) Operation is indicated when the symptoms show partial destruction of the cord, compression from a blood clot or fragment of bone.

(4) It may be advisable to perform a delayed operation in apparently complete transverse lesions because the symptoms sometimes change and become less severe, showing that the primary symptoms were due to concussion or to extradural hemorrhage.

(5) If after two weeks improvement is present, operation is indicated.

(6) When the radiograph shows pressure from displaced fragments and the symptoms point to a partial lesion of the cord, immediate operation is indicated; when, however, the symptoms are those of complete destruction of the cord and the radiograph shows marked displacement of fragments, operation is useless.

(7) Operation is indicated in all lesions of the cauda equina or posterior nerve-roots. In these cases restoration of function should follow the operative restoration of continuity by suture.

(8) Operation is indicated when the symptoms point to extra- or subdural hemorrhage. In these instances the symptoms have a gradual

onset, the paralysis is incomplete, and the areas of anæsthesia are irregular.

(9) It may be argued that there are reported cases of complete destruction of the cord (Harte, Munro) in which restoration of function has taken place after operation. It is with this in mind that one is often prompted to operate on apparently hopeless cases. It may be said, however, that the operative mortality should be considered, that many cases show as much improvement without operation as with operation, and that it is only in those cases of apparently complete destruction of the cord which show improvement after several weeks that operation is indicated.

(10) With definite evidence of fracture or dislocation and complete bilateral circular paralysis of motion and sensation, operation is contraindicated.

(11) When the symptoms are those of compression by blood (extradural or subdural) without fracture or dislocation, do not operate. Perform lumbar puncture.

(12) When the symptoms are those of compression by blood and fragments of bone, in which the paralysis of motion and sensation is not complete, circular or immediate, immediate operation is indicated; and, especially, if the symptoms are persistent.

(13) Do not operate in the presence of severe shock.

(14) Late operation is indicated in those cases in which symptoms of pressure are progressive, or in which the pressure is evidently due to the growth of callus about the seat of fracture.

(15) Late operation should be performed when improvement has taken place in patients in whom symptoms of improvement are not progressive. When symptoms are retrogressive, operation is not indicated.

LAMINECTOMY.—*Technic.*—The details of this operation may be found in any of the books on operative surgery. As a general rule a median incision over the spinous processes at the site of fracture or kyphosis is the best. The muscles are separated from the vertebral column and retracted, and the laminæ exposed. Care should be taken not to press forward any of the fragments into the cord in removing fragments. These should be removed rather than elevated. Dislocation of the arches or fracture-dislocations are best reduced after the removal of several laminæ, so that one may see that no additional pressure is produced at the point of compression. The dura will usually be found to be not torn. It should always be opened. Any subdural clot should be removed. After reducing any displacement and removing fragments or blood clot, the dura should be closed without drainage with absorbable sutures and the wound of the soft parts sutured. It is useless to suture the cord when it has been completely crushed trans-

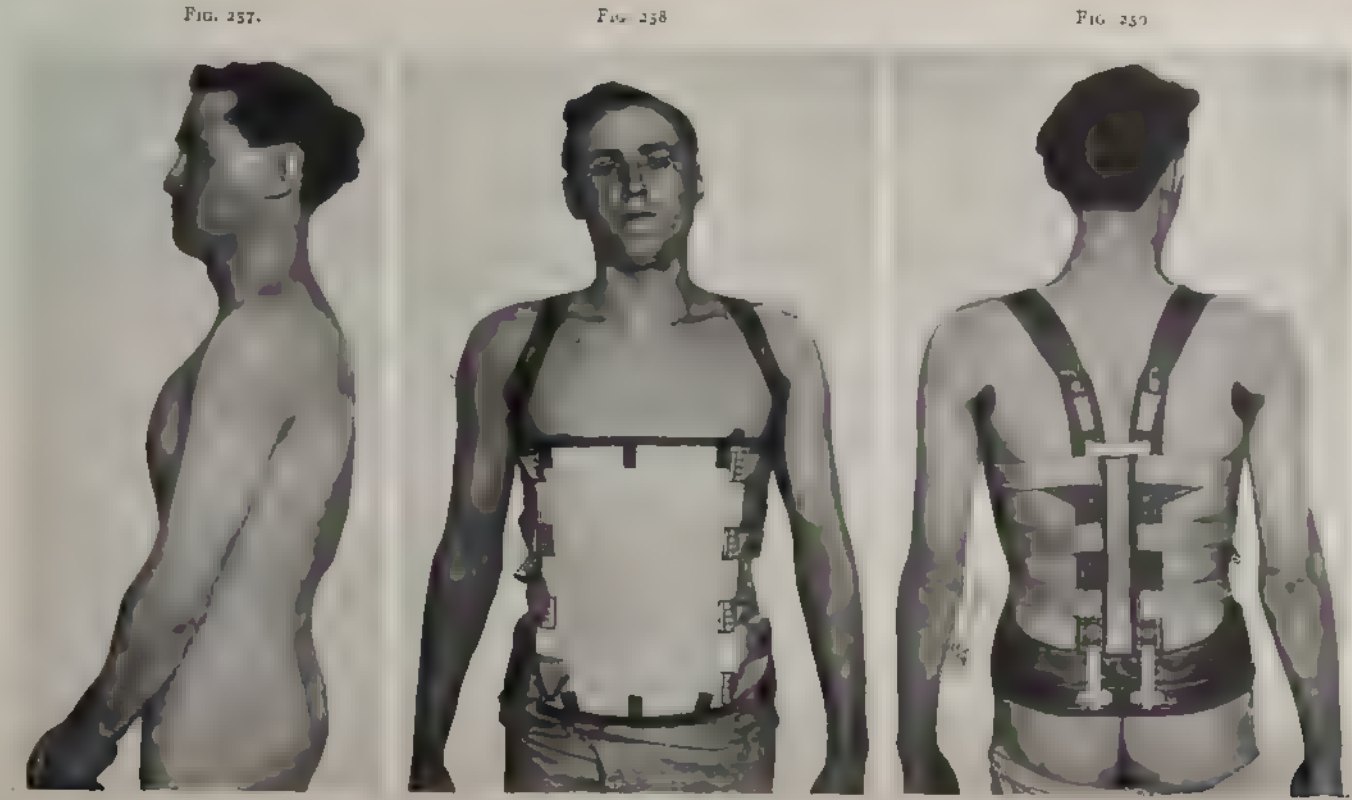

Fig. 257. Fig. 258 Fig. 259

Fig. 257.—Photograph showing deformity in compression fracture of the body of the second lumbar vertebra.
Figs. 258 and 259.—Photographs showing use of spinal convalescent brace for fracture of vertebræ.

versely. Lacerated or severe nerve-roots should be repaired by fine silk sutures.

AFTER-TREATMENT.—In all cases, whether apparently hopeless or not, the paralysis should be treated by massage and electricity if of the flaccid type; when it is of the spastic type electricity will excite the muscles to spasmodic contracture and should not be used. Spasmodic contractures seen in partial lesions may be very annoying to the

FIG. 260 FIG. 261

FIGS. 260 AND 261.—Photographs showing use of convalescent brace in the treatment of fractures of cervical vertebræ

patient. They may be partially controlled by the use of the bromides or chloral. When the patient complains of severe pain, especially at the level of the injury, the use of morphine will often be necessary. The general health of the patient should be promoted by fresh air, nourishing food, and pleasant companions.

During the stage of convalescence in those cases unassociated with paralysis support to the spine should be given by means of braces (Figs. 257–261).

CHAPTER XI

FRACTURES OF THE STERNUM

Anatomy.—The sternum (Fig. 262) or breast-bone is situated in the middle of the anterior portion of the thorax; it joins the costal cartilage of the first seven ribs on each side, and articulates with the inner extremities of the clavicles, forming the shoulder girdle anteriorly. It is formed of three parts: the manubrium, the gladiolus or body, and the xiphoid or ensiform process or appendix.

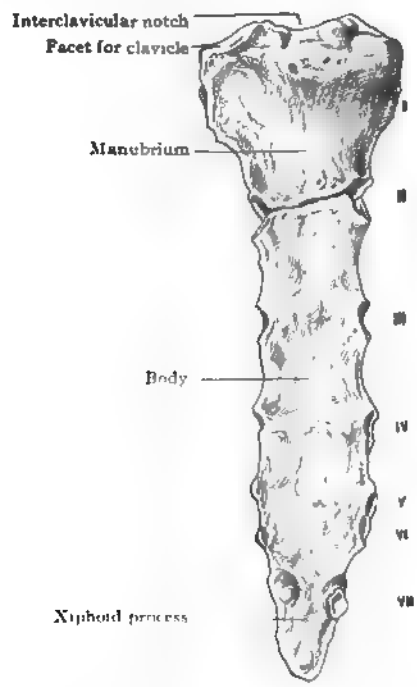

FIG. 262.—Sternum, anterior view.

The manubrium has on its upper margin three notches: the median or interclavicular notch, and two lateral or clavicular notches for union with the sternal extremities of the clavicles. Below these are two additional notches to accommodate the costal ends of the first ribs. The manubrium is triangular in shape, with its base above. The gladiolus is flattened, narrow above, and has on each side a demifacet at its upper angle, which unites with another demifacet on the lower corner of the manubrium for the articulation of the cartilage of the second rib. Below this demifacet are additional notches for the cartilages of the third, fourth and fifth costal cartilages. The sixth

and seventh costal cartilages articulate with the constricted lower end of the gladiolus by separate notches, the notch for the seventh being formed by a demifacet on the xiphoid cartilage.

The xiphoid cartilage sometimes remains cartilaginous until advanced life before it ossifies and becomes ankylosed with the gladiolus. It may be perforated, notched, or irregular in outline.

Surface Markings.—The anterior surface of the sternum may be palpated throughout. The junction of the manubrium and gladiolus is marked by a transverse ridge at the level of the second costal cartilage (Ludwig's angle). The lower portion of the sternum, the xiphoid cartilage, is generally depressed and is sometimes called the scrobiculus cordis or the "pit of the stomach." The sternoclavicular articulations are readily palpable.

Statistics.—Bruns observed in 8560 cases, 17 instances (0.1 per cent.) of fracture of the sternum; Chudowsky, in 2366 cases, 6 instances (0.25 per cent.); and Plagemann in 1393 cases, 5 instances (0.359 per cent.).

Etiology.—This is a rare injury, probably because the sternum is protected from indirect violence by being connected with the elastic costal cartilages and ribs. When fracture occurs, it is usually due to such great violence that injury to the ribs or thoracic viscera also occurs. Fracture of the sternum may also be produced by violence which forcibly flexes or extends the spine. Thus fracture of the sternum or of the spine or of both together is produced. Great muscular efforts, such as occur in lifting heavy weights or in parturition, have been followed by this fracture. It may also be caused by direct violence, such as a blow of moderate force, limited to a small area, and by bullets.

Varieties.—The first portion of the sternum and the last portion very frequently become united to the middle portion in early adult life by osseous union. Before this takes place there is fairly free movement possible at these points. In young patients it is therefore difficult to tell whether a given deformity is a dislocation or a fracture. Fracture may occur close to or at the joints. The most common site of fracture is near the junction of the manubrium and upper end of the gladiolus (Figs. 263 and 264). As a rule the line of fracture is more or less transverse. Longitudinal fracture should not be confounded with congenital fissure. Both are rare. The frequent irregularities of the ensiform cartilage should always be remembered.

Symptoms.—The symptoms of fracture of the sternum are localized pain and tenderness, mobility, crepitus and in some cases deformity (Fig. 265). These symptoms may be exaggerated by forcible respiration and by change of position. The attitude is often character-

istic. The patient assumes a sitting position, with stooping of the shoulders, and a part of the weight of the shoulders is supported by the arms on each side of the bed. Late ecchymoses may be observed. As a rule the anterior periosteum or the ligament is torn, while the periosteum on the posterior surface is stripped up and remains intact. Other symptoms that may be present are dyspnœa, expectoration of blood, and orthopnœa.

Complications.—The importance of the injury is due rather to the complications that may exist than to the fracture itself. There may be profuse hemorrhage into the mediastinum, rupture of the lungs

FIG. 263. FIG 264.

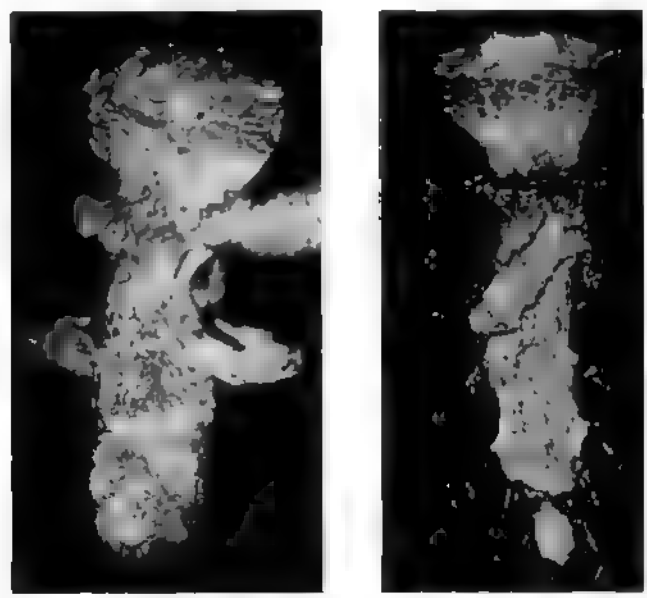

FIG. 263.—Transverse fracture of sternum, union The gladiolus was fractured transversely near its junction with the manubrium Union has occurred with secondary changes in the bone. The costal cartilages of the second and third ribs of both sides are ossified The ensiform appendix is missing. (Mutter Museum, No. 1202 10.)

FIG 264.—Oblique fracture of sternum; union The gladiolus was fractured near its junction with the manubrium. The callus marking the line of fracture runs from the attachment of the third right costal cartilage obliquely downward almost to the fourth left costal cartilage and then curves upward to the third. The callus is smooth and prominent. (Mutter Museum, No. 1202.)

or pericardium, and the development of an area of suppuration about the seat of fracture or in the mediastinum.

Diagnosis.—This may readily be made from the objective symptoms. At times these may consist only in local tenderness, swelling, and ecchymosis, while in the other cases all of the symptoms above mentioned may be present.

Osseous union takes place in from four to eight weeks.

Prognosis.—The prognosis is dependent upon the presence of complications. In simple uncomplicated cases there should be no

mortality, and union should progress without difficulty after proper reduction of the fragments. Gurlt records 98 cases; of these 54 were simple cases with 46 recoveries and 8 deaths, and 44 were complicated cases with 1 recovery and 43 deaths. Doubtless in the eight cases that died there was some complication present.

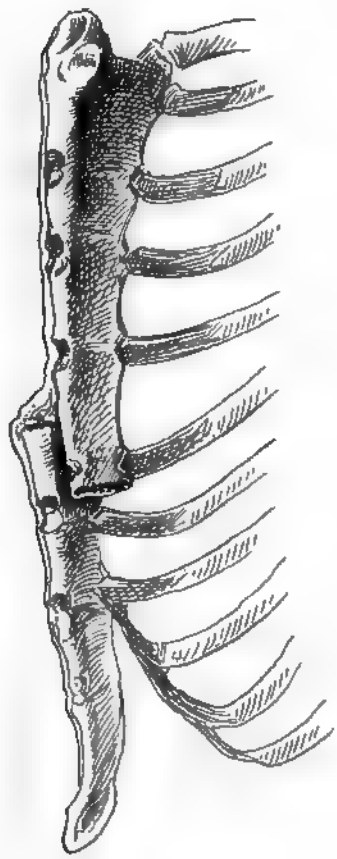

FIG. 265.—Showing type of displacement usual in fractures of the sternum.

Treatment.—Reduction of the fragments, if deformity is present, is to be accomplished by traction, hyperflexion, and direct pressure. A firm support, such as a sand pillow, should be placed between the shoulders. The arms should then be drawn upward over the head and rotated outward slowly and with considerable force. At the same time pressure over the lower end of the anterior fragment will generally result in reduction. This may also be accomplished by bringing the patient's head and shoulders over the end of a table and then drawing the arms upward and forcibly outward. Recurrence of this deformity often takes place after reduction. The chest should be immobilized in an adhesive plaster swathe, or a firm cotton roller bandage. If reduction cannot be accomplished by these manipulative efforts, an incision should be made at the seat of fracture, and the depressed fragment raised by a suitable instrument. Retention may be made by a plate or by direct suture with chromic catgut or silver wire. The after-treatment in these cases and in those in which there is no deformity consists in the use of bromides or anodynes for a few days and locally an ice-bag.

In the treatment of complications one should be guarded by general principles. When a localized area of suppuration occurs it should be promptly incised, and if its seat is the mediastinum, proper drainage alongside or through the sternum should be obtained.

CHAPTER XII

FRACTURES OF THE RIBS AND THE COSTAL CARTILAGES

Anatomy.—The ribs consist of twelve pairs and extend from the thoracic vertebræ outward, forward, and finally inward, terminating in costal cartilages in front. They form the thoracic wall. They are divided into the upper seven, called true or sternal ribs, the lower five, false or vertebral ribs. The lower two of the latter are known as the floating ribs. The typical rib may be divided into the following parts: the head, the neck, the body. The head is the posterior enlarged end, next to this is the constricted neck between the head and the tubercle; the latter marks the beginning of the body. Beyond the tubercle the body presents a rough surface, the angle of the rib. The body is curved on two axes, the dorsal curve extending from the head to the angle and beyond this the curve is forward and more gradual, ending in the sternal extremity which receives the costal cartilage. The ribs differ from each other somewhat, the first and second presenting marked peculiarities. The ribs increase in length from the first to the seventh and then decrease to the twelfth. The eleventh and twelfth ribs are short, slightly curved, the crests of the heads are wanting, and the tubercles have no articular surface.

The costal cartilages serve to connect the ribs with the sternum. The upper seven ribs have a direct connection with the sternum through separate costal cartilages, while the eighth, ninth, and tenth have a common cartilage which joins the sternum in connection with the cartilage of the seventh rib. The costal cartilages are continuous with the ribs, increase in size from the first to the seventh and then decrease in size and length so that the eleventh and twelfth ribs have very little cartilaginous end.

The articulations of the ribs with the vertebræ are divided into costocentral and costotransverse articulations. In the costocentral articulation there are the capsular ligament, the anterior costocentral or stellate ligament, and the interarticular ligament. In the costotransverse articulation there are the capsular ligament, the middle costotransverse or interosseous ligament, the posterior costotransverse ligament, and the superior costotransverse ligament.

The costochondral articulations are formed by the junction of the costal cartilages with the cup-shaped ends of the ribs.

In the chondrosternal articulation there are the interarticular ligaments, the anterior superior and inferior chondrosternal ligaments, the capsular ligaments, and the chondroxiphoid ligament.

Surface Markings.—The ribs can be palpated anteriorly, laterally and posteriorly as far as the edge of the erector spinal muscle. Occasionally the twelfth rib does not extend forward as far as the edge of this muscle, so that in counting the ribs one should begin above. The costochondral junction can be palpated, and especially so in persons showing a rhachitic tendency.

Statistics.—Bruns observed in 8560 cases of fracture, 819 (9.5 per cent.) instances of fracture of the ribs; Chudowsky in 2366 cases, 193 (8.15 per cent.) instances; and Plagemann in 1393 cases, 40 (2.8 per cent.) instances of fracture of sternum.

Pathology.—Fractures of the ribs are most frequently seen in adults and very rarely in children. This is accounted for by the great elasticity of the ribs in childhood. Green-stick fracture of the ribs doubtless occurs more frequently than statistics would lead one to suppose, and are often overlooked. In adults fractures frequently occur with little if any tearing of the periosteum and the symptoms are obscure. Fractures of the first and second ribs are unusual on account of their protected position behind the clavicle, and of the last two ribs on account of their mobility. Over-riding of fragments is impossible unless several adjoining ribs are broken. Angular deformity of a broken rib is also limited on account of its fixed position, the other ribs acting as splints.

Etiology.—Fracture of the ribs may be caused by external violence or by muscular action. The most usual form of external violence is a blow, fall, kick, or some compressing force. Direct violence by driving the rib inward causes fracture at the point of impact, and generally with inward displacement of the ends of the fragments; hence puncture of the viscera is more frequently seen in this class of violence. Indirect violence, by depressing the chest, has a tendency to bend the rib and cause a fracture beginning on the external surface. Fractures by indirect violence are most frequent near the angle, as this is the point of weakness and of greatest convexity. Fracture by muscular action may be produced by violent coughing and sneezing, or by lifting a heavy object. The tenth and eleventh ribs are most frequently the site of fracture. Pathological fractures of ribs are sometimes seen in general paralysis of the insane, and are probably due to trophic changes in the bone which make them more friable.

Varieties of Fracture.—Fracture of the ribs (Figs. 266 and 267) are most frequently seen involving the lateral and anterior portions, probably fracture at the angle being the most frequent. The lesion may involve only one rib, but, as a general rule, two or more are broken; and in some forms of injury, such as a "squeeze," ribs may be fractured on both sides of the body. In fracture of a single rib the periosteum is generally not torn; while if several ribs are fractured

the periosteum is torn and more or less deformity may be present. Fractures of the ribs may be open, or compound, but are rarely made so by puncture of the skin by a fragment of the rib. The wound is generally due to the fracturing force.

Symptoms.—The symptoms of an uncomplicated fracture of the ribs are often obscure. When only one rib is fractured the symptoms may be limited to local tenderness and pain (Fig. 268) on pressure, pain on deep inspiration, a little swelling, late ecchymoses, and the presence of a nodule due to callus. The most common symptoms are local pain and tenderness on pressure, crepitus, mobility of the fragments, pain on moderate or deep inspiration and on anteroposterior

FIG. 266.—Left rib, fracture; union. The fracture occurred 10 cm. from the sternal extremity; Left rib; fracture; union. The fracture occurred 9 cm. from the sternal extremity. Left rib; fracture; union. The fracture occurred 7 cm. from the sternal extremity. (Mutter Museum, Nos. 1217-37-36-34.

compression of the chest. The respiration is generally "catchy" or shallow and is due to irritation of the intercostal nerve by œdema, ecchymosis, callus, or fragments of bone. Ecchymosis appears after a few days in most cases. Swelling is generally present at the site of fracture and is due to bruising of the soft parts by the initial violence. Hæmoptysis may be present when the fracture is complicated with a wound of the lung.

Crepitus may be obtained by applying the finger-tips over the rib at each side of the suspected point of fracture and by causing alternate pressure (Fig. 269); or it may be detected by laying the palm of the hand over the point of tenderness while the patient coughs or the examiner makes firm pressure in the region of the injury with the

other hand. Crepitus may also be detected by auscultation. Abnormal mobility may be difficult to recognize on account of the normal mobility of the chest wall. A valuable symptom is pain caused by anteroposterior compression of the chest wall (Fig. 270). The pain is always greater at the seat of fracture and may be referred along the course of the intercostal nerve (Fig. 268). Pain will also be complained of

FIG. 267.—Röntgenogram of healed fractures of the fourth to ninth left ribs

at the seat of fracture when a forced inspiration is attempted, on account of the increased movement of the chest wall.

Complications.—The complications of fractures of the ribs are those due to injury of the thoracic or abdominal contents. These complications are fairly frequent and may be as follows:

FIG. 268.—Showing relation of intercostal artery, vein and nerve to the rib.

FIG. 269. FIG. 270.

FIG. 269.—Method of making alternate pressure over rib near seat of fracture to determine abnormal mobility and pain.

FIG. 270.—Method of making anteroposterior compression of the chest-wall. In fracture pain will be determined by this manipulation.

Intrathoracic.—(*a*) Laceration of pleura and lung. The most common indication of such a lesion is subcutaneous emphysema, first noted at the seat of fracture and rapidly spreading. This condition always denotes puncture of the lung. Instead of producing a sub-

FIG. 271.—Compression injury of chest. Man caught under elevator. Injury consists of fracture of left fourth rib, which punctured the lung with resultant hæmothorax. Note compensatory hyperdistention of right lung, or pneumothorax.

FIG. 272.

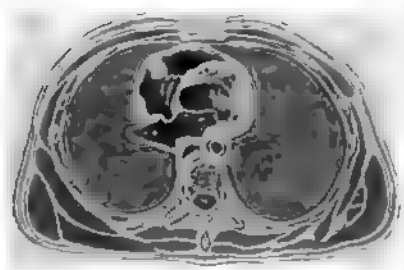

FIG. 273.

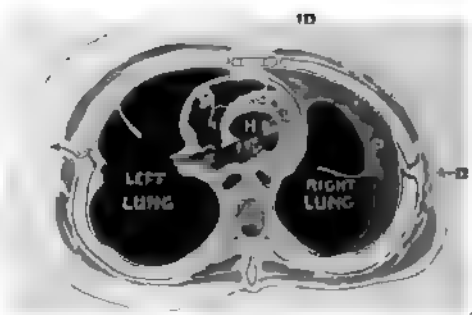

FIG. 272.—Cross-section of chest, showing normal relations of intrathoracic structures to the overlying ribs.

FIG. 273.—Diagrammatic representation of complications which may occur in fracture of the ribs. On the left side is shown the presence of subcutaneous emphysema from injury to the lung due to fracture of the ribs at (*A*). On the right side is shown the presence of hæmothorax and compression of the lung following a fracture of the ribs at (*D*) and associated injury to the right lung, (modified after Eisendrath).

cutaneous emphysema, the air from the ruptured lung may escape only into the pleural cavity, giving rise to a pneumothorax; or there may also be some blood in the pleural cavity in addition to the air, causing a hæmopneumothorax (Figs. 271–273). The lung may actually be-

come compressed and collapsed by large quantities of air and blood in the pleural sac. When the emphysematous condition extends into the mediastinum and the interlobular cellular tissue of the lung, the patient's condition becomes critical. (*b*) Pericardial and heart injuries. These are very infrequent, except after very great violence. (*c*) Laceration of the intercostal artery is rather more infrequent than one would suppose. The subsequent hemorrhage is rarely severe enough to cause alarming symptoms, unless the site of fracture communicates with a wound into the pleura. (*d*) Traumatic asphyxia. This condition follows compression of the chest in conjunction with fracture or dislocation, and is characterized by a dusky, cyanotic discoloration of the skin of the head, face, neck, and upper part of the

FIG. 274. FIG. 275.



FIGS. 274 AND 275.—Method of application of the adhesive plaster swathe in the treatment of fractures of the ribs. External splinting of this character gives entire relief from pain by splinting the external respiratory muscles of the chest.

chest, accompanied by subconjunctival bulbar ecchymosis, usually limited to the interpalpebral space. This blueness appears immediately after the accident and is probably due to minute capillary extravasations. (*e*) Hernia of the lung. A few cases of this rare complication have been reported, notably by Wahl, Huguier, Weiss, and Volger. In most of the cases reported, the ribs involved were one or several of the first five ribs.

Intra-abdominal.—The most frequent injuries of the abdominal organs seen as a complication of fracture of the ribs are rupture of the liver, spleen, stomach, or intestine, and laceration of the diaphragm.

Diagnosis.—The diagnosis may generally be made from the subjective and objective symptoms present. The most frequent are localized pain and tenderness, crepitus, swelling, and restricted respiration.

Prognosis.—This is generally favorable in the usual uncomplicated costal fractures. Union occurs in three to five weeks by interosseous and ensheathing callus, which often leaves an irregularity because perfect immobilization of the parts is impossible. When fracture of several adjacent ribs has taken place, union often occurs not only between the fragments of each rib but the several ribs are united by an exuberant callus. Hernia of the lung may occur after much displacement or comminution of fragments. Marked dyspnœa of the pneumothorax is often a very distressing and at times fatal condition. The development of pleurisy, pericarditis or pneumonia makes the prognosis grave, but recovery after severe intrathoracic injuries often takes place.

Treatment.—Fracture of the ribs should be treated by reduction of the fragments and immobilization. Reduction of fragments may best be accomplished by forcible inspiration and manipulation. If the ends of fragments are depressed, it rarely may be advisable to resort to incision for reduction. In the majority of cases there is very little deformity, but perfect reduction is impossible. Immobilization should aim at splinting the parts so that thoracic breathing is limited. This is best accomplished by the application of a circular swathe of adhesive plaster six to eight inches in width, encircling the chest with its centre at the seat of fracture (Figs. 274–275). The patient should be standing with the hands resting on the head during its application. One end of the plaster is applied and fixed to the side of the chest opposite to the fracture, and is carried around the body. Its application is completed at the end of a forced expiration. Before applying this dressing all hair should be removed from the chest. Several narrow strips of adhesive plaster each overlapping the one below may sometimes be found more comfortable. The lowest should be applied first. In a few cases such constriction of the chest will be contraindicated, especially if the patient has asthma or chronic bronchitis. In this instance the plaster may be applied half way around the chest, thus limiting motion on the side injured only.

Another form of dressing consists in the application of a firm binder of heavy muslin carried around the thorax and pinned down the front; straps should be carried from its upper edge over the shoulders, like suspenders, to prevent its slipping downward. This circular dressing should be worn at least three weeks, after which a circular cotton roller bandage may be applied for two more weeks.

The intrathoracic complications demand, as a rule, no special treatment unless they produce grave symptoms. The cellular emphysema

sometimes present requires no attention, as the air is soon absorbed. Even when great extension of the emphysema occurs, no danger is to be apprehended, except when it extends into the mediastinum and interlobular tissue of the lungs. Pneumo- and hæmopneumothorax and pleural effusion, if of alarming degree, call for aspiration. Extreme congestion of the lungs, with accompanying grave dyspnœa, should be relieved by venesection and the traditional treatment for pulmonary inflammations.

Fractures of the Costal Cartilages

These fractures occur most frequently near the costochondral junction and involve usually the seventh or eighth cartilages. The partially ossified cartilages of the aged are more susceptible than those of the young; the changes taking place in advanced life are of a fibrinous character, and calcification and ossification are not common. The line of fracture is generally transverse, excepting when the break is an extension from a fracture of the sternum, when it may be longitudinal or diagonal in character.

Etiology.—Many of these fractures are due to direct violence, although there are reported cases due to indirect violence and muscular action.

Symptoms.—Deformity is the most constant symptom. In addition there is localized pain and at times a soft crepitus. The displacement of the fragments generally shows the sternal one to be displaced inward and vertebral one outward.

Diagnosis.—This rests mainly upon the deformity and site of the lesion.

Prognosis.—Is good. Union takes place not by cartilage but by osseous or fibro-osseous tissue. This forms a bony callus around the ends of the fragments, and is a more or less similar union to that seen in fractures of the ribs.

Treatment.—The treatment consists in replacement by manipulation, combined with forced inspiration. Immobilization is obtained in the same way as is used for fracture of the ribs.

CHAPTER XIII

FRACTURES OF THE CLAVICLE

Anatomy.—The clavicle (Fig. 276) or collar-bone is shaped like an italic *f*, and is composed of a body or middle portion, the sternal and the acromial extremities. The inner end articulates with the sternum and is firmly attached to the latter by the sternoclavicular ligament and to the cartilage of the first rib by the costoclavicular ligament. The outer end articulates with the acromial process of the scapula and is firmly fixed to the acromial process of the scapula by the acromioclavicular ligament and also to the scapula by the coracoclavicular ligament, which is composed of two parts, the trapezoid and the conoid. It is on account of the arrangement of the ligaments attached to the outer end of the clavicle that displacements of fragments do not as a rule occur in fracture of its outer one-fourth.

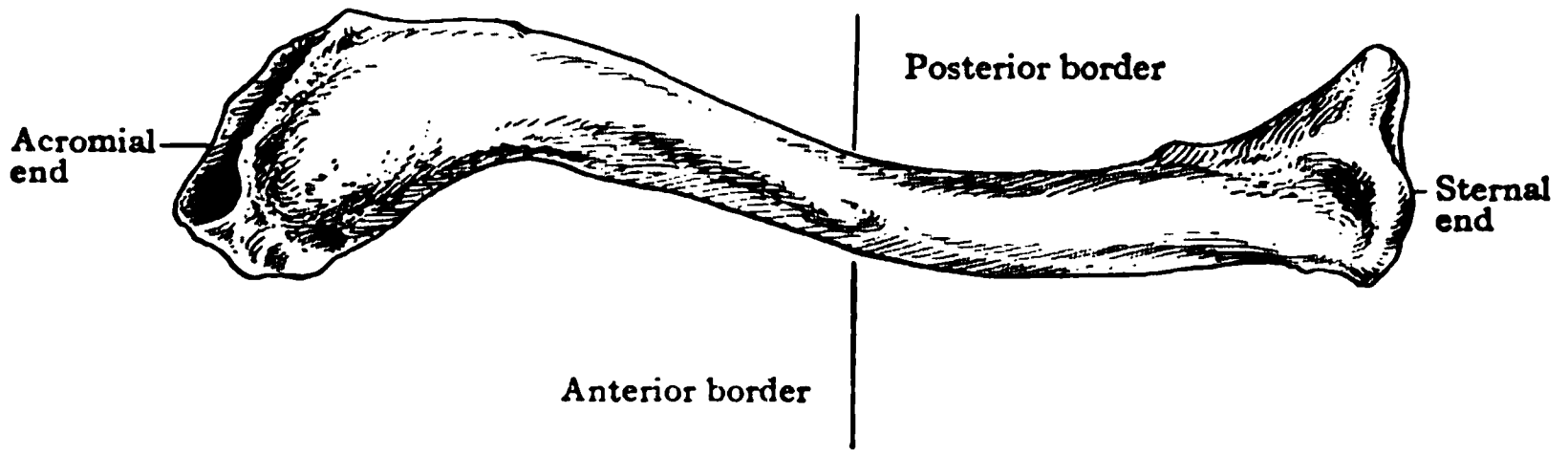

FIG. 276.—Right clavicle, upper surface.

Surface Markings.—The clavicle is superficial throughout its entire length. One can readily palpate the sternoclavicular and acromioclavicular joints and note the distinct S-shape of the bone and the junction of its two curves at its middle, where fractures most often occur (Fig. 277). Beneath the clavicle are the subclavian artery and vein, which are at times injured in fracture of the clavicle. The brachial plexus also lies beneath the clavicle and is separated from it by the subclavius muscle. Its entire anterior surface can be felt from the sternal to the acromial end. In thin persons the middle of the bone may be readily grasped so as to demonstrate the presence of crepitus.

Statistics.—Fractures of the clavicle constitute from 14 to 16 per cent. of all fractures. Freeman, in 1911, in a report of 1428 cases of fracture treated at the Homestake Mine in Lead, South Dakota, gives only 4 per cent. involving the clavicle. Malgaigne shows 10 per cent.; Bardenheuer 13 per cent.; Pitha, 18.7 per cent.; Bruns in 8560 fractures, 960 cases (11.2 per cent.); Chudowsky in 2360 fractures, 113 cases (4.17 per cent.); Immelmann, in 4048 fractures, 40 cases (1 per cent.), and Plagemann in 1393 fractures, 54 cases (3.87 per cent.).

Clavicular fractures are especially frequent during childhood; the mechanism which generally produces a dislocation at the shoulder-joint in adults, namely, a fall upon the shoulder or a force transmitted from a fall on the hand, causes a fracture of the clavicle during childhood.

Etiology.—Fractures of the clavicle may be the result of direct violence, indirect violence, or muscular action. By far the most common cause, however, is indirect violence. Thus in falls upon the shoulder, elbow, or hand, while the arm is extended and the muscles

FIG. 277. Palpation of clavicle, method of determining crepitus, abnormal mobility, and deformity.

held rigid, the force of the impact is transmitted to the clavicle, which constitutes the only bony connection of the arm with the trunk. A tendency to exaggerate the curves of this doubly curved and twisted bone is thus produced, and the bone gives way as soon as the strain becomes too great. Cases have been reported by Malgaigne and others, in which the fracture was produced by bending of the clavicle over the first rib by sudden depression of the shoulder. Forcible compression

of the shoulders may also produce a fracture of the clavicle by indirect force.

Instances of fracture of the clavicle by direct force are those in which the clavicle is directly struck by a blow or a falling object directed backward and downward or by the recoil of a rifle butt.

Fracture by muscular action may be produced by vigorous sudden action, in which sudden contraction of the deltoid and pectoralis major muscles occurs, as in lifting heavy weights, suddenly seizing a fixed object when one is falling, or violently using a tennis racquet.

FIG. 278.—Fracture of the middle third of the clavicle, direct violence.

Varieties.—The outer part of the middle third is the most common site of fracture, but from its obliquity the line may extend into the outer or inner third. The frequency with which fractures occur at this region, as a result of indirect violence, is due to the small diameter of the bone and the sharpness of the curve at this point. Comminuted, multiple, or open fractures are rarely seen. Transverse and green-stick fractures are frequent in children, with very little deformity, displacement of fragments, or laceration of the periosteum.

Symptoms.—Fractures of the middle third (Figs. 278–281) present a characteristic symptom-complex. The usual deformity is produced by a tilting upward of the outer end of the sternal fragment while the inner end of the acromial fragment is carried inward underneath the sternal fragment. Thus the two portions of the clavicle form an angle

with its apex upward; at times they may resemble a Y, or T. The shoulder is displaced forward, downward and inward (Fig. 282). The projection upward of the outer end of the sternal fragment is due to the pull of the sternocleidomastoid muscle and the lifting force exerted by the outer fragment being thrust under it. The displacement inward, forward and downward of the acromial fragment is due to the fact that the clavicle is the support which holds the scapula and the attached arm in its proper relation to the thorax (Fig. 283). Fracture of the clavicle removes this support, and, as a result, the scapula is rotated around the dorsolateral aspect of the chest, and the acromion depressed, by the weight of the upper extremity and the action of the serratus magnus, the pectoralis major, and the rhomboideus muscle. Shortening of the clavicle may be determined by measuring from the acromion to the sternoclavicular articulation and comparing this with the sound side. Shortening is great in oblique fractures with overriding, and may amount to one or two inches. In some transverse and incomplete fractures angular deformity may be present in an upward and backward direction. In green-stick and subperiosteal fracture there may be no deformity. In all of these fractures the amount and the direction of the displacement are influenced by the continuance of the fracturing force, after rupture of the bone has occurred, and by the line of fracture.

FIG. 279.—Fracture of the middle third of the clavicle by indirect violence, characteristic deformity.

Displacement of fragments may be readily palpable and their outlines visible in many cases. Crepitus is determined by grasping the two fragments or, in children, by grasping the shoulder and by movement, which causes the fractured ends to rub against each other. Crepitus is not present in incomplete and in green-stick and rarely in subperiosteal fracture.

Fractures of the outer third (Figs. 284–286) come next in frequency to fractures of the middle third, and are as a rule irregularly transverse in direction. This displacement is dependent upon the location of the line of fracture. When it is in the area of the attachment of the coracoclavicular ligament (Fig. 287), little if any displacement of the fragments takes place; but when the line of fracture is beyond

the attachment of this ligament, the inner end of the outer fragment may be tilted upward by the trapezius, and the outer end of the inner

FIG. 280.—Fracture of the clavicle, junction of the middle and inner thirds. Characteristic displacement of fragments. Outer end of inner fragment is displaced upward; outer fragment inward and downward.

FIG. 281.—Fracture of middle third of clavicle, absence of displacement of fragments, produced by indirect violence.

fragment drawn downward and inward by the attached fibres of the deltoid and portion of the pectoralis major muscles. Considerable angular displacement is possible.

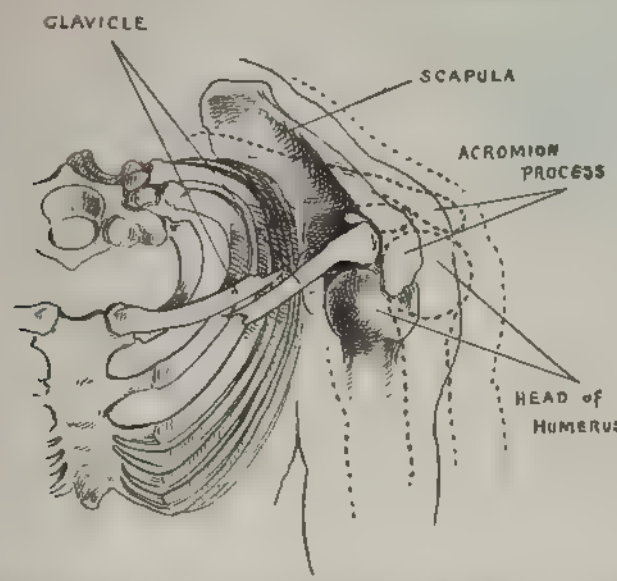

FIG. 282.—Shows typical displacement of fragments in complete fracture of middle third of clavicle. The inner fragment is pulled upward by the action of the sternomastoid muscle, while the outer fragment is carried downward, forward and inward with the shoulder. Dotted lines show normal position of shoulder.

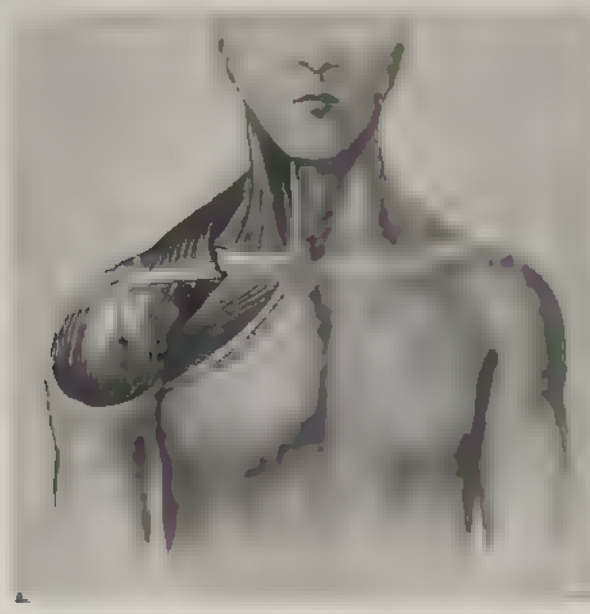

FIG. 283.—Drawing to demonstrate typical displacement of fragments in fracture of middle third of clavicle.

Fractures of the inner third (Fig. 288) are very infrequent. The deformity when present consists in a displacement downward and for-

ward of the inner end of the outer fragment, or angular distortion of both fragments in the same direction. Displacement is generally limited by the attachment of the costoclavicular ligament below and the sternocleidomastoid muscle above. Most fractures here are due to direct violence. Fig. 281 represents a case due to indirect violence—a fall upon the shoulder.

The local deformity in fractures of the clavicle at its various parts has been described. In addition crepitus may be obtained except when the fragments are impacted, or widely separated, or when the fracture is incomplete. There is swelling and ecchymosis at the seat of fracture; generally inclination of the head toward the affected side in fractures of the middle third, displacement to relax the sternomastoid muscle, and a characteristic attitude with inability to raise the arm. This loss of function is due to pain, and prevents the raising of the hand to the head or placing the arm in marked abduction.

In children fractures of the clavicle are often incomplete, or green-stick, and are unattended by deformity, crepitus, or displacement. These fractures are often overlooked unless the child complains of pain and refuses to move the arm voluntarily. Examination will often detect localized tenderness, swelling, and slight irregular deformity, generally anteriorly or upward; and in the course of a few days or a week there will be a circumscribed spindle-shaped swelling due to the formation of ensheathing callus.

FIG. 284.—Fracture of outer end of clavicle. The line of fracture is in area of attachment of the coracoclavicular ligament and no displacement of fragments occurs.

In fractures of the outer third without deformity or displacement of fragments, crepitus may be elicited, as a rule, by careful pressure on the upper surface of the outer fragment, while grasping the middle of the clavicle firmly and making motion. When crepitus cannot be elicited in this manner the presence of a fracture may be diagnosed by localized pain, ecchymosis, and swelling. Erdman considers that the diagnosis may be made in doubtful cases by the lessened transmission of respiratory sounds to points on the clavicle beyond the seat of fracture.

Fractures near the acromial end may simulate supra-acromial dislocation. In green-stick, subperiosteal or incomplete fractures the formation of callus may simulate a syphilitic periostitis. A case has recently been treated by Dr. Kelly in which the fracture resulted from a slight fall upon the elbow in a patient having a syphilitic lesion of the clavicle.

Complications.—Open fractures are rare except in cases in which the violence has been great and there are associated injuries. Complications that may occur are laceration of the brachial plexus, subclavian artery, subclavian or internal jugular veins, and puncture of the pleura or apex of the lung. The late complications are those due to pressure of fragments or excessive callus.

Prognosis.—Union generally takes place in children in fifteen to twenty-one days and in adults in from twenty-one days to six weeks. Non-union is rare and when it does occur only a moderate degree of disability persists. Moderate deformity at the seat of fracture does not interfere greatly with the subsequent use of the arm. Impairment of function from the pressure of exuberant callus on the blood-vessels and nerves behind the clavicle is more often the result of the use of a large axillary pad during the treatment rather than direct pressure by

FIG. 285. FIG. 286.



FIG. 285.—Fracture of tip of outer end of clavicle. This partakes of the nature of a tear-fracture from force exerted through the acromioclavicular ligament.
FIG. 286.—Fracture of the outer end of the clavicle. Fragments are held together by the attachments of the coracoclavicular ligaments.

callus. The normal abduction of the arm may be lessened by union of callus to the coracoid process.

Treatment.—Many cases of fracture of the clavicle are accompanied by very little deformity. This is especially so in the subperiosteal and green-stick fractures seen in the middle third in children, and in fractures of the outer third of the clavicle at the attachment of the coracoid-clavicular ligament. In these cases a simple retentive dressing is all that is necessary. Reduction of the deformity in green-stick fractures may often be readily accomplished; when the displacement is slight, reduction is not advisable. In such cases a small pad over the seat of fracture held in place by adhesive plaster, and the use of a sling with the arm bound to the side, or the application of the claviculo-humeral dressing meet the indications for treatment (Figs. 289–290). The pad placed over the site of break will retain its place

well if covered with adhesive plaster with the rubber side next to the skin. It is in cases of complete fracture of the clavicle at the middle third, attended by marked deformity, that retention of the fragments in their correct position after proper reduction often becomes difficult. Fortunately the permanent deformity often resulting is more of a cosmetic defect than a permanent disability.

Correction of the deformity in complete fractures of the middle third is attempted by grasping the arm and shoulder and endeavoring

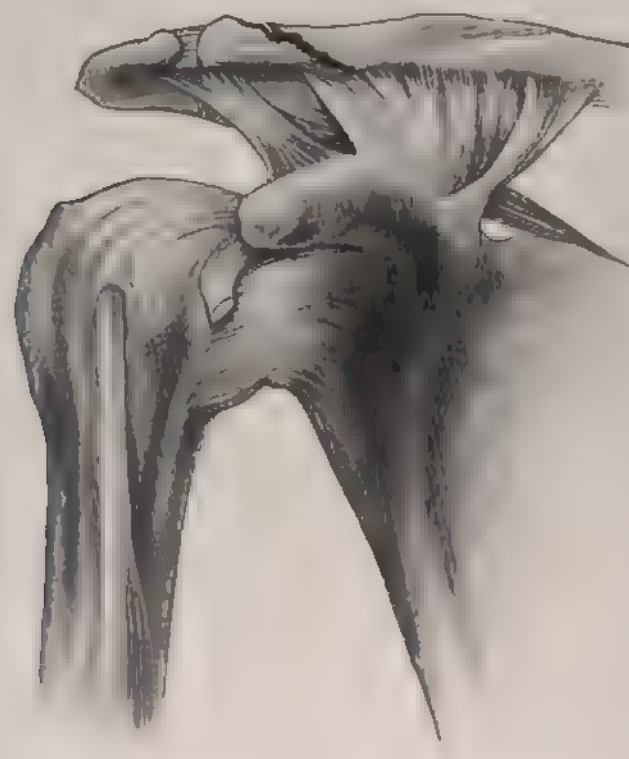

FIG. 287.—Drawing to show the attachments of the coracoclavicular and coraco-acromial ligaments and the reason for absence of displacement in fractures of the outer end of the clavicle

to swing the scapular backwards around the posterior aspect of the chest toward the median line of the back. By this manœuvre the shoulder is carried upward, outward and backward, and the outer or acromial fragment is brought into its normal position. At the same time moulding of the fragments is performed, and in most cases perfect reduction of the fragments may be accomplished. The difficulty is in maintaining reduction until firm union has been established.

The following methods of treatment are recommended:

Dorsal Recumbency.—The flexed forearm and arm are held near the chest by a circular bandage. The patient is then placed upon a firm, level mattress, with his head raised on a pillow and turned toward the injured side, to relax the sternomastoid muscle; and a small sand-bag is placed over the acromion to hold the shoulder in the desired direction. The forearm may be held across the chest with a bandage looped around wrist and fastened to opposite side of the bed. This postural form of treatment in bed should be persisted in for from ten to fourteen days and is irksome only during the

Fig. 288.—Fracture of the inner end of the clavicle. (Courtesy of Dr. P. G. Skillern, Jr.)

first few days. At the end of that time the patient may be allowed to get up, as a rule, and continue treatment by one of the ambulatory methods, because the fragments show usually less tendency to displacement after muscular spasms have been lessened and the fragments surrounded by reparative exudates. Dorsal recumbency is as a rule recommended only to women who dislike clavicular deformity because they are required at times to go in public with the neck exposed. In men the deformity often seen after a broken clavicle is not objected to if good function is promised.

Sayre Dressing or Its Modifications (Figs. 289–293).—This fracture dressing is advisable in late adolescence and in adult life. It is not practicable in young children, in short people, or in women with large breasts. The skin of the chest should be shaved if hairy, and

Fig. 289. Fig. 290.

Fig. 291. Fig. 292.

Figs. 289–292.—Method of applying Sayre dressing for fracture of the clavicle. Fig. 289, first stage, Fig. 290, second stage, Fig. 291, posterior view, Fig. 292, third stage of modified Sayre dressing.

the chest, arm, and forearm thoroughly washed with soap and water, rubbed with alcohol, and well powdered. Especial attention should be given to the axilla. All apposed portions of skin should be carefully protected by several layers of lint or sheet-wadding. After the fragments have been completely reduced, a cuff of lint three inches in width

is placed about the upper arm. Over this the end of a three-feet long strip of adhesive plaster, three inches in width, is passed in the form of a loop around the arm, care being taken that it is not so tight as to constrict the vessels. The elbow is drawn well back and fixed in this position by the plaster being carried around the entire chest from back to front to the anterior axillary line of the same side. The elbow is flexed and the forearm laid upon the front of the chest with the palm on the opposite breast. The second adhesive strip, three inches in width, with a hole cut in it for the olecranon, is then applied. Beginning on the posterior surface of the upper arm it is carried down to the olecranon, over the extensor surface of the flexed forearm and hand, and over the opposite shoulder, so that the end may lie upon the dorsum of the scapula of the uninjured arm. Before fixing the strip over the sound shoulder and back, the forearm and hand should be drawn toward the sound shoulder with a fair amount of force. The loop of the first strip acts as a fulcrum and the shoulder of the injured side is thereby carried upward, outward, and backward. A modification of the Sayre dressing is the addition of a third strip of adhesive plaster beginning at the elbow, running upward over the seat of fracture, and down the posterior part of the arm. A small folded piece of lint is placed between the seat of fracture and the adhesive plaster. Ordinarily in most individuals this dressing may remain in place for two and a half to three weeks, after which time it may be replaced by a sling for the forearm and a circular bandage fixing the arm to the chest wall. The patient will, however, be much more comfortable if the dressing is renewed about every six or seven days and reapplied in the same manner after bathing the skin with alcohol or soap and water.

FIG. 293.—Finished Sayre dressing for fracture of the clavicle.

THE CLAVICULO-HUMERAL BANDAGE DRESSING (Figs. 294 and 295).—In early childhood and stout individuals the Velpeau dressing with certain modifications is the one of choice. All apposed skin surfaces should be carefully protected. After complete reduction the elbow of the injured side is brought well to the front of the chest and

the hand placed upon the opposite shoulder. A roller bandage is carried from the scapula of the well side obliquely over the back of the injured shoulder, over this, down the outside of the arm, under the elbow, across the chest to the opposite axilla, and to the point of starting. After a sufficient number of turns have been made to support the arm, the bandage is carried around the arm and chest by circular turns from the elbow upward to the shoulder This dressing is re-enforced by the application of a light plaster-of-Paris case (Figs. 32 34) or a silicate of sodium dressing. Before the dressing has set the patient is placed flat upon his back, the shoulders are pressed backward and held in this position until the dressing has hardened. In some cases a

FIG 294. FIG. 295.

FIGS 294 AND 295 Photographs to show application of clavi.culo-humeral bandage in fracture of the clavicle unattended by any great degree of deformity The skin contact surfaces should be well separated by sheet-wadding before applying the bandage.

small pad should be placed over the outer end of the sternal fragment before this dressing is applied. The patient is then allowed to walk about and, if advisable, a window may be cut in the dressing at the end of a week to observe the position of the fragments. In cases attended with considerable deformity this dressing should be worn four weeks.

In fractures of the outer end of the clavicle attended by displacement of fragments, the most satisfactory dressing is Stimson's "figure-of-8," made of adhesive plaster (Figs. 296 and 297).

Operative Treatment.—In all cases in which deformity recurs in spite of all measures made to maintain reduction, the seat of fracture should be exposed under strict asepsis, and delicate plate applied or the fragments may be held by the use of chromic catgut sutures after suitable drill holes have been made. A small drill may be used

to pin the fragments together. If left in place it acts as a nail, and fixes the fragments in the corrected position. After the wound has been closed and a sterile dressing applied, a bandage, re-enforced by a plaster-of-Paris case should be applied.

FIG. 296. FIG. 297

FIGS. 296 AND 297.—Stimson's "figure-of-8" dressing for fracture of acromial end of the clavicle. Fig. 296 shows figure of 8 adhesive plaster, pad over seat of fracture and wrist-sling. Fig. 297 shows complete dressing.

SUMMARY OF TREATMENT

In green-stick fractures and when there is little displacement, a simple retentive dressing, such as a sling to support the entire arm and hand, with perhaps a pad over the seat of fracture held in position with a strip of adhesive plaster. The claviculo-humeral dressing is excellent.

If much displacement and in women fearing disfigurement, reduction should be followed by dorsal recumbancy, as described, to hold the lower angle of the scapula against the ribs for about two weeks; then ambulatory treatment for about three weeks.

In other cases ambulatory treatment by a Sayre, claviculo-humeral or Stimson dressing or some modification of them.

In very troublesome fractures, subcutaneous nailing with Roberts drill-nail method, or operative fixation with absorbable or wire sutures or with a delicate steel or an aluminum plate.

If non-operative treatment has left undesirable deformity, removal of prominence with chisel.

CHAPTER XIV

FRACTURES OF THE SCAPULA

Anatomy.—The scapula (Fig. 298) or shoulder-blade is a large, flat, irregular bone forming the posterior part of the shoulder girdle. It articulates with the clavicle and humerus at its outer extremity and rests upon the posterior surface of the thorax, being separated from it by muscles alone. It is a triangular-shaped bone, having two surfaces, the ventral and dorsal, three angles, the superior, the inferior and lateral, and three margins, the internal or vertebral, the external or axillary, and the superior. The dorsal surface is divided into two parts, called the supra- and infraspinatous fossæ, by the spine. The superior border has a well-marked notch—the suprascapular notch—and external to this a hooked-like process extending forward and outward, the coracoid process. From the external angle there is a moderate constriction called the neck and, external to this, an expanded portion, the head, the outer surface of which is smooth and concave. This is termed the glenoid cavity and is the articular surface for the head of the humerus. The external process of the spine which passes over the neck and glenoid cavity from behind and above is a strong, irregular, broad process called the acromion. It contains a facet internal to its apex for articulation with the clavicle.

Surface Markings.—The scapula can readily be palpated, especially in thin individuals. The borders, angle, and spine may be outlined by flexing the elbow and placing the hand of the side to be examined on the opposite shoulder (Fig. 299). The inferior angle, the superior angle, the vertebral and axillary borders can be felt readily, and the changes in their relation with the spine noted during abduction of the arm. The upper border cannot be so readily palpated. The acromion and spinous processes may be readily felt; the coracoid process, while not noticeable on inspection, can be readily felt about one inch below the clavicle (Fig. 300). The acromion process may be used as a fixed point in estimating suspected shortening of the humerus, the external condyle being utilized for the other fixed point. The two upper extremities should be placed in the same relative position and measurements between these points carefully noted.

Statistics.—Bruns, in 8560 cases of fracture, records 100 cases (1.1 per cent.) of fracture of the scapula; Chudowsky, in 2366 cases of fracture, 20 cases (0.84 per cent.); Immelmann, in 4048 cases of fracture, 63 cases (1⅝ per cent.); and Plagemann, in 1393 cases of

fracture, diagnosed by Röntgen rays, 13 cases (0.93 per cent.) involving the scapula.

Fracture of the scapula may occur in any part of the bone; namely, the body, the superior angle, the inferior angle, the spine, the acromion, the neck, the coracoid process, and the rim of the glenoid cavity.

Fracture of the Body of the Scapula—Etiology.—The body of the scapula is, on account of its position and mobility and its splinting by muscular masses, well protected against ordinary forms of accidental injury. Fracture when it does occur is usually the result of direct violence, as from falls, street accidents, blows upon the shoulder, and impacts from heavy falling objects. Severe contusion of the soft parts, as a rule, accompanies this form of injury.

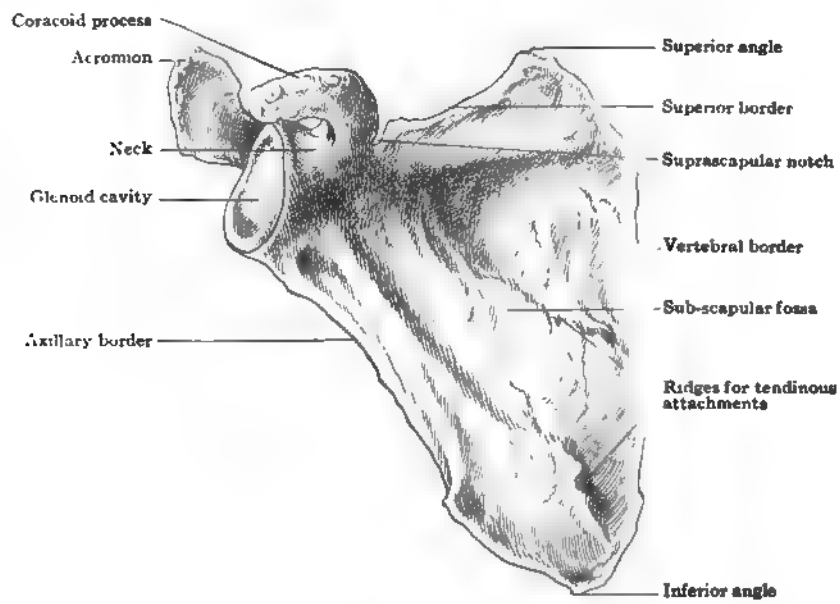

FIG. 298.—Right scapula, anterior view.

Varieties.—The fracture may be single or multiple, and the lines may be transverse or oblique. Comminution of fragments is frequent. Open fractures of the body are rare, excepting when due to gunshot or other penetrating wounds. Displacement of fragments may be due to the fracturing force or to the pull exerted by the serratus magnus and teres major muscles; hence the deformity may be by angulation, overriding or separation.

Symptoms.—The symptoms consist of localized pain, tenderness on pressure, abnormal mobility, crepitus, ecchymosis and diminished function. Crepitus and increased mobility may be demonstrated by placing the hand of the injured side on the opposite shoulder, thereby

making the lower angle prominent, or by placing the forearm behind the thorax on the injured side.

Prognosis.—In fracture of the body of the scapula union occurs in three to four weeks. Accurate apposition of the fragments is not

FIG. 299. FIG. 300.

FIG. 299.—Method of palpation for suspected fracture of scapula.
FIG. 300.—Method of palpation of coracoid processes of the scapulæ.



FIG. 301.—Left scapula, stellate fracture of the superior angle. Starting from a point in the spine 2 cm. from the posterior border, fracture lines passed upward, backward to the posterior border, and downward. A fragment 2 × 5 cm. was detached from the posterior border. The fragments are well united, and the callus is abundant. (Matter Museum No. 1247.)

always possible and union occurs often with over-riding and excessive callus. Inflammatory processes or exostoses in the bursa may be followed by permanent disability.

Treatment.—Approximation of the fragments is best produced by immobilization and splinting. This is accomplished by the employment of a moulded and padded gypsum case over the scapular region, held in place by adhesive plaster; and by immobilizing the entire upper



Fig. 3[illegible] Fracture through spine of scapula.

Fig. 304.—Right scapula, comminuted fracture of the base of the acromion process, union. One line of fracture passed transversely 5 cm. from the apex of the acromion. The other passed at a right angle to it from its centre toward the border. Union is complete on the under surface; on the outer surface the fracture lines are marked by deep indentations. (Mütter Museum, No. 1247.40.)

extremity with a firmly fitting clavicular-humeral bandage. This dressing may be re-enforced by a few turns of a gypsum bandage.

Fractures of the Superior Angle of the Scapula (Fig. 301)—**Etiology.**—Fractures of the superior angle are very rare. Few have

been observed or reported except in conjunction with fractures of the spine or body of the scapula They are usually the result of direct violence.

Varieties.—The lines of fracture may involve the spine or extend into the subspinous fossa, as in that recorded by Hamilton. Displacement may occur upward due to the pull of the levator scapulæ muscle.

Symptoms are similar to those described for fracture of the body. Displacement of the fragment upward would be readily palpable.

Treatment.—Immobilization of the arm by clavicular-humeral bandage after fixing the scapula by a padded gypsum splint.

FIG. 304.—Fracture through base of acromial process of scapula.

Fractures of the Inferior Angle of the Scapula—Etiology.—Generally due to direct violence. Cases have been reported in which the fracture was the result of muscular action, as in wrestling or catching oneself with the hand while falling.

The line of fracture is more or less transverse, and there is generally displacement of the lower fragment forward and upward, due to the pull of the serratus magnus and teres major muscles.

Symptoms.—Pain, tenderness on pressure, abnormal mobility

crepitus, displacement forward and upward of the detached lower angle with moderate over-riding of the fragments. Marked disability of the arm combined with apparent shortening of the bone measured from the spine to the lower angle are also present.

Treatment.—The actual displacement may be partially overcome by bringing the elbow forward across the chest and fixing it here by

FIG. 305

FIG. 306

FIG. 305.—Strain-fracture of acromial process of scapula.
FIG. 306.—Separation of the epiphysis of the acromial process of the scapula.

means of the clavicular-humeral bandage. Union occurs in three to four weeks. After the third week the forearm may be placed in a sling and the arm fixed to the chest by a circular bandage

Fractures of the Spine of the Scapula (Fig. 302)—**Etiology.**—Fractures here are more or less frequent on account of the exposed position of the scapular spine, and are the result of direct violence.

Varieties.—The line of fracture may involve only a portion of the spine or it may cause a complete separation, involving the spine at the base of the acromion.

Symptoms.—Fractures of the spine may be recognized clinically by tenderness on pressure, crepitus and abnormal mobility in the region of the spine, and some irregularity of outline.

Treatment.—This consists in immobilization of the parts by a padded gypsum splint and an overlying claviculo-humeral bandage.

FIG. 307.—Method of determining abnormal mobility and crepitus in fracture of the acromial process of the scapula by forced hyperabduction of the arm.

Fractures of the Acromion—Etiology.—Fractures of the acromion may be the result of direct violence. They also occur in conjunction with dislocation of the upper end of the humerus, and may be due to hyperabduction of the arm without dislocation. They may be the result of indirect violence, such as falls upon the hand or elbow or by the force, acting through attached ligaments, resulting in a sprain-fracture.

Varieties.—The following varieties of acromial fractures may be distinguished: at the base of the acromion (Figs. 303 and 304); close the point of articulation with the clavicle; sprain-fracture (Fig. d separation of the acromial epiphysis (Fig. 306). The two

centres of ossification for the acromion appear about the sixteenth year, and ossification is not complete until from the twenty-first to the twenty-fifth years.

Symptoms.—The lesions may be obscured by absence of deformity and swelling of the soft parts. Flattening of the shoulder is produced when the acromion is fractured at its base and is due to the weight of the arm pulling the fragment downward and inward. In fracture of the tip of the process, little or no deformity is present and crepitus may be obtained by grasping the elbow while the shoulder is pushed upward. Inability to abduct the arm is generally present. Crepitus may be obtained by hyperabduction of the arm (Fig. 307).

Prognosis.—Fibrous is more common than bony union, and is due usually to inability to obtain close approximation of the fragments: This is especially so in fractures at the base of the process.

Fig. 308.—Dressing to immobilize shoulder in fracture of scapula.

Treatment.—The indication for treatment is to immobilize the arm and at the same time force the head of the humerus well up against the scapula. These indications are met by the application of a firmly applied claviculo-humeral bandage, reinforced by a few turns of a gypsum bandage (Fig. 308).

If the deformity is great, the best results will be obtained by treating the patient in bed on a flat, firm mattress, with the arm held in marked abduction so as to relax the deltoid which is the displacing muscle.

Fractures of the Neck of the Scapula—Varieties.—Fractures of the so-called anatomical neck that is immediately behind the glenoid cavity and parallel with it are practically unknown. Fractures of the surgical neck (Fig. 309) are of three varieties: The fracture line in one passes behind the coracoid process downward from the suprascapular notch to the axillary border, and the coracoid process is separated from the body of the scapula; in the other the fracture line begins in front of the coracoid process, passing down to the axillary border, and the coracoid process remains attached to the body of the scapula.

These fractures are very rare. A third variety is that in which

there is separation of the scapular epiphysis as a whole. The articular head includes not only the glenoid neck, but also the coracoid and acromion bases. Such an instance has been cited by Poland.

Etiology.—The cause of these fractures is generally a fall or blow upon the shoulder. Farabeuf considers that this fracture may be produced by a blow upon the posterior aspect of the head of the humerus when there is outward rotation of the arm, thereby making the anterior portion of the capsule tense; or, if the arm is directed backward, a fall upon the elbow may produce a similar result.

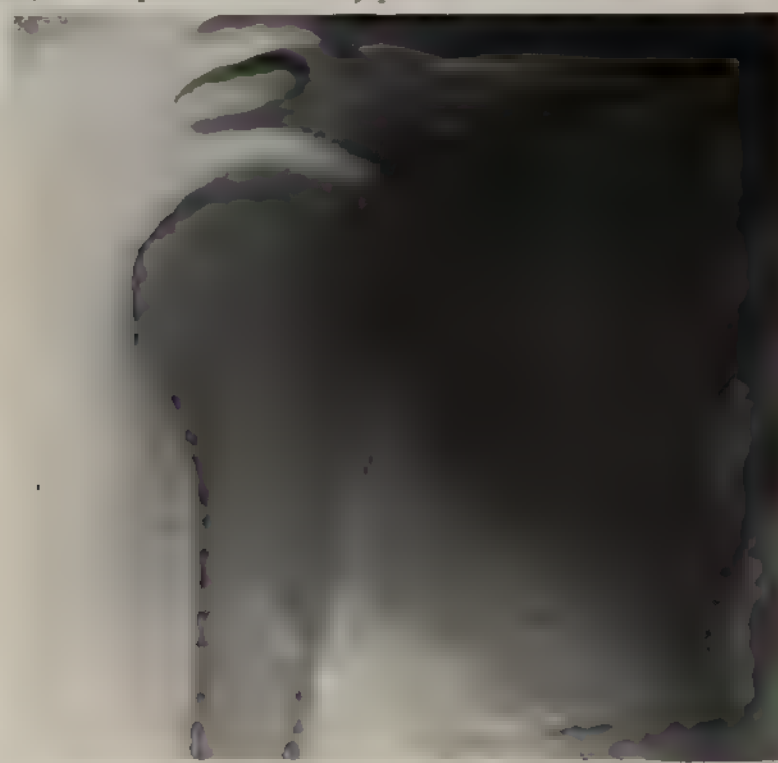

FIG. 309.—Fracture of the surgical neck of the scapula.

Symptoms.—These consist of flattening of the shoulder prominence of the acromion, loss of voluntary motion of the arm, crepitus after reduction, and recurrence of the deformity when the arm is allowed to drop from the elevated position. The deformity consists in sinking of the outer fragment of the scapula with the attached humerus (Fig. 310). At times the edge of the fractured surface of the scapula may be felt through the axilla. When the line of fracture begins at the suprascapular notch, the relation of the coracoid process with the head of the humerus is unaltered, but when the coracoid process re-

mains attached to the body of the scapula these relations are changed. Forced elevation of the arm will often determine crepitus (Fig. 311).

Diagnosis.—The condition should be differentiated from acromio-clavicular luxation and deltoid paralyses, from the drooping of the shoulder at times seen after reduction of dislocations of the upper end of the humerus, and from axillary dislocation of the head of the humerus.

Treatment.—The indications in the treatment of these injuries is to elevate the arm and to produce counter-pressure upon the acromion end of the clavicle. This is best accomplished by a clavículo-humeral dressing, with a moderate pad in the axilla and the entire bandage

Fig. 310 Fig. 311

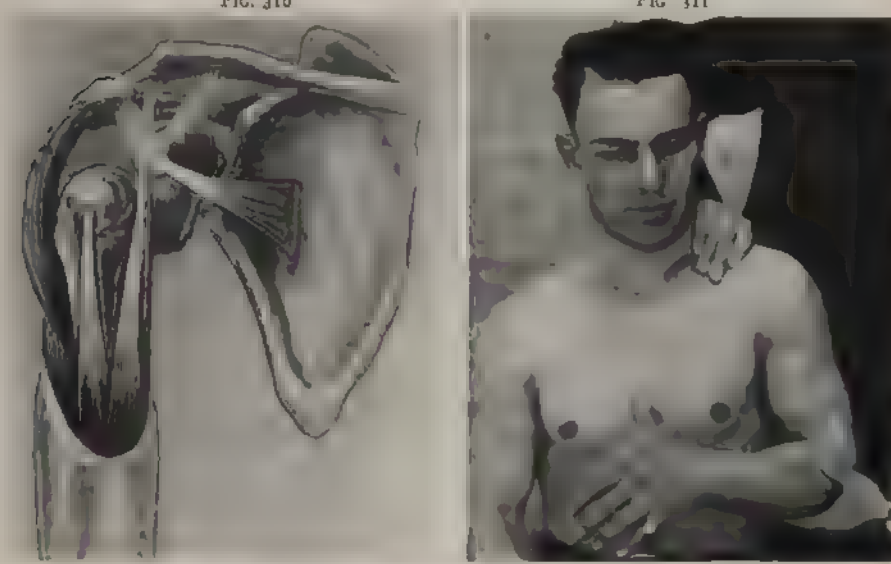

Fig. 310.—Drawing to show the displacement of fragments in fracture through the neck of the scapula.
Fig. 311.—Method of determining crepitus and abnormal mobility in fracture of the neck of the scapula by forced elevation of the shoulder.

reinforced by a gypsum case. Union takes place with a moderate amount of displacement of the fragments, and may be followed by some impairment of motion dependent upon the amount of periarticular callus present.

Fractures of the Coracoid Process—Etiology.—Uncomplicated fractures of the coracoid process are very rare. They are most often seen as complications of luxation of the head of the humerus, or of coincident injury to the clavicle, ribs, or other portions of the scapula, occurring therefore from indirect or direct violence. A few cases of fracture by muscular action (Fig. 312), as in wringing clothes, throwing a ball, or in forced supination, have been observed.

Varieties.—The line of fracture is usually at the base of the process, or it may be at the epiphyseal line, being in the latter instance an epiphyseal separation. Longitudinal splitting of the process has been reported.

Symptoms.—In the absence of displacement of the process, the symptoms noted are pain, localized tenderness, crepitus, and ecchymosis. Pain is increased on deep inspiration and on elevating the arm, due to the pull of the pectoralis minor muscle, and also on flexion of the supinated forearm from the pull of the short head of the biceps muscle. Displacement of the coracoid process is generally limited by the action of the attached muscles and the coracoclavicular ligament.

FIG. 312.—Tear fracture of epiphysis of coracoid process of scapula

When the latter is torn, the process may be displaced downward and inward, due to the pull of the coracobrachialis, the biceps, and pectoralis minor muscles. The presence of coincident injuries of a grave nature will often obscure the symptoms of fracture of the coracoid and render its early diagnosis impossible.

Treatment.—The arm should be placed in a position of hyperflexion and the hand midway between pronation and supination. This is best accomplished by a modified Velpeau bandage reinforced by a few turns of the gypsum bandage.

Fractures of the Rim of the Glenoid Cavity—Etiology.—Fractures of the rim of the glenoid cavity are seen occasionally as a complication of luxation of the upper end of the humerus. They are the

result of moderate violence acting through the head of the humerus either from a direct fall upon the shoulder or upon the elbow or hand, when the arm is in a position of hyperabduction.

Varieties.—The following varieties have been noted: fracture of the inner rim of the articular surface in a longitudinal direction; fracture of the outer or lower border involving a part of the neck (v. Bruns); a comminuted or stellate fracture line involving the glenoid cavity and the neck and part of the body (Poland, Flower).

Symptoms.—Persistence of crepitus after a reduction of a luxation of the head of the humerus, and a tendency toward a recurrence of the luxation on the removal of a retentive dressing are significant of fracture of the rim of the glenoid. Other symptoms will be pain on motion, swelling about the joint, and ecchymosis. There may occur a late limitation of motion, and in some cases ankylosis of the joint, due to union of the fragments with the head of the humerus. A radiograph should help in making an early diagnosis.

Treatment.—Immobilization with the claviculo-humeral dressing until union has occurred should be the line of treatment. After this has occurred massage and passive motion should be fairly vigorous, so as to prevent the formation of ankylosis.

CHAPTER XV

FRACTURES OF THE HUMERUS

Anatomy.—The humerus (Figs. 313–314), one of the typical long bones of the skeleton, is composed of the upper extremity, the shaft, and the lower extremity.

The upper extremity is composed of the head, which is directed inward, upward and backward, at an angle of 130 degrees with the axis of the shaft, the anatomical neck, the greater and lesser tuberosities, and the surgical neck. The anatomical neck is the constricted portion immediately beneath the head, to which the capsular ligament is attached. Beneath the anatomical neck there are two rough prominences, the larger or greater tuberosity being directed outward and the smaller tuberosity being directed inward and forward; between these two is the bicipital groove. Below the tuberosities there is a marked constriction, the surgical neck.

The shaft is cylindrical above and transversely expanded and triangular below, and in the lower half of the shaft there are three surfaces, the antero-internal, the antero-external and the posterior.

The lower end of the humerus changes from the three-sided form noted above to a flattened and broad form, and ends in the two condyles, the internal and external, which are placed in front transversely at the lower end of the shaft. A continuation of the axis of the humerus would be at a point posterior to the condyles. This is shown by the lateral view of the lower end of the humerus and in part accounts for the extreme flexion and limited extension possible at the elbow-joint. The axis of the condyles is placed somewhat obliquely to that of the shaft, forming an angle of 85 degrees which accounts for the carrying angle. The external surface of the external condyle forms a small blunt projection, the external epicondyle, and on the inner surface of the internal condyle is placed the prominent internal epicondyle. Between the two condyles there are two anterior and one posterior depressions. The former are the coronoid fossa and the radial fossa for the accommodation of the coronoid process and the head of the radius on full flexion; the latter or posterior depression, called the olecranon fossa, is for the olecranon process on full extension. The articular surface of the lower end of the humerus consists of the capitellum upon the external condyle, which articulates with the head of the humerus; and the trochlea upon the internal condyle, which articulates with the sigmoid cavity of the ulna. These

two articulating surfaces of the lower end of the humerus are divided by a ridge.

Surface Markings.—The head of the humerus can be felt most readily through the axilla. The roundness of the shoulder is due to the bulk of the deltoid muscles overlying the greater and lesser tuberosities of the humerus, which may be felt through the muscle. Evidences of fracture of the upper end of the humerus may be determined by placing the fingers at the anterior edge of the deltoid (deltopectoral groove) with the thumb behind, and then grasping

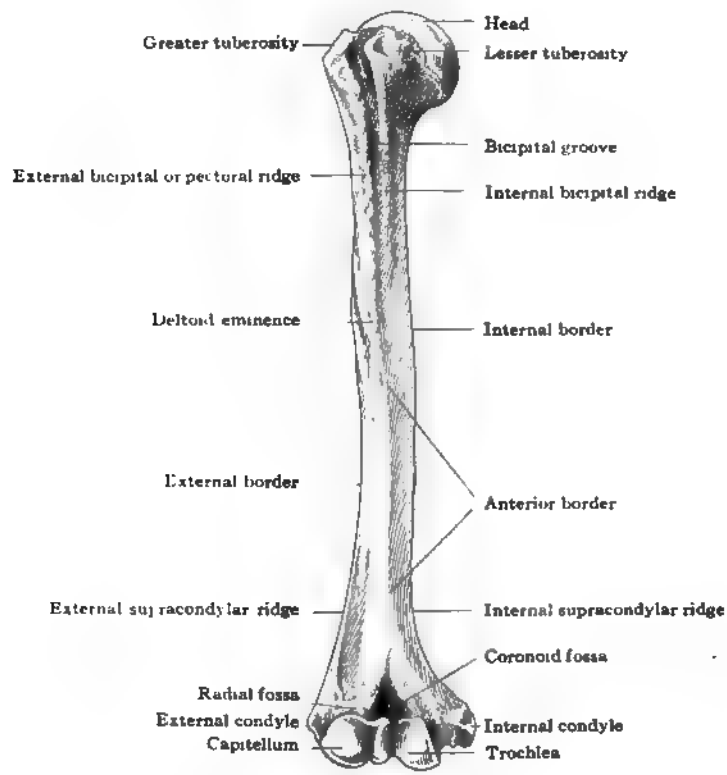

FIG. 313.—Right humerus, front view.

the flexed elbow with the other hand (Fig. 317); by making careful rotation, crepitus may be determined in a non-impacted fracture. The shaft of the bone can be readily palpated throughout its entire length (Fig. 318). The internal and external condyles of the humerus may be readily palpated (Fig. 319); and these two prominences may be used in conjunction with the tip of the olecranon in determining displacement of fragments in fractures at the lower end of the humerus or of the olecranon. In full extension a line drawn between the

internal and external condyles posteriorly will touch the tip of the olecranon (Fig. 320). During full flexion the tip of the olecranon will be found below this line.

FIG. 314.—Upper end of humerus, showing cupping of epiphysis to receive the pointed head of the diaphysis. (Piersol's Anatomy.)

The head of the radius may be palpated and felt to rotate in the dimple just below and anterior to the external condyle (Fig. 321). The coronoid process may be felt in thin subjects by making deep pressure in the hollow, situated anteriorly just below the joint. The axis of the upper part of the upper extremity, or arm, forms with the fully extended and supinated forearm an obtuse angle, with its opening outwards, called the carrying angle (Fig. 322). This angle is greater in the female than in the male on account of the greater width of the female pelvis.

Statistics.—Von Bruns, from a study of 8560 cases of fracture, found the humerus involved in 866 cases (10.1 per cent.); Chudowsky, in 2366 cases, found 210 cases (8.17 per cent.); Immelmann, in 4048 cases, found 940 cases (23.5 per cent.) and Plagemann, in a study of 1393 cases, studied by radiograms, found the humerus to be involved in 194 instances (13.92 per cent.). Of these he classifies as follows:

Fractures of the humerus, 194 cases (13.9 per cent.):

(*a*) Of the upper end, 73 cases (5.24 per cent.):

FIG. 315 FIG. 316.

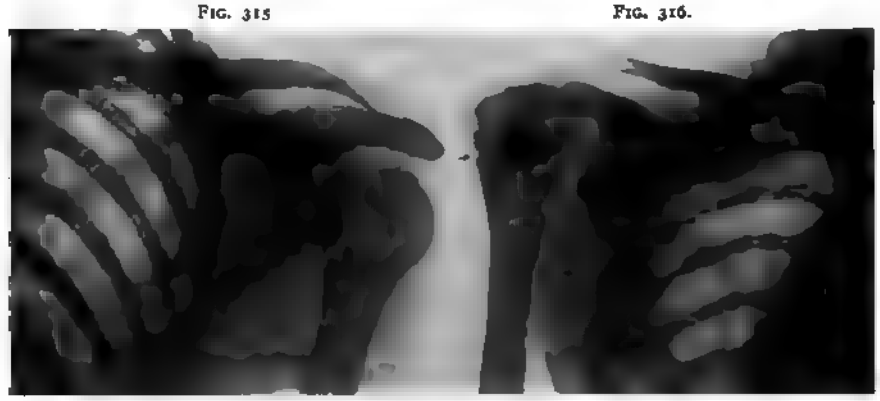

FIG. 315.—Röntgenogram of normal shoulder-joint
FIG. 316.—Röntgenogram showing normal epiphysis of upper end of humerus.

FIG. 317 FIG. 318



FIG. 317.—Method of determining crepitus and abnormal mobility in fracture of the upper end of the humerus.

FIG. 318.—Method of determining crepitus and abnormal mobility in fracture of the shaft of the humerus.

FIG. 319. FIG. 320.

FIG. 319.—Method of palpation of the condyles of the humerus.

FIG. 320.—Shows the normal relation of the olecranon process of the ulna and of the condyles of humerus in full extension of the elbow.

(1) Fractures of the anatomical neck..... 4 (0.29 per cent.)
(2) Fracture of the greater tuberosity... ... 30 (2.15 per cent.)
(3) Fracture through the tuberosities..... 10 (0.71 per cent.)
(4) Separations of the upper epiphysis.... . 7 (0.509 per cent.)
(5) Fractures of the surgical neck .. .. 22 (1.57 per cent)

(*b*) Of the diaphysis, 18 cases (1.29 per cent).

(*c*) Of the lower end, 103 cases (7.32 per cent.)

(1) Supracondylar fractures .... 43 (3.08 per cent.)
(2) Supracondylo-intercondylar fractures .... 11 (0.78 per cent.)
(3) Fractures of the external condyle..... 15 (1.07 per cent)
(4) Fractures of the internal epicondyle..... 18 (1.29 per cent.)
(5) Separation of the lower humeral epiphysis 10 (0.71 per cent.)
(6) Fractures of the cubital process..... 6 (0.43 per cent.)

Fractures of the Upper End of the Humerus

Varieties of Fractures.—Fractures of the upper end of the humerus may be classified as : (1) fractures of the head; (2) fractures of the anatomical neck; (3) fractures through the tuberosities; (4) fractures (isolated) of the greater or lesser tuberosity; (5) separation of the upper epiphysis; (6) fractures of the surgical neck.



Fig. 321.—Palpation of the head of the radius. Normally it may be felt to rotate with the shaft on pronation and supination of the hand.

Fig. 322.—The carrying angle; formed by the deviation of the axis of the forearm from the humeral axis. (Davis' Applied Anatomy.)

Fractures of the Head of the Humerus (Fig. 323).—Fractures involving the head of the humerus without injury to other parts of the bone are extremely rare. Fractures involving the head are generally found in conjunction with fractures of the anatomical neck or tuberosities, or with anterior dislocation of the humerus. Fractures of the head may be fissured fractures. The fragments may be impacted or displaced, and can generally only be detected by X-ray examination. They should be differentiated from fracture of the anatomical neck, subdeltoid bursitis, and sprain-fractures. Cases have been recorded by Gosselin and Gross, and by Malgaigne.

Etiology.—The articular surface may be chipped off, or may be indented, or the line of fracture may extend out through the anatomical or surgical neck, or the tuberosities. These fractures are occasionally seen accompanying dislocation.

FIG. 323. FIG. 324.



FIG. 323.—Incomplete fracture of the head of the humerus.
FIG. 324.—Fracture of the anatomical neck of the humerus, with dislocation of the head into the axilla. The semi-circle group of arrows shows the position of the head.

Symptoms.—Simple fissuring or even a complete separation of the head of the bone may be unrecognized. A radiogram should usually be made in injuries about the shoulder-joint. When the line of fracture extends into other parts, the symptoms present will partake of those seen in fractures of the various regions involved. Union is apt to occur with some deformity or excessive intra-articular callus and subsequent limitations of motion.

Treatment.—Unless satisfactory reduction and approximation of the fragments can be obtained and shown to be so by radiogram, excision of the head should be performed. It is possible that nailing the head in position, as is done in the femur, may give satisfactory results and thus obviate excision.

Fractures of the Anatomical Neck.—These fractures occurring as isolated injuries are almost as rare as fractures of the head of the bone, except in those instances in which they are associated with luxation of the humerus.

Etiology.—This fracture is seen most frequently in advanced life and as a result of direct violence, such as a fall upon the shoulder. The line of fracture is rarely limited to the anatomical neck, but generally involves one or both tuberosities and is frequently impacted. It is also occasionally seen in conjunction with luxation of the head. The upper fragment may not be impacted with the lower, and may lie free in the cavity of the joint or be in the axilla. The possibility of non-union in unimpacted fractures of the anatomical neck should always be remembered, as well as the resulting intra-articular callus formation which may lead to a marked ossifying arthritis.

Symptoms.—Fractures of the anatomical neck (Fig. 324) are often difficult to distinguish, without the aid of the radiogram, from fractures of the surgical neck, tuberosities, or intra-articular fractures of the shoulder-joint. The chief symptoms are swelling, pain on motion, loss of function, and the gradual appearance of ecchymosis within forty-eight to seventy-two hours. Deformity as a rule is slight, unless the head is dislocated into the axilla. Crepitus may be demonstrated in non-impacted fractures, when the upper fragment remains in the joint cavity, but it is difficult to differentiate the crepitus from that obtained in any other intra-articular fracture of the shoulder-joint. There is generally slight flattening of the shoulder, shortening of the arm, if the upper fragment is dislocated, and marked pain on rotation of the arm.

Diagnosis.—This can best be determined by the radiogram. In all cases of injury about the shoulder-joint one should use this means of accurate diagnosis whenever possible. The condition should be differentiated from luxation of the humerus, from fracture through the tuberosities, and from fracture of the surgical neck.

Prognosis.—The prognosis is dependent upon the age of the patient, and upon whether the fragments are impacted. Complete recovery is the exception. The usual result is recovery with moderate impairment of motion, chiefly in abduction. Necrosis of the head may occur if detached from the shaft, although union has taken place in cases in which the head has been considerably isolated.

Treatment.—The treatment of many of these cases is simple. When impaction of fragments is present the arm should be supported by a sling, the shoulder perhaps protected by a shoulder cap, and the arm held to the chest wall by means of a swathe. Very gentle mas-

sage and passive motion should be begun very early, not later perhaps than on the fifth to the seventh day. When there is non-impaction with rotation outward of the head of the bone, attempts should be made to bring the line of fracture together by abduction and traction of the arm. The limb should be held in this position either by a suitable traction or extension apparatus or by means of a triangular support. Gentle massage should be begun at the end of the first week. When the head has been dislocated into the axilla and in those instances in which union does not occur in non-impacted cases with the head remaining in the joint cavity, excision of the capital fragment usually should be performed. This procedure is advised only in those

FIG. 325. FIG. 326.



FIG. 325.—Fracture of the humerus through the greater tuberosity with dislocation of the head into the axilla.
FIG. 326.—Fracture of the humerus through the tuberosities.

cases in which the patient's general health warrants such a procedure. When this is inadvisable, however, a surprising amount of function may be observed even in the most unpromising cases.

Fractures through the Tuberosities (Figs. 325 and 326).—These fractures are not as rare as fractures of the anatomical neck. They are often found in conjunction with fracture lines extending partially through the anatomical neck and are at times hard to differentiate from high fractures of the surgical neck. The line of fracture is often seen to begin anteriorly about the level of the anatomical neck and to run downward and backward through the tuberosities. Comminuted fractures of the tuberosities are frequently seen. Such fractures are a common accompaniment of luxation of the head of the humerus.

Etiology.—This variety of fracture is the result of a fall directly upon the shoulder or upon the elbow when the arm is in a position of adduction with the elbow inward and backward. Fracture by abduction is very infrequent, and impaction of fragments is the rule.

Symptoms.—The symptoms of fracture through the tuberosities are swelling about the shoulder-joint, generally a moderate degree of shortening due to impaction of the fragments, occasionally crepitus, inability to lift the arm, apparent thickening of the bone, and marked local tenderness in the region of the tuberosities. A positive diagnosis can generally be made by the rontgenogram, and the differential diag-

FIG. 327.—Fracture of the greater tuberosity and of the surgical neck of the humerus.

nosis from fracture of the anatomical neck, the surgical neck, or an isolated fracture of either of the tuberosities established. The difficulty of taking two good X-ray plates in planes of an angle of 90 degrees in the shoulder region somewhat impairs the value of the radiographic diagnosis.

Treatment.—If impaction of the fragments is present and the head of the bone in its normal position, attempts at further reduction should not be made. The arm should be held to the side, the forearm placed in a sling and the shoulder protected by a shoulder cap for two weeks. The value of the shoulder cap is not great as a fixation

apparatus but protects the region from blows which might do harm. Careful massage and passive motion should be employed early. The late results are generally a limitation in rotation and abduction. Where a dislocation of the head of the humerus accompanies the fracture, the head may be reduced by operative means and nailed to the shaft. If this is not feasible, resection of the head should be performed.

Fractures (Isolated) of the Greater or Lesser Tuberosities.—Isolated fracture of the greater tuberosity (Figs. 327 and 328) may or may not accompany anterior dislocation of the head of the humerus. One case has been reported by Malgaigne in which it accompanied a backward dislocation of the head of the humerus.

Statistics.—In Plagemann's statistics of 30 isolated fractures of the greater tuberosity, he differentiates three groups: a tearing off of the greater tuberosity; a transverse or comminuted fracture of the tuberosity, and a tearing out of a small portion of its cortex. Of the first class the fracture was found six times in conjunction with a preglenoid dislocation, and eight times as an uncomplicated fracture; of the second class in four instances there was a transverse fracture of the upper face of the greater tuberosity, four times a multiple transverse fracture, and three times a comminuted fracture of the entire tuberosity; and in the third class, in six instances there were portions of the cortex torn off the upper surface of the greater tuberosity.

Fractures of the greater tuberosity were encountered twenty-four times in the male and six times in the female.

FIG. 328.—Humerus, right; fracture of the greater tuberosity. The fracture has occurred with slight posterior displacement due to the action of the supraspinatus, infraspinatus and teres minor muscles. A deep fissure lies between the fragment and the head of the capsular ligament. Union is firm. (Mütter Museum, No. 1262.30.)

Etiology.—Fracture of the greater tuberosity is due either to a direct fall upon the shoulder, a fall upon the elbow or hand, producing at the time an accompanying dislocation of the head of the humerus, or to the direct pull of the attached supraspinatus, infraspinatus, and teres minor muscles. The tuberosity may be entirely detached and dislocated upward and outward, or it may be incompletely detached and held by a portion of periosteum to the shaft. In the latter instance a longitudinal fissure is seen beginning at the level of the anatomical neck and running downward. The fragment may be so separated that the long tendons of the biceps may be interposed. When the fragment is entirely detached it may be displaced between

the acromion and the head of the humerus, causing locking of the joint. Cases of fracture accompanying anterior dislocation of the humerus are often unrecognized.

Symptoms.—Isolated fracture of the tuberosity with dislocation of the fragment may be recognized by the presence of crepitus when the arm is abducted and rotated. There is inability to rotate the arm outward, marked tenderness over the tuberosity, apparent increase in the anteroposterior diameter of the shoulder, and moderate projection of the acromion. When the fragment is not detached the only symptoms that may be present are localized tenderness, inability of outward rotation, and ecchymosis. When there is an accompanying dislocation of the head of the humerus, the presence of fracture may be overlooked. Some authorities maintain there is a marked liability to the recurrence of the dislocation of the head of the humerus when accompanied by fracture of the greater tuberosity.

Diagnosis.—A diagnosis may be made from localized tenderness, failure of voluntary outward rotation, absence of shortening, occasional crepitus, absence of flattening of the shoulder, and the retention of rotation of the head of the bone with the shaft.

Treatment.—Where the fragment remains in its normal position due to the attached periosteum, the only dressing required will be a wrist-sling, a swathe fixing the arm to the chest and wall, and a protective shoulder cap. When the tuberosity is displaced upward and outward, the arm should be fixed in a position of abduction and outward rotation. When the displaced fragment tends to interpose between the acromion and the head of the humerus, the fragment should be exposed and nailed in its proper place as suggested and performed by Keen.

Isolated fractures of the lesser tuberosity are more infrequent than those of the greater tuberosity. They have been observed accompanying an anterior dislocation of the head of the humerus, a fracture of the greater tuberosity, or a fracture of the anatomical neck. When seen unaccompanied by other lesion, the fracture is generally due to forcible outward rotation of the arm or to sudden contraction of the subscapularis muscle. When separation of the tuberosity takes place, the inner edge of the occipital groove is removed, and dislocation of the long tendon of the biceps muscle may occur.

Symptoms.—Inward rotation of the humerus is impossible. Outward rotation is increased. There is generally marked tenderness the coracoid process and a firm mass not moving with rotation lt in the position of the small tubercle. Bardenheuer tends to assume a position of outward rotation.

Crepitus may at times be felt on forcible inward rotation of the humerus.

Diagnosis.—This can be made by the inability of voluntary inward rotation of the arm, the presence of tenderness, and the detection of a firm mass and occasional crepitus just outside and below the coracoid process. A radiogram will settle the diagnosis.

Treatment.—This consists in flexion of the forearm upon the arm to relax the biceps muscle, adduction, and inward rotation. This posture is maintained by a wrist-sling, a swathe binding the arm to the chest wall, and a protective shoulder cap. Fixation should be continued for four weeks, and judicious massage and gentle passive motion begun at the end of ten days. The late results are good.

Separation of the Upper Epiphysis.—The shape and limits of the upper epiphysis of the humerus may readily be seen by the accompanying radiograms (Figs. 314–316). The upper epiphysis is formed of the head and the two tuberosities. The line of the epiphyseal cartilage in its inner third is the same as that of the anatomical neck, and the remaining portion passes outward just below the tuberosities. The under surface of the epiphysis is cup-shaped, deeper in its centre than at its periphery.

Epiphyseal separations (Figs. 329 and 330) have been observed from infancy to the twentieth year of life. They occur most frequently between the age of eight and eighteen. In many cases there is only a separation at the line of the epiphyseal cartilage, but in a considerable number of cases, in addition to the separation of the epiphysis, there is a fracture cutting off a wedge-shaped portion of the upper end of the diaphysis. This remains attached to the epiphysis. One should remember that only after the third year is it possible to distinguish the entire epiphysis by radiogram on account of the three centres of ossification appearing at this time.

Etiology.—Separations of the upper epiphysis of the humerus have been observed in infants after childbirth due to traction upon the arm, to inward pressure upon the outer surface of the humerus, or to injury from the finger of the obstetrician hooked into the axilla. The injury in other instances is generally the result of direct violence, as a fall directly upon the shoulder, or of indirect violence, as by hyperabduction of the arm, or by forcible outward rotation combined with traction. The condition may also be the result of a fall upon the elbow when the arm is in abduction.

Symptoms.—In many cases there may be no gross deformity to the shoulder region aside from a general swelling. If the separation takes place with a fracture of a portion of the upper end of the diaphysis, as is

seen in young children, the head of the bone may be rotated by the attached muscles so that the articular surface is directed downward and the fractured surface upward. The upper end of the diaphysis may assume an outward position, it may be found posterior, anterior or dislocated into the axilla, and its end may be felt in any of these positions The anterior dislocation of the upper end of the shaft is a very common form of deformity (Figs. 331–335). When the end is displaced

Fig. 329. Fig. 330.

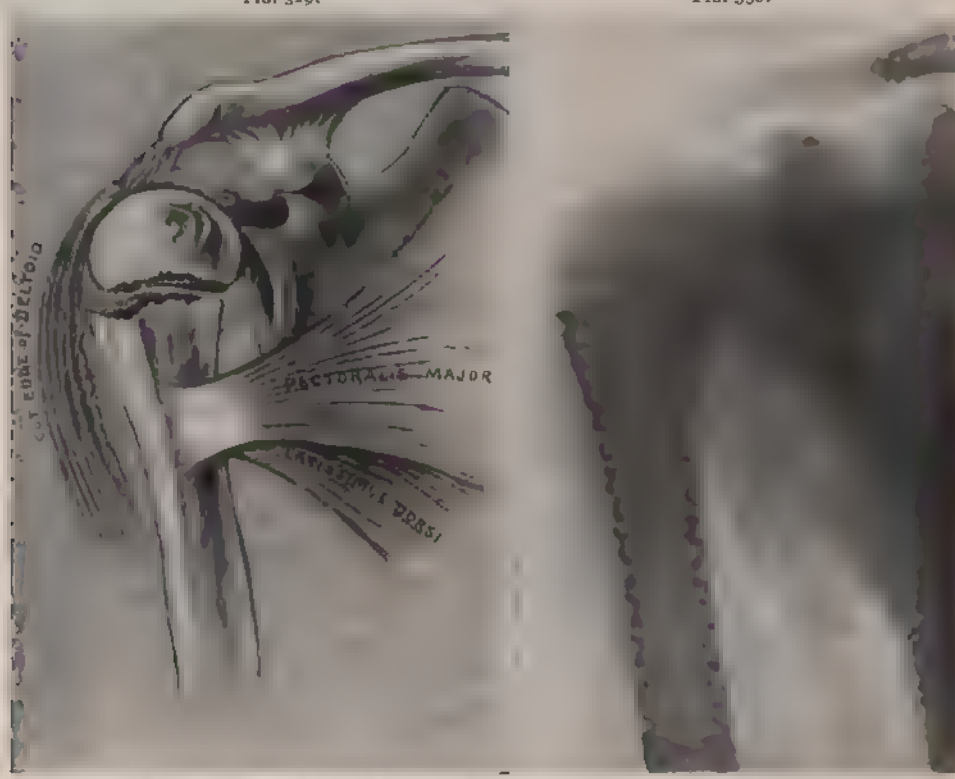

Fig. 329.—Drawing to show the usual character of epiphyseal separation. A portion of the diaphysis is usually attached to the separated epiphysis. (Made after roentgenograms of Fig. 330.)
Fig. 330.—Separation of upper epiphysis of humerus. Note that a small portion of the edge of the diaphysis is attached to the epiphyses. (See Fig. 329.)

into the axilla, it may be below the coracoid process and readily detected. Crepitus is generally soft in character unless a fracture of a portion of the diaphysis is also present, in which instance true bony crepitus may be elicited in the absence of impaction of fragments. Pain, disability, and ecchymosis appearing in the course of several days are characteristic symptoms. Passive rotation of the elbow discloses absence of rotation of the head of the bone in non-

impacted fractures; when the latter condition is present rotation of the head occurs. In some cases there may be considerable stripping up of the periosteum which remains attached to the two fragments and prevents reduction.

Diagnosis.—In making a correct diagnosis of this lesion the radiogram is often invaluable. At other times it may be of little use. It should be used. Before the third year of life the radiogram will be of

FIG. 331 FIG. 332.

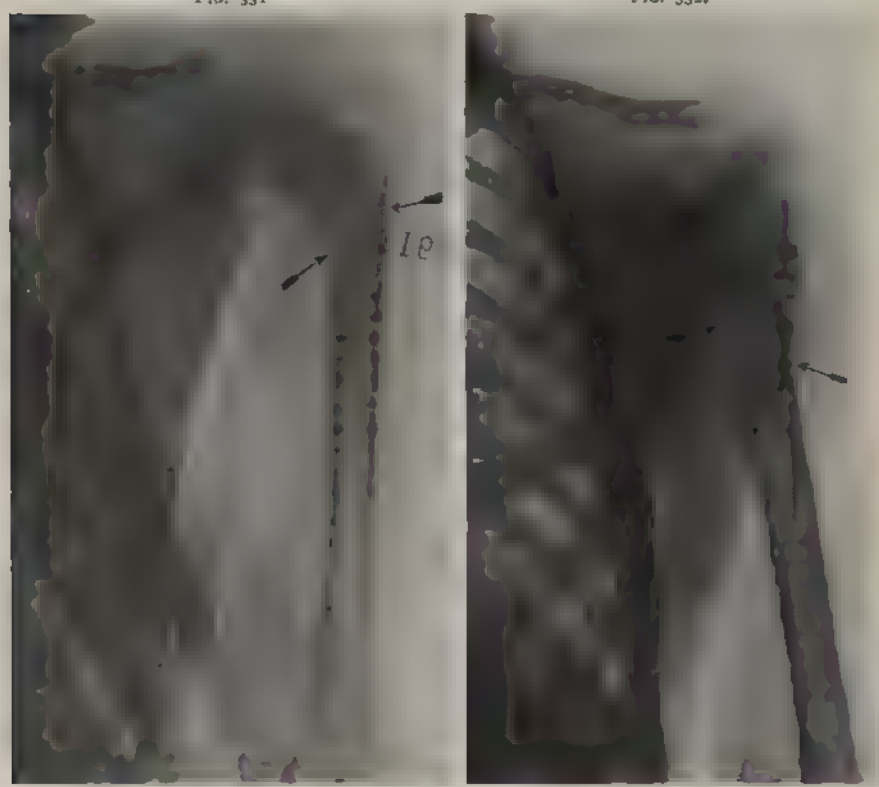

FIG. 331.—Separation of upper epiphysis of humerus. Note that line of fracture begins at the epiphyseal line and that an unusually large fragment of the diaphysis is attached to the epiphyses (Before reduction.)

FIG. 332. Same as Fig. 331, after reduction.

little value and the diagnosis will depend greatly upon the deformity that may be present, localized pain, and an inability of voluntary movements. After this time of life it is of value in recognizing separations that have not been perfectly reduced, and in those in which there is a fracture of the diaphysis of the adherence of a small fragment of bone to the epiphysis. In some patients examined a considerable time after injury it is possible to diagnose a previous epiphyseal separation

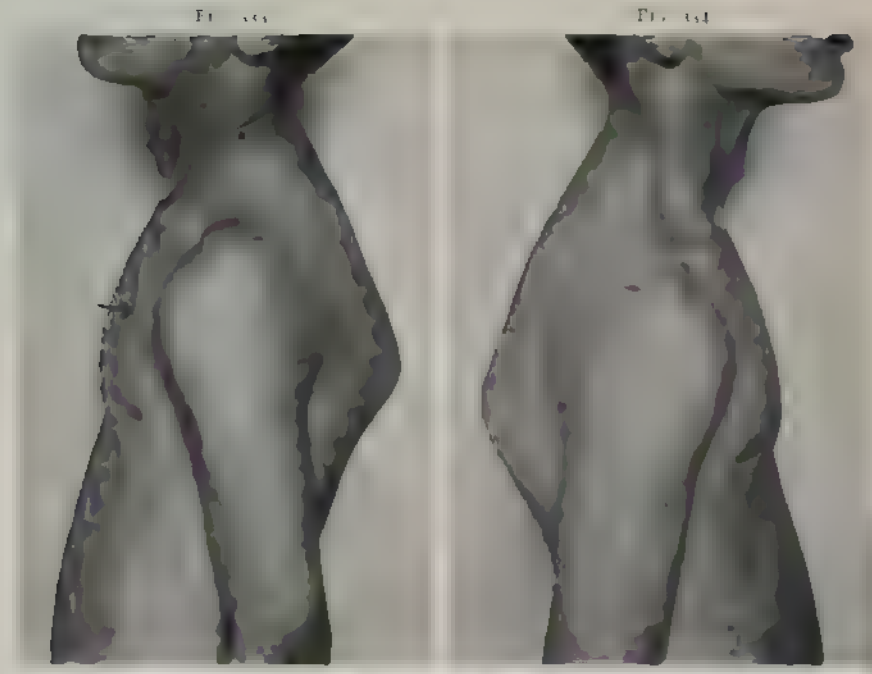

FIGS. 343 AND 344.—Photographs of case (Figs. 341 and 342) of separation of upper epiphysis of left humerus. Fig. 343 shows upper end of diaphysis is displaced forward producing the swelling observed at the anterior aspect of the left shoulder. Fig. 344 normal right shoulder for comparison.

FIG. 345.—Photograph taken ten weeks after injury, all motions of the leg and shoulder are normal excepting abduction, which is still slightly impaired.

by the radiogram showing new bone formation. A careful comparison with the radiogram of the sound shoulder is frequently essential, and very often radiograms taken in several planes will be necessary. Other

signs by which a diagnosis may be made are visible projection of the upper end of the diaphysis, change in the normal axis of the humerus, and occasional shortening and distortion of the anterior axillary fold.

Treatment.—In uncomplicated cases without displacement of fragments and in those in which reduction may readily be accomplished by means of traction, hyperabduction and manipulation, retention is best maintained by placing a small folded towel in the axilla, and fixing the arm to the chest wall by a modified Velpeau dressing. When reduction is difficult, a general anæsthetic, preferably nitrous oxide gas, should be used; then by forced traction, hyperabduction and manipulation, reduction may usually be accomplished. The arm is to be dressed with the modified Velpeau bandage. If a secondary radiogram shows partial recurrence of the deformity, the arm should be placed in a

FIG. 336



FIG. 337

FIG. 336.—Oblique fracture of surgical neck of left humerus.
FIG. 337.—Comminuted fracture of surgical neck of right humerus.

position of permanent abduction and held there by a Monks splint or a gypsum encasement or by permanent traction with weight and pulley. In the last method the patient is kept in bed for several weeks. When reduction cannot be accomplished, owing to rotation of the epiphysis or to the presence of a portion of attached periosteum preventing replacement, incision and subsequent reduction should be adopted. The line of separation should be exposed, the fragments reduced and coaptation maintained by chromic catgut or fine, flexible wire sutures passed through the periosteum. One should avoid doing too much injury to the epiphyseal cartilage by the insertion of sutures, nails or screws through it. Serial radiograms should be made after reduction to ascertain whether reduction is being maintained.

After-results.—Interference with the subsequent growth of the humerus from the upper end is always a possibility in diastases of epiphyses. In giving a prognosis this liability should always be remem-

bered. After union takes place there will generally be some temporary reduction of abduction and rotation, which should disappear within three to four months.

Fractures of the Surgical Neck (Figs. 336–338).—In this group of fractures are included those occurring between the epiphyseal line

FIG. 338

FIG. 339.



FIG. 338.—Humerus, left, fracture of the surgical neck, union. The fracture passed immediately below the condyles and through the lower portion of the anatomical neck. The lower fragment was drawn to the inner side and has united in a position of outward rotation, an irregular opening leads through the callus in the anterior surface to the head. The union is firm. (Mutter Museum, No. 1262 15.)

FIG. 339.—Method of determining shortening in fracture of the humerus by measuring from the acromion process of the scapula to the external condyle of the humerus, and comparison with the same measurement of the other arm.

and the attachment of the greater pectoral muscle. The level of the fracture line is subject to considerable variation; it may extend upward into the head of the bone as seen in comminuted fractures, or it may descend to a lower level than the upper edge of the attached pectoral muscle, as in oblique fractures. The line of fracture may be transverse, oblique, spiral, or comminuted in character. The frag-

ments may be impacted or non-impacted. In Plagemann's 22 cases the lines of fracture were transverse in 10 instances, oblique in 3, spiral in 2, and in 7 cases there was a bending fracture with the breaking off of a three-cornered piece from the cortex of the humerus. The spiral fractures were found especially in the young, the oblique and bending fractures in strong men, while the transverse fractures were observed at all ages. Fractures in this area are considered by many authorities to occur in the adult as a result of such violence as in chil-

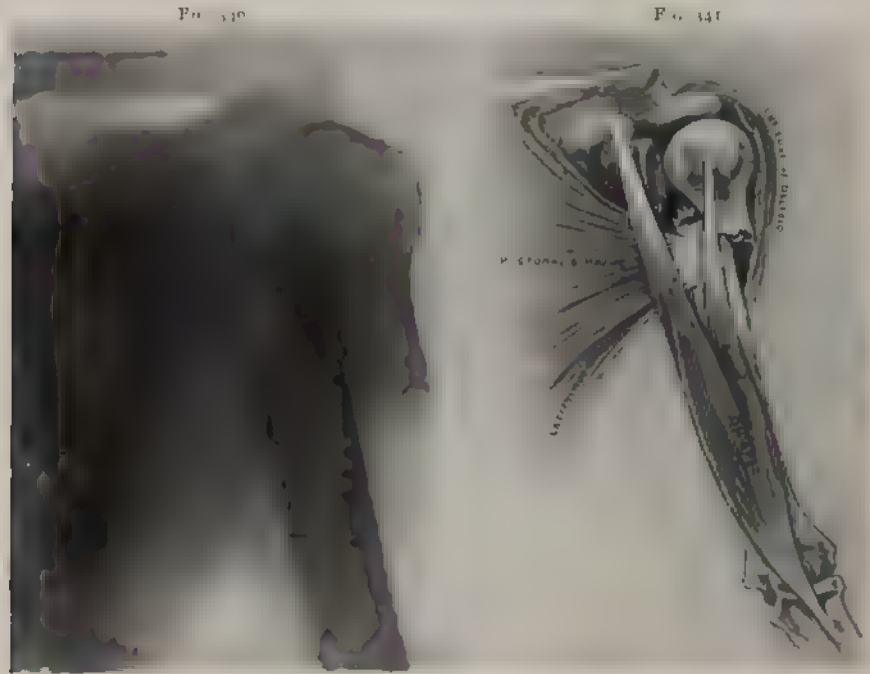

FIG. 340. Fracture of humerus through surgical neck and low
FIG. 341. Drawing to show the displacement of fragments in Fig 340, and the muscles which determine the character of the displacement.

dren produces an epiphyseal separation. While this may be partially so attention is directed to the many fractures of the surgical neck occurring during childhood, and in which there is no lesion of the epiphyseal cartilage. Comminution and associated fractures of the tuberosities are frequently seen.

Etiology.—The fracture may result from falls upon the lateral or anterior aspect of the shoulder, from a blow directed downward upon the upper arm when the latter is in a position of abduction, from hyperabduction with leverage against the acromion process, by falls upon the hand or elbow and rarely by muscular action.

Symptoms.—In fractures of this variety there are localized pain, tenderness, complete or almost complete inability to use the arm, swelling, and effusion of blood in the tissues. In impacted fracture, there is generally some thickening of the bone at the seat of fracture, due in many cases to comminution of fragments, and flattening of the shoulder externally; the arm is held supported by the other hand, and is generally kept close to the side. There may be moderate deformity at the seat of fracture due to slight displacement of the upper end of the lower fragment inward, and slight internal angulation. The shortening is generally slight and is dependent upon the degree of impaction. Rotation of the elbow shows coincident rotation of the head of the humerus. In non-impacted fractures in addition to the local signs of fracture there is often marked shortening (Fig. 339), as measured from the tip of the acromion process to the external condyle, and the head of the bone fails to rotate with rotation of the shaft and elbow. The deformity may be slight or extensive. When this is present the upper fragment is generally abducted and rotated outward, due to the pull of the muscles attached to the tuberosities, or it may be rotated inward, upward and forward; while the upper end of the lower fragment is drawn inward, upward and forward by the pull of the pectoralis major, teres major and latissimus dorsi muscles (Figs. 340 and 341). The upper end of the lower fragment may, however, be displaced upward and outward by the pull of the deltoid muscle, in those cases of oblique fracture in which the line of fracture is from without, running inward, and downward. Abduction of the elbow is constant as a rule, and in some cases may resemble the position assumed in interior dislocations of the head of the humerus. Crepitus is generally obtainable in all cases of non-impacted fractures after reduction has been accomplished, and in most cases before reduction has been attempted. In all non-impacted fractures there is a marked depression at the insertion of the deltoid muscle. The exact line of fracture and the dislocation of the fragments may readily be determined by the radiogram.



FIG 342. Method of reduction of fragments in fracture of the surgical neck of the humerus by traction and manipulation.

Diagnosis.—In the ordinary case diagnosis of fracture of the surgical neck is generally made without difficulty. In impacted fractures the diagnosis will be determined by the presence of localized pain, swelling, thickening about the site of the suspected fracture, ecchymosis, inability to use the arm, the presence of moderate deformity, and the radiogram. In non-impacted fractures the diagnosis will be made from localized signs of fracture plus crepitus, abnormal mobility, characteristic deformity, shortening, and the failure of the head of the bone though in its normal position to rotate with rotation of the elbow and shaft. The radiogram of course acts as contributory evidence of a fracture. Fracture of the surgical neck may be differentiated from dislocation of the head of the humerus by the presence of the head of

FIG. 343. Dressing for fracture of the surgical neck of the humerus. After reduction of the fragments, the arm should be kept away from the chest wall by a moderately thick pad, the forearm supported by a wrist sling, and the shoulder region protected by a shoulder cap.

FIG. 344. Shows completed dressing for fracture of the surgical neck of the humerus.

the bone in the glenoid cavity, by crepitus, and the other characteristic signs of fracture. High fractures of the surgical neck are often mistaken for fractures of the anatomical neck

Complications.—These are injury to the axillary vessels or the brachial plexus, empalement of the muscles and at times the skin by sharp fragments, and rupture of the tendon of the biceps muscle. These complications are, as a rule, rare.

Treatment.—The form of treatment of fractures of the surgical neck of the humerus is dependent in a great measure upon the occurrence or non-occurrence of impaction of fragments.

In impaction of fragments, in which the radiogram shows little displacement and slight mal-alignment, the best results will be obtained

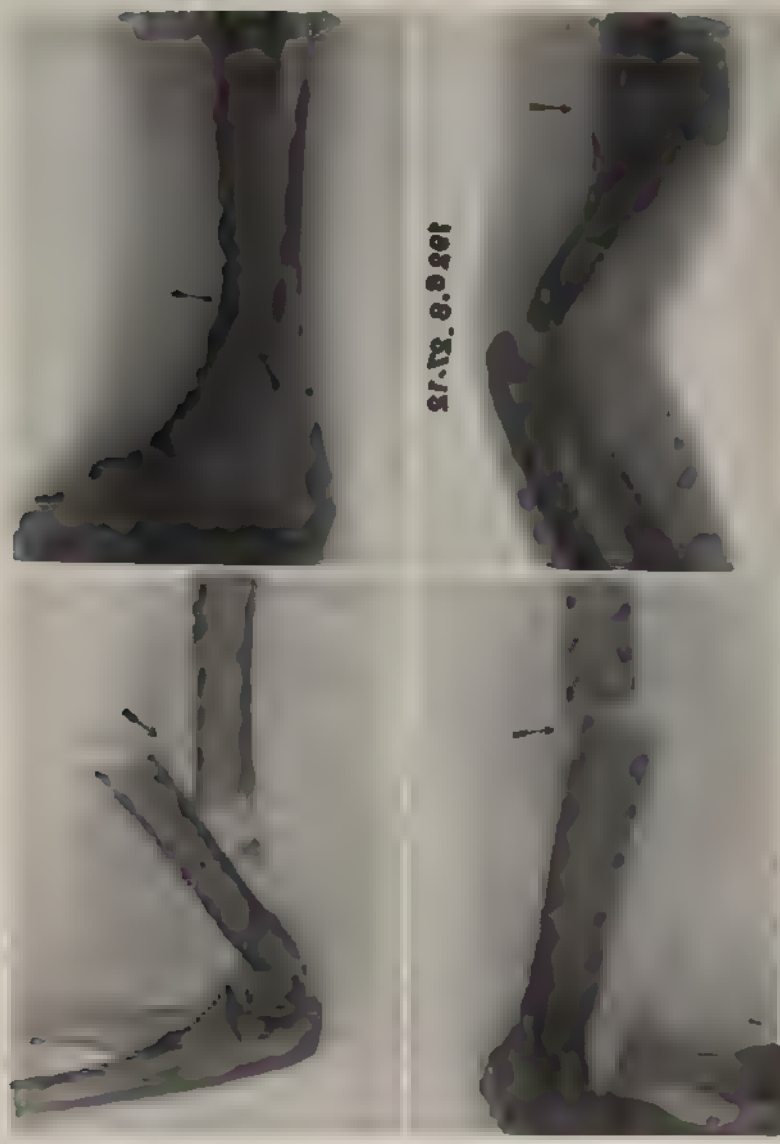

Fig. 345. Fig. 346.

Fig. 347. Fig. 348.

Fig. 345.—Spiral fracture of shaft of humerus.

Fig. 346.—Irregular transverse fracture of the shaft of the humerus. Reduction and immobilization have been faulty, so that union has occurred with marked deformity, angularity and over-riding. Note the extensive area as which has been produced not only at the seat of fracture, but also for a long distance away, due to the stripping up of the periosteum.

Fig. 347.—Transverse fracture of middle of shaft of humerus.

Fig. 348.—Oblique fracture of shaft of humerus with over-riding and angular deformity.

probably by avoiding separation of fragments and using a wrist-sling, a small axillary pad, a circular swathe binding the arm to the chest,

and a protective shoulder cap. Gentle massage and passive motion should be begun at the end of the third or the fourth day and immobilization continued for three to four weeks

In non-impacted fractures the line of procedure and form of treatment are entirely different. The best results are obtained by complete reduction and apposition of the fractured ends. In many instances this can be accomplished by traction and manipulation alone (Fig. 342) during thorough muscular relaxation obtained under general anæsthesia. After reduction three forms of retention are favorable. In the transverse fractures, reduction is not as a rule followed by recurrence of deformity if proper retentive apparatus is applied It is desirable to use an axillary pad to control the inward pull of the greater pectoral and broad dorsal muscles, to employ a wrist-sling, to fix the arm to the chest wall with a swathe, and perhaps to protect the region with a shoulder-cap splint (Figs 343 and 344). The last is often unnecessary and sometimes undesirable. The cases in which this dressing will not prevent recurrence of deformity are as a rule the oblique, spiral, and multiple fractures. For these, ambulatory treatment with the use of vertical traction is sometimes sufficient but may be inefficient because it is seldom constant. A considerable number of these cases are best treated by recumbency in bed and the application of continuous traction apparatus in the abducted position. There are, however, a small number of these fractures in which, for various reasons, ideal results cannot be obtained by either of these methods; in these it is wise to adopt open operation and obtain anatomical approximation and fixation by means of a metal plate or perhaps by the absorbable catgut mat of Straus plate. The ideal incision is made along the anterior border of the deltoid muscle.



FIG. 349.—Long oblique fracture of shaft of humerus.

Many fractures at the upper end of the humerus may be satisfactorily treated by simple restraint of motion induced by carrying a broad strip of adhesive plaster or bandage once around the arm and chest and placing the wrist in a narrow sling. Other fractures in this region may need in addition the hollow of the axilla filled with a folded napkin or thin compress and the arm secured against the chest with the elbow carried a little forward. By these dressings the thorax acts

FIG. 350 FIG. 351.

FIG. 350.—Transverse fracture of the shaft of the humerus. (See Fig. 351.)
FIG. 351.—Drawing made from Fig. 350 to demonstrate the action of the muscles which determine to a great extent the character of the displacement of the fragments in fracture below the attachment of the pectoralis major muscle.

as a splint. In such cases the shoulder cap of gypsum or other rigid material is usually unnecessary.

After-results.—These are generally good. Impairment of full motion persists for a time, but can be overcome by persistent massage and passive motions. In some cases there will be permanent impairment of motion due to exuberant callus, to failure to properly reduce and maintain reduction, to comminution of fragments, and to involvement of muscles in projecting sharp fragments. Pseudarthrosis is infrequent, and delayed union when seen is not generally permanent.

Fractures of the Shaft of the Humerus.

Varieties of Fractures (Figs. 345–349).—Fractures of the shaft of the humerus include all fractures involving the diaphysis between the insertion of the pectoralis major muscle and the upper limits of the supracondylar ridges. These fractures are as a rule complete and closed in character. Occasionally an incomplete fracture of the shaft is observed in children. Plagemann, in the 18 cases of his statistics, gives the lines of fracture as follows: 11 transverse, 2 oblique, 3 spiral and 2 bending fractures with the separation of a rhomboidal piece of bone. Longitudinal fractures are extremely rare, but have been reported by Gurlt, Cloquet and Krönlein.

Etiology.—Fractures of the shaft are the result of external violence or muscular action. Fractures by external violence result from a direct blow, a fall upon the arm against some object, by crushing accidents and collision of vehicles. Fractures in these regions by indirect violence such as a fall upon the elbow or hand are extremely rare. Fractures by muscular action are more frequent in the shaft of the humerus than in any other bone. They result from the throwing of objects, the use of racquets, in tests of strength and in wrestling. Pathologic fractures are not infrequent in the shaft of the humerus, and occur from malignant or other disease of the bone, and in nervous affections, particularly in tabes dorsalis and syringomyelia.

Symptoms.—The symptoms of fractures of the shaft are those common to all fractures, such as loss of function, pain, tenderness, crepitus, abnormal mobility, and deformity. The last is dependent upon the site of fracture, the fracturing force, and the pull of muscles. In fractures of the upper third the lower end of the upper fragment is drawn inward by the pectoralis major, latissimus dorsi, and teres major muscles, and the upper end of the lower fragment pulled upward by the deltoid, and in some degree by the biceps and triceps muscles (Figs. 350 and 351). In fractures of the middle third there may be slight overlapping of the fragments; generally it is absent. In fractures at the junction of the middle and lower thirds the upper fragment is not displaced to any appreciable extent, but the lower fragment is apt to be drawn upward and backward by the triceps muscle.

Diagnosis.—This may readily be made by the usual evidence of fracture and radiograms. Little difficulty is experienced in making a diagnosis.

Complications.—The complications of fracture of the shaft are injury to the blood-vessels or to the nerves, and pyogenic infection in open fractures. Injury to the blood-vessels may be the result of the fracturing force or may be due to puncture or laceration of the brachial artery and its accompanying veins from sharp fragments of bone, and

is shown by the development of thrombosis and gangrene. Injury to the nerves may consist in laceration from sharp fragments, inclusion of a nerve in callus, or the result of over-stretching. The nerve most frequently injured is the musculospiral, although the median and ulnar nerves may also suffer injury. Von Bruns reports 189 injuries of nerves complicating fractures; and of these 138 were of the upper extremity. The musculospiral was involved in 77 cases, the ulnar in 19, and the median in 17. In 52 per cent. of cases of injury to the musculospiral nerve the fracture was in the middle third, and in 38 per cent. in the lower third. Blenke, in a report of 68 cases of musculospiral paralysis found that the fracture was in the middle third in 56.3 per cent. and in the lower third in 41.3 per cent.

FIG. 352.—Röntgenogram of oblique fracture of the shaft of the humerus in the region of the musculospiral nerve; followed by paralysis of the muscles supplied by this nerve.

Three forms of musculospiral paralysis are recognized: *Primary paralysis* is due to the nerve injury caused either by the fracturing force, by the sharp ends of fragments, or by being caught between fragments and crushed. Even with apparent continuity of nerve structure the nerve-fibres may be destroyed within the neurilemma. *Intermediate paralysis* (Figs. 352 and 353) is due to the stretching of the nerve over dislocated fragments and may appear within a few hours or it may not appear for several days. *Secondary paralysis* does not appear until the end of three to four weeks and is due to pressure from surrounding or lateral callus or to pressure from cicatricial tissue. The symptoms of nerve injury may appear immediately or later, and are shown by motor paralysis and loss of sensation over the region supplied by the nerve. The most common symptoms of injury to the musculospiral nerve is wrist-drop. When the nerve is only irritated hyperæsthesia

ent.

ight forms of paralysis due to compression, it is often the

rule that recovery takes place within a few months without any treatment being applied to the nerve itself. In such cases support of the

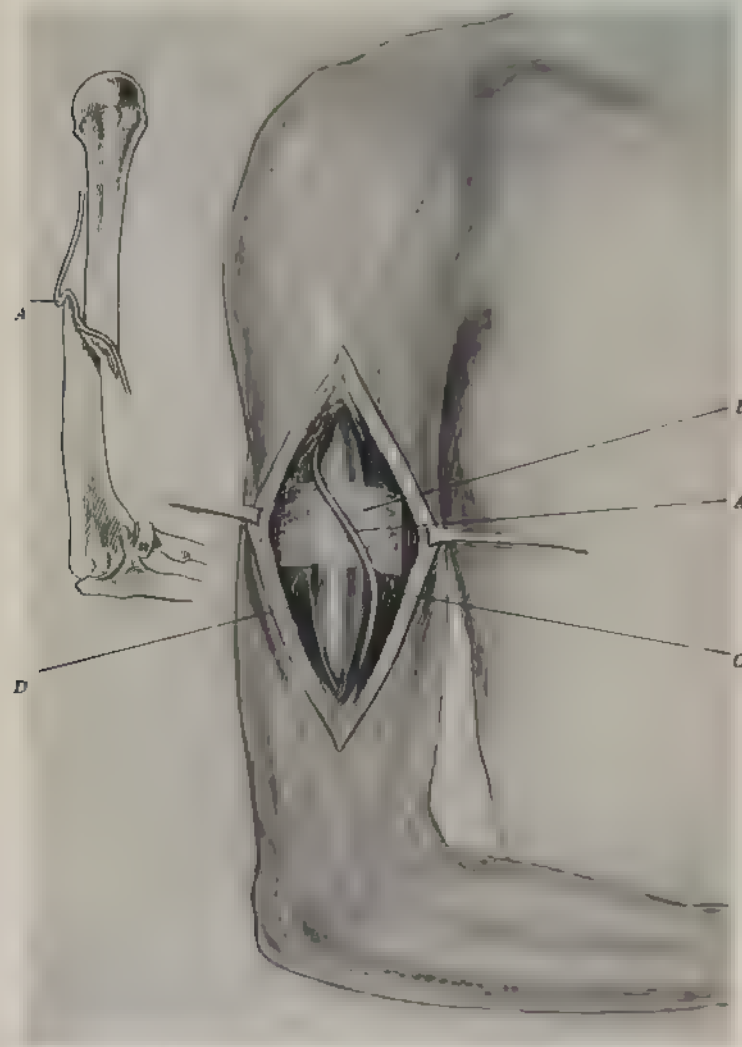

FIG. 353.—Drawing to show operation for musculospiral paralysis occurring as a complication of fracture of the shaft of the humerus. Small figure shows the nerve (*A*) pierced by the sharp point of the lower fragment and caught between the fragments as found at operation. Large figure shows nerve (*A*) separated from the fragments of the humerus (the point of lower fragment being removed) by a flap of fascia (*B*), taken from the subcutaneous fascia at the posterior part of the incision (*D*), which has been carried forward and is sutured to the biceps muscle (*C*). (See roentgenogram, Fig. 352.)

forearm and hand, combined with massage, passive motion, and electricity, will be followed by restoration to the normal condition.

When severe injury to the nerve has occurred and the reactions of degeneration are present, or in those instances in which secondary

" wrist-drop " has occurred as a result of the presence of callus, operative means of restoration of nerve continuity or release from callus will be necessary. If the nerve is torn completely across, attempts should be made to suture the severed ends by direct apposition or by plastic neurorrhaphy; if this is impossible on account of great loss of nerve tissue, the intervening gap may be filled by a graft from the radial nerve or the ends of the severed nerve may be implanted into the median nerve. Perhaps a graft might be furnished by the patient's sciatic nerve, which is so large as scarcely to miss the small strip required.

When the paralysis is the result of ensheathing callus, this should be chiselled away; this procedure may be expected to give complete restoration of function after a sufficient time has elapsed. When the paralysis proves to be permanent, the disability may be improved by tendon grafting of the muscles in the affected region.

Treatment.—All fractures of the shaft of the humerus should first be carefully examined for evidence of injury to blood-vessels and nerves. If these complications do not exist, reduction and immobilization of the fragments should be performed. Fractures of the shaft should be thoroughly reduced, under general anæsthesia, if there is doubt as to the replacement and no contraindication exists to using nitrous oxide or ether. Transverse fractures as a rule remain in good position after reduction and proper immobilization. Spiral oblique and comminuted fractures are more difficult to retain in proper anatomical adjustment by non-operative means. It is probable that the comparatively frequent non-union, delayed union, or pseudarthrosis in brachial fractures is due to improper reduction and faulty immobilization. If reduction is not accomplished, muscular tissue is apt to separate the fragments and lead to non-union. If a dressing is applied which checks motion at the elbow-joint and produces increased motion at the seat of fracture, pseudarthrosis is likely to result. In transverse, and in some spiral, oblique and comminuted fractures, the following dressing is recommended: surround the arm from elbow to shoulder with several layers of sheet-wadding, apply coaptation splints anterior, internal, posterior and external, place a small pad in the axilla, bind the arm to the chest wall, apply a shoulder cap for protection and a small wrist-sling (Figs. 354–356). The weight of the forearm and arm will give some traction, but it is by preventing the over-riding of the fragments and by securing muscular rest that anatomical apposition is preserved and union secured by this dressing. In spiral and oblique fractures, when the fragments tend to become displaced, the Middledorpf triangular apparatus or the Monks splint may be tried.

Fig. 354



Fig. 355



Fig. 356



Figs. 354, 355 and 356.—Method of applying dressing for fracture of shaft of humerus. Fig. 354 shows axillary pad, arm protected by circular layers of sheet-wadding, cotton roller bandage to hand and forearm, coaptation splints about arm and wrist shell. Fig. 355 shows padded shoulder cap and arm bound to chest by a broad strip of adhesive plaster. Fig. 356 shows completed dressing.

These cases generally require traction, and it may be obtained by the Hamilton adhesive plaster extension apparatus supplemented by bed traction at night. In those cases in which one is unable to obtain anatomical apposition by any of these means open operation and the use of a metal plate, nails or screws, or an absorbable fixation appliance are advocated.

Fractures in the upper third of the shaft may often be well treated by the simple dressing described for fractures of the upper end of the bone. In such cases the axillary pad may act better if wedge shaped with the base of the wedge downwards. In this form of dressing it is well to see that pressure is not great on the brachial artery by determining the presence of the radial pulse after the upper arm has been bandaged to the chest.

When the shaft is broken above the insertion of the deltoid the upper fragment is liable to be pulled inward by the axillary muscles and the lower fragment pulled upward and outward by deltoid action. When the fracture is below the deltoid insertion the upper fragment may be displaced outward by the pull of that muscle, and the lower fragment have its upper extremity displaced toward the axilla by the biceps, triceps and coraco-brachial muscles.

Instead of using coaptation splints for fractures in the middle of the shaft a moulded gypsum contour splint on the inner aspect of the arm from axilla to the palm of the semi-supinated hand may be employed. A short gypsum contour splint from shoulder to elbow added on the outside of the arm sometimes may be needed for additional support.

In fractures of the lower part of the shaft angular deformity is not uncommon. This is due to the elbow being flexed by the muscles attached to the condyles of the humerus. Accordingly these bring the upper end of the lower fragment forward, when gravity causes the forearm to drop.

After reduction low shaft fractures are usually satisfactorily maintained in coaptation by means of a plastic contour splint moulded to arm, forearm and palm with the elbow flexed at right angle and the wrist extended with the hand supine. The plastic splint should be reënforced at elbow by additional layers, or an angle of metal. The right angle posture of the elbow is not advisable as a rule in fractures close to or involving the condylar end of the bone.

After-results.—In uncomplicated fractures of the shaft of the humerus, union occurs in three to five weeks. With comminution of fragments union requires a longer time, possibly five to eight weeks. Fractures of the upper and of the lower third, uniting with the formation of considerable callus or deformity, are often followed by a

moderate degree of impairment of motion at the shoulder- or elbow-joint, respectively.

Failure of union occurs more frequently following fractures of the shaft of the humerus than of any other bone. Von Bruns records 376 cases of ununited fractures among 1274 cases of all bones. Of these he estimates that only 56 per cent. of recoveries follow resection. In 187 cases of pseudo-arthrosis of the humerus so treated, 98 recovered, 3 were improved, 73 were unimproved and 5 died.

The causes of delayed union and pseudo-arthrosis may be interposed muscular tissue, injury of nerves or blood-vessels, or necrosis of the ends of the fragments. General systemic conditions may here as elsewhere be the cause.

The treatment consists in massage, injection of blood, or irritating substances such as tincture of iodine, the use of Bier's hyperæmia; and finally open operation with resection of the fragments or the inlaying of an autoplastic bone graft applied laterally, or the insertion of an autoplastic bone dowel into the medullary cavity.

Fractures of the Lower End of the Humerus

Varieties of Fractures.—The following forms of fracture of the lower end of humerus may be described: (1) supracondylar; (2) diacondylar; (3) intercondylar, T, Y, or atypical; (4) separation of the lower epiphysis; (5) external epicondyle; (6) external condyle; (7) capitellum; (8) internal epicondyle; (9) internal condyle; (10) trochlea.

In a consideration of fractures of the lower end of the humerus there are several very important facts to be borne in mind. The normal outlines (Figs. 357–360) as shown by röntgenogram, should be carefully studied, in the adult and in children. Certain varieties are seen more often in childhood, while other forms are met with more frequency in adult life. Fractures occurring during childhood are, as a rule, the result of indirect violence transmitted through the hand and forearm to the elbow. The majority of these fractures observed in children result from hyperextension, combined with abduction or adduction. On the other hand, fractures of the lower end of the humerus observed in adult life are usually the result of machinery accidents or direct crushing injuries, and are seldom observed occurring from indirect violence as a result of a fall upon the hand with the elbow in a position of hyperextension. When fractures do occur in adults from indirect force, the resulting fracture partakes of the nature of a sprain-fracture, as a rule. On account of this diversity in etiology and in lesions observed during childhood and adult life some authorities have been led to consider these fractures separately.

Other differences observed in these two classes are that while, in

children, marked deformity may be followed by distinct disability for a period of from six months to a year, still in the course of several years the absorption of callus, bony development, and adaptability of

FIG. 357.

FIG. 358.

[illegible] [illegible] and lateral views. [illegible] Antero- [illegible]

the [illegible] give a result that often can hardly be distinguished [illegible] In adults, however, the reverse is gen-

erally the case. Unless good and very often perfect anatomical apposition of the fragments is obtained, the resulting changes in the carry-

FIG. 361. FIG. 362.



FIG. 361.—Supracondylar fracture of humerus, very little displacement of fragments. Anteroposterior view. (See Fig. 362.)

FIG. 362.—Supracondylar fracture of humerus, extension type. Lateral view. (See Fig. 361.)

FIG. 363 FIG. 364



FIG. 363.—Supracondylar fracture of humerus. Lower fragment has stripped off periosteum for a considerable distance from the diaphysis with resulting ossification along periosteum. Anteroposterior view. (See Fig. 364.)

FIG. 364.—Supracondylar fracture of humerus. Lateral view. Extension type. (See Fig. 363.)

ing angle and the development of osteoarthritis will be followed not only by deformity but by great impairment in function.

Supracondylar Fractures (Figs. 361–364).—In this form of fracture the fracture line occupies a more or less transverse position across the humerus just above the tips of the external and internal epicondyles. It should not be confused with a low fracture of the shaft (Figs. 365 and 366) or with a diacondylar fracture. In 103 fractures of the lower end of the humerus Plagemann found 43 supracondylar fractures. Wendt in 134 fractures, 61 cases, and in a later classification 102 times in 302 fractures of the lower humeral end. Hilgenreiner found in 110 fractures of the lower end 21 instances of this variety. Of the 43 supracondylar fractures of Plagemann's classification, all were observed in children between the ages of three to fourteen



FIG. 365. FIG. 366.

FIGS. 365 AND 366.—Low fracture of the shaft of the humerus. This should not be confused with the supracondylar type of fracture.

years with the exception of 3 cases, occurring at eighteen, thirty-two and forty-eight years.

The supracondylar fractures have been grouped in the following four classes by Kocher, and in these classes Plagemann divides his 43 cases as follows: 31 extension fractures, 5 flexion fractures, 5 abduction fractures, 2 adduction fractures.

In the extension fractures the line of fracture is from a point just above the attachment of the joint capsule on the anterior surface, upward and backward, and in addition the line of fracture runs from a plane on the external surface inward and upward. The fracture is the result generally of a fall upon the outstretched hand with the elbow in hyperextension and abduction; the resulting fracture takes place just above the attachment of the joint capsule. This fracture is seen

so frequently in children on account of the greater strength of the capsule than that of the attached bone. Fractures of this variety are never observed in adults produced in this manner, but are always the result of direct violence. The dislocation backward of the lower end of the humerus may be great but in some cases little dislocation is present.

In flexion fractures the line of fracture is low posteriorly and runs forward and upward. This form of fracture is very rare. Its mechanism is more or less theoretical. It is considered to be the result of a fall upon the extensor surface of the semi-flexed forearm, and it is thought that the line of force is transmitted directly upward in the line of the long axis of the humerus. When it is considered that the condyles occupy a plane anterior to this long axis, it can be readily understood how the cubital process may be fractured from the lower end of the shaft of the humerus and displaced upward. In fractures by extension the lower end of the upper fragment is displaced anteriorly by its fellow fragment, while in the flexion variety of fracture the lower end of the upper fragment is displaced posteriorly.

In the abduction fracture the line of fracture runs from inward and below upward and outward. These cases appear to be the result of hyperabduction with the elbow in full extension.

In the adduction fractures the line of break is the reverse, being from below and on the outside to a point upward and inward. These fractures are the result of hyperadduction with the elbow in full extension. The last two varieties may be incomplete and show only an infraction of the outer or inner cortex of the bone.

Symptoms.—The symptoms common to all fractures of the lower end of the humerus are pain, tenderness, swelling, ecchymosis, loss of function. In addition to these there are symptoms characteristic of the different fractures. In the fracture by extension the usual deformity is an anterior displacement of the lower end of the upper fragment forward and a posterior displacement of the lower fragment with the attached structures of the elbow-joint. The condition at first glance closely resembles a posterior dislocation of the radius and ulna, and the two conditions should carefully be differentiated. This posterior displacement is due to the fracturing force, to the muscular pull upward and backward of the triceps muscle, and to the upward pull of the biceps and brachialis anticus muscles. In addition the attachment of the forearm muscles to the lower fragments tend to rotate the lower fragment forward, producing a certain degree of flexion. As a result of these forces the upper arm just above the elbow forms an obtuse angle with its opening posterior. Crepitus is present in all cases unless the dislocation of the fragments is great or there is

interposition of soft parts between the fragments. Abnormal mobility is always present in complete fractures.

In flexion fractures, which are rarely observed, the lower end of the upper fragment is posterior to the lower fragment. In these fractures, as well as in the abduction and adduction fractures, the deformity is not great. Crepitus and abnormal mobility are always present except in the incomplete form.

Diagnosis.—This can generally be made by the presence of the above noted symptoms. In fractures about the elbow-joint, a general anæsthetic usually should be given, not only for diagnosis but also for reduction. The conditions should be differentiated from posterior luxation of the radius and ulna. The normal relative position of the epicondyles and the olecranon process will aid in arriving at a correct diagnosis. A radiogram in anteroposterior and lateral planes should be made before reduction for diagnosis and afterward to determine if anatomical reposition of the fragments has been accomplished.

Diacondylar Fractures (Figs. 367–370).—Under this heading are included those transverse partially intra-articular fractures occurring above the line of the epiphysis. By some authors, they are classified as low supracondylar fractures and by others this variety is not differentiated from a supracondylar fracture. These fractures, however, have been recognized by Kocher, by Chutro, and by Ashhurst. The line partakes of the character of a supracondylar fracture by extension. The line of fracture is, however, lower, is more or less crescent-shaped and traverses the olecranon and coronoid fossæ. The lower fragment consists of the entire articular surface, together with the epicondyle, and there is generally a marked slipping up of the posterior portion of the periosteum with generally lateral and often posterior displacement of the lower fragment. The line of break is above the epiphyseal line.

The mechanism of this fracture is essentially the same as that of a supracondylar fracture by extension, although it may be produced by a fall directly on the extensor surface of the flexed forearm. A rare variety of this fracture is the fracture of the Posadas type (Figs. 371 and 372), detailed by Posadas and also by Ashhurst, in which the fracture produced by flexion causes the lower fragment to be displaced forward and to be complicated by a posterior dislocation of the radius and ulna.

Symptoms.—To the general symptoms of fracture about the elbow there may be added crepitus, localized pain on pressure, occasionally abnormal mobility and deformity. The crepitus can be obtained by flexion and extension of the elbow. Abnormal mobility is dependent upon the degree and extent of attachment of the joint capsule to the



FIG. 367.—Diacondylar fracture of humerus with marked lateral and posterior displacement of lower fragment.

FIG. 368.—Diacondylar fracture of humerus with little displacement of fragments.

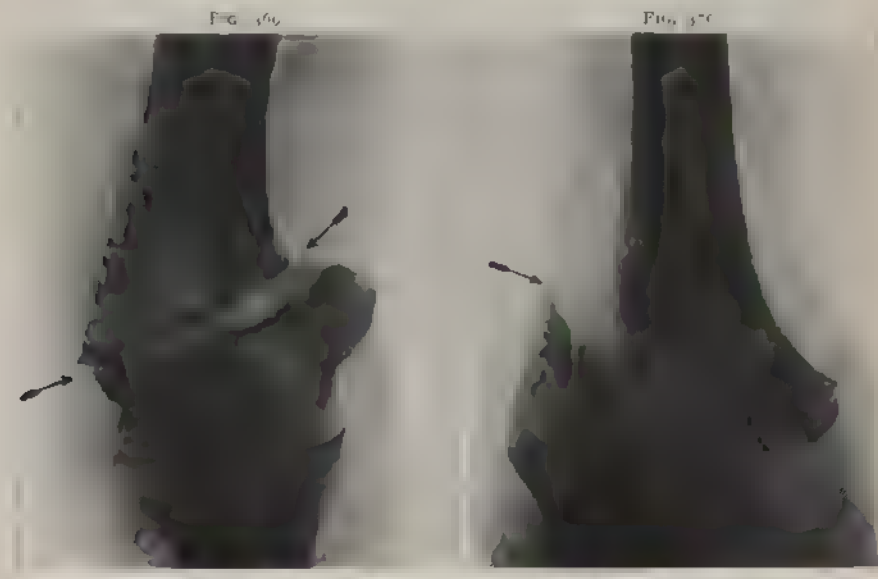

FIG. 369.—Oblique diacondylar fracture of humerus with line of fracture running downward and outward (adduction type).

FIG. 370.—Oblique diacondylar fracture of humerus with line of fracture running downward and inward (abduction type).

upper fragment. In some cases the abnormal mobility will be limited to hyperabduction and adduction. Deformity is not always present; when considerable displacement is present the lower fragment may be

displaced laterally to either side and posteriorly. Anterior dislocation of the lower fragment is rare. An absolute diagnosis of this form of fracture is practically impossible without the radiogram. Here particularly an anteroposterior and lateral view should be taken before reduction.

Diagnosis.—This is made mainly by the radiogram. The condition should be differentiated from supracondylar fracture and separation of the entire lower epiphysis. From the latter it may be distinguished by the detachment of the *entire lower* portion of the diaphysis from the lower fragment, and one should be on guard to recognize this important point. In separation of the lower epiphysis small fragments of the diaphysis frequently remain attached to the epiphyseal cartilage.



FIG. 371. FIG. 372.

FIG. 371.—Diacondylar fracture of humerus, "Posadas' type," with dislocation of head of radius. Fracture by flexion.
FIG. 372.—Diacondylar fracture of humerus, "Posadas' type."

Intercondylar, T, Y, or Atypical Fractures (Figs. 373–375).—These fractures are generally the result of direct violence, are frequently compound and are usually observed in adults. Of the eleven cases reported in Hagemann's statistics all cases were observed in adults with the exception of one seen in a twelve-year-old boy. The essential features are the separation of the condyles from the shaft and their separation from each other. The lines of fracture are rarely typical, there is often great displacement of fragments and marked injury of the overlying soft parts. Perforation of the soft parts and skin may be produced by the sharp ends of fragments. The upper line of fracture may be more or less transverse and about the line of a supracondylar fracture. Running from this line there is generally a

vertical line of fracture separating the two condyles irregularly. The separation of the condyles from each other may vary from a mere fissure to great displacement. At times marked comminution of fragments may be present.

The fracture most frequently is the result of direct violence such as machinery accidents. Madelung considers that it may, however, be produced by the direct wedge-like action of the ulna in falls upon the flexed forearm.

Symptoms.—As most of these fractures are the result of direct violence, the local signs of marked contusion of the soft parts are present. Swelling, ecchymosis, the formation of blebs, and superficial



FIG. 373. FIG. 374. FIG. 375

FIG. 373 Intercondylar T or Y fracture of lower end of humerus.
FIG. 374 Intercondylar T or Y fracture of lower end of humerus
FIG. 375 Intercondylar atypical fracture of lower end of humerus

areas of gangrene are frequent. If the fracture is compound, we have in addition the evidences of such an injury. In typical fractures there is independent mobility of the condyles, broadening of the width between the condylar limits, mobility of the condyles upon the shaft of the humerus, and often marked deformity so that the position of the condyles may be anterior or posterior to the end of the shaft. The latter may at times be palpated between the separated condyles, while, on the other hand, the ulna may apparently be displaced between them. Crepitus is present in nearly all cases and is only limited by the degree of displacement of the fragments, the interposition of soft parts, or the presence of marked œdema.

Diagnosis.—Cases of suspected intercondylar, T, Y, or atypical fractures should have lateral and anteroposterior radiograms made.

In many obscure cases a positive diagnosis can be made only by this procedure.

Separations of the Lower Epiphysis (Figs. 376–379). The lower epiphysis of the humerus is developed from four centres of ossification. A study of the radiogram of the lower end of the humerus shows that before the appearance of any of the centres the lower end of the diaphysis extends below the level of the olecranon and coronoid fossæ, that it is rounded, and it is impossible to determine the internal from the external condyle without a study of the relative positions of the bones of the forearm. The centres of ossification appear in the following order: capitellum, from one to two years; internal epicondyle (epitrochlea), fifth to sixth year; trochlea, eleventh year; and external epicondyle, twelfth year. The centres of ossification increase in size so that those of the capitellum, trochlea, and epicondyle are entirely fused from the twelfth to the thirteenth year, and are entirely united with the diaphysis at the fifteenth year. The centre of the internal epicondyle does not fuse with the diaphysis until the eighteenth year.

Separation of the lower epiphysis is observed during childhood up to about the fourteenth to the eighteenth years. When occurring near the eighteenth year the lesion is usually a separation of the epiphysis of the internal epicondyle. The line of separation may be entirely through the epiphyseal cartilage, or there may be attached to the epiphyseal cartilage portions of the lower end of the diaphysis. The line of separation is variable and the portion of attached diaphysis is, as a rule, fairly constant when present. Separations that are produced by a fall upon the hand with the elbow in a position of full extension may have a portion of the posterior edge of the diaphysis attached. In addition there is usually marked stripping up of the periosteum. In separations produced by direct violence the portion of attached diaphysis will depend in a great measure upon the direction of the fracturing force. The fracture line may at times involve a portion of the epiphyseal line and then run upward through either condyle.

Symptoms.—In addition to the usual signs of fracture, swelling, tenderness, and ecchymosis, there is present crepitus, which is usually soft in character. Deformity when present consists of slight or moderate displacement posteriorly or laterally of the lower epiphysis. This may be recognized by the fact that the radius and ulna may be displaced posteriorly or laterally at will by the surgeon and with little force. Abnormal mobility may be developed by the same manipulations. Many cases of epiphyseal separation resemble sprains of the elbow and formerly were often so diagnosed. There is, however, persistent inability to move the forearm on account of localized pain and

Fig. 376 Fig. 377.

Figs. 376 and 377. Separation of lower epiphysis of humerus. Anteroposterior and lateral views.

Fig. 378. Fig. 379.

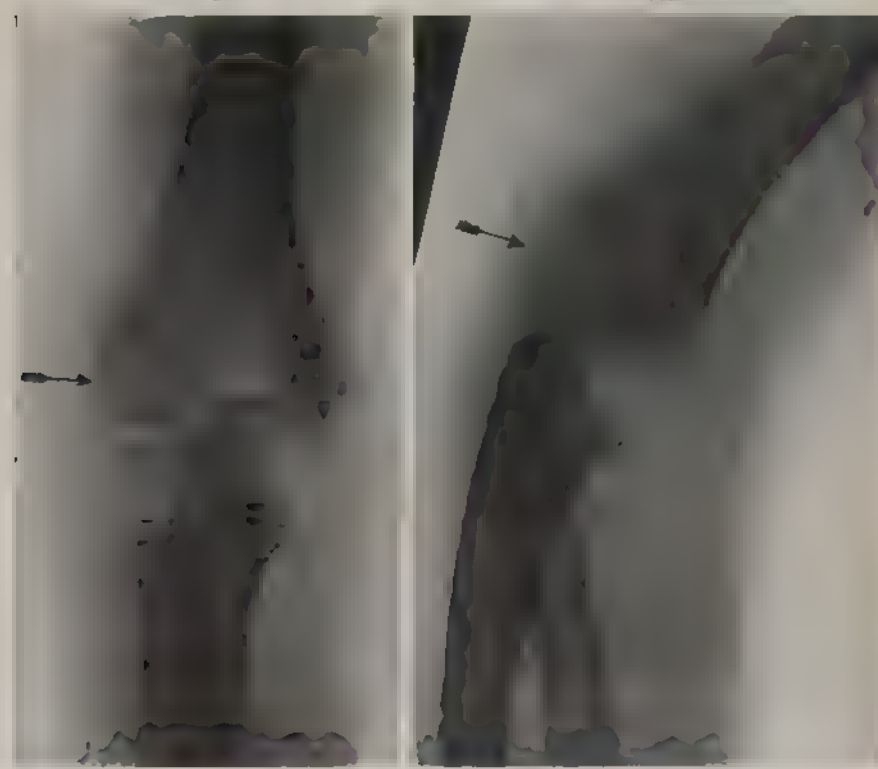

Figs. 378 and 379.—Separation of lower epiphysis of humerus with small fragment of diaphysis attached. Anteroposterior and lateral views.

tenderness, and these two symptoms persist much longer than would be expected in a sprain about the elbow-joint.

Diagnosis.—This can usually be made by the presence of persistent tenderness, pain on motion, soft crepitus, ability to produce an exaggerated degree of abduction and adduction at the elbow-joint, and by careful interpretation of the radiographic findings.

In a study of epiphyseal separations by the radiogram it is very important to bear in mind the time of appearance of these centres of ossification, and the date of their fusion with each other and with the

FIG. 180.

FIG. 181

FIGS. [illegible]

diaphysis. In many instances a diagnosis by the radiogram of epiphyseal separation can be made only by a comparison of the injured with the uninjured side before attempts at reduction have been made. In the early years of life diagnosis will depend entirely upon the altered relation of the centres of ossification to the diaphyses. Later, during childhood or before fusion of the epiphyses with the diaphyses, it may be possible to distinguish epiphyseal separation here as elsewhere [illegible] fact that it is only in the very early years of life that a pure epiphysion occurs. After the sixth or seventh year and [illegible] it is noteworthy from a radiographic point of view

that in epiphyseal separations a small portion of the diaphysis is very often separated from the diaphysis, and remains attached to and is displaced with the epiphysis. When callus has formed, it may be possible to make a diagnosis of epiphyseal separation by radiograms from the presence and amount of callus formed after injuries in which, at the time of accident, a positive diagnosis was impossible.

Fractures of the External Epicondyle (Figs. 380 and 381).—Fractures of the external epicondyle are infrequently seen. The fracture may be the result of direct violence acting upon the external surface of the lower end of the humerus; or of indirect violence, as

FIG. 382 FIG. 383.



FIGS. 382 AND 383.—Fracture of external condyle of humerus. Anteroposterior and lateral views.

when a tear-fracture results from hyperadduction of the elbow. It may be associated with posterior dislocation of the radius and ulna.

Symptoms.—The symptoms of this fracture are localized pain, swelling and tenderness, slight crepitus over the external condyle, and the possibility of moderate hyperadduction of the forearm by forcible motion.

Fractures of the External Condyle (Figs. 382–385).—Fractures of the external condyle were observed by Plagemann in 15 instances out of 103 fractures of the lower end of the humerus. This frac-

ture is frequently observed in children. The line of fracture may run upward and outward obliquely from the joint surface, so that the detached fragment may consist of a part of the trochlea, the capitellum, and the epicondyle. In many instances the line of fracture begins near the external trochlear ridge, and runs obliquely outward to a point below the epicondyle. This form is especially seen in children, and at times great difficulty may be observed in deciding between a fracture of the condyle and an epiphyseal separation in which a considerable portion of the diaphysis is attached to the dislocated epiphysis. The fracture may be produced by a fall directly upon the

FIG. 384. FIG. 385.

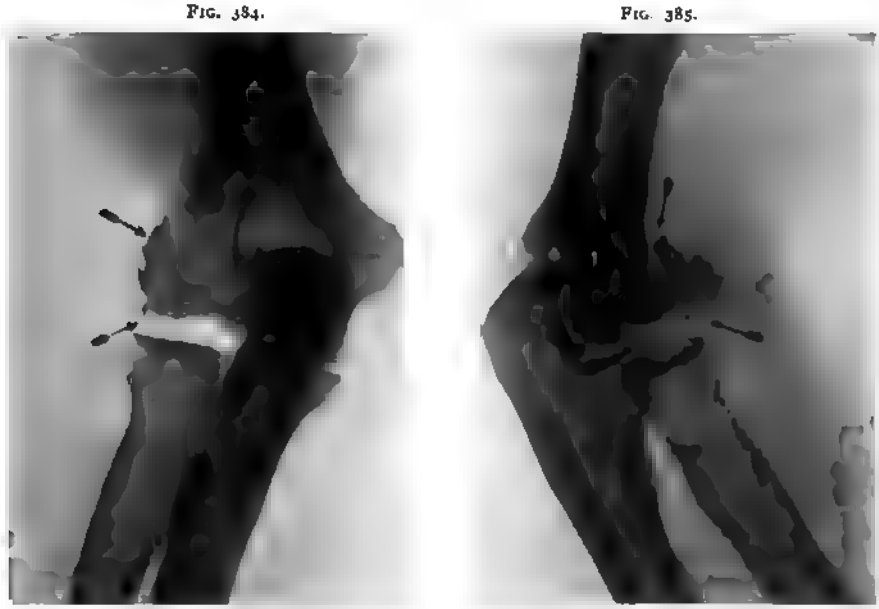

FIGS. 384 AND 385.—Fracture of external condyle of humerus, fall upon hand with arm hyperextended. Anteroposterior and lateral views.

external condyle; by a fall upon the hyperflexed elbow, the external condyle being the point of impact; by hyperadduction of the elbow, in which instance the fracture partakes of the nature of a tear-fracture; or by a fall upon the hand, with the elbow in full extension, the force being transmitted through the radius to the capitellum.

Symptoms.—Examination shows localized pain, tenderness, swelling, and in some instances contusion of the soft parts over the external condyle. In addition there will be found crepitus, mobility of the condyle if the detached fragment is large, possibility of hyperadduction, and occasional displacement of the fragment upward. When the condition is present, hyperabduction of the forearm is possible dition of cubitus valgus may be obtained. When marked

displacement of the fragment is present the roughened edge of the large fragment may be felt. Widening of the joint may be present. Dislocation backward of the ulna may be present as a complication.

Fractures of the Capitellum (Figs. 386 and 387).—This fracture is one of the rarest of fractures occurring at the lower end of the humerus. Kocher described four cases under the classification of "fractura rotuli humeri." Cases have been reported by Stimson, Flint, Lorenz, Jopson and Hahn. The injury consists in the separation of the articular surface of the capitellum and is entirely intra-articular. All of the reported cases appear to have been produced by transmitted

FIG. 386. FIG. 387.

FIGS. 386 AND 387.—Separation of the epiphysis of the capitellum of the humerus, to which is attached a small portion of the diaphysis. Anteroposterior and lateral views.

force acting through the head of the radius, while the elbow was in a position of flexion, or by muscular action in which the head of the radius exerted upward pressure against the capitellum by the pull of the biceps muscle. Several reported cases were the result of crushing injuries or direct violence.

Symptoms.—The symptoms consist in pain, tenderness, swelling, and limitation of motion. This limitation is dependent in a great degree upon the displacement of the fragment. The elbow is generally held in a position of partial extension and passive motion may be complete. The condition resembles in certain ways a fracture of the head of the radius. Supination is limited and possible only with consider-

able pain. Palpation may determine the presence of the fragment near the head of the radius.

Fractures of the Internal Epicondyle (Figs. 388-391).—In many instances detachment of the internal epicondyle is a separation of the epiphysis, which only fuses with the diaphysis of the humerus at about the eighteenth year. This lesion is seen most often between the ages of ten and eighteen years, and consists in complete detachment of the ephysis either alone or in conjunction with posterior luxation of the ulna and radius. The fracture or separation may be the result of direct violence, such as a fall upon the abducted arm; more fre-



FIGS. 388 AND 389.—Fracture of the internal epicondyle of the humerus, the epicondyle is rotated laterally and displaced forward. Anteroposterior and lateral views

quently, however, it results from hyperabduction of the elbow while in a position of full extension, forming a "sprain"- or tear-fracture. Attached to the epicondyle are the superficial flexor muscles and the internal lateral ligament. It is readily seen, therefore, how hyperabduction of the elbow may produce this separation. It is frequently found in conjunction with posterior dislocation of the radius and ulna, a lesion produced most frequently during hyperextension and hyperabduction of the elbow. The attached epicondyle is generally displaced forward and downward, and the ulnar nerve may at the same time suffer injury.

Symptoms.—When the fragment is small and not displaced, the symptoms consist in localized pain, a tenderness, and crepitus. When the fragment is displaced downward and forward there is swelling, pain on using the superficial flexor muscles of the forearm, ecchymosis, and crepitus during reduction of the displaced fragment. Motion at the elbow is not interfered with, as a rule, except for limitation due to pain.

Injury to the ulnar nerve, either immediately as a result of the fracturing force, or secondarily from involvement in callus, is a complication to be feared, yet is very infrequent.

Diagnosis.—This can be readily made by the evidences of localized injury, crepitus, and the presence of the dislocated fragment at a point

FIG. 390. FIG 391.

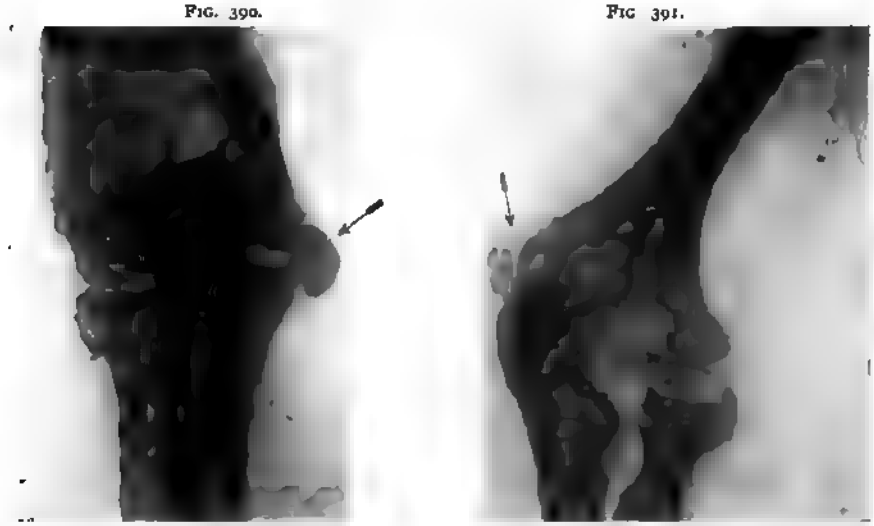

FIG. 390.—Fracture of the internal epicondyle of humerus. Marked downward and forward displacement of the epicondyle.
FIG. 391.—Fracture of the internal epicondyle of the humerus without displacement of the fragment.

below and in front of its normal position. Rotation of the fragment is at times present. Wilms states that in all his cases of posterior dislocation of the forearm occurring from the tenth to the fifteenth years of life there was present a separation of the internal epicondyle.

Fractures of the Internal Condyle (Figs. 392–394).—This fracture of the lower end of the humerus is unusually rare. This is shown by the statistics of Mouchet, 1 case in 170 fractures; Chutro, 2 cases in 106 fractures; Kocher, 6 cases in 45 fractures; and Ashhurst, 4 cases in 56 fractures of the lower end of the humerus. The line of fracture as a rule runs from the inner border above the internal epicondyle downward and outward to the trochlear surface, and at times beyond the external border of the latter. The fracture in the

majority of cases is the result of a fall upon the extensor surface of the ulna with the elbow in a position of flexion, the force being transmitted through the ulna to the trochlea with a resulting breaking off of the internal condyle. Fractures by abduction or adduction may be produced in childhood, when the resulting lesion is more of an epiphyseal separation with an attached portion of the diaphysis in the region of the trochlea. The displacement of the condyle is usually upward, inward and backward; at times little if any displacement will be present. In the case illustrated, due to a fall upon the ulnar surface of the forearm with the elbow in a flexed position, the displacement was lateral, and the upper end of the condylar fragment was tipped forward on extension of the forearm. At times when the displacement is



FIG. 392. FIG. 393. FIG. 394

FIG. 392.—Tear-fracture of the internal condyle of the humerus
FIG. 393.—Tear-fracture of the internal condyle of the humerus.
FIG. 394.—Fracture of the internal condyle of the humerus.

posterior the ulna and radius may be displaced with the internal condyle.

Symptoms.—The symptoms observed in fracture of the internal condyle are swelling, greatest about the internal aspect of the elbow, localized pain and tenderness, ecchymosis, abnormal mobility of the internal condyle revealed by palpation, broadening of the distance between the epicondyles, change in the relation between the epicondyles and the tip of the olecranon, crepitus, loss of the carrying angle, and marked deformity, if the radius and ulna are displaced posteriorly with the displaced internal condyle.

Diagnosis.—This can usually be made by the local signs of fracture, the broadening of the lower end of the humerus with mobility of the internal condyle, the possibility of excessive abduction and adduction with the elbow fully extended, and a study of the radiogram. When there is in addition a dislocation of the head of the radius, its head may be felt below and posterior to the external condyle.

Fractures of the Trochlea (Figs. 395–397).—This is a rare frac-

FIG. 395.



FIG. 396.

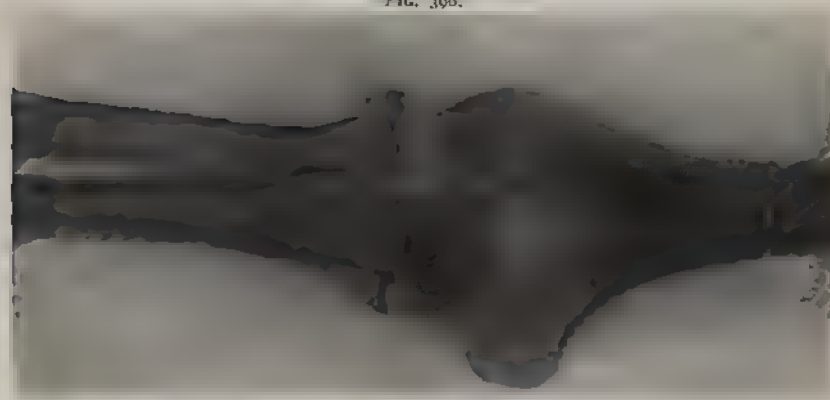

FIG. 397.

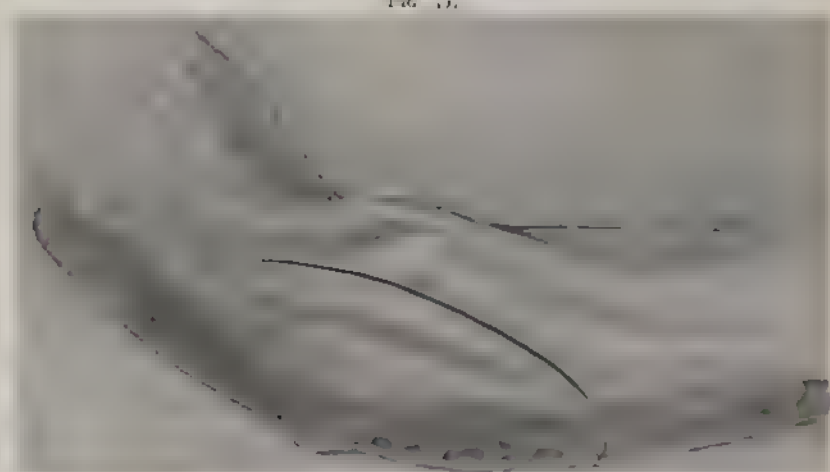

FIGS. 395, 396, AND 397.—Fracture of the capitel um (International Clinics, Dr. John H. Jopson)

ture at the lower end of the humerus. By many authorities it is not even mentioned. Langier first described the fracture; Stimson reports two cases. The fracture consists in a chipping off of a part of the trochlear surface. From the few cases reported it is difficult to describe the mechanism of the fracture; it seems to occur from falls upon the hand with the elbow in a position of hyperextension, the force being transmitted through the radius, the interosseous ligament, and the ulna. Falls directly upon the upper extensor surface of the ulna with the elbow in a position of partial flexion may transmit sufficient force to break off a portion of the trochlea.

Symptoms.—The symptoms of a fracture of the trochlea are those of an indefinite injury to the elbow-joint. In addition to localized pain, tenderness, and effusion into the joint, it may be possible to palpate the displaced fragment. In a case reported by Stimson the fragment could be palpated beneath the epitrochlea. Both cases reported by Stimson were followed by good results and did not require removal of the displaced fragments.

When the elbow has been crushed under heavy pressure or shattered by a gunshot injury, the lines of breaking are too irregular to classify.

Complications of Fractures of the Lower End of the Humerus

The important complications of fractures at the lower end of the humerus are: open wounds, Volkmann's ischæmic contracture, injury to important blood-vessels, and injury to the musculospiral, median, or ulnar nerves.

Open fractures at the lower end of the humerus are sometimes seen, and usually are caused by direct violence. This is especially the case in the supracondylar fractures of the adult, and at times in the epiphyseal separations observed during childhood.

Volkmann's Ischæmic Contracture.—This complication is observed not only in fractures about the elbow-joint but also in fracture of the bones of the forearm. The condition, first described by Volkmann in 1880, consists in a primary disturbance of the blood supply of the muscles from a dressing that is too tight or from other causes that produce pressure upon the muscles, and as a result marked ischæmia occurs. This compression is shortly followed by a true rigor mortis of the affected muscles, and later by hyaline degeneration and the replacement of the muscle-fibres by fibrous connective-tissue. Not only does this change effect the muscles, but the nerves appear to be similarly destroyed, though to a less degree. The sheath of the nerves is particularly involved. The degeneration, muscular and neural, may be complete or partial, and may involve some or all of the muscles and nerves. The flexor muscles seem to be most often involved. The

lesion is *not always* due to the application of tight splints, dressings, or bandages. Cases have been observed in which no constricting dressing was used. In many cases, however, a dressing is applied which at the time is sufficiently loose not to impede the circulation, but which causes constriction later when increased swelling has taken place, either from hemorrhage or œdema. In many of the cases the duration of the constriction has not been long. How rapidly the development of this grave ischæmia occurs is not definitely known, but certainly not longer than from six to twelve hours may suffice. The condition is seen particularly in children, and has been seen following thrombosis of the veins, compression of the main blood supply to the affected limb, and exposure to prolonged cold. Following the degeneration of the muscular fibres contractures rapidly develop.

Symptoms.—In patients who develop Volkmann's ischæmic contracture, it has been discovered that, while as a rule the dressing has not been applied so tightly as to be primarily uncomfortable, complaint of severe pain in the affected part is sometimes made in the first twenty-four hours. This may be looked upon by the patient's family and also by his physician as being the usual pain expected in fractures, and the dressing therefore may not be removed or even examined. Thus the only period at which successful measures can be adopted to prevent the development of ischæmic contracture passes without relief being given. In some cases the pain is not sufficiently severe to attract the attention of the family or nurses. When the patient is seen after the lapse of twenty-four hours, there may be found, on removing the splint or other dressing, that there is an area of superficial necrosis where the point of greatest pressure occurred. The hand will already, or at most within the following forty-eight hours, have assumed the characteristic attitude described by Volkmann. This superficial area of necrosis may subsequently slough and involve deeper structures than the skin. Examination of the extremity will reveal a board-like hardness of the muscles and absence of voluntary contraction with painful and restricted passive motion. The fingers first show signs of contracture, the hand is in the position of pronation, the elbow semi-flexed, the wrist extended, the metacarpophalangeal joint extended, and the interphalangeal joints flexed. Flexion of the wrist permits of extension of the fingers. The flexor group of muscles is permanently shortened, and show marked wasting. The fingers are generally cold and blue, and at the end of twenty-four to forty-eight hours vesication may be noticed, particularly of the fingers. In severe cases there may be ischæmic neuritis of the median and ulnar nerves, with reaction of degeneration, and loss of sensation in certain regions. Glossy skin, changes in the finger-nails and trophic ulcers develop from slight mechanical injuries. The final stage is a claw-like deformity of the hands.

Treatment.—This ischæmic contracture may, in many cases, be improved by the conscientious application of massage, passive motion, and electricity. The result, however, in a great measure will depend upon the original muscular and nerve destruction. In severe cases little permanent benefit will be obtained by non-operative means.

Various operative measures have been suggested and used to improve the condition. They consist of: lengthening of the flexor tendons of the forearm; freeing by dissection of the median and ulnar nerves from the surrounding cicatrix, and their transplantation to the subcutaneous tissue; myotomy and tenotomy of muscles and tendons; and resection of the radius and ulna with the removal of a portion of each sufficient to allow full extension of the fingers. In cases not operated upon, considerable improvement may be obtained by the use of suitable splints and apparatus, which correct to a degree the deformity.

Volkmann's ischæmic paralysis should be differentiated from the contractures of anterior poliomyelitis, Little's disease, and peripheral nerve paralysis.

Injury to important blood-vessels is rarely observed in fractures of the lower end of the humerus, except in patients in whom considerable injury has been done to the soft parts in fractures due to direct violence. When severe injuries occur to the soft parts, the fracture may be an open one, and thrombosis, laceration of important blood-vessels, and large hæmatomas may result.

Injury to Nerves.—Injury to the musculospiral, median or ulnar nerves complicates some fractures of the lower end of the humerus. Primary, intermediary, or secondary nerve lesions may result. Primary nerve lesions consist in laceration or compression of the nerve. Intermediary lesions, causing motor or sensory paralysis, may arise from injury following attempts at reduction or late manipulations of the fragments. Secondary nerve paralysis is due to the pressure of developed callus.

Many of the nerve lesions complicating these fractures are not permanent and rarely require operation. Their frequency is shown by the statistics of Ashhurst, 1 case (median) in 56 cases; Coenen, 3 cases (musculospiral) in 31 supracondylar fractures; Destot, Vignard and Barlatier, 1 case (musculospiral) and 1 case (median) in 72 fractures above the elbow; Broca and Mouchet, 9 cases of nerve injury among 78 elbow fractures. Müller considers that nerve complications develop in one-fifth of all cases of supracondylar fractures (Ashhurst).

Treatment.—The anatomical reconstruction of the lower end of the arm bone in all these injuries requires that the fragments be returned to their normal relations. The functional reconstruction requires that the position of the bones be not allowed to interfere with the mechanical

perfection of the elbow-joint, that the muscles have opportunity to act successfully, that damage to nerves and blood-vessels be repaired, in a manner to correct wrist-drop from musculospiral palsy, pressure anæmia, and similar complications, and that the contour of the limb lose not its original symmetry and beauty.

The full accomplishment of these ends is possible only when accurate diagnosis is united with mechanical precision and surgical judgment. It must be admitted at the outset that in some instances it will be impossible for the patient to obtain these essentials to perfection. Even operation, replacement and direct fixation may prove incapable of giving a good result.

The complicated mechanism of the elbow and its association with man's manual dexterity make its reconstruction after fractures an important surgical problem.

Fortunately the majority may be treated with practical success, if the practitioner in charge will take the trouble to carefully examine and compare both arms of the patient, under general anæsthesia, and use as a check the dry bones taken from a human skeleton. The character of the fracture, the nature of the displacement, and the way to correct the deformity will then usually be apparent to a medical graduate of average knowledge and ability.

Elbow fractures are so notoriously liable to lead to suits for malpractice that a considerable number of physicians hesitate to undertake their treatment. Anæsthesia for the primary examination, and frequent inspection of the limb entirely uncovered by fracture dressings, will probably reveal any condition which renders the protection of consultation with a surgical specialist desirable.

It is true that checks to the hinge-like action of the joint or a diminished pronation and supination of the hand, from unreduced fragments, osteophytes, intra-articular adhesions, or extra-articular contractures and rigidity demand first consideration. Nevertheless, it is important to conserve the so-called carrying angle; its cosmetic, as well as its functional, value is important.

The reconstruction of the elbow-joint is not, as a rule, a difficult problem, if the exact line or lines of fracture and the form of displacement are known, and if the doctor is alive to the mechanics of the undertaking. The various accessories of diagnosis and treatment, utilized in other fractures, generally permit the patient, unless the circumstances are exceptional, to secure a useful and undeformed joint. It is not just, however, to expect the average medical practitioner to obtain in the more complicated cases such uniformly satisfactory and perfect cures as the surgical specialist of metropolitan centres. The latter has a wide experience, which may be readily sup-

plemented by the expert radiographer and the aseptic plant of a modern hospital operating room.

Secondary ankylosis of the joint is a common result of bad fractures and a likely occurrence in badly treated ones. This impaired mobility of the joint surfaces is to be averted by accurate replacement of the fragments, followed by careful massage and passive motion begun early. Prompt correction of the bony distortion is essential.

In the treatment of the various fractures of the lower end of the humerus, several facts should be borne in mind. Before reduction it is wise to have anteroposterior and lateral view radiograms made. After reduction and whatever method of fixation has been used it is judicious to have the part radiographed again. Success in the treatment of these difficult fractures depends largely upon complete reduction and the retention of the obtained anatomical coaptation of fragments under the guidance of radiograms. It is by accurate apposition of the fragments and fixation for the requisite time that exuberant callus, fibrous infiltration of the parts, and arthritic deposits of new bone are avoided. To insure the reduction of fractures of the lower end of the humerus, a general anæsthetic should usually be employed as an adjunct. Some of these fractures are impacted and may require a considerable amount of force to break up the impaction and to permit proper reduction of the fragment. Reduction may be accomplished only after hyperextension, longitudinal traction with countertraction, flexion, hyperflexion, lateral moulding and manipulation.

FIG. 398. Diacondylar fracture of the humerus. Note the marked posterior displacement and moderate rotation of the lower fragment. (See Fig. 399.)

Usually reduction is far more readily accomplished than is the retention of the fragments in their normal position. The method of retention which usually gives the best results, because it makes use of the triceps muscle, Nature's elbow splint, is the modified Jones position, that is, hyperflexion and supination. The best results are obtained by this position in the following fractures of the lower end of the humerus: supracondylar fractures (with the possible exception of the hyperflexion type); diacondylar fractures: separation of the lower

epiphyses: fractures of the external epicondyle, external condyle, internal epicondyle, and internal condyle. Hyperflexion of the elbow, as is shown so admirably by Ashhurst, gives the greatest stability to the broken lower humeral end. Flexion of the lower fragment on the forearm is prevented on account of the relaxation of the forearm muscles attached to internal and external epicondyles, and the point of insertion of the triceps muscle, being carried anterior to the long axis

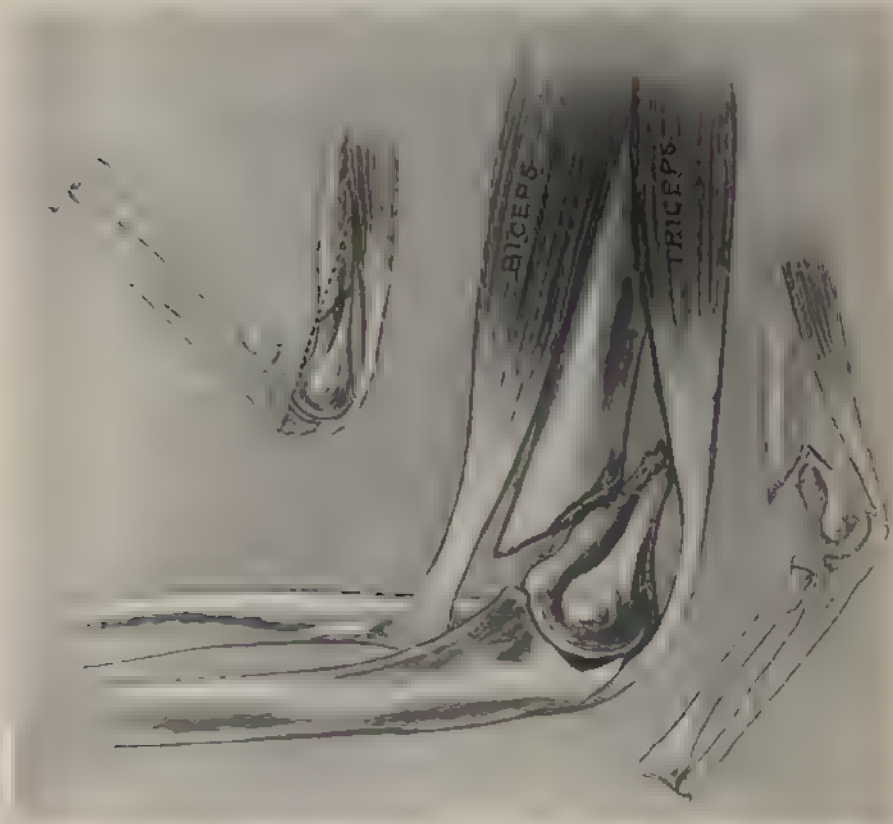

Fig. 399.—Drawing to show the effect hyperflexion has in maintaining reduction of fragments. The central figure (middle after Roentgenogram Fig. 398) shows the effect of the pull of the triceps muscle in maintaining deformity. The figure to the right shows this very clearly. The figure to the left shows the supporting action of the triceps muscle in maintaining apposition of fragments when hyperflexion is used after proper reduction. (Small figures modified after Ashhurst.)

of the humerus, tends to hold the lower fragment in its proper relation with the upper one; thus posterior displacement of the lower fragment is impossible (Figs. 398 and 399). Robert Jones says that if we desire to improve statistics of good functional results, we must recognize the hyperflexed and supinated position as the chief ally in the treatment of severe injuries to the elbow. The extended position of the elbow maintained by an anterior contour gypsum splint, securing the

normal carrying angle of the elbow is often entirely satisfactory. The elbow should not be quite in full extension.

In the treatment of the Kocher flexion type of supracondylar fracture, continued hyperflexion and supination will be followed usually by good anatomical retention of the fragments, provided *proper reduction is first obtained.* If, however, the surgeon depends upon continuous hyperflexion without first having absolutely reduced the fragments, it is often impossible to prevent recurrence of deformity. In a very small percentage of cases in which, because of marked obliquity of the



FIG. 400.—Method of reduction of fractures of the lower end of the humerus. Longitudinal traction and counter-traction, supination, flexion, and hyperflexion.

line of fracture it is impossible to engage the fragments, a better result may possibly be obtained by a right-angle anterior angular splint. This is a dangerous posture for treating fractures of the lower end of the humerus, because of the risk of producing cubitus varus. It is probably preferable in such cases to obtain anatomical apposition by open operation and direct fixation with screws or some similar device, when reduction is not easily maintained by the almost fully extended posture or hyperflexion.

In the intercondylar, T, Y, and atypical fractures, it is very difficult

to properly reduce or mould the fragments into their normal relations and to maintain proper anatomical apposition. In these cases it is wise sometimes to adopt open operation and the direct fixation of the fragments.

In fractures of the internal epicondyle it is generally possible to maintain the fragment in its proper position by hyperflexion. If, however, this cannot be done the almost extended position or open fixation is advisable. In some instances subcutaneous nailing may answer. In troublesome fractures of the trochlea and capitellum, open operation and the removal of the detached fragment is recommended.

In the reduction of these fractures at the lower end of the humerus

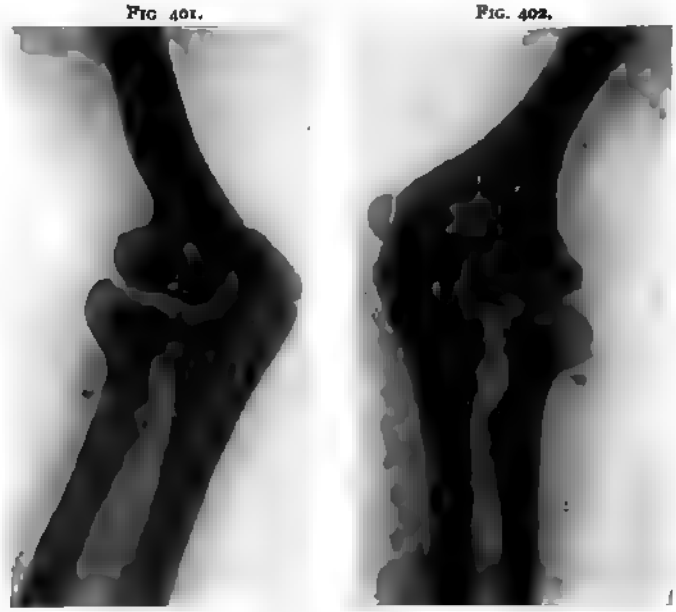

FIG. 401. FIG. 402.

FIGS. 401 AND 402.—Old fracture of external condyle of humerus, untreated. (See FIGS. 403 and 404.)

an assistant should grasp the arm firmly, steady it, and at the proper time make counter-traction; the surgeon should first hyperextend the elbow-joint, separate impacted fragments, and then, by means of manipulation, engage the ends of the fragments; when this procedure has been accomplished, direct traction should be made upon the condyles; internal rotation should be corrected and the elbow slowly flexed, hyperflexed, and the forearm supinated (Fig. 400). If proper reduction is accomplished, cubitus valgus (Figs. 401–404) or varus (Figs. 405–408) will be rare in the types of fracture in which this form of dressing is advised. The degree of hyperflexion will depend upon the amount of swelling present. In cases with much swelling it is always wise to abstain from using flexion for a few days. As a rule it

should stop at the point which causes discomfort or which is likely to cause compression of the brachial artery. It is dangerous in the early days of a severe fracture in out-patient hospital practice because the great swelling may endanger circulation and be unrelieved. The radial pulse should always be felt, after the bandage or other dressing has been applied, and an unobstructed beat of the radial artery proved to be present.

There are several suitable dressings for maintaining this flexed position. One is an adhesive plaster strap so applied as to give an even pull upon the surfaces of the forearm and arm. This strap should be two inches in width. It is applied by placing its centre

FIG. 403. FIG. 404.

FIG 403 AND 404.—Right cubitus valgus. Old fracture of external condyle of humerus, untreated (See Figs. 401 and 402.)

over the upper outer surface of the arm, and the two ends are then carried around the extensor surface of the supinated forearm at a point about two inches above the radial styloid. A wrist-sling made of a cotton roller bandage surrounded by rubber-tubing may be used to support the limb (Figs. 409 and 410). A good form of dressing is that made by the cotton roller bandage properly applied.

In young children liable to disarrange the dressing, a tightly fitting undershirt with sleeve long enough to come beyond the fingertips of the injured limb may be satisfactorily utilized. The shirt is put on with the broken arm through its appropriate sleeve, the elbow acutely flexed, and the end of the sleeve closed with needle and thread. Then the

loose end of the sewn sleeve is sewed firmly to the neck of the shirt in front of the child's opposite sternoclavicular joint.

If the adhesive strap method is used its ends, as Cotton has wisely said, should cross at an angle and be pinned as well as stuck together

The hyperflexion and supination or extension with supination should be maintained for at least three weeks The dressing should be inspected every other day during the first week and twice weekly during the succeeding two weeks; it should be changed whenever necessary. At the end of three weeks the acuteness of the hyperflexed posi-



FIG. 405. FIG. 406.

FIGS. 405 AND 406.—Old fracture of internal condyle of humerus. (See Figs. 407 and 408.)

tion or the extended elbow position, whichever has been chosen, should be decreased slowly so that at the end of the fourth week the elbow is brought to a right angle and the limb is bandaged and carried in a sling. Passive motion should be begun carefully and should at no time be sufficiently violent to cause undue pain. Careful massage of the soft parts may be indulged in from the end of the first week. It may even be started immediately after injury by an experienced surgeon. Early passive motion, if injudiciously employed, and forcible manipulation are liable to dislocate fragments, increase the formation of excessive callus, and delay the resumption of normal motion

The near-extended posture of the elbow-joint, the acutely flexed position, and occasionally right-angle flexion may be used in most of these lesions; *provided* that the medical attendant knows the line of fracture, reduces the fragments, keeps them reduced, inspects the arm frequently, and prevents the moderate displacement which may result in a secondary cubitus varus or valgus.

The fracture dressing should be simple but efficient. Fixation in the extended position of the elbow with the hand supinated has been advocated. This posture is valuable in maintaining the divergent angle between the axes of the arm and forearm and permitting easy recog-

FIG. 407. FIG. 408.



FIGS. 407 AND 408.—Right cubitus varus. Old fracture of internal condyle of humerus. (See Figs. 405 and 406.)

nition of any tendency to abnormal adduction or abduction. Thus the production of cubitus varus or valgus is rendered unlikely. The joint should be almost but not quite fully extended. The extended elbow in condylar fractures may be maintained by a deviating anterior wooden splint properly padded or by anterior and posterior moulded splints of gypsum or other plastic material. The position is not especially inconvenient or irksome to the patients. It should not be full extension. This is irksome and there is a risk of over-extension displacing fragments. The gypsum encasement may be used, if it is split so as not to make injurious circular constriction in case of unexpected swelling.

In some cases the difficulty of diagnosis, the gravity of the lesion

of the bones and soft parts, the unusual displacement of the fragments, the development secondarily of new bony processes and atrophic modification of osseous surfaces may cause partial or complete ankylosis of the joint and deformity of the limb. It is always wise, therefore, to give a guarded prognosis, until the ultimate outcome is clearly established. A very little callus in the olecranum fossa will greatly limit extension.

After-results.—In cases of fracture of the lower end of the humerus the after-results will depend almost entirely upon the perfection of reduction accomplished and the proper anatomical retention of fragments. If these two objects are thoroughly met, the after-results should be satisfactory. In adults the after-results are not quite so good, as a rule, as in childhood. This is probably due to the greater violence necessary in the production of fractures in adults, with its consequent greater detachment of periosteum, and severer comminution of fragments. In childhood nature has a way of so readjusting the parts that in after years perfect functional results may be obtained

FIG. 409. FIG. 410.

FIG. 409.—Method of maintaining hyperflexion of elbow by adhesive plaster strip.
FIG. 410.—Rubber tubing sling. Finished dressing in position of hyperflexion.

in injuries which at the time of convalescence appeared hopeless in that regard.

The end results in fractures of the lower end of the humerus of various authors are given by Ashhurst as follows:

Author	Number of cases	Number treated	Results					
			Perfect	Limited motion	Cubitus varus	Cubitus valgus	Volkmann's-Ischæmic paralysis	Flail-joint
			Per cent.	*Per cent.*	*Per cent.*	*Per cent.*		
Ashhurst	56	47	38 (81.0)	4 (8)	4 (8)	1 (2.0)		
Coenen	31	28	7 (25.0)	12 (43)	7 (25)	1 (3.0)	1	
Cotton	31	27	5 (18.5)	10 (37)	11 (40)	1 (3.7)		
Destot, Vignard and Barlatier	..	39	11 (28.2)	28 (71.8)				
Hilgenreiner	21	14	3 (21.3)	4 (28.5)	4 (28.5)	1	..	2

Cubitus Valgus; Cubitus Varus.—These two terms designate the changes which may result after fracture at the lower end of the humerus. Cubitus valgus denotes an increase in the carrying angle, and cubitus varus a decrease, a loss of, or a reverse at, the carrying angle normally present. The last condition is commonly termed a "gunstock" deformity. The carrying angle is the normal angle formed by the prolongation at the elbow of lines through the axes of the humerus and of the forearm, when the latter is in a position of full extension and supination. It normally disappears when the forearm is pronated or when the forearm is flexed on the arm. It is due to the normal obliquity in the transverse plane of the articular surface of the lower end of the humerus and in a slight obliquity of the transverse plane of the upper articular surfaces of the bones of the forearm. In a series of 50 cases examined by Ashhurst, the carrying angle varied from 162 to 178 degrees. It is greater in women than in men on account of the greater width of the female pelvis. Either condition may result after supracondylar fractures of the lower end of the humerus, although cubitus varus is the more frequent. It has been considered by some authorities to occur frequently after fracture of the internal condyle, external condyle, or epiphyseal separations. This deformity is frequent after fractures of the lower end of the humerus, when the surgeon has treated the injury in the semi-flexed position of a right-angle anterior splint or a right-angle trough splint. These tend to displace the fragments, and especially is this the case in fractures of the internal condyle. If the fracture is thoroughly reduced and the arm treated by the hyperflexed position or the almost completely extended position, the normal carrying angle is much more likely to be

preserved. Perfect reduction must, however, be assured at the time the fracture is put up in a retentive dressing.

The operative treatment of either condition consists in an osteotomy of the humerus in the supracondylar region. For cubitus valgus the osteotomy should be performed from the inner surface, and for cubitus varus from the outer surface of the humerus. The line of osteotomy should be complete, so that the entire thickness of the bone is severed. The correction is then made, the wound closed, and the arm dressed in full extension and supination on a splint or in a gypsum case, being careful to maintain the correct carrying angle. In mild cases, however, it is scarcely necessary to correct either of these deformities. Unless the conditions are moderately great, they interfere but little with function.

Cubitus varus or "gunstock" deformity is the commoner of the two, and interferes greatly with carrying a bucket or bag, because the burden tends to strike the thigh when the patient walks. He must compensate for the brachial deformity by greatly bending his trunk towards the side of the distorted arm if the weight be heavy.

The "gunstock" deformity of the arm, termed cubitus varus, is due to angular deviation or upward with inward displacement, or both, of the whole lower end of the bone or of its internal condyloid portion. It may be a primary or a secondary distortion. This can be avoided if the medical man is not forgetful of its possibility, and constantly compares the injured with the uninjured arm in the extended position with the hand fully supinated. The normal carrying angle is greater in men than in women, and in adults than in children. It also varies in individuals of the same age and sex, and is not shown when the hand is pronated. Its loss by deformity from fracture is a cosmetic blemish, and, if marked, interferes much with the utility of the joint. It is probably caused by the fracture dressing or the sling, in which the arm is carried, lifting the ulna upward toward the shoulder or permitting the ulna, acting as a lever, to displace in the direction of adduction the fragment detached from the shaft of the humerus. It may perhaps occur from gravity when an imperfectly dressed fractured arm is laid across the chest of a recumbent patient.

Cubitus varus is found in supracondylar fractures, fractures near the epiphyseal line, T and Y and comminuted fractures, and fractures of the internal condyle. The opposite distortion, cubitus valgus, takes place when abnormal abduction of the forearm at the elbow is produced by angular or rotary displacement outward of the entire condylar extremity or the fractured external condyle.

The medical man should remember that there is normally no lateral movement of the elbow-joint, and that the hinge is primarily con-

structed by the articulation of the ulna with the humerus. The wrist-joint, on the other hand, is primarily an articulation of the radius with the carpus.

Secondary cubitus varus and cubitus valgus may perhaps be due to an imperfect growth at the epiphyseal line after fractures in that region among children. The surgeon is not responsible for its existence. It is then not a deformity due to a primary rotation or an early deviation occurring during treatment of the fracture.

Summary of Treatment of Fractures of Humerus

Upper End.—Restraint of motion, using chest as thoracic splint, perhaps compress in axilla, elbow flexed and perhaps carried a little forward, wrist sling. Sometimes shoulder cap, preferably of plastic materials. Occasionally traction in abduction. Rarely operative fixation with nail or screw or suturing of periosteum with catgut.

Shaft.—At upper part, similar to fractures of upper end of bone; in middle, narrow coaptation splints of wood or metal but using also thorax as splint, and sometimes adding shoulder cap. Extension weight sometimes hung from elbow. Occasionally gypsum contour splint on outer aspect or inner side of arm. Lower part of shaft and the true supracondylar fracture, right angle splint of wood or metal or of plastic material with elbow flexed at right angle and hand supinated. Elbow should not be supported by a sling lest it cause overlapping. Operation occasionally, to fix with plate or screws or absorbable tube of catgut or fascia, and sometimes after deformed or non-union.

Lower End.—Usually by acute flexion of elbow, maintained by adhesive plaster band, hand covered with mitt or sleeve stitched to opposite sternoclavicular region, by bandage. Sometimes near-extended elbow maintained by anterior deviating wood or metal splint or plastic material to sustain carrying angle. Avoid right-angle anterior splint or posterior trough right angle splint, as a rule, though such may be used for a few days, while swelling is great. Operation required occasionally when reduction impossible or deformed union present. In all fractures of humerus be sure of reduction before applying dressing.

CHAPTER XVI

FRACTURES OF THE RADIUS AND ULNA

Anatomy.—The radius (Fig. 411), the outer bone in the forearm, plays little part at the elbow but its principal part at the wrist. The principal parts of the radius are the disk-like head; the neck, a constriction below the head; the tuberosity below the head for the insertion of the biceps tendon; the shaft which, like the ulna, is three-sided like a prism, on cross-section, and enlarges as the lower extremity is reached; the flattened lower end presents two surfaces, the volar and the dorsal, and has the styloid process below at its outer corner. The head of the radius presents a cup-like depression at its top to articulate with the capitellum of the humerus; at its lower end it articulates with the scaphoid and semilunar of the carpus and laterally with the head of the ulna.

The ulna (Fig. 412), the inner bone of the forearm, is parallel to and a little longer than the radius. The upper extremity has on its anterior aspect the greater sigmoid notch, which articulates with the trochlea of the humerus. The olecranon is the hook-like upper extremity of the ulna. The triceps muscle is inserted upon the olecranon dorsally; the upper portion of this process curves forward over the greater sigmoid cavity, and on extension fits into the olecranon fossa at the back of the lower end of the humerus. The anterior and upper part of the humeral shaft terminates in the coronoid process, which fits into the coronoid fossa of the humerus on flexion of the elbow. The shaft of the ulna becomes smaller in circumference towards its lower extremity and terminates in its head or capitellum, from which extends a pointed process called the styloid process. The lower end of the ulna articulates laterally with the side of the base of the radius.

The trochlea of the humerus articulates with the greater sigmoid notch of the ulna, the humero-ulnar articulation; the capitellum of the humerus with the upper articular surface of the head of the radius, the humero-radial articulation, and the radial notch of the ulna with the articular circumference of the head of the radius, the proximal radio-ulnar articulation. Surrounding these three articulations there is a common capsular ligament. In addition there is a radial or internal lateral ligament and an ulnar or internal lateral ligament, and the annular or orbicular ligament which surrounds the neck of the head of the radius for three-quarters of its circumference, the remaining portion being formed by the radial articulation of the ulna.

The carrying angle normally averages for boys, 168 degrees; for girls, 178.24 degrees (Ashhurst). This is the result of the fact that

the axis of the trochlea is not at right angles to the axis of the shaft of the humerus, but forms an oblique angle, so that when the forearm is extended the axes of the humerus and forearm bones form an obtuse angle at the elbow.

The distal radio-ulnar joint is formed by the articular surface of the ulnar notch of the radius and the circumference of the capitellum of the ulna, and also by the triangular cartilaginous disk between the

FIG. 411.

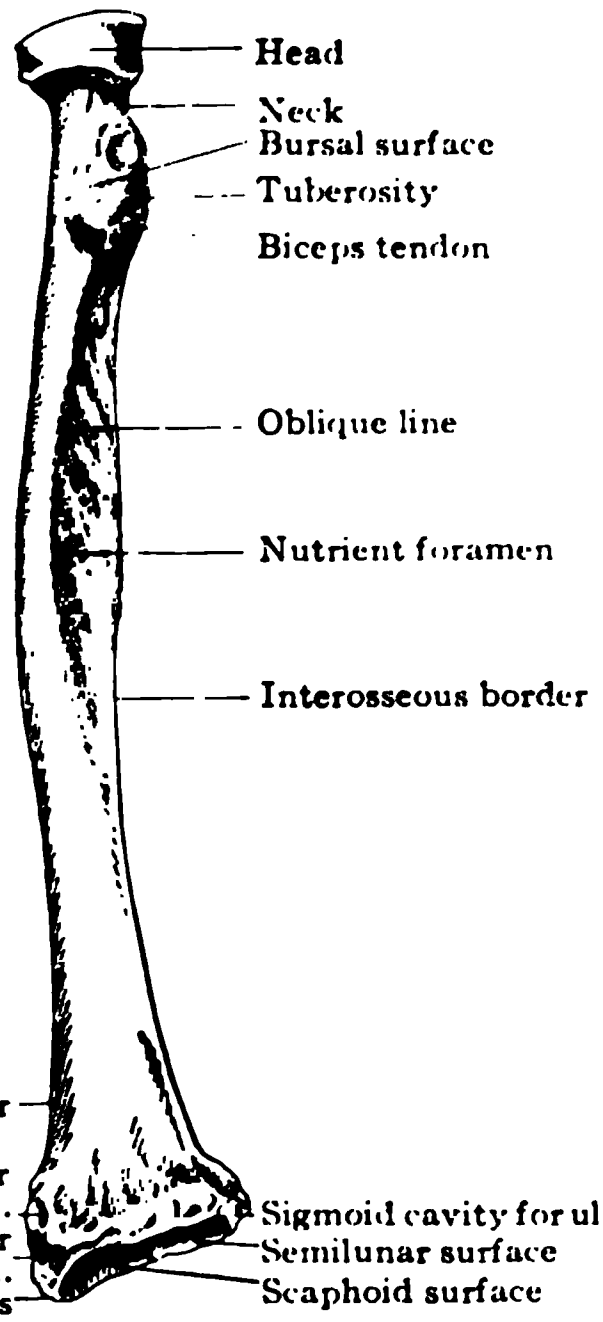

FIG. 412.

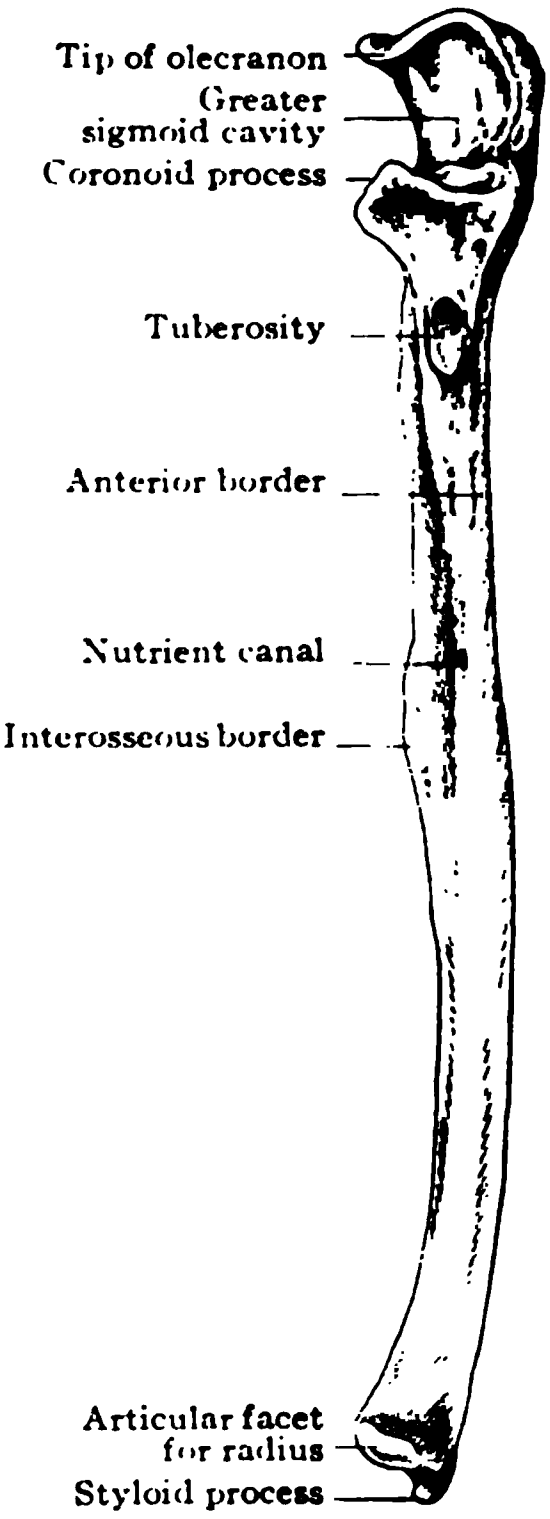

FIG. 411.—Right radius; flexor surface.
FIG. 412.—Right ulna; outer surface.

head of the ulna and the cuneiform bone. In addition there are fibres known as the anterior and posterior radio-ulnar ligaments.

Pronation and supination are produced by rotation of the upper end of the radius on a longitudinal axis through its head and neck; and at its lower end by the rotation of the radius around the head of the ulna. The entire movement may be likened to rotation around a cone with its apex through the head of the radius and its circumference at its lower extremity. The range of motion is about 180 degrees around the base of the cone.

Surface Markings.—The radius is palpable throughout its entire extent, except for a small portion of its upper third. The head of the radius can be readily palpated, and this fact is of importance in determining fracture of the radius. By placing the thumb over the head of the radius, which may be felt just below the external condyle of the humerus, its mobility may be determined by pronation and supination of the forearm. In thin persons the tuberosity of the radius may also be felt. Of special importance in examination of the forearm are the normal radial arch in the lower one-third of its palmar surface and the relation of the radial styloid in comparison with the ulnar styloid. Normally it will be found to be about a quarter of an inch below the ulnar styloid.

The ulna can be felt throughout along its posterior border. Especial attention should be given to the position of the olecranon in relation to the internal and external condyles of the humerus. In



FIG. 413. Lower portion of left humerus with radius and ulna. Incomplete double fracture of the radius and ulna. The radius sustained an incomplete fracture both at the middle and at 4 cm. from the wrist-joint The ulna sustained incomplete fracture at the lower third, at 7 cm. and at 4 cm. from the end. From a boy fourteen years of age whose arm was torn off by machinery (Mütter Museum, No. 1307.)

thin persons the coronoid process may be felt anteriorly on semiflexion of the elbow-joint.

Statistics.—The frequency of fractures of the bones of the forearm has been variously estimated by different authors. Bruns, from a study of 8560 fractures, reports 752 (8.7 per cent.) fractures of radius and ulna; 215 (2.5 per cent.) fractures of ulna; 103 (1.2 per cent.) fractures of the olecranon, and 828 (9.6 per cent.) fractures of the radius. Chudowsky, from a review of 2366 fractures, estimates 125 (5.32 per cent.) fractures of the ulna and radius, 79 (3.34 per cent.) fractures of the ulna, and 253 (10.69 per cent.) fractures of the radius. Immelmann collected 4048 fractures, and of these 84 (7.5 per cent.) involved the ulna and radius, 23 (2.03 per cent.) the ulna, and 123 (11.1 per cent.) the radius. Plagemann's statistics from Muller's clinic at Rostock reports 1393 fractures, all with radiographic diagnoses, and of these 134 (9.62 per cent.) cases involved the ulna and radius, 20 (14.3 per cent.) cases the ulna alone, 11 (0.79 per

cent.) the olecranon and coronoid processes, and 73 (5.24 per cent.) the radius alone

Fractures (Combined) of Ulna and Radius

Statistics.—Of the 134 cases of fracture of both bones of the fore-

Fig. 414. Fig. 415.

Figs. 414 and 415.—Fracture of shafts of radius and ulna. Marked over-riding of fragments. Anteroposterior and lateral views.

arm recorded in Plagemann's classification, the following division was made: fractures of the upper end of both bones of the forearm, 7 (0.509 per cent.); fractures of the shafts of the bones, 47 (3.37 per cent.); fractures of the lower end of both bones, 80 (5.74 per cent.).

Etiology.—The cause may be direct or indirect violence. When

direct violence has been operative, the cause is generally a blow, a kick, or a fall upon the forearm at the site of fracture. When indirect violence has been received, the cause is usually a fall upon the hand. In cases due to direct violence the seat of fracture is at or near the

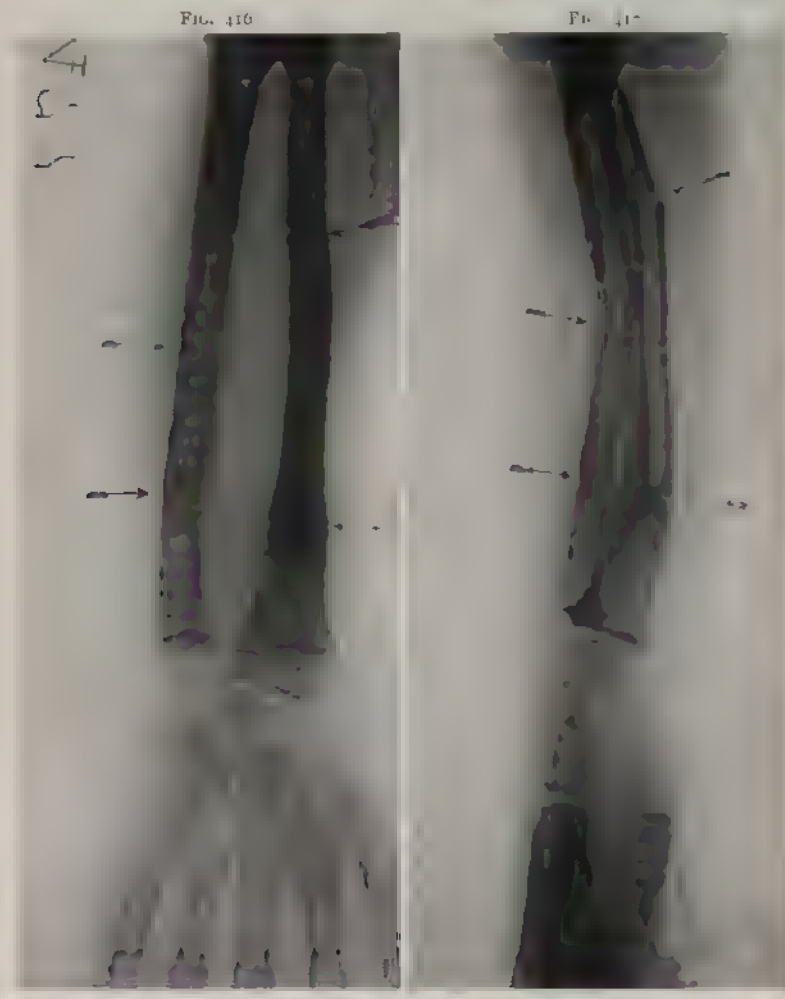

FIGS. 416 AND 417.—Multiple incomplete fractures of shafts of radius and ulna. Anteroposterior and lateral views.

same level in both bones. When due to indirect violence the level of fracture in the two bones varies. Generally the site of fracture is at a higher place in the ulna than in the radius. A few rare cases of fracture by muscular action have been recorded in which there was a contributing form of external violence, as in shovelling or in rising upon the hands while on the ground. The fracture is rarely observed in

children. Oberst, in a study of 92 cases of fracture of both bones, found the fracture at the same level in 50. In 31 the fracture of the radius was higher, and in 11 the fracture of the ulna was higher. In 4 instances the fracture involved the upper third, in 36 cases the middle third, and in 52 cases the lower third and the junction of the lower and middle thirds.

The line of fracture may be transverse, oblique, or spiral, and rarely longitudinal. The fracture may be partial, incomplete, subperiosteal, or "green-stick" (Figs. 413–419). A fairly common form of fracture observed at the lower third of the radius is the "cortex

FIG. 418.



FIG. 419.



FIG. 418.—Fracture of shafts of radius and ulna. Overriding of fragments.
FIG. 419.—Complete fracture of shafts of radius and incomplete fracture of ulna. Union without reduction of fragments, with posterior deformity.

fracture" seen in children. In childhood the cortex is flexible, and as a result of impaction and slight flexion the cortex bulges outward. In adults the same form of violence will produce a transverse fracture.

The fracture may be open, comminuted, or multiple. Extensive damage to the soft parts is the result of severe direct violence, and marked displacement of the ends of the fragments may be the result.

Displacements.—The displacements noticed in fractures of both bo[illegible] of the forearm depend in a great degree upon the fracturing [illegible]sition of the fracture, its character, the pull exerted by [illegible] and the weight of the forearm. In fracture of the [illegible] bones there is in many instances not only fracture,

but also a dislocation of one or more bones or an associated fracture of the lower end of the humerus.

In fracture the result of severe direct violence, the displacement of the fragments may be considerable. The usual displacements are angular, rotary, over-riding. In many fractures of both bones, little if any displacement is noticed, with the exception of slight angulation due to the fracturing force, or to the weight of the forearm. Of special importance are supination displacement of the upper fragment of the radius in forearm fractures between the attachment of the biceps and the insertion of the pronator radii teres; inward or central displacement bringing the ends of the fragments of the radius and ulna



FIG. 420.—Drawing to show the usual displacement of fragments in fractures of the shafts of the radius and ulna. Note over-riding and pulling over of lower fragment of radius by the action of the pronator quadratus muscle.

together in fractures about the middle third (Fig. 420); displacements due to the pull of the pronator radii teres, causing pronation of the upper fragments of the lower middle region of the forearm; and that caused by spasm of the quadrate pronator in fractures at the junction of the middle and lower thirds or below that point, which results in pronation of the hand with the rest of the lower arm supinated or held in mid-supination.

Symptoms.—The symptoms of simultaneous fracture of the radius and ulna will depend to a great degree upon the character of the injury. In incomplete, subperiosteal, "green-stick" and cortex fractures, deformity may be absent or slight. The usual symptoms then will be local-

ized pain, tenderness on pressure, disinclination to use the part, and swelling. When deformity is present, it is of the angular variety. One bone may be the seat of a complete fracture, in which case crepitus may be obtained, while the other bone may be incompletely fractured. Fractures of the above character are observed up to almost the fifteenth year. Sometimes the fracture is not recognized at the time of injury, and the local symptoms may be ascribed to a severe contusion and the true condition understood only at the end of several weeks, when the presence of moderate callus formation will attract the attention of the child's parents.

In incomplete fracture of both bones, in addition to the local signs of fracture observed in the incomplete forms of fracture, there are displacement of the fragments, deformity, crepitus, and often marked swelling of the forearm and bruising of the soft parts.

Complications.—The complications of fracture of both bones of the forearm that may arise are gangrene, Volkmann's ischæmic con-

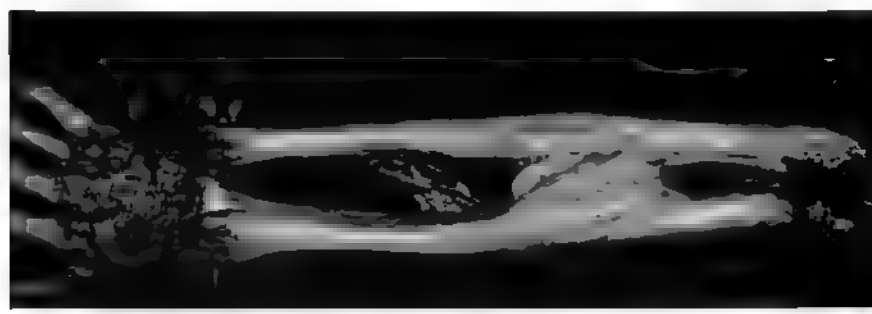

FIG. 421.—Bone of right upper extremity, union with co-ossification. The fracture occurred above the middle of the forearm. The uniting callus is smooth but exuberant, and firmly binds the radius and ulna together. The forearm is fixed midway between pronation and supination. It is difficult to state in the radius the precise location of the fracture. (Mütter Museum, No. 1307.02.)

tracture, diffuse cellulitis, union with angular displacement, union with fusion of the fragments by a bridge of callus (Fig. 421), delayed union, non-union, pseudo-arthrosis, and persistence of failure of full supination, due to rotary displacement of the upper or lower fragments of the radius, according to the situation and direction of the line of fracture.

Diagnosis.—In incomplete fractures the diagnosis may usually be made by the persistence of localizing symptoms at the point of suspected fracture. In complete fractures the diagnosis as a rule is obvious. Radial and ulnar injuries resembling fractures, especially fracture of the incomplete variety, should be carefully radiographed. In some few cases a positive diagnosis is otherwise impossible.

Treatment.—In incomplete fractures in which there is no deformity, the indications for treatment are simple. In such fractures of the upper two-thirds of both bones, the arm and forearm should be im-

mobilized on an anterior angular splint for a period of about three weeks.

In incomplete fractures, in which there is angular deformity, the fracture should be made even complete, if this rupture of fibres is necessary to obtain correction of the deformity. Here, as elsewhere, sometimes careful bending may reconstruct the bent bone without causing complete fracture *with displacement*. This is the ideal reduction. In a few cases reduction may be accomplished by traction on the hand, counter-traction above the elbow with the latter semi-flexed, and local moulding and pressure at the seat of fracture. In fractures of this form involving the upper two-thirds of the forearm, immobilization after reduction is best accomplished by the application of an anterior angular splint applied to the arm and forearm, with the elbow in a position of semi-flexion and the hand in full supination (Fig. 422). Full supination is advised, because a wide separation of the radius and ulna is obtained in this position, and when the pull of the biceps muscle tends to supinate the upper fragment of the radius the lower fragment is brought into its correct position by this procedure. If, after the application of the anterior angular splint, there is noticed any tendency toward posterior bowing at the seat of fracture this may be corrected by the application of an additional posterior splint applied from the olecranon to the wrist (Figs. 473 and 474). A better plan is the application of moulded gypsum splints or an encasement to maintain the desired position.

In complete fractures, reduction of the fragments will often call for not only considerable force, but also considerable manipulation of the fragments. The arm should be flexed at the elbow, an assistant should make steady counter-traction above the elbow, and the operator traction above the wrist. By means of considerable force and manipulation reduction in many cases may be accomplished. A general anæsthetic is advisable whenever reduction may be painful or difficult. After reduction has been obtained the parts should be immobilized as above described. In fracture of the lower third or at the junction of the middle and lower third of both bones, immobilization of the elbow-joint is not always necessary. As a rule the fragments may be held properly reduced by the use of an anterior splint, extending from the fold of the elbow to the metacarpophalangeal joints of the fingers, and a posterior splint, applied from the same level above to the midmetacarpal region below. In the application of splints in fractures of the bones of the forearm, a preliminary bandage next to the skin should not be applied. Such bandaging is seldom if ever necessary underneath a splint dressing anywhere. A longitudinal pad to maintain separation of the radial from ulnar fragments should not be used; it is of little value in preventing bridges of callus, and may cause very

FIG. 422. FIG. 423. FIG. 424.

FIG. 422.—Method of dressing with well-padded outer angular splint with forearm at right angle to arm and in full supination.
FIGS. 423 AND 424.—Application of padded right-angled anterior splint and posterior splint for fracture of shafts of radius and ulna

harmful pressure. Proper reduction and fixation are the means of obviating such complications. Gypsum contour splints are especially valuable because they fit accurately. A slight depression in the surface may be made with the surgeon's thumb at any spot where a little additional pressure is needed to keep a fragment in position. This is done just before the splint hardens. Attention should be paid to preventing the recurrence of angular deformity, and the dressing should be carefully watched so as to avoid undue constriction or pressure necrosis (Figs. 425 and 426). The development of non-union, pseudo-arthrosis or faulty union should be carefully observed and appropriate means for their correction instituted.

In fractures of radial shaft below the insertion of the round pronator, the upper fragment may be pronated strongly. The surgeon

FIG. 425. FIG. 426.



FIG. 425.—Photograph showing areas of pressure necrosis from poorly padded anterior and posterior splints applied too tightly.

FIG. 426.—Posterior deformity from green-stick fracture of shafts of radius and ulna before reduction.

should see that the lower part of the bone is not allowed to unite in a supine position.

In cases of fracture of both bones, in which the fragments cannot be properly reduced or in which reduction cannot be anatomically maintained, open operation with direct fixation is advised. The development of pseudo-arthrosis or non-union is usually due to faulty immobilization or to the interposition of soft parts. In many cases of delayed union longer immobilization with general treatment will effect a cure. In pseudo-arthroses open operation is often necessary, with the resection of the ends of the fragments and the insertion of an autogenous bone-graft, or the fixation of the freshened bone ends by plates, wires, nails or screws.

Results.—Union occurs in the majority of cases in from three and a half to six weeks. The subsequent usefulness of the part depends in great measure upon the character of the fracture, its position, and the

amount of callus necessary to obtain union. When excessive callus occurs, pronation and supination may be greatly interfered with and fusion of the two bones by callus may occur. In cases in which pronation and supination are impaired, without the presence of excessive callus to account for the condition, the disability may be due to the fact, as pointed out by Konig, that union occurs with the lower fragment pronated and the upper fragment supinated, rotary malposition being the result. Supination is therefore impaired to the limit in which it is possible for the upper fragment to supinate. When union takes place with the fragments displaced towards each other and the

FIG. 427. FIG. 428.

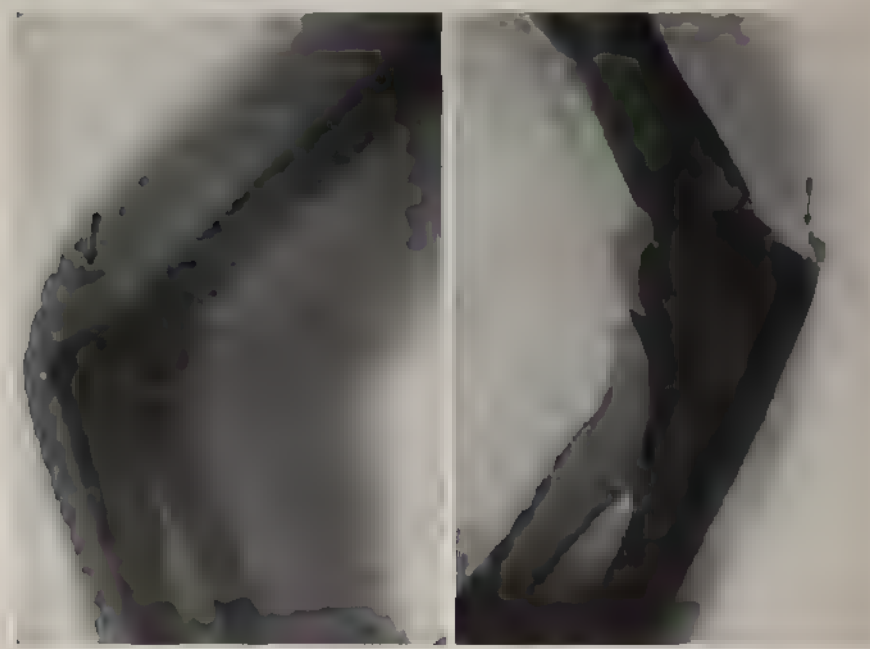

FIG. 427.—Tear fracture of the tip of the olecranon process by muscular action.
FIG. 428.—Fracture of olecranon exostosis from direct pull upon flexed elbow.

hand pronated, the interosseous membrane is stretched at the point of union of fragments by moderate rotation so that supination is limited.

ISOLATED FRACTURES OF THE ULNA.

Statistics.—Plagemann's statistics include 31 cases of fractures of the ulna. Of these there were 11 cases (0.78 per cent.) of fracture of the olecranon and coronoid process. Of these the olecranon alone was involved in 7 cases; there were 15 cases (1.07 per cent.) of fracture of the shaft, and 5 cases (0.359 per cent.) of fracture of the lower end or head of the ulna.

Fractures of the Olecranon.—Fractures of the olecranon process

(Figs. 427–432) may be the result of direct violence, of muscular action, or of a combination of both. Those resulting from direct violence, such as a fall upon the olecranon or the extensor surface of the upper forearm, are usually transverse in direction; they may, moreover, be comminuted or compound. Fractures the result of muscular action are always transverse and single. Olecranon fractures may be associated with fractures of the coronoid process. That fractures of the olecranon are not so frequently the result of direct violence alone

Fig. 429 Fig. 430

Fig. 429.—Incomplete fracture of base of olecranon process. Direct violence.
Fig. 430.—Comminuted fracture of olecranon. Direct violence.

is shown by the frequent absence of local trauma. Many of these fractures unquestionably are the result of the sudden flexing of the elbow by the muscles—the triceps holds the olecranon firmly and, as the patient falls upon the hand or semi-flexed forearm, an extreme force is indirectly brought to bear on the ulna at the point of articulation of the olecranon with the trochlea of the humerus, and fracture results. Most fractures resulting from direct violence are comminuted in character.

Displacement.—In a consideration of the displacement that may occur in fracture of the olecranon it should be remembered that the three articulations of the elbow-joint are surrounded by an articular

capsule. This is attached to the ulna just in front of the tip of the olecranon and extends forward on the lateral aspect of the olecranon to a point anterior to the coronoid process. It forms with the annular ligament a firm support to the component bones of the joint. Further support is given by the attachment of the triceps muscle, which is chiefly inserted into, and completely surrounds, the olecranon process; it also gives lateral expansion to the ulna and antebrachial fascia. It is for this reason that fractures of the olecranon, transverse in character and at a position well back towards the tip, are often observed

FIG 431 FIG. 432.



FIG. 431.—Transverse fracture of olecranon process. Muscular action. Very little separation of fragments.

FIG. 432.—Transverse fracture of olecranon process. Marked separation of fragments.

without any displacement. The fragment is mostly intra-articular and is held attached to the remaining portion of the ulna by the articular capsule and by the lateral expansions of the insertion of the triceps muscle. When, however, the fracture line is situated more anteriorly, separation occurs, as it also may when the fracture is the result of muscular action. In such instances the lateral expansion of the insertion of the triceps muscle and the articular capsule are torn; and therefore displacement readily occurs by the action of the triceps muscle (Fig. 433). This displacement is always greater on flexion at the elbow and usually may be made to disappear on full extension.

Symptoms.—The usual signs of fracture, swelling, ecchymosis, effusion of blood into the elbow-joint, local pain, deformity (Figs. 434 and 435), and tenderness are present. The arm may be carried in any position. There is generally actual loss of power of extension. Extending power, however, may be present to a limited degree when the periosteum and the lateral expansion of the triceps tendon are not completely torn. Extension is best tested by having the patient attempt it against resistance. Crepitus can generally be obtained, even in those cases in which there is considerable separation of the fragments, by manipulation of the fragments during full extension at the elbow. Separation of the fragments may be detected by palpation. A radio-

FIG. 433.—Drawing to show the action of the triceps muscle in causing separation of fragments in fracture of the olecranon process. (Made after Fig. 432.)

gram will always make the diagnosis certain. A source of error possible in radiographic diagnosis is the belief that a partially ossified process or a normal epiphyseal line in a young subject is a fracture line. The olecranon may have one or two centres of ossification. These centres increase in size until about the sixteenth to the seventeenth year, when complete ossification of the epiphyseal line takes place. Separation of the olecranon epiphysis is rare, and can only be diagnosed by radiographic examination and careful comparison with its fellow of the opposite arm. If, in the presence of clinical localizing signs of injury to the epiphysis, the radiograms show distinctly a marked displacement as compared with the other side, one is justified

in making a positive diagnosis. The surgeon should make himself familiar with the radiographic appearances of the bones at the elbow-joint at various ages. The ossific centres are often mistaken for fracture fragments.

Treatment.—Reduction of this fracture is readily, as a rule, accomplished by full extension of the forearm with some form of traction above the olecranon. Union in many cases is fibrous and not bony. This is due to a certain amount of separation of fragments and the interposition of small portions of fascia. Open operation should be followed by firm bony union. Non-operative treatment consists in nearly full extension at the elbow, and the application of a well-

FIG. 434. FIG. 435.



FIGS. 434 AND 435.—Photographs showing slight deformity after incomplete fracture at base of olecranon process. Union with posterior angulation.

padded splint to the flexor surface of the arm, forearm and hand, extending from the axilla to the palm of the hand. This splint should be held firmly to the arm with circular strips of adhesive plaster and a bandage; an additional strip should be placed above the olecranon and run downward in a diagonal direction, to hold the olecranon firmly apposed to the remaining ulnar fragment (Figs. 436 and 437). If no separation of fragment is present, immobilization may be made upon a well-padded internal right angular splint. The internal splint should hold the elbow-joint at a right angle (Fig. 438). Look out that a pressure sore is not produced over the epicondyle.

In young adults, members of the working class and others, whose occupation depends in a great measure upon the ability to fully extend

FIG. 436



FIG. 437



FIG. 438

FIGS. 436 AND 437.—Straight splint applied to internal surface of arm and flexor surface of forearm for fractures of the olecranon process. Note application of adhesive straps. One strap particularly should be placed just above the process.

FIG. 438.—Application of the internal right-angle splint for fracture of the olecranon process when there is no separation of fragments.

the arm, and also in all instances where great separation of fragment is present, operation and suture of the fragments are recommended. Convalescence is more rapid, union is bony and a strong useful arm is obtained. A U-shaped incision, approximation of the fragments and suture with twenty-day chromic catgut or kangaroo tendon, closure of the wound, and the application of a splint holding the arm in a little less than full extension will meet all operative indications (Fig. 439).

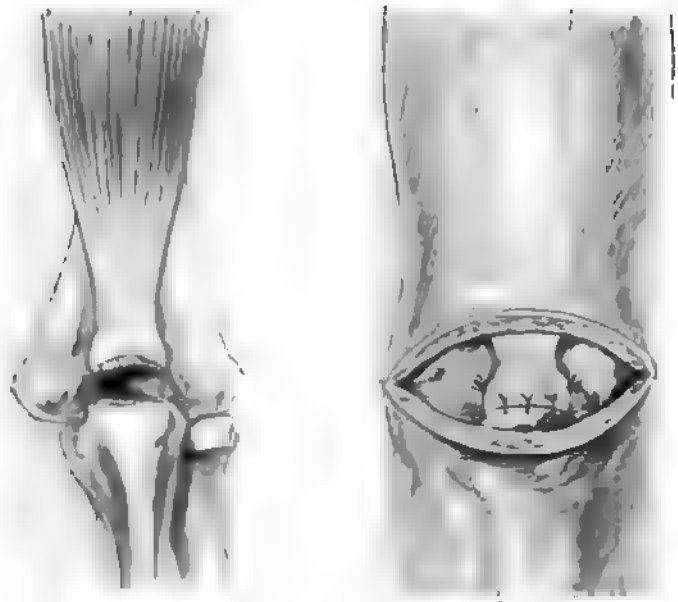

Fibrous union is more frequent than is generally supposed, and while the function of the part may be decreased somewhat, it is good for all practical purposes, except in those instances in laborers where the degree of extension is of paramount importance. Bony union results generally in those cases in which there is no separation of fragments and in the operative cases. In some instances it is remarkable that, although there is a marked appreciable gap between the fragments and only fibrous union, extension with considerable power is present. The olecranon is similar to the patella in its function, and demands a very similar treatment when it is fractured It is probable that suture

FIG. 440. FIG. 441.

FIG. 440. Fracture of coronoid process of ulna.
FIG. 441. Fracture of the coronoid process of the ulna complicating a posterior dislocation of radius and ulna previously reduced.

of the capsule may be as efficient as sutures carried through the fragments. In this it resembles to a certain extent fracture of the patella, though in the latter injury there is more opportunity for separation because of the greater tendency to wide laceration of the muscular tendinous envelope.

Fractures of the Coronoid Process (Figs. 440–444).—This fracture was considered extremely rare. The radiograph has, however, revealed the more relative frequency with which it occurs. Although many authorities consider isolated fracture of the coronoid process extremely rare, except as an accompaniment of backward or lateral dislocation of both bones of the forearm, the three cases here

illustrated, in which there was no dislocation or tendency to dislocation present, were seen by Dr. Kelly. Its occurrence is probably not very unusual.

The mechanism of this fracture is not definitely understood. Some surgeons consider it the result of a fall upon the ulnar border of the hand with the forearm in a position of partial flexion, the force being transmitted through the ulna to the coronoid process, which is broken by counter-pressure against the trochlea of the humerus. By other writers it is believed to be due to action of the brachialis anticus muscle, and to partake of the nature of a tear- or sprain-fracture; other authorities attribute its occurrence to hyperflexion of the elbow-joint. It is suggested by the authors that coronoid fracture may result from a

FIG. 442. FIG. 443. FIG. 444.

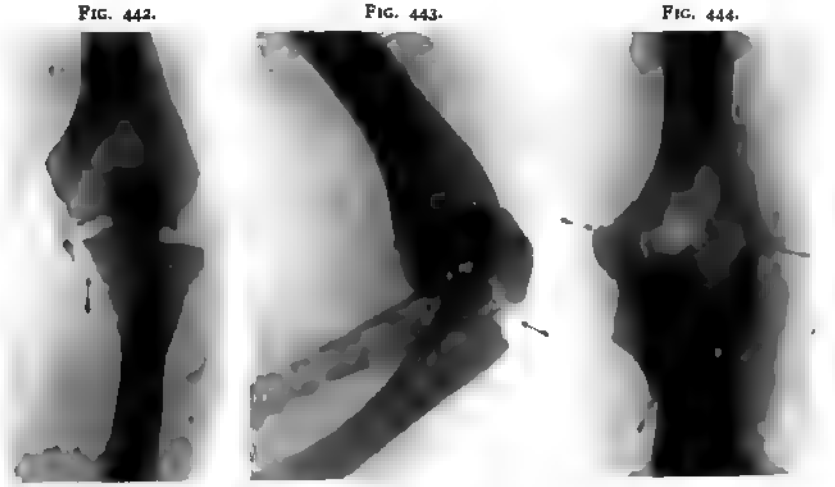

FIG. 442. Fracture of coronoid process of ulna.
FIG. 443.—Fracture of coronoid process of ulna complicating a fracture of the olecranon process.
FIG. 444.—Fracture of base of coronoid process of ulna complicating a diacondylar fracture of the humerus.

fall upon the hand, with the forearm in a position of partial flexion, transmitting the vulnerating force through the interosseous ligament from the radius to the ulna and thus driving the coronoid process against the trochlea. The force thus transmitted may or may not be severe enough to produce an accompanying dislocation backward of both radius and ulna at the elbow. An accompanying feature of the anterior portion of the head of the radius has been described by some authors.

The line of fracture may be at the tip or at the base of the process. When due to muscular action we would think that only a portion of the process would be torn off, while, when produced by indirect force applied through the forearm, the fracture line is at the base of the process.

Displacements.—In fractures of the process unaccompanied by posterior dislocation of both bones of the forearm, displacement of the process is slight. This is due to the firm attachment of annular and lateral ligaments and the tendon of the anterior brachial muscle. When there is present a posterior dislocation of both bones of the forearm, the fragment tends to remain in normal relation with the anterior surface of the trochlea, and to be separated from its attachment to the shaft of the ulna.

Symptoms.—The symptoms of fracture of the coronoid process unaccompanied by luxation of the bones of the forearm are often

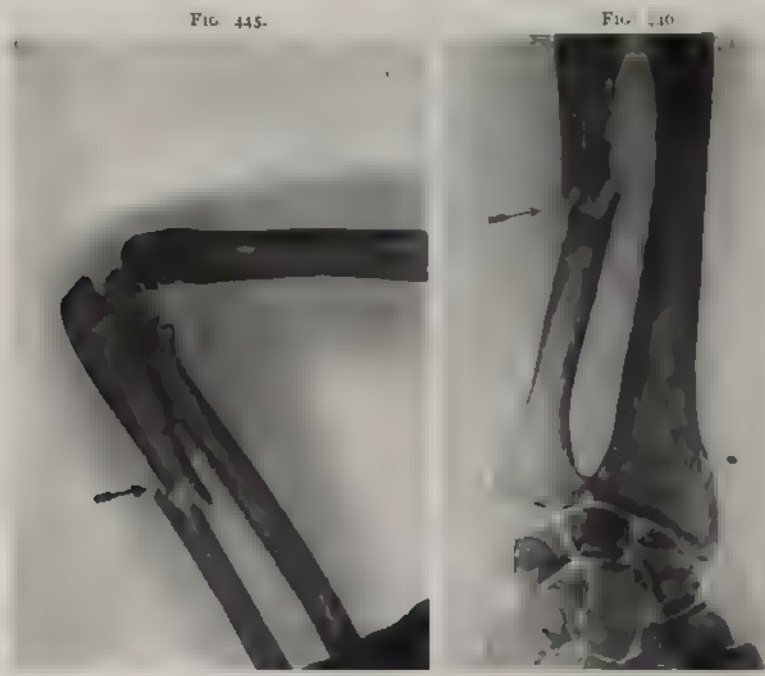

FIG. 445. FIG. 446.

FIG. 445. Fracture of shaft of ulna, upper third.
FIG. 446. Fracture of shaft of ulna, lower third.

indefinite. A definite diagnosis may be made, if there is localized pain and tenderness, increased by flexion at the elbow, local swelling, retention of the normal landmarks about the elbow, and a suggestion of crepitus on deep palpation over the coronoid. A radiographic examination will clear up doubt. When there is present a dislocation of both bones posteriorly, fracture of the coronoid process may be diagnosed by the comparative ease with which a recurrence of the dislocation is reproduced when the elbow assumes a partially flexed position.

Treatment.—In fracture accompanied by dislocation, the latter condition should be reduced by traction with counter-traction, followed by attempts to extend the joint and suddenly flex it. After reduction the

forearm is carried to a position of hyperflexion. This position should be maintained for from two to three weeks, using the form of dressing described under fractures of the lower end of the humerus, and then may be kept in flexion greater than a right angle for about two weeks longer. When there is no dislocation present, there is generally little displacement of the coronoid fragment. In this condition the arm and forearm should be immobilized at a right angle on an internal or anterior angle splint for three to four weeks. Very slight passive and active motion should, as in all fractures, be started early, but not be more than moderately indulged in until the end of four weeks. Com-



FIG. 447. FIG. 448.

FIG. 447.—Fracture of shaft of ulna, middle third.
FIG. 448.—Multiple fracture of shaft of ulna, lower third.

plete or nearly complete immobilization is perhaps more essential in this than in other fractures, so that anatomical apposition of the fragments is maintained, callus formation thus lessened, and therefore the possibility of interference in subsequent joint function decreased. If fibrous union only is obtained and there is marked interference with flexion of the elbow, resection of the detached fragment may be necessary.

Results.—The after-results are generally favorable not only for union but also for subsequent return of full function.

Fractures of the Shaft of the Ulna—Etiology.—Isolated fractures (Figs. 445–448) of the shaft of the ulna are usually the result of

direct violence, generally received by a fall directly on the posterior surface of the ulna or by a blow being received with the arm uplifted to protect the body or head. This is the so-called "parry fracture." Fractures by indirect force, such as a fall upon the hand, are extremely rare, as are also fractures by violent bending, torsion, pronation, or supination. When the fracturing force is severe, the fracture may be multiple or compound. A not uncommon complication of fracture of the shaft of the ulna is an anterior dislocation of the head of the radius. This complication is considered by Helferich and Dorfler to accompany fractures of the shaft only when the fracture involves the upper third of the ulna. Oberst and also Wilms do not coincide in this view, and report cases in which the fracture involved the middle third of the ulna. This lesion is most frequently the result of a direct blow received upon the posterior aspect of the outer surface in the upper or middle thirds of the shaft of the ulna.

Displacement.—In uncomplicated fracture of the ulnar shaft, the presence or absence of displacement is dependent upon the degree of the fracturing force, the nature of the fracture, and its position. Study of radiographs and patients seems to show that the displacement of the fragments is never uniform. There is doubtless a certain tendency for the lower fragment to be displaced toward the radius in complete fractures by the pull of the pronator quadratus muscle. An important factor, however, in producing this displacement is the weight and position of the hand held in ulnar adduction, which tends also to throw the upper end of the lower fragment toward the radial shaft (Fig. 449). In incomplete fracture the angle of deformity is generally toward the radius.

Symptoms.—The symptoms of incomplete fractures may be limited to localized swelling, ecchymosis, pain and tenderness on pressure, especially on attempting to squeeze the shafts of the ulna and radius together. No deformity may be present. Crepitus is necessarily absent. In complete fractures there will generally be noted localized swelling, ecchymosis, pain, crepitus, deformity, inability to use the forearm, and marked pain on attempting forcibly to extend the forearm. Shortening will be absent unless there is an accompanying dislocation of the head of the radius, when it may occur. Radiographic diagnosis is important in obscure cases.

Treatment.—The reduction of the fragments is best obtained by direct manipulation, and in fractures of the middle and lower thirds by firm and marked ulnar abduction of the hand in a position of semipronation. In fractures of the upper and middle thirds, immobilization may be obtained by the use of a right-angle anterior angular splint, and in fractures of the lower third by the use of an anterior and a posterior splint, which carries the hand in marked ulnar abduc-

Of these, 23 cases (1.65 per cent.) were of the head or neck; 12 cases (0.25 per cent.), fractures of the shaft; and 38 cases (2.72 per cent.), fractures of the lower end of the radius.

Fractures of the Head of the Radius.—Radiography has shown that this formerly supposed rare fracture occurs with comparative frequency. Recent literature and a study of a collection of radiographs in hospitals will show fracture of the head and neck of the radius to be not unusual.

FIG. 450. FIG. 451.

FIG. 450.—Fracture of the head of the radius. No displacement of fragments.
FIG. 451.—Fracture of the head of the radius; slight displacement of fragment, complicated by fracture of coronoid process of the ulna.

Etiology.—Fracture of the head of the radius may result from various injuries. The most common lesions are those caused by indirect violence, such as a fall upon the prone hand with the elbow in full extension, a violent abduction of the forearm, and as a complication of a posterior dislocation of both bones of the forearm, and those due to direct violence, such as a blow or a fall upon the head of the bone.

Varieties.—Fractures of the head of the radius (Figs. 450–453) are intracapsular. The fracture may be longitudinal, wedge-shaped and diagonal; also multiple or impacted. The position and form of

the fragments are dependent upon the character of violence. Fractures associated with dislocation usually show a line of fracture involving a portion of the upper rim of the head; those caused by violent abduction are situated, as a rule, on the outer rim. Fractures due to transmitted force through the forearm and to falls upon the palm of the hand may show a multiple fracture or the fragment may be impacted. Fracture of the epiphysis or through the epiphyseal cartilage is occasionally seen

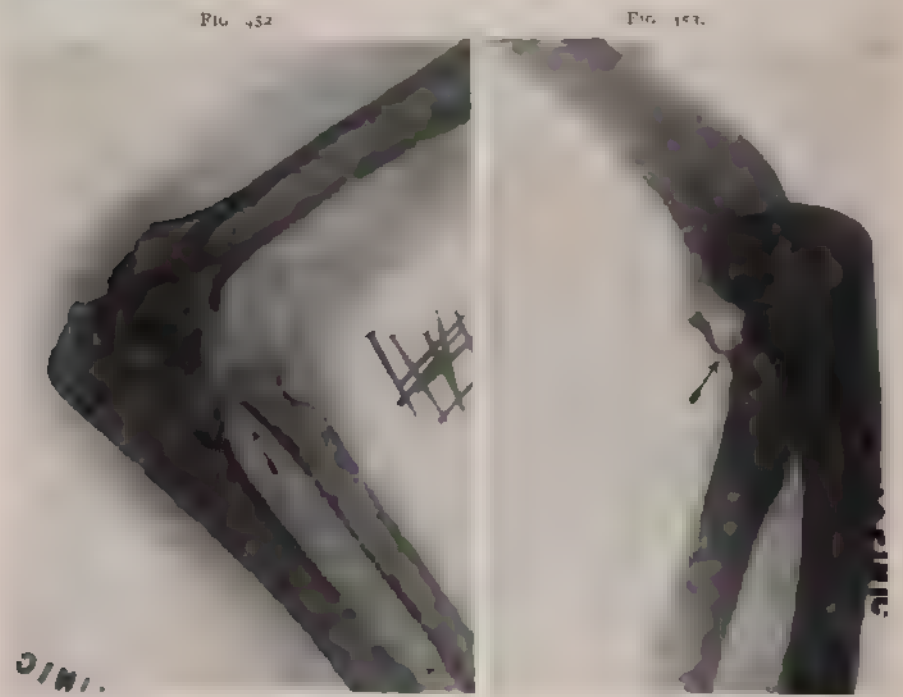

FIG. 452. FIG. 453.

FIG. 452. Fracture of the head of the radius. Moderate displacement of the fragment.
FIG. 453. Fracture of the head of the radius complicating posterior luxation of radius and ulna which had been reduced.

Displacement.—The fragment rarely becomes detached, being held by a portion of intact periosteum. Impaction of the fragment is often seen. It may, however, become displaced downward, and outward or backward, and unite with the neck of the radius; it may at times stimulate a fracture of the coronoid process of the ulna. When union of the fragment occurs, if it be not impacted, a certain amount of permanent displacement is frequently present.

Symptoms.—The most noteworthy symptoms of fracture of the head of the radius are pain and tenderness over the region of the head, increased by passive pronation and supination of the forearm; impairment of voluntary pronation, supination, flexion and extension; broad-

ening of the head of the radius; and moderate swelling of the elbow-joint. Crepitus is present, if the fragment is not impacted, it is elicited when the forearm is pronated and supinated, while direct pressure is made with the examiner's thumb over the radial head. (Dislocation of a misplaced fragment may be at times detected by palpation.) Associated injuries, such as dislocation of the bones of the forearm, and fracture of the external condyle or epicondyle, will be recognized by their usual symptoms. The use of the X-ray is very essential for a proper diagnosis of these fractures, and also in the diagnosis of dislocation of the head of the radius (Figs. 454-456).

FIG. 454.—Posterior luxation of the radius and of the ulna.

Treatment.—The form of treatment will depend in a great measure upon the radiographic findings. When it is found that the fracture is fissured in type, with little or only moderate displacement of the fragments, good functional result should be obtained by non-operative methods. The same may be said of fractures in which the fragments are impacted. Such lesions may be immobilized on an anterior right angular splint with the hand in supination or on an internal angular splint with the hand in pronation for three to four weeks. The supine position is probably as a rule the better. After the first week gentle massage should be instituted, and the end of the third week this should be supplemented by passive motion.

When there is considerable displacement of fragments, and when there is marked comminution of the bone, union is likely to occur with the formation of considerable callus, which will probably interfere with flexion, and extension of the elbow, and especially with pronation and supination of the radiohumeral joint. Often non-union occurs, and the separated fragments then may greatly interfere with the normal motions. In these cases the best results will be obtained by arthrotomy

for the removal of the separated fragments or resection of the broken head of the radius. The loss of the radial head, if the neck is not

Fig. 455. Fig. 456

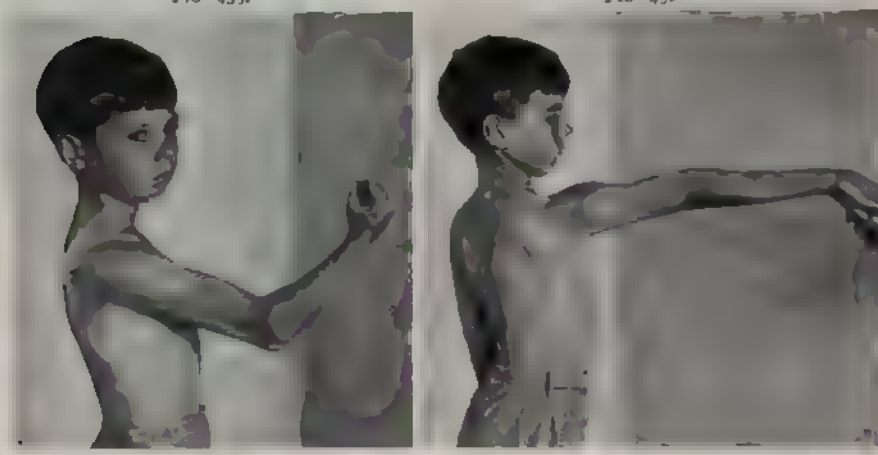

Figs. 455 and 456.—Posterior luxation of the radius and ulna. Untreated case. Patient fell off hay wagon three weeks previously. Fig. 455 shows the extent of forced flexion operative reduction. See Fig. 454 for roentgenogram. (Courtesy of Dr. Morris Booth Miller.)



Fig. 457.—Fracture of the upper radial epiphysis. Boy fell over handle of bicycle on palms with arms extended.

removed and the orbicular ligament left intact, is not a cause of much functional disability.

Results.—T. T. Thomas reports 18 cases treated conservatively as follows: union without deformity, 3 cases; union with deformity, 5

cases; non-union, 8 cases; bony ankylosis, 1 case; fibrous ankylosis, 1 case; and greatly impaired function, 2 cases. Hitzrot reports 19 cases. Of these, in 15 instances treated non-operatively there was loss of half of rotation in all but 2 cases; of 4 operative cases, in which the fragment or part of the head was removed, rotation was better preserved and was nearer normal in those in which the entire head was excised.

Separation of the Upper Radial Epiphysis.—This condition is

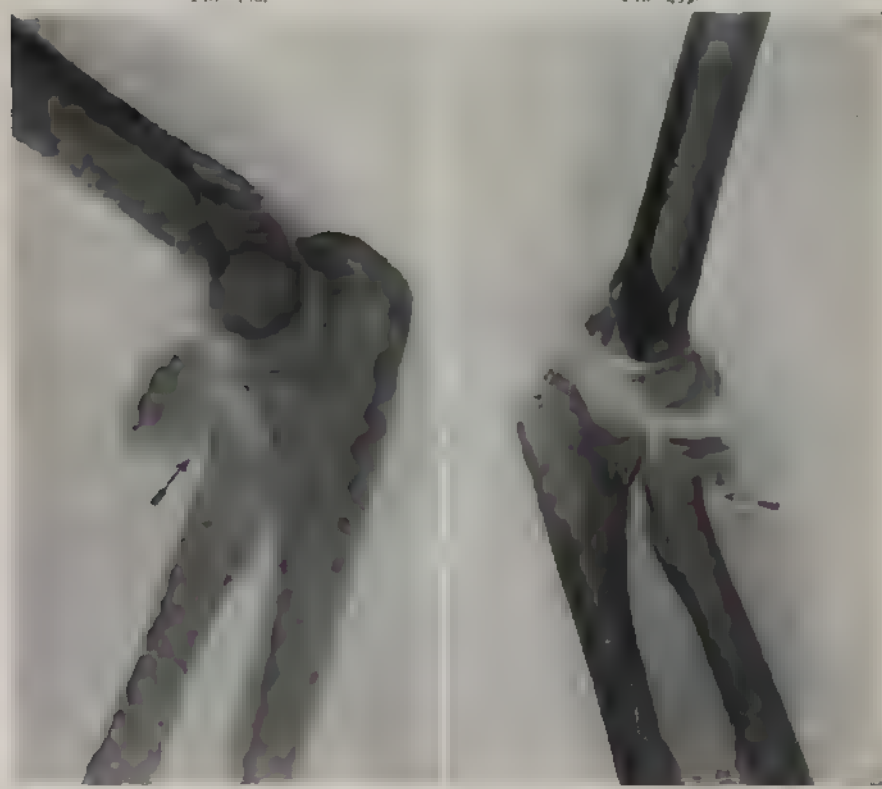

FIG. 458. FIG. 459.

FIG. 458.—Fracture of the neck of the radius with marked displacement of fragments.
FIG. 459.—Fracture of the neck of the radius

extremely rare. Its presence can scarcely be demonstrated even by the radiogram, unless there be marked separation. The centre for this epiphysis appears as a single centre about the fifth or sixth year, and becomes completely ossified about the seventeenth or eighteenth year.

Fractures of the Radial Epiphysis.—More common than separation of the radial epiphysis is its fracture (Fig. 457). This condition, however, is also rare. Fracture usually occurs through the upper portion of the epiphysis with the fracture line continuing into

the diaphysis. Impaction of the fragments is the rule. The case illustrated is bilateral and resulted from a fall over the handle-bars of a bicycle. The boy, who was thirteen years of age, fell on both palms with the elbows in full extension. Immobilization on an internal right-angle splint for three weeks was followed by perfect functional results.

Fracture of the Neck of the Radius.—Of 23 cases of fracture of the head and neck of the radius observed by Plagemann, 4 alone involved the neck. Of 18 cases of fracture of the head and neck of the radius studied by the authors in a collection of radiographs, 9 involved the neck of the radius alone.

Etiology.—Fracture of the neck of the radius (Figs. 458 and 459) results from indirect force, like falls upon the palm of the pronated hand with the elbow in extension, and forces causing severe abduction of the elbow. From the greater frequency with which fractures of the neck are associated with posterior dislocation of the ulna or with fracture of that bone, it seems probable that the lesion is more often the result of greater violence than is fracture of the radial head. Fracture of the coronoid process is also at times observed in conjunction with fracture of the neck of the radius.

Displacement.—The fracture may be transverse, oblique, or comminuted. Impaction with slight displacement occurs frequently. In other instances the fracture is attended with considerable displacement of the upper fragment, mainly characterized by partial rotation outward and forward. The line of fracture may be both intra- and extra-articular. Fracture of the head of the radius may also involve the neck when the line runs in a ventral direction.

Symptoms.—In fractures of the neck of the radius the most characteristic symptoms are marked swelling in the region of the head and neck, impairment of pronation, supination, and flexion. If the fracture is not impacted there will be noted crepitus at the seat of fracture on passive pronation and supination, with failure of rotation of the head of the radius. In addition there will be localized pain, swelling, tenderness, and in some cases noticeable deformity on palpation. In cases the result of severe direct violence or wrenching, there may be marked swelling of the soft parts with ecchymosis. A radiograph should be made in suspected cases.

Treatment.—The treatment of these cases depends upon the variety of fracture and the character of the displacement of the fragments. In impacted fractures with little displacement, good results may be obtained by immobilization for from three to four weeks upon an anterior right-angle splint. Gentle massage should begin at the end of the first week, and be followed by very gentle passive motion at the end of the third week. When impaction is not present and but moderate displacement of the upper fragment has occurred, attempts at

reduction should be made by manipulation; if reduction is obtained, immobilization as above outlined should be the method of procedure. The maintenance of reduction should be proved by radiography. If reduction is impossible, or its maintenance difficult, or if comminution of the fragments is present, arthrotomy and resection of the upper fragment should be performed.

Results.—Union occurs as a rule within three or four weeks. Non-union is not as frequent as in fractures of the radial head. Hitzrot reports ten cases of fracture of the neck of the radius treated by non-operative means with loss of about 25 per cent. of rotation.

Fig. 460.—Fracture of the shaft of the radius, upper third.

Isolated Fractures of the Shaft of the Radius (Figs. 460–463.)—Fracture of the shaft of the radius was observed by Plagemann 12 times in 73 such radial lesions, while isolated fractures of the shaft of the ulna were observed 15 times in 31 cases of ulna fracture. These statistics as to the relative frequency are similar to those generally reported. Of these 12 isolated fractures of the shaft of the radius Plagemann gives the localization as follows: 2 transverse fractures of the upper third; 3 oblique fractures at the junction of upper and middle thirds; and 7 fractures near the junction of the middle and lower thirds.

Etiology.—Fractures of the shaft of the radius are generally the result of direct violence. Indirect violence may occasionally produce the injury; especially when the force is applied in a longitudinal direction as in cases reported by Falkson. Muscular action easily produces a fracture. The line of fracture is usually oblique, spiral, or irregularly transverse.

Displacement.—As a rule the displacement of fragments is not great. Their position, however, is dependent upon the location of the fracture, its variety, and upon the action of the attached muscles, particularly the biceps, the pronator teres, and the pronator quadratus. The upper fragment of the radius in fractures above the insertion of the pronator teres is inclined to become supinated by the action of the biceps (Fig. 464) and pulled upwards. Below the insertion of this muscle up to the tubercle the displacement tends to cause angulation toward the shaft of the ulna, due to the pull exerted by the pronator teres and quadratus. When this fracture is below the insertion of the

pronator teres, the lower end of the upper fragment is apt to be pronated, and the hand may need to be pronated during treatment. When



FIG. 461. FIG. 462. FIG. 463.

FIG. 461.—Fracture of the shaft of the radius, junction of middle and upper thirds.
FIG. 462.—Fracture of the shaft of the radius, middle third.
FIG. 463.—Fracture of the shaft of the radius, lower third.



FIG. 464.—Drawing to show the effect of the triceps muscle in causing displacement of the upper fragment in fracture of the upper third of the shaft. (Made after roentgenogram, Fig. 460.)

the fracture is just above the square pronator the lower fragment may by spasm be pronated and drawn towards the ulna (Fig. 465).

Symptoms.—As most of the fractures are the result of direct vio-

lence, there is generally moderate swelling and ecchymosis of the overlying soft parts, localized pain, tenderness on pressure, abnormal mobility, deformity, and crepitus. When the thumb is placed over the head of the radius, and passive pronation and supination of the hand made, it will be found that the head of the radius fails to rotate unless impaction of the fragments is present or the fracture is incomplete. In very muscular subjects the diagnosis may be made with certainty only with the help of the radiogram.

Treatment.—Reduction of fragments may be accomplished by extension, counter-extension and local manipulation of the fragments. In fractures below the middle and in the lower third, when the upper



FIG. 465.—Drawing to show the action of the pronator quadratus muscle in producing displacement of the lower fragment in fracture of the lower third of the radius. (Made after roentgenogram, Fig. 462.)

end of the lower fragment is markedly inclined toward the ulna, reduction may possibly be aided by marked ulnar adduction of the hand in addition to traction and counter-traction. After reduction the parts should be immobilized upon carefully padded anterior and posterior splints, with the hand in a position midway between pronation and supination, or fully supinated. In fractures of the upper third or above the insertion of the pronator teres muscle, the tendency toward supination of the upper fragment due to the pull exerted by the biceps muscle should be remembered; and in this form the parts should be immobilized upon a right-angle anterior splint or moulded gypsum splints with the forearm in full supination. Immobilization with frequent re-

moval of dressings should be continued for three or four weeks. In cases in which satisfactory reduction cannot be accomplished or where non-union persists, the seat of fracture should be exposed, reduction accomplished, and a direct fixation by plate, wire, absorbable lashings, fascial envelopment, or inlaying of bone graft adopted.

Fractures of the Lower End of the Radius.—Fractures of the lower end of the radius constitute a large percentage of all fractures. Plagemann's statistics based upon radiographic diagnosis of 1393 cases show that there were 38 (2.72 per cent.) cases of fracture of the lower end of the radius.

The term Colles's fracture has by unfortunate custom been used for a long time to designate all fractures occurring at the lower end of the radius. The more closely, however, fractures here are studied, the more fully is the fallacy of using the term indiscriminately shown. There are so many varieties of fracture of the lower end of the radius possible that the term "Colles's fracture" and even that of "classic fracture" should be avoided. Many of these cases are clinically similar, and the form of treatment is more or less uniform.

Etiology.—Fractures of the lower end of the radius may be the result of falls upon the palm of the hand in a position of pronation, of falls upon the dorsal surface of the flexed wrist, by direct violence (chauffeur's fracture), and by the pull exerted by the anterior or posterior ligaments in a position of hyperextension or hyperflexion. In the majority of fractures of the lower end of the radius it may be generally stated that they are the result of a fall upon the palm of the hand which allows transmission, through the carpus to the radius, of the force due to the weight of the falling body and its velocity. In addition, the pull of the anterior carpal ligament in fractures occurring with the hand in a position of hyperextension, or the posterior carpal ligament in fractures with the hand in a position of hyperflexion, is a factor in the production of these fractures. The agency of the ligamentous attachments is clearly shown in the sprain-fractures seen about the wrist-joint. Fractures by direct violence are rare, except in the variety known as chauffeur's fracture; this injury is produced by the cranking handle of the gasoline engine in back-firing striking against the posterior part of the wrist-joint. All injuries resulting from this back-firing are not necessarily fractures of the lower end of the radius, for fractures involving the carpal and metacarpal bones have been thus caused. Sprain-fracture of the radius may result from back-firing by throwing the hand into a position of forcible hyperextension. In fractures produced by falls upon the hyperextended hand, the line of break, its direction, and the degree of displacement of the lower fragment depend to a great degree upon the amount of pronation present at the time of the fall. In falls forward the degree of

pronation is generally marked, while in falls to the side or backward the impinging hand generally is in a position of marked supination or semi-pronation.

Varieties.—Study of many radiograms and a small but well-illustrated group of pathological specimens has seemed to justify the following division of fractures occurring at the lower end of the radius:

1. Irregular, transverse fracture of the radius and ulna (Figs. 466 and 467). It consists of an irregular, transverse fracture line of both radius and ulna, situated from one to one and a half inches above the articular surface of the radius. It is mentioned here only on account of the clinical resemblance which it bears to the classic fracture of the base of the radius. It is most frequently observed during childhood.

2. Fracture of the styloid process of the radius (Figs. 468–471). The following varieties may be recognized:

(*a*) Fracture of the tip of the process.

(*b*) Fracture of the tip of the process with fracture of the shaft of the ulna.

(*c*) Fracture of the base of the process with fracture of the scaphoid. This fracture is relatively rare. It is the result of a fall upon the hand in a position of full pronation. It may be associated with fracture of the carpal bones, particularly the scaphoid. Infrequent forms of fracture of the radial styloid are those resulting from muscular pull with the hand in forced hyperflexion seen in the infrequent sprain-fractures.

3. Irregular, transverse fracture with posterior and at times outward (radial) displacement of the lower fragment (Figs. 472–477). It is often unwisely called Colles's fracture of the radius, although Colles did not describe the usual situation of the fracture line, but placed it ¾ to 1 inch further from the radio-carpal joint. Formerly the fracture line in this fracture was considered as running obliquely upward and backward. The line varies within certain limits, but it is generally near the point where the cancellous bone of the base is rapidly replaced by compact bone. Obliquity of direction of the fracture line is not necessarily characteristic, nor is the exact distance of the same above the articular surface. The principal characteristics of this well-known fracture are an isolated fracture of the lower end of the radius, with the fracture line generally transverse, about three-eighths to three-fourths of an inch above its distal extremity, with posterior and at times outward (radial) displacement of the lower fragment. Impaction of the fragment is often present, as is also outward displacement of the wrist, and rotation posteriorly of the articular surface of the lower end of the radius. The types of this "classic" fracture may be described thus:



FIG. 486.

FIG. 486.—Low transverse fracture of radius and ulna. Clinical resemblance to Colles's fracture.
FIG. 487.—Low transverse fracture of radius and ulna. Marked displacement of lower fragments.

Fig. 468



Fig. 469.

Fig. 470.



Fig. 471

Fig. 468.—Fracture of the tip of the styloid process of the radius.
Fig. 469.—Fracture of the base of the styloid process of the radius.
Fig. 470.—Fracture of the base of the styloid of the radius and of the styloid of the ulna.
Fig. 471.—Separation of lower epiphysis of radius with fracture of outer part of the diaphysis, resembling in a great degree fracture of the styloid process.

A FIG. 466. B



A FIG. 467. B

FIG. 466.—Low transverse fracture of radius and ulna. Clinical resemblance to Colles's fracture.
FIG. 467.—Low transverse fracture of radius and ulna Marked displacement of lower fragments.

Fig. 468



Fig. 469.



Fig. 470.



Fig. 471.

Fig. 468.—Fracture of the tip of the styloid process of the radius.
Fig. 469.—Fracture of the base of the styloid process of the radius.
Fig. 470.—Fracture of the base of the styloid of the radius and of the styloid of the ulna.
Fig. 471.—Separation of lower epiphysis of radius with fracture of outer part of the diaphysis, resembling in a great degree fracture of the styloid process.

(*a*) Those of adult life.

(*b*) Those of childhood.

(*c*) Associated with fracture of the styloid process of the ulna.

(*d*) Associated with comminution of the lower fragment.

(*e*) Associated with fracture of the neck of the ulna.

4. Irregular, transverse fracture with anterior displacement of the carpal fragment; sometimes called reversed Colles's fracture and Smith's fracture (Figs. 478 and 479). At times the line of fracture runs obliquely upward and forward. This lesion was first recognized by Smith and later Roberts collected 24 cases and 31 specimens.

5. Separation of the radial epiphysis (Figs. 480–483).

(*a*) With fracture of the diaphysis.

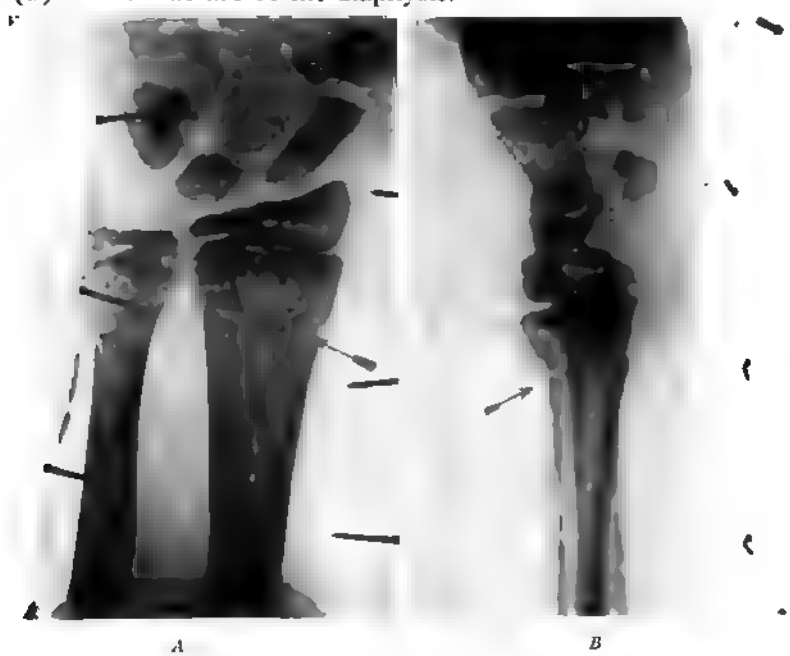

A B

FIG. 472.—Irregular transverse fracture of lower end of radius. Type of Colles's fracture. Note that external view shows usual rotation backward of lower fragment.

(*b*) With fracture of the anterior edge of the diaphysis.

(*c*) With fracture of the posterior edge of the diaphysis and accompanying separation of the ulnar epiphysis.

Isolated separations of the radial epiphysis are very rarely seen. It is doubtful if a pure epiphyseal separation ever occurs, excepting in very young children. The usual lesion consists in an accompanying fracture of either the posterior or anterior edge of the diaphysis, plus the separation of the epiphysis. The periosteum remains intact on the side opposite to the detached fragments. The lesion closely resembles the classic fracture at the lower end of the radius, except for the ab-

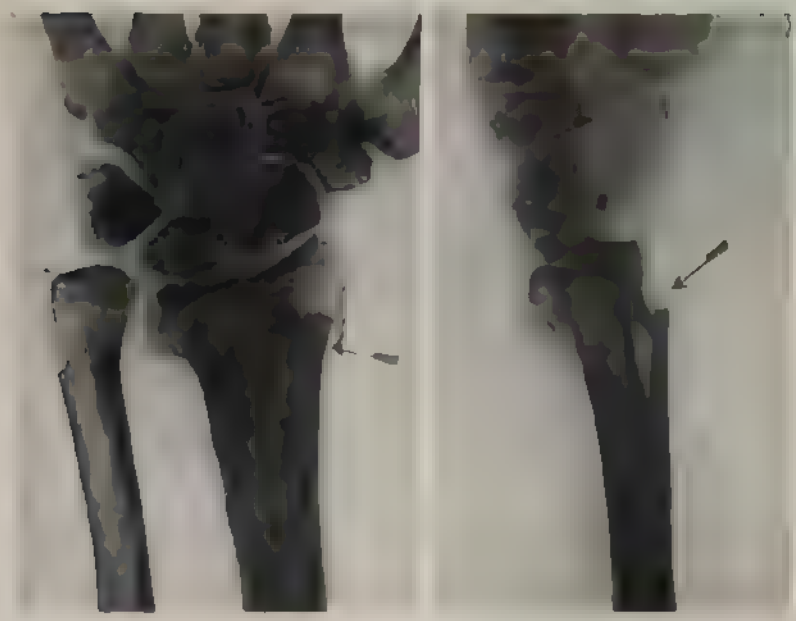

A B

FIG. 473.—Transverse fracture of the lower end of the radius with impaction of fragments and posterior displacement of the lower fragment



A B

FIG. 474.—Transverse fracture of the lower end of the radius with outward and posterior displacement of the lower fragment. This type gives the abduction and "silver-fork" deformity typical of many Colles's fractures.

sence of impaction, outward displacement, and loss of shortening of the distance between the radial styloid and the upper end of the bone.

6. Fractures through the carpal articular surface with separation of the posterior articular edge. This is the true but unusual Barton's

A B

FIG. 475.—Old united Colles's fracture with ununited fracture of the styloid process of the ulna. Note abduction and posterior displacement of lower part of radius. This fracture was never properly reduced.

FIG. 476.

1 B

FIG. 476.—Atypical type of fracture of lower end of radius. Note comminution of fragments. Not a typical form of Colles's fracture.

FIG. 477.

A B

FIG. 477.—Healed fracture of lower end of radius. Note posterior displacement and rotation of the lower fragment. Typical form of unreduced Colles's fracture in old people.

fracture (Figs. 484 and 485). This fracture may have associated with it a fracture of the ulnar styloid, or a fracture of the internal articular edge as well. Such injuries are usually the result of direct violence.

7. Fractures through the carpal articular surface with separation of the anterior articular edge. This may be designated reversed Barton's fracture (Fig. 486). They may be the result of direct violence or be produced by forcible hyperflexion, in which instances they may be well termed sprain-fractures.

8. Green-stick fractures (Figs. 487 and 488). Several varieties of green-stick fractures occur:

(*a*) Involving the entire thickness of the bone.

(*b*) Involving only a portion of the cortex (cortex or infolding fractures)

A B

FIG. 478.—Type of so-called reversed Colles's fracture. Note the anterior displacement of the lower fragment, which is shown well on lateral view.

(*c*) Involving the entire thickness of the shaft accompanied by a fracture of the ulnar styloid or shaft.

(*d*) A form of cortex fracture which is only recognizable after four to five weeks have elapsed, when it will be noticed by a deposit of cancellous tissue along the course of previously detached periosteum. In this form of fracture there is no appreciable bony lesion discoverable with the radiogram at the time of the injury.

Of particular interest is the infolding fracture. It is observed in children between the ages of seven and fourteen. The lesion consists of bending outward of the cortex and occurs where the resistant

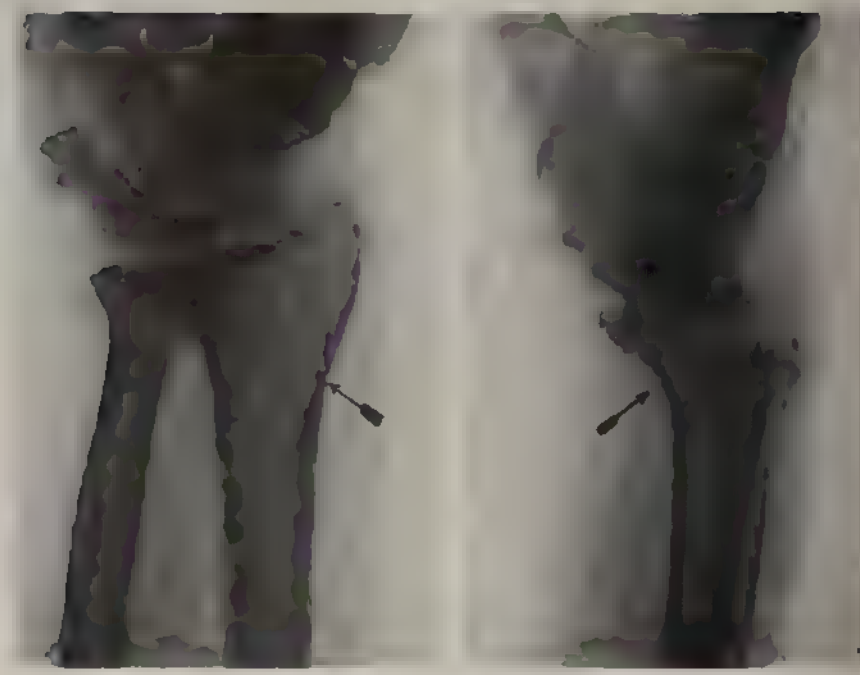

A B

FIG. 479.—Fracture of the lower end of the radius with anterior displacement of the carpal fragment. Note that the radial arch on the flexor surface is markedly increased. (The so-called reversed Colles's fracture, or Smith's fracture.)

FIG. 480 FIG. 481

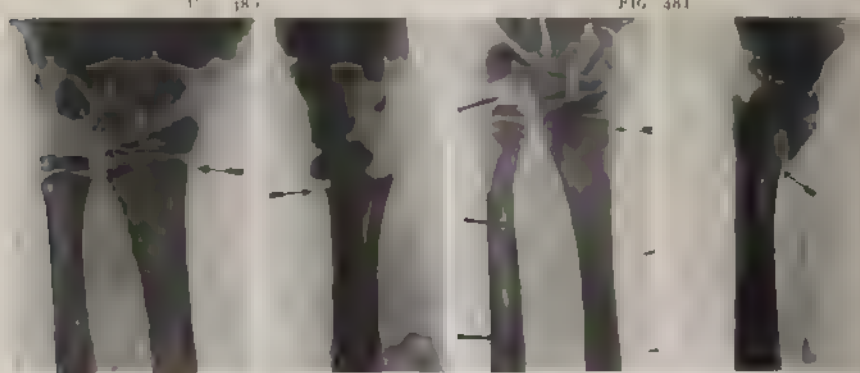

A B A B

FIG. 480.—Separation of lower radial epiphysis with posterior displacement of epiphysis, and a small fragment of the diaphysis.

FIG. 481.—Separation of lower radial epiphysis and fracture of the anterior portion of the lower edge of the diaphysis with anterior displacement of the lower fragment. (A reversed Colles's type.)

cortex meets the flexible cortex. The position of this fracture varies with the age of the child. The younger it is, the nearer is the line of fracture to the epiphysis. In childhood the cortex is still flexible, and as a result of impaction and slight flexion, the cortex bulges outward.

9. Longitudinal fissure fracture (Figs. 489 493). Irregular longitudinal fissuring may be observed, without transverse fracture, with transverse fracture, and with oblique fracture. This variety is rather unusual and is generally the result of transmitted force directed upward through the hyperflexed palm and carpal bones. A rare form is double longitudinal lines united by a transverse line resembling the Greek letter π.

10. Isolated oblique fracture running downward and outward

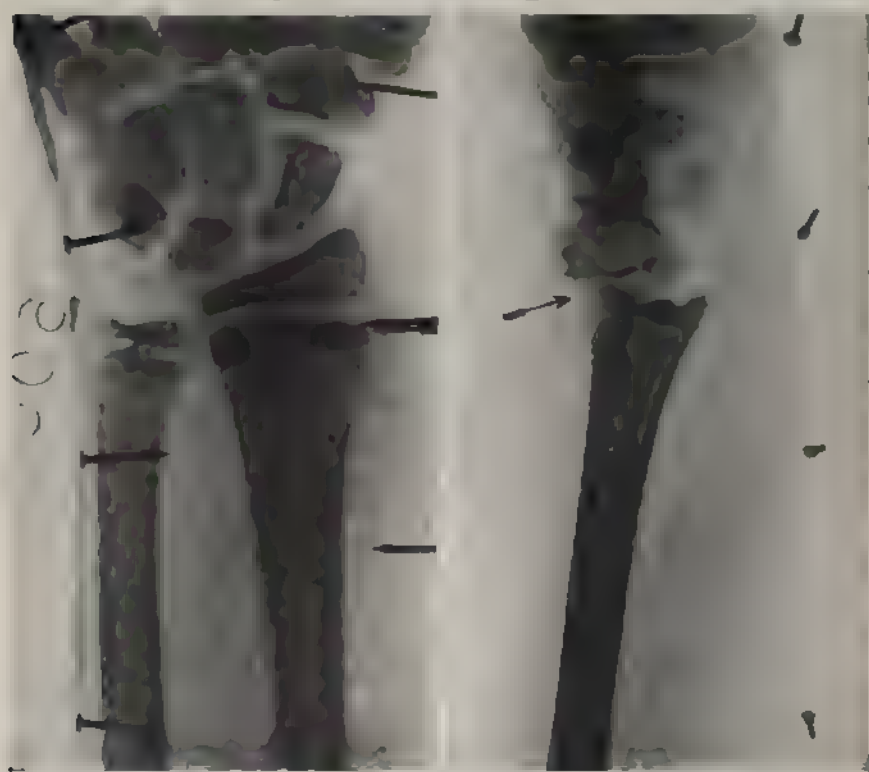

A B

FIG. 482.—Separation of lower radial epiphysis with posterior displacement of the lower fragment.

(Fig. 494). This lesion may have associated with it comminution and fissuring of the upper fragment.

11. Isolated oblique fracture running downward and inward (Figs. 495 and 496).

12. Transverse fissuring or incomplete fracture without displacement in the adult.

13. Sprain-fractures (Figs. 497 and 498). A variety of lesions may be classified under this term. These fractures are the result of rapid, forcible hyperflexion, hyperextension, or hyperadduction. The

A B

FIG. 483.—Separation of the lower radial epiphysis with outward and posterior displacement of the epiphysis.

FIG. 484. FIG. 485.



A B A B

FIG. 484.—Fracture through the carpal articular surface with separation of the posterior articular edge (Barton's fracture).

FIG. 485.—Fracture through the carpal articular surface with separation of the posterior articular edge.

lesion consists of the detachment of particles of cortex at the point of attachment of ligaments forcibly stretched.

14 Chauffeur's fracture (Figs. 499 501). Under this term are classified those fractures received while cranking a gasoline motor, when back-firing occurs. They are the result of direct violence from the starting handle hitting the back of the hand or forearm, or are due to forcible hyperextension. They differ in character, depending upon the mode of production. When due to direct violence, a transverse fracture usually results. When due to forcible hyperextension, the fracture partakes of the nature of a sprain-fracture. The location of the lesion depends upon the part struck when due to direct violence and may involve the radius alone, the radius and ulna, the carpal bones, or the metacarpals When due to hyperextension the lesion usually involves the anterior articular edge or the styloid process.

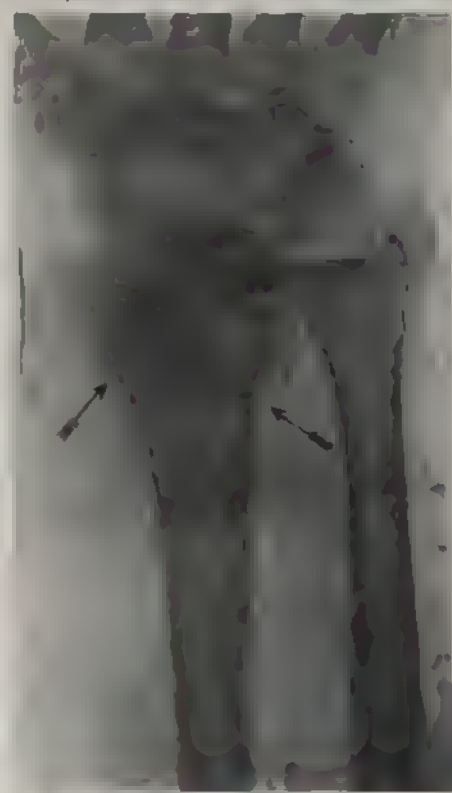

FIG. 486.—Fracture through the carpal articular surface with separation of the anterior articular edge (Reversed Barton's fracture.)

The above classification of fractures occurring at the lower end of the radius is sufficiently comprehensive to cover practically all forms in this region.

Symptoms.—It may be stated that unnecessary roughness is often used in endeavoring to make a diagnosis of fracture at the lower end of the radius. The necessity of pain-giving manipulation may be limited in the majority of cases by careful observation of the part and comparison with the other forearm Crepitus is a symptom which is often absent and it causes only pain to the patient to endeavor to demonstrate its presence. Many of these fractures are impacted and some comminuted, and crepitus is not demonstrable without undue force. In the classic fracture, when severe, inspection will show general swelling about the wrist-joint and even extending several inches above it. On the flexor surface there will be loss of the normal radial arch, and on the extensor surface swelling over the upper end of the lower fragment extending downward for a variable distance, presenting from a lateral position the so-called "silver-fork" deformity (Fig. 502). When the backward displacement is marked, the dorsal edge of the

lower fragment can be felt as a ridge about half an inch above the wrist-joint. This is best done by running a finger of the surgeon down the posterior surface of the radius. In addition to this deformity, there is generally abduction of the hand and broadening of the wrist (Figs. 503 505). Palpation of the parts shows loss of the radial arch at its lower flexor region and at times prominence of the lower end of the upper fragment on the flexor surface. Prominence of the lower fragment occurs posteriorly with rotation of the same back-

A B

FIG. 487.—Incomplete (green-stick) fracture of the lower end of the radius. Typical cortex or infolding fracture. Entire thickness of bone is not involved.

ward, so that the transverse plane of the articular surface of the lower end of the radius is rotated from ten to thirty degrees. Posteriorly there is a loss of prominence of the styloid process of the ulna, with a corresponding prominence of the same on the flexor surface of the wrist, so that it is brought into a closer relation with the pisiform bone. Comparison of the radial styloid with that of the ulna will show that it is carried toward the elbow and is therefore on a line with, or a little above, the ulnar styloid. Normally it occupies a lower plane

A B

FIG. 488.—Incomplete (green-stick) fracture of the lower end of the radius with fracture of the styloid of the ulna.

FIG. 489. FIG. 490.



FIGS. 489 AND 490.—Types of longitudinal fissure fracture of the lower end of the radius.

Fig. 491 Fig. 492 Fig. 493.

Figs. 491 to 493.—Types of [illegible] tissure fractures of the lower end of the radius

A B

Fig. 494.—Isolated oblique fracture of the lower end of the radius with the line of fracture running downward and outward.

(Fig 506) In many cases there is not only a posterior rotation and displacement of the lower fragment, but also an external or radial abduction of the carpus and fingers. The hand and fingers are held in semi-flexion, and full flexion is possible to a less degree relatively than full extension.

Impaction of fragments is present in many instances, so that crepitus and abnormal mobility are not readily determined The swell-



FIG. 495.—Isolated oblique fracture of the lower end of the radius with the line of fracture running downward and inward.

FIG. 496.—Isolated oblique fracture of the lower end of the radius with the line of fracture running downward and inward, also a fracture of the lower third of the ulna.

ing noticed in all fractures of the lower end of the radius may at times be augmented by an effusion of serum within the tendon sheaths, the presence of hemorrhage outside the sheaths, and effusion within the wrist-joint. The line of the radiocarpal joint is a curve with convexity upward in the normal condition. Pressure here will often differentiate a mere sprain or rheumatic arthritis from fracture above the joint, because the tenderness elicited will be over the curved joint line instead of over the base of the radius.

In the non-classic fractures of the lower end of the radius, the symptoms above described will be wholly or in part absent, and when present may show specific differences. Many of these fractures are unaccompanied by deformity or crepitus, the most noticeable symptoms being localized swelling and localized tenderness on pressure. This occurs when there is little displacement and little laceration of periosteum. In some cases, notably the transverse fractures with impaction and little deformity, the infolding fractures and the

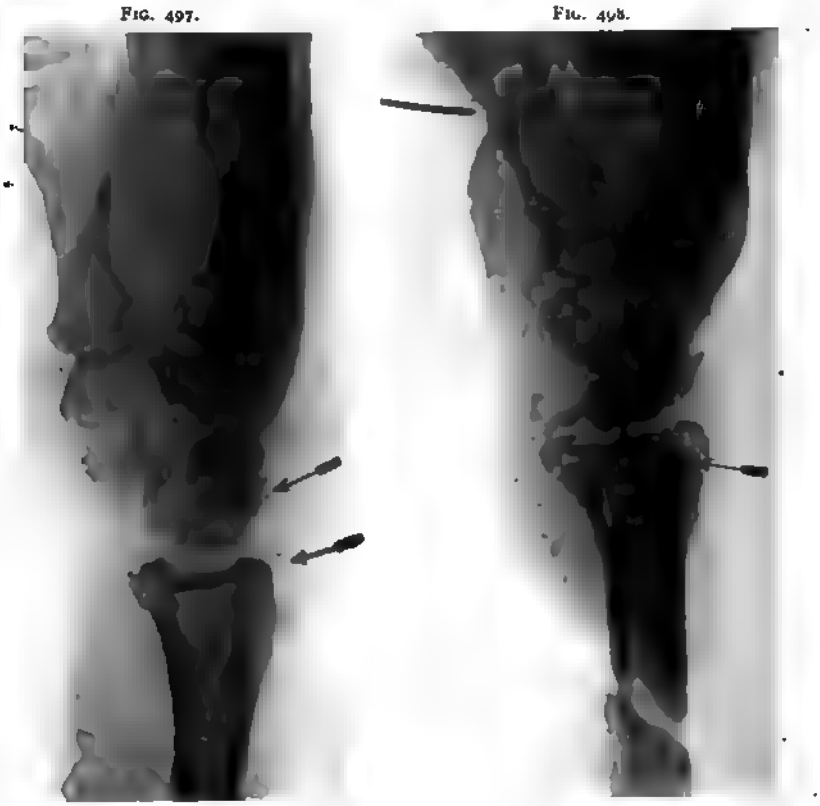

FIG. 497. FIG. 498.

FIGS. 497 AND 498.—Types of sprain-fracture of the lower end of the radius.

sprain-fractures, there may be bony lesions discoverable only by the radiogram.

In injuries about the wrist-joint, lateral and anteroposterior radiograms should be taken, if practicable, in all cases of doubtful diagnosis, and also when it is necessary to determine the degree of replacement of the fragments after reduction.

Diagnosis.—The diagnosis of fractures at the lower end of the radius is to be made by careful inspection, and palpation and the radiogram. Deformity when present is usually typical. The most striking

A B

FIG. 499.—Chauffeur's fracture. Line of fracture is at base of styloid process. No displacement of fragments.

FIG. 500 FIG. 501

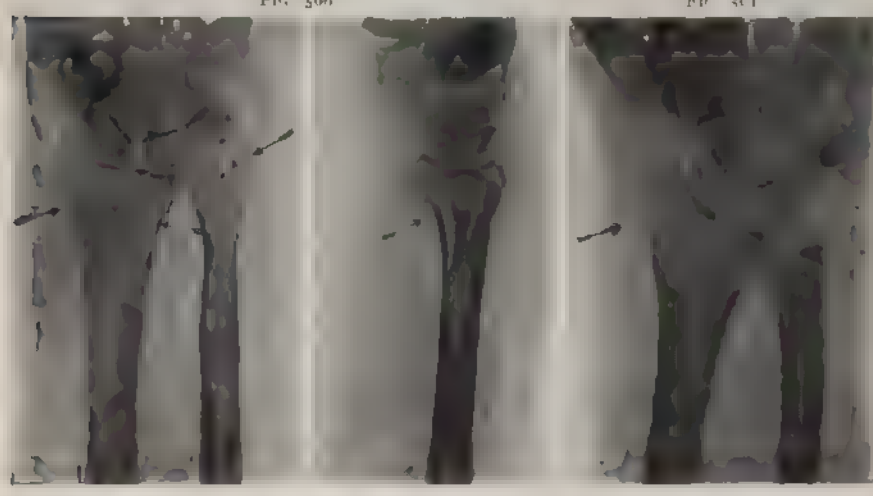

A B

FIG. 500.—Chauffeur's fracture. Line of fracture is transverse at lower end of radius, also involves styloid of radius, also a fracture of styloid of ulna.

FIG. 501.—Chauffeur's fracture by muscular action, a small portion of bone is torn out of outer part of radius at base of styloid process.

changes are absence of the radial arch, broadening at the wrist, rotation, and at times displacement of the lower fragment posteriorly, combined with localized swelling. There is generally effusion into the tendon sheaths. Lateral displacement of the hand, the so-called bayonet deformity, is frequently present, particularly in people of ad-



FIG. [illegible].—[illegible] Colles's fracture [illegible]. Note the so-called "silver-fork" deformity.

FIG. [illegible].

FIG. [illegible].



[illegible] prominence

[illegible] In doubtful cases the diagnosis may be made by the use of the radiogram.

[illegible] fragment usually [illegible] the wrist-joint [illegible] running from radial [illegible] with the patient's hand [illegible] towards the palmar surface [illegible] there is much



FIG. 505.—Drawing to show deformity which may occur in fracture of the lower end of radius and ulna. Note posterior displacement of both lower fragments.

FIG. 506.—Method of palpation to determine the relative positions of the styloid processes of the radius and of the ulna. Normally that of the radius occupies a lower plane than that of the ulna.

displacement radially the edge of the fragment may be felt as a ridge on the radial border above the wrist

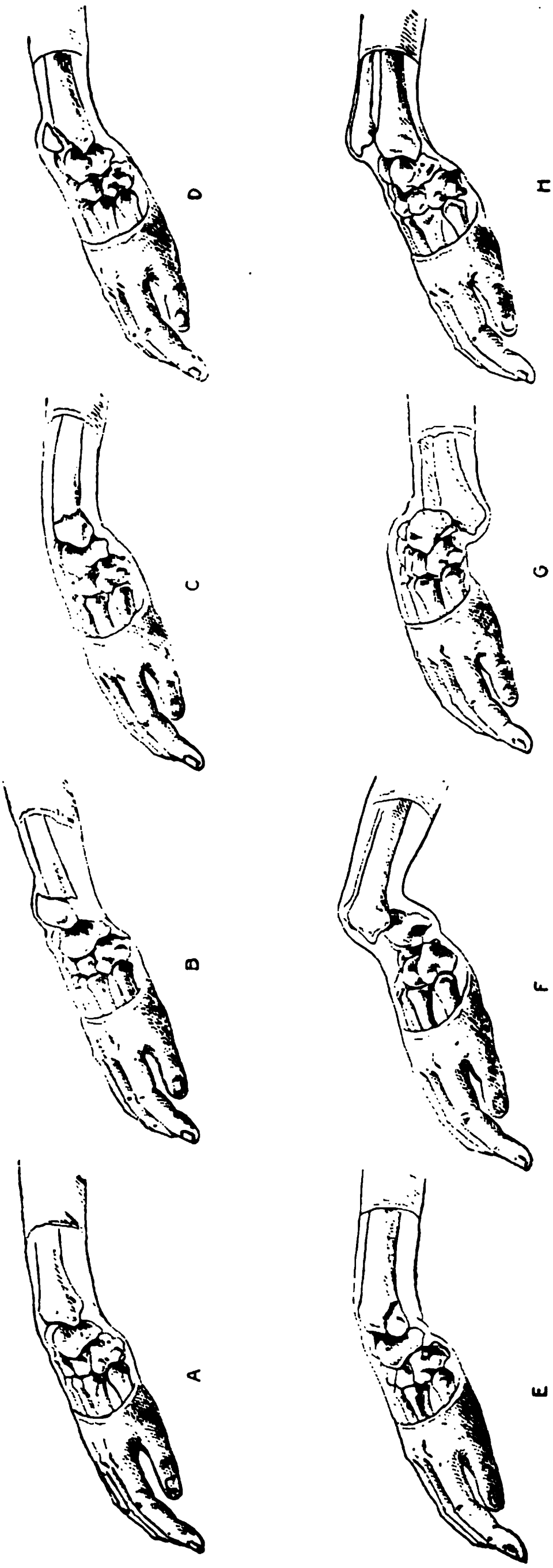

FIG. 507.—Diagrammatic drawing to show the various lesions with their deformities that may occur about the wrist-joint; *A*—normal wrist joint; *B*—Colles's fracture; *C*—reversed Colles's or Smith's fracture; *D*—Barton's fracture; *E*—reversed Barton's fracture; *G*—posterior luxation of carpal bones; and *H*—rupture of radioulnar ligaments with prominence of ulnar styloid.

Differential Diagnosis (Fig. 507).—Conditions that may be confused with the classic fracture are backward and forward luxation at the radiocarpal articulation, mediocarpal luxation backward, chipping off at the posterior edge of the radius at the radiocarpal joint and of the anterior edge of the radius.

In these instances the radiogram is of invaluable assistance in arriving at a correct diagnosis. Careful comparative study of the anatomical relations of the two wrists will aid much. The test to discriminate between radiocarpal arthritis and fracture by pressure over the joint line has been mentioned. Fracture without displacement will be made evident by tenderness on pressure and will perhaps show within a few days a localized ridge of callus. It must be remembered that the uninjured wrist may be somewhat deformed by previous fracture forgotten by the patient. Recently such an instance occurred in the practice of one of the authors. The woman denied the receipt of any injury of the opposite arm, but the suspicion of the surgeon was confirmed by X-ray study.

Treatment.—In the treatment of fracture at the lower end of the radius it is well to have a clear conception of the exact nature of the fracture before reduction is attempted. In the typical or classic fracture, without complicating lesions, however, reduction usually may be performed satisfactorily without a primary radiogram. This statement applies particularly to the fracture with backward displacement of the lower fragment. The most important task in the treatment of typical fractures at the lower end of the radius with posterior displacement of the basal fragment is to obtain complete reduction. To retain the fragments in their proper position after reduction, until union has occurred, is not very difficult. The vital mistake often made is not securing complete reduction. In many instances this will be secured only with the help of an anæsthetic, because the pain of forcible reduction is great. Primary anæsthesia with ether or momentary unconsciousness from nitrous oxide gas is all that is necessary. Bad results following this fracture are usually attributable to the surgeon's failure to secure reduction and not to faulty methods of immobilization.

If the fragments are thoroughly reduced, the tendency to recurrence of the deformity is slight except when the lower fragment is much comminuted or the complicating fracture of the ulnar styloid or head permits displacement. After thorough reduction, the simplest form of retention will suffice in most cases, provided that the arch of the lower fifth of the radius on its flexor surface is thoroughly reconstructed. The existence of this arch-like contour in the normal radius is often forgotten. There are many methods of reduction which may be used in the reduction of fractures of the base of the radius. In many fractures here, notably the sprain-fractures, comminuted frac-

tures, and fractures of the radial styloid, reduction is accomplished with little effort and without anæsthesia. It is, however, in the most frequent typical and nearly transverse fracture that considerable effort at reduction is necessary. Firm impaction is present in a large number of instances. No one method of reduction is applicable to all cases.

Frequently reduction may be accomplished by firmly seizing the forearm, with one hand at the junction of its middle and lower thirds for counter-traction, and making traction by grasping the wrist of the patient with the other hand, which should encircle his wrist-joint, with the thumb pressing upon the backwardly displaced lower fragment. The fragments should be disengaged by traction and counter-traction, aided perhaps by first increasing the deformity by forcible dorsal extension at the seat of the fracture. Strong pressure with the operator's thumb will aid in forcing the lower fragment into place. After the fragments have been disengaged, marked flexion at seat of fracture is made, combined with adduction. This latter procedure will correct posterior displacement of the lower fragment, re-establish the radial arch, and overcome the abducted position of the lower fragment, which is so frequently present in the typical injury (Figs. 508–510).

After the radial arch has been corrected, the undue prominence of the ulnar styloid changed, and rotation and adduction of the lower fragment accomplished, one may be reasonably sure of obtaining a good result if the corrected position of the lower fragment is maintained until union has occurred.

Maintenance of reduction may be accomplished by the use of any of several forms of dressing. A gypsum splint moulded to fit the dorsal or the flexor surface when the wrist is somewhat flexed cannot be improved upon. In reduced fractures with little tendency to displacement, a slightly padded, narrow wooden splint applied to the dorsal surface of the forearm and hand, extending from a few inches below the elbow to a point just above the metacarpophalangeal joints, will steady the fragments and be all that is necessary (Figs. 511 and 512). This is due to the circumstance that the dorsum of the reconstructed radius is practically level (Fig. 513). This is not the case with the flexor surface of the radius, which is arched in its lower fifth. If a wooden splint is placed on the palmar surface, it must be covered with sheet-wadding and have a hard pad placed at its lower end to fill the normal radial arch. It should in many cases be supplemented by a posterior splint. The splints may be attached to the forearm and hand by thick strips of adhesive plaster one and one-half inches in width, the upper strip at the upper level of the splint, the second strip over the lower fragment, and the third strip, about one-half inch in width, should be applied to the lower end of the splint and hand (Fig. 514). Over the splint, forearm, and hand a snugly-fitting muslin bandage



FIG. 508.—Method of breaking up impaction of a classic fracture at the lower end of the radius by increasing the deformity.

FIG. 509.—Method of reduction of a classic fracture at the lower end of the radius by forcible carrying forward of the lower fragment, with adduction of the hand.



FIG. 510.—Morton's method of reducing a Colles's fracture by sudden snapping of the lower fragment forward. The thumbs are placed on the posterior surface of the lower fragment, the interlocked fingers of both hands on the anterior surface of the lower end of the upper fragment, and by a sudden snapping motion the lower fragment is carried forward with the hand of the patient.

two inches in width should be applied and the part put at rest in a comfortably fitting sling. It is probably of little consequence whether the forearm and hand are kept in the semi-prone or the fully prone posture, if the reduction is complete and the radial arch maintained.

In fractures in which there is marked tendency to repeated displacement of the fragments, anterior and posterior splints of basswood are applied by some. They should be of the same length as described above. Both splints should be pistol-shape, so as to maintain adduction of the lower fragment and hand. They are best described by the accompanying illustrations. The two splints should be carefully padded with four to six layers of sheet-wadding and, in addition, a pad of sheet-wadding should be placed on the flexor surface of the forearm to maintain the lower end of the upper fragment in its proper position and retain the normal radial arch (Figs. 515–517).



FIGS. 511 AND 512.—Show application of posterior padded straight splint for immobilization of fracture at the lower end of the radius when there is no tendency toward recurrence of the deformity.

If reduction is complete and the wrist kept flexed, the extensor tendons will hold the lower fragment in place nearly always. A pad may be at times placed over the posterior portion of the lower fragment, but great care should be used in its application, as pressure sores are prone to develop if the dressing is at all tight. In many instances this pad is unnecessary. It is well to remember that in fractures, pressure from pads for the purpose of reducing deformity is dangerous. The splints should be held to the forearm and hand with three strips of adhesive plaster, as shown in the illustration, and over all a snugly-fitting muslin bandage should be applied. The forearm should be carried in a sling until union is firm. The use of strips of adhesive

plaster around limbs to hold splints in position is fraught with danger, except in skilled hands. Inflammatory swelling may unexpectedly occur, and cause injurious constriction.

The treatment of these cases is well conducted with moulded contour splints of plaster-of-Paris. A plaster bandage should not be applied in a circular manner until swelling has subsided, but an anterior or a posterior splint should be moulded from gauze and gypsum, properly padded with a thin layer of sheet-wadding and applied to the part. The splints should be held in place with a gauze bandage. Whatever dressing is adopted, reduction of the fragments must first

FIG. 512.—Demonstrating the plane of the posterior aspect of the bones of the forearm and hand.

FIG. 513.—Method of application of anterior and posterior padded splints for fracture at the lower end of the radius. Note supplementary pad to retain radial arch.

be secured, and in all cases the fingers should be allowed opportunity for active movements from the very beginning of treatment.

As has been said above, splints may be applied with the hand in a position of semi-pronation or pronation, though even supination is not objectionable. Every fracture should be inspected not later than twenty-four hours after the application of the splint; the bandage should be removed, and the parts examined for areas of undue pressure, and the splint or splints reapplied. The surgeon should always remove the splints immediately and examine the parts if there is any evidence of undue swelling or cyanosis of the fingers. This precaution should be taken for pain, numbness, paræsthesia, and for localized pain

FIG. 515

FIG. 516

FIG. 517



FIGS. 515, 516 AND 517.—Method of application of the anterior and posterior padded abduction splint. This form of splint is useful in maintaining reduction of fragments when there is a tendency toward adduction deformity.

in the region of the lower fragment or the bases of the second and third metacarpals posteriorly. If a moulded metal (Figs. 518 and 519) or gypsum splint is used on the palmar aspect of the forearm, it should

extend as far as the middle of the palm, and the wrist should be partially flexed.

The line of treatment here indicated is that to be used in practically all recent fractures of the lower end, or base, of the radius. When the ulnar styloid is broken from its shaft, as a complication of the break of the radius, it is well to deflect the hand a little towards the ulnar border of the forearm by the retentive dressing. A small pad against the broken process or a "thumb dent" in the gypsum splint may aid in holding the little fragment in place. Union is apt to be fibrous, probably because it usually is not kept in contact with the shaft. This defect is not very important.

FIG. 518.

FIG. 519.



FIGS. 518 AND 519.—Use of the Levis's metal splint in the treatment of fractures at the lower end of the radius.

After-treatment.—The dressing should be inspected every one or two days for the first week, and every third day during the second week. If the radiogram shows that reduction is faulty, further reduction should be accomplished. At every dressing the splint should be removed, the arm bathed, and moderate massage and passive motion of the wrist-joint performed by the surgeon. At the end of the second week the posterior splint may be discarded if two splints have been employed. At the end of three or four weeks all may be removed. An adhesive plaster cuff two inches wide may be used for

slight protection for a week or two longer. Some patients who are careful or are not exposed to strain upon the forearm and hand will not require such a long period of restraint. Some cases will need very little dressing, except an adhesive plaster cuff, from the beginning.

The more or less transverse fracture about a half inch above the radiocarpal joint, with displacement of the lower fragment forwards, is often called Smith's fracture, or reversed Colles's fracture. It produces a deformity resembling the planes of a gardener's spade instead of the silver-fork deformity of the typical transverse fracture in the same portion of the radial base.

Its treatment should be conducted on the same principles as the typical or so-called classic fracture, which is similar in etiology except that the force in that instance drives the lower or basal fragment backwards. Forcible reduction, under anæsthesia if need be, to reconstruct the normal arch of the palmar surface of the radius is demanded. Then a moulded gypsum splint to maintain the integrity of this arch or a metal splint similarly fitting the anatomical contour should be applied, permitting free motion of the fingers. Frequent removal of the retentive dressing, with light massage and mobilization, will complete the cure in about three or four weeks.

The classic fracture is very common, is often mistaken for a strain, is very frequently badly treated, because not reduced, and therefore causes patients and physicians much trouble. It is easily treated if promptly reduced and kept reduced. The dressing should be simple and frequently removed for inspection during the first ten days. Then it may be replaced by a gypsum encasement, split or not split.

Surgeons see every year cases that have not been reduced. Refracture should then be performed if the injury is less than three months old. After that osteotomy is probably better. The incision should be made on the radial edge of the wrist. Sometimes there is great radial deviation from imperfect reduction of the fragments or crushing or impaction of bone; sometimes the ulna may cause a prominence at the back of the wrist. The ulna may be shortened by removing a disk with the Gigli wire saw, if the radial displacement of the hand is great from shortness of the radius. If deformity arises from unreduced anterior displacement of the carpal fragment, osteotomy will be a means of relief as it is in unreduced posterior displacement

After-results.—It is a remarkable fact that many bad anatomical results are finally followed by fairly good functional results. Bad functional results are in most instances due to incomplete reduction of fragments. In a small number of cases, however, poor functional results are due to a perineuritis, limitation of motion due to a coincident tenosynovitis followed by adhesions and circulatory disturbances. Many of these poor results will be obviated by passive motion

and massage from the day of fracture. This is especially so in people of advanced years. In these cases the part should not be allowed to stiffen. This can be prevented by daily massage and passive motion. Bad results nearly always mean failure to reduce fragments, or incomplete reduction and prolonged immobilization. Both factors may be the cause of the bad result.

In cases in which deformity persists, it is generally due to failure of reduction, and consists in posterior displacement with rotation and abduction of the lower fragment; the ulnar styloid is prominent, the radius shortened, and the wrist broadened. Fractures of the lower end of the radius have a reputation of being difficult to treat with favorable results. This opinion is due to the long-standing unwillingness of many members of the profession to admit that complete reduction immediately after the receipt of injury is the keynote to success. Early complete reduction, early superficial massage, and early mobilization, active and passive, will give a satisfactory functional result in the vast majority of fractures of the base of the radius. These fractures are especially satisfactory for treatment if the surgeon appreciates these necessary factors in the management of the lesion. They prove the doctrine of Lucas-Championnière to be of high significance in fracture treatment.

Summary of Treatment of Fractures of Radius and Ulna

REDUCTION FIRST

Fractures of Radius and Ulna Combined.—Upper Two-thirds of Shafts.—Flexed elbow, supination, anterior angular support with gypsum contour splint, wood or metal angular splint. Sometimes additional posterior splint. Gypsum encasement after swelling, but must be split to give frequent inspection. Look out that round pronator does not pronate upper fragment of radius.

Lowest Third of Shafts.—The same as above; immobilization of elbow not always necessary in lowest third, but use an anterior and a posterior splint. Operation if reduction is not maintained, direct fixation.

Fractures of Ulna (Isolated).—Olecranon, extended elbow with anterior straight splint or gypsum-gauze contour splint. Operation occasionally.

Coronoid process, hyperflexion of elbow. Operation of excision sometimes needed.

Shaft.—Upper two-thirds, flexed elbow, supination, anterior right angle splint or gypsum-gauze contour splint.

Lowest one-third, flexed elbow, supination, an anterior and a posterior splint; or, if no displacement, anterior splint of gypsum, wood or metal only, from elbow to mid-metacarpal region.

Fractures of the Radius (Isolated).—HEAD.—Flexed elbow; supination, with anterior right angular splint; or pronation with internal angular splint. Operation for excision of head occasionally.

NECK.—Flexed elbow, anterior right angle splint, operation for excision of fragment occasionally.

SHAFT.—Upper one-third flexed elbow, supination, right angle anterior splint or gypsum contour. Middle and lower one-third flexed elbow, mid-pronation, anterior and posterior splints from elbow to metacarpal heads. Operation for direct fixation with moderate frequency.

LOWER END OR BASE OF RADIUS.—Be sure to break up impaction, and reduce with great force, if necessary, to restore arch of anterior surface of radius. Maintain with wrist flexed, in usual fracture, by anterior trough, or posterior contour of gypsum-gauze; or, if do not flex wrist, employ posterior straight splint or anterior and posterior straight splints with firm pad under arched lower fifth of anterior surface of bone.

Old unreduced fracture, refracture, or reconstruct bone by osteotomy.

CHAPTER XVII

FRACTURES OF THE CARPAL BONES

Anatomy.—The eight bones forming the carpus (Fig. 520) are arranged in two rows, the proximal and the distal. Enumerated from the radial to the ulnar side the proximal row are: scaphoid, semilunar,

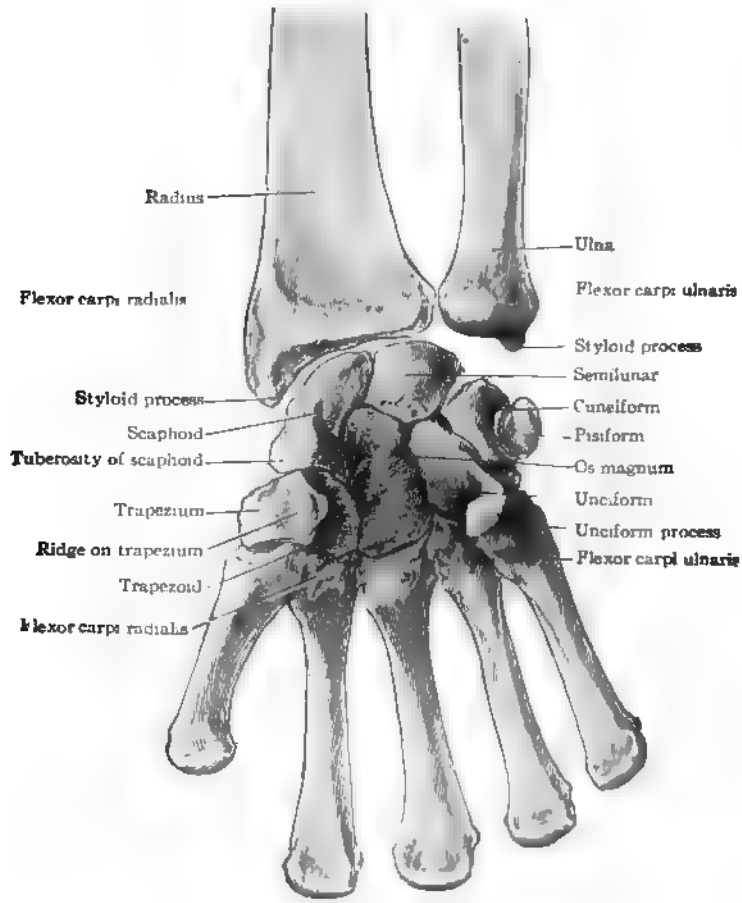

FIG. 520.—Anterior view of the bones of the carpus and the metacarpus. (Davis.)

cuneiform and pisiform; the distal row are: trapezium, trapezoid, os magnum, and uncifonn.

The lower end of the radius and the lower surface of the triangular fibrocartilage articulate with the upper surfaces of the scaphoid, semilunar, and cuneiform bones. The ulna is separated from the articulation by the triangular fibrocartilage; the pisiform bone does not enter into the articulation. The lower row of carpal bones articulates with

the metacarpals as follows: the trapezium with the first metacarpal, better called the proximal phalanx of the thumb; the trapezoid with the second metacarpal; the os magnum with the third metacarpal; and the unciform with the fourth and fifth metacarpals. The carpal bones are irregularly shaped and take their names from objects which they resemble.

The carpal ligaments join the bones of the forearm, the carpal and metacarpal bones, together and consist of the radiolateral ligament, the ulnar lateral ligament, the anterior radiocarpal ligament, the posterior radiocarpal ligament, and the transverse carpal or anterior annular ligament. In addition there are ligaments which unite the carpal to the metacarpal bones, and are known as the volar and dorsal intercarpal, the volar and dorsal carpometacarpal ligaments, and the volar and dorsal basal ligaments.

Surface Markings.—The site of the radiocarpal joint is the space between the styloid process of the radius and the tubercle of the scaphoid and its line is convex proximally. The line of the intercarpal joint corresponds to the lowest transverse furrow in front of the wrist; this also marks the upper edge of the anterior annular ligament. On the flexor surface of the wrist the tubercle of the scaphoid may be felt below the styloid process of the radius, the trapezium below the tubercle of the scaphoid, the pisiform below the ulnar styloid, and the cuneiform to the inner side of the pisiform.

Statistics.—Plagemann's statistics from Müller's surgical clinic at Rostock, based upon radiographic diagnosis of 1393 fractures, shows the carpal bones to be involved in 29 instances (2.08 per cent.), divided as follows:

		Per cent.
Fractures of the scaphoid	13	0.93
Fractures of the semilunar	5	0.359
Fractures of the cuneiform	3	0.21
Fractures of the os magnum	1	0.07
Fractures of the scaphoid and semilunar	5	0.509
Fractures of the scaphoid, semilunar and cuneiform	1	0.07

Etiology.—Fractures of the carpal bones may be the result of direct violence, as a blow from a heavy instrument, or of indirect violence, as a fall upon the hand either in flexion or extension, and at times with the hand in rotation or abduction. They most frequently result from such forces as usually produce fracture of the base of the radius, viz., a fall upon the extended or hyperflexed pronated hand. They are occasionally seen in combination with fracture of the bones of the forearm, usually a fracture of the styloid of the radius or a comminuted fracture of the lower end of the radius. Carpal fracture may occur in conjunction with a dislocation of other carpal bones. The variation in frequency is well shown in Plagemann's statistics.

Symptoms.—Those common to fractures of any of the carpal bones are localized pain, tenderness on pressure, and local swelling, and pain on movement of the wrist-joint, particularly on abduction or adduction. Many of these cases go unrecognized for weeks and are erroneously treated as sprains of the wrist-joint. At times there is a history of injury, followed by severe pain, swelling and tenderness, with pain on motion, which after a few days subsides to a certain degree but fails to entirely disappear. There is inability of full passive flexion or expansion of the wrist-joint, which is accompanied by muscular spasm. There is generally no crepitus or ecchymosis present. Swelling persists, and the outline of the extensor tendons of the thumb is more or

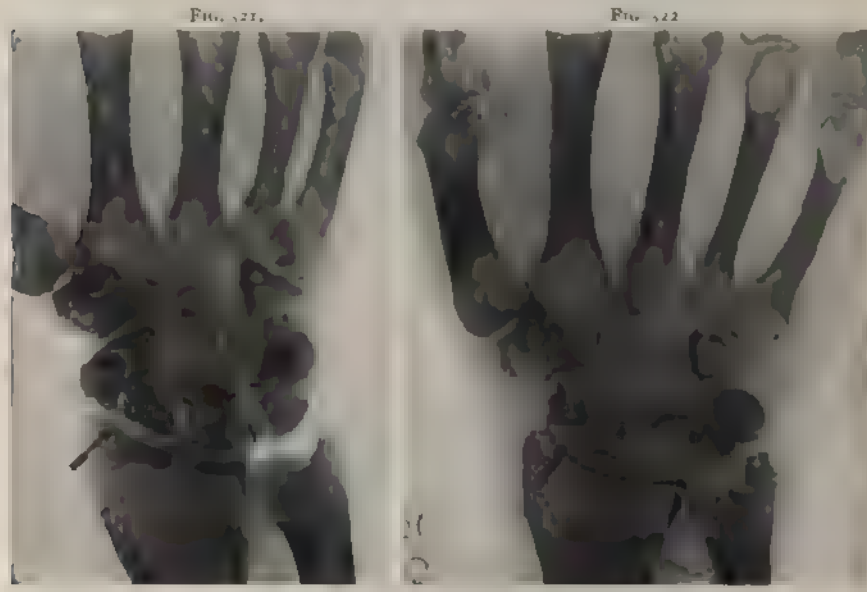

Fig. 521.—Comminute fracture of the carpal scaphoid.
Fig. 522.—Fracture of the carpal scaphoid.

less obliterated by this persistent swelling, particularly in fractures of the scaphoid.

In fractures of the scaphoid (Figs. 521–525) there is limitation of extension, local pain in the hollow between the extensors of the phalanges of the thumb, when the hand is in the adducted position. The lesion is generally a fracture at the neck of the scaphoid, without much displacement of fragments. When displacement of fragments occurs, it is generally the proximal fragment that is dislocated. Flexion of the wrist shows abnormal prominence formed by the scaphoid, anteroposterior thickening, and definite pain and tenderness over the scaphoid in the region of the anatomic snuff-box and at times posteriorly. In old cases there will be found definite swelling over the

Fig. 523 Fig. 524.

Figs. 523 and 524.—Sprain-fracture of the tubercle of carpal scaphoid.

Fig. 525 Fig. 526

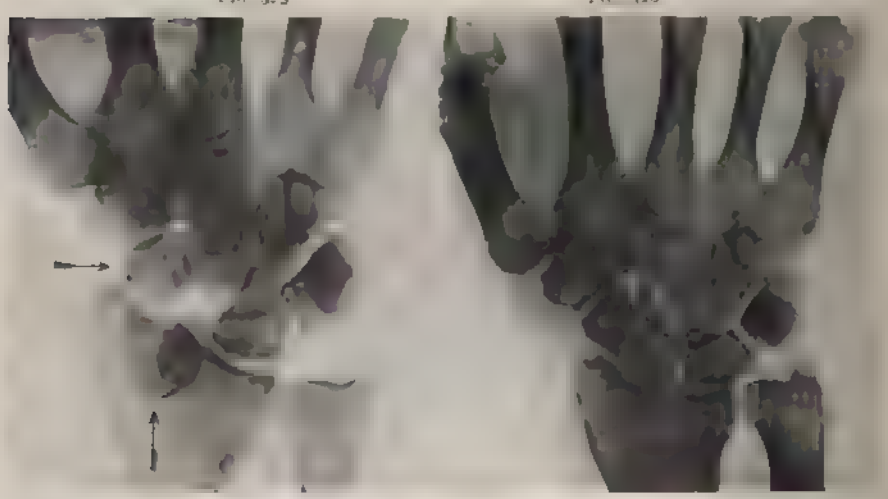

Fig. 525.—Fracture of the carpal scaphoid with backward luxation of the radial fragment, which was removed at operation.
Fig. 526.—Fracture of carpal semilunar, direct violence.

radial half of the wrist-joint. In all cases anteroposterior and lateral radiograms should be made, so that a definite diagnosis may be made and the presence of comminution or displacement of fragments noted. *It should be* remembered that occasionally supernumerary carpal bones

or additional centres of ossification may be mistaken for fractures of carpal bones, when X-ray examinations are made.

Fractures of the semilunar are usually the result of great direct violence, gunshot and open wounds, and are generally associated with other injuries. Fracture of the semilunar (Fig. 526) shows local pain, tenderness on pressure, and pain on motion, particularly on forced extension. Swelling is marked over the region of the bone rather than being limited to the radial side, as in scaphoid fractures.

Fractures of the cuneiform are extremely rare. They are the result of direct violence. The same may be said of the remaining carpal bones. The usual symptoms would be local pain, tenderness on pressure, and passive motion with local swelling.

Diagnosis.—Injuries of the wrist-joint should be carefully studied clinically, and by radiography, always in two planes, when suspicious symptoms persist for more than a day or two and diagnosis is difficult. Actual fracture usually will show that active and passive movements at the wrist-joint are limited and painful; and attempts to continue passive motion beyond a certain degree probably will be followed by extreme pain and at times muscular spasm. Crepitus and ecchymosis are rarely observed, while swelling is persistent. When these symptoms last for a considerable length of time a diagnosis of carpal fracture may with propriety be made, and can often be confirmed by radiogram.

Treatment.—The line of treatment to be adopted in the individual case depends upon the time which has elapsed since the receipt of the injury, and the occurrence or absence of displacement of fragments. When dislocation of a fragment or fragments is present, which cannot be overcome by manipulation, excision of one or several fragments should be performed. When there is no displacement of fragments and the patient is seen shortly after injury, attempts to secure union should be made during from four to six weeks. This is to be undertaken by placing the hand and forearm at rest upon a well-padded anterior splint of wood, reaching from the bend of the elbow to the tip of the fingers, with the hand in semi-pronation. Instead of this dressing a well-fitting plaster-of-Paris case, which is better, may be used. If union has not resulted in four to six weeks, as shown by the radiogram, excision of one or both fragments should be performed. Whenever symptoms of discomfort or disability persist after excision, the parts should be immobilized for a period of two weeks, when active and passive motion should be begun. Supernumerary bones or unusual ossific centres should be differentiated from the supposed fracture before operation is performed for removal of a suspected fragment. Gouty or tuberculous disease might be the cause of the carpal pain and swelling. A slipping fragment may be held in place until union occurs by boring a small hole with a brad-awl and nailing it in position with a steel needle or a small wire nail.

CHAPTER XVIII

FRACTURES OF THE METACARPAL BONES

Anatomy.—The metacarpal bones (Fig. 520), five in number, support the fingers and form the skeleton of the palm of the hand. They are long bones and may be divided into a base, shaft, and distal end or head. The bases articulate with the carpal bones and the heads articulate with the proximal phalanges.

The metacarpophalangeal articulations are characterized by the fact that, while the articular surfaces are irregularly spherical, the range of motion is limited by the strong lateral ligaments, so attached

Fig. 527. Fig. 528.

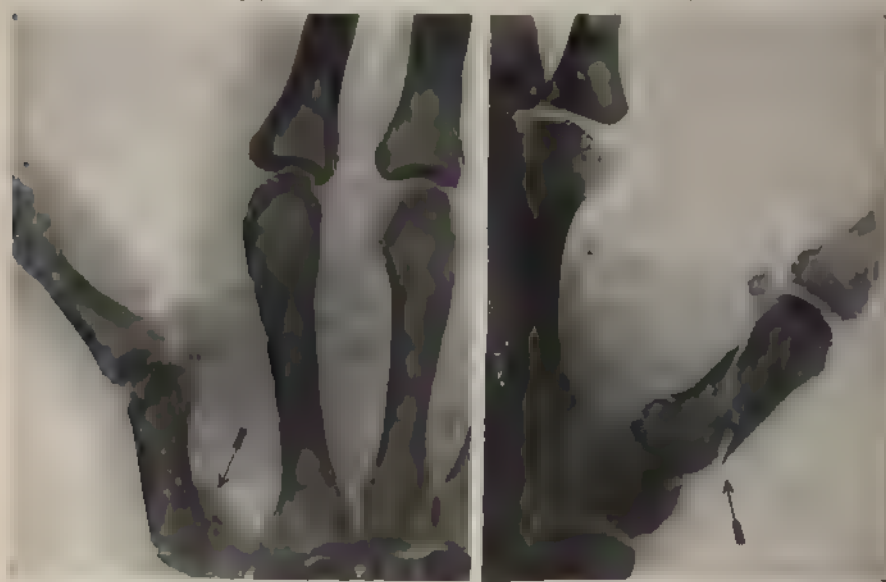

Fig. 527.—Transverse fracture of first metacarpal at the junction of the base and the shaft.
Fig. 528.—Oblique fracture of the shaft of the first metacarpal.

to the heads of the metacarpal bones that they become tense on flexion of the phalanges. The capsules of the joints are also reinforced by the accessory volar and the transverse capsular ligaments.

Surface Markings.—The metacarpal bones can be readily palpated throughout. The heads of the metacarpal bones form the first row of the knuckles.

Statistics.—Plagemann's statistics from Muller's clinic at Rostock shows that of 1393 fractures radiographically diagnosed there were 46 metacarpal fractures, divided as follows: first metacarpal, 9 times; second, 16 times; third, 9 times; fourth, 4 times; and fifth, 8 times.

Fig. 529.

Fig. 530.

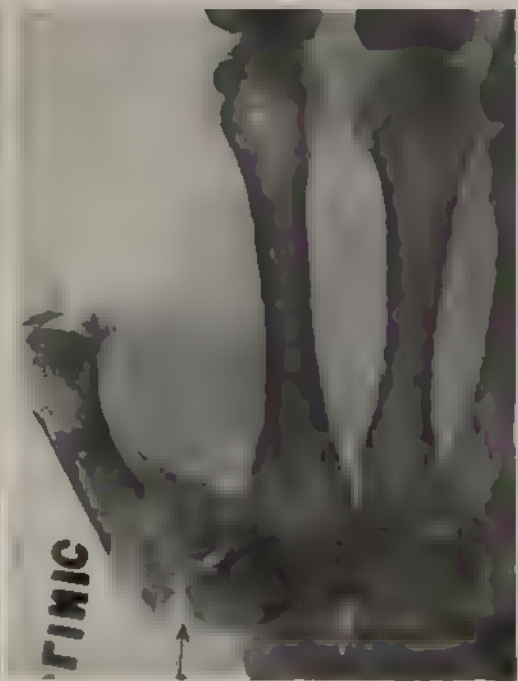

Fig. 531.

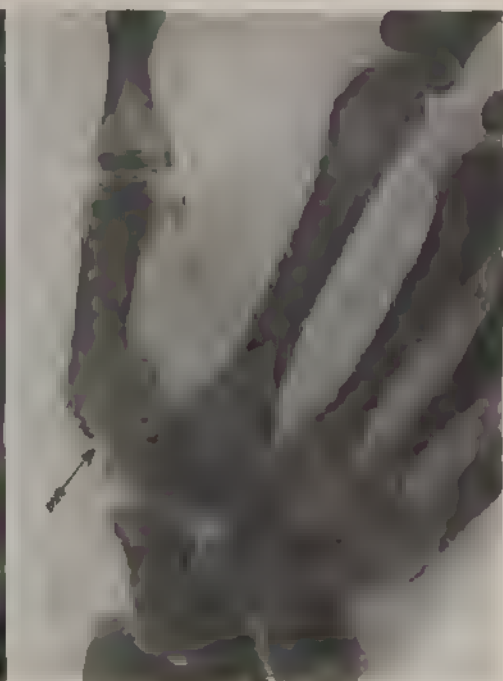

Figs. 529, 530, and 531.—Oblique fractures of the base of the first metacarpal involving the articular surface, the so-called 'stave of the thumb.'

His statistics also show that the case and the head are less frequently fractured than the shaft, with the exception of the first metacarpal,

Fig. 532.

Fig. 533

Figs. 532 and 533.—Separation of the epiphysis of the first metacarpal with a fracture of a portion of the diaphysis.

Fig. 534

Fig. 535.

Fig. 534.—Separation of the epiphysis of the second metacarpal. Note callus formation about separation.

Fig. 535.—Transverse fracture of shaft of fourth metacarpal.

and here there were in 9 cases 6 fractures of the base. In addition to the usual oblique and transverse fractures of the bodies of the meta-

FIG. 536.—Fracture of shafts of second, fourth and fifth metacarpals.
FIG. 537.—Comminuted fracture of the base of the fifth metacarpal.
FIG. 538.—Arrest of growth of fourth metacarpal following previous separation of its epiphyses.

carpals, there were in nine instances spiral fractures of the bodies, and in one instance he observed an epiphyseal separation of the head of the fourth metacarpal with an attached portion of the diaphysis.

Etiology.—Fracture of the metacarpals may be the result of either indirect or direct violence. Those by indirect violence are generally due to force applied upon the distal end of the bone in its long axis, such as occurs in the striking of a blow or in a fall upon the flexed hand. The normal arch of the bone is exaggerated, and fracture occurs. Fractures by direct violence are usually the result of a severe blow or crushing force on the back of the hand. Fractures are usually transverse or oblique, though occasionally spiral, fissured, or comminuted. The spiral fracture is most frequently observed involving



FIG. 542.—Method of determining crepitus and mobility of fragments in fracture of the metacarpals.

the fourth or fifth metacarpals. Here a twisting force, such as a fall upon the back of the hand or the fingers, produces the fracture.

Symptoms.—Fractures of the first metacarpal or, better called the first phalanx of the thumb, differ from those of the other four metacarpals to such an extent that they should be considered separately. Fractures of the shaft of this bone give the usual symptoms of fracture; these fractures are rare. The usual fracture of the first metacarpal involves the base of the bone, and here three varieties of fracture occur. The first variety (Figs. 527 and 528) is a transverse or irregular oblique fracture at the junction of the shaft and base not involving the articular surface, and is generally impacted. The second variety (Figs. 529–531) is the oblique fracture, the fracture line running upward and backward through the base of the metacarpal, the

FIG. 540.

FIG. 541.

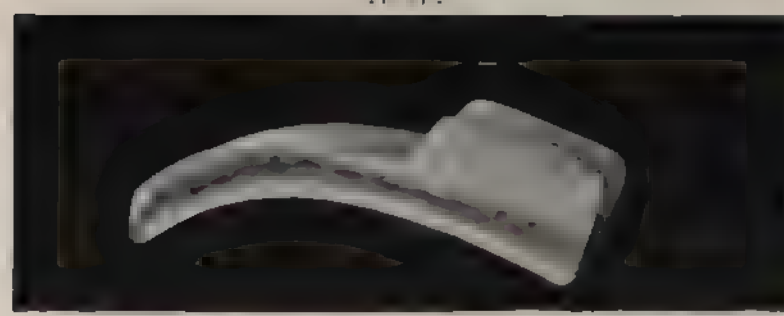

FIG. 542.



FIGS. 540, 541, AND 542.—Method of application of padded gutter aluminum splint for fractures of the first metacarpal.

so-called "stave of the thumb" or Bennett's fracture. The upper end of the lower fragment in this injury is displaced upward and

backward, and resembles a subluxation of the metacarpal plus crepitus. This fracture is always observed in adults. The third variety (Figs. 532 and 533) of fracture is an epiphyseal separation of the basal epiphysis with a fracture through a small portion of the diaphysis. The symptoms of all of these fractures are deformity, crepitus when impaction is absent, shortening of the thumb, and pain and tenderness on pressure.

FIG. 543.



FIG. 544.

FIG. 545.



FIGS. 543, 544 AND 545.—Method of application of padded posterior wood splint for fractures of the second to the fifth metacarpals.

Fractures of the other four metacarpal bones (Figs. 534–538) are readily recognized by deformity, localized pain and tenderness on pressure, at times crepitus, shortening of the affected bone, and irregularity of the knuckle's outline in the hand affected. An infallible sign of fracture is pain at the seat of fracture on making direct firm pressure over the knuckle in the longitudinal axis of the bone (Fig. 539). Pain will often be elicited by the surgeon making traction on the finger and then pushing the bones of the finger toward the wrist.

Diagnosis.—In doubtful fractures, particularly those at the base of the second, third, and fourth metacarpals, radiograms should be made to establish the diagnosis.

Treatment.—Impacted fractures of the base of the first metacarpal should be immobilized on a gutter splint of aluminum, or a moulded

Fig. 546



Fig. 547

Fig. 548

Figs. 546, 547 and 548.—Method of application of padded palmar splint for fracture of the second to fifth metacarpals, when a tendency to recurrence of deformity is not present.

gypsum splint, for three or four weeks; the impaction need not be interfered with unless deformity is great. In the other fractures of the first metacarpal, reduction should be made and maintained by the use of a gutter splint for three to four weeks (Figs. 540–542). Frac-

tures of the other four metacarpals should be treated by reduction, consisting of traction and manipulation, and the corrected position maintained by a well-padded posterior splint of wood, extending from the upper third of the forearm to the tip of the fingers (Figs. 543–545). Immobilization should be maintained for three to four weeks. It is frequently difficult to maintain proper apposition in oblique fractures of the shaft. When no deformity is present a palmar tin splint may be used (Figs. 546–548).

In fractures of the shafts of the last four metacarpals, recurrent angular deformity may be overcome by the use of the roller bandage placed in the palm of the hand with the fingers flexed over it and held in place by suitable dressing and a bandage. In some instances a hard ball of rubber or ivory or celluloid placed in the palm will probably answer the purpose better. When over-riding of fragments persists, permanent traction and counter-traction may be used. Satisfactory traction is readily made by fastening lateral strips of adhesive plaster to the finger and tying their distal ends over a tack driven into the end of a palmar splint of wood fixed to the forearm and extending beyond the finger-tips. To secure counter-traction the board should be cut narrow just above the thenar eminence, and be fixed to the wrist by a wristlet of adhesive plaster. The ends of the traction strap may be secured to the tack by a rubber cord. Another good method is to reduce the fracture and nail its fragments together with a brad-awl and a straight surgical needle or a carpet tack.

After-results.—The great majority of fractures of the metacarpals are followed by good functional results, even in the presence of moderate deformity. Epiphyseal separation of the metacarpals may be followed in later life by failure of development of the metacarpal and subsequent shortening with deformity.

CHAPTER XIX

FRACTURES OF THE PHALANGES

Anatomy.—There are three bones or phalanges to each of the fingers, and two to the thumb. They may be divided into the proximal or first row, the middle or second row, and the distal or third row. Like all long bones they may be divided into two extremities and a shaft. The interphalangeal articulations are formed by the bases forming the articular sockets, and the trochlear surfaces forming the articular heads. They are held together by lateral ligaments.

The lines of the interphalangeal joints may be determined by the position of the transverse furrows on the palmar surface of the fingers. The first furrow is midway between the metacarpophalangeal articulation and the joint between the first and second phalanx; the two remaining furrows represent the position of the interphalangeal joints. The distal ends of the first phalanges form the second, and the distal ends of the second phalanges form the third row of knuckles.

Statistics.—Plagemann's statistics from the Rostock clinic, based upon the radiographic examination of 1393 fractures, shows 75 (5.405 per cent.) fractures of the phalanges. Of these 42 were complicated and 33 subcutaneous fractures. Of the 75 only 59 were subsequently radiographically examined, and of these there were 19 fractures of the first phalanx, 19 of the second phalanx, and 25 of the distal phalanx. In the fractures of the distal phalanx 10 were comminuted. The most frequent were fractures of the index-finger, then the fifth finger, the third finger, the thumb, and the fourth finger.

Etiology.—Fractures of the phalanges (Figs. 549–553) are usually caused by direct violence, such as blows and machinery accidents, but occasionally are the result of indirect violence, such as a fall upon the tip of the extended finger or a blow as in catching a baseball. Fractures by direct violence may involve any portion of the bone, while those produced by indirect violence are more commonly noted as involving the base of the phalanges. Many of the fractures of the phalanges are compound, which is due usually to the nature of the injury and the subcutaneous character of the bones. Fracture of the phalanges may be fissured, multiple, comminuted, oblique, transverse and articular.

Symptoms.—The symptoms of fracture of the phalanges are localized pain, swelling, tenderness on pressure, deformity, abnormal mobility, crepitus, and widening at the seat of fracture with slight displacement. As many of these fractures are open, there is in addition direct evidence of the presence of the fracture.

FIG. 549.

FIG. 550.

FIG. 549.—Transverse fracture of proximal phalanx of thumb.
FIG. 550.—Comminuted fracture of proximal phalanx of fifth finger.

FIG. 551.

FIG. 552.

FIG. 551.—Articular fracture of base of middle phalanx of third finger. "Base ball" finger.
FIG. 552.—Articular fracture of head of middle phalanx of thumb. "Base ball" thumb.

Diagnosis.—Diagnosis of fracture of the phalanges can, as a rule, be readily made, even without the radiogram. Difficulty will at times be experienced in diagnosing articular fractures; here the use of the radiogram will materially help in diagnosis. However, in its absence a diagnosis may be made by widening of the bone, deformity, preter-natural mobility, and the tendency toward displacement which is present.

Treatment.—In the treatment of phalangeal fractures reduction is generally accomplished by traction and maintained by the use of a padded wood or tin or aluminum splint (Figs. 554–559) applied to the flexor surface of the palm of the hand and fingers and held in place by adhesive plaster and bandage. Gypsum encasements will often be better than wooden splints. In some cases deformity may be prevented by splinting the injured and the next finger together. In some fractures in which deformity is recurrent, it may be prevented by the use of a traction apparatus.

In open fractures the wound should be thoroughly sterilized with iodine or other antiseptic and closed, and then treated as a simple fracture. Necrosis of bone may

FIG. 553.—Separation of epiphysis of proximal phalanx of ring finger.

FIG. 554.

FIG. 555



FIG. 556



FIGS. 554, 555, AND 556.—Method of application of padded aluminum splint for fractures of phalanges of index finger.

Fig. 557.



Fig. 558

Fig. 559.

Figs. 557, 558 559.—Method of application of padded aluminum splint for fractures of phalanges of fingers

follow in some cases and the final result may be healing with loss of bony structure. Open and comminuted fractures should not be subjected to hasty amputation, because fingers may often be saved by plastic procedures. Denuded bones may be covered with tegumentary flaps from other fingers or parts of the hand. In some cases the stripped bones may be inserted into a space or pocket, made by an incision or incisions in the skin and superficial fascia of the patient's abdomen or thigh, and thus provided with cutaneous covering. In other instances free flaps may be transplanted to the hand and the denuded phalangeals may be subsequently modelled into useful fingers. These procedures are particularly valuable when the thumb is injured, for its opposing pressure against another part of the hand or even a stump of a finger gives the patient a grasp.

After-results.—Union occurs in closed fracture in three to four weeks. In articular fractures union may occur with ankylosis of the opposing joint surfaces. In open fracture healing may follow only after necrosis and loss of bony structure.

CHAPTER XX

FRACTURES OF THE PELVIS

Anatomy.—The pelvis (Figs. 560 and 561) is formed by the two innominate bones, the sacrum and the coccyx. The innominate bone in the adult consists of a single bone, formed by fusion of its three constituents—the ilium, ischium, and pubes. In childhood it consists of these three bones separated by a Y-shaped cartilage on the floor of the acetabulum. This ossifies and unites the segments about the fourteenth or fifteenth year of life. The innominate bone is irregular in form, shaped like the blade of a screw propeller. It is narrow near its centre where the acetabulum or socket for the head of the femur exists, and expanded above and below this region. The ilium is the largest of the three segments, forms about the upper third of the acetabulum, and consists of an expanded portion called the ala, and the body. The ischium is composed of a body and two rami, the superior and the inferior, which form the posterior and inferior boundary of the obturator foramen. Its body forms approximately the inferior two-fifths of the acetabulum, and terminates at its postero-inferior part in the tuberosity of the ischium. The pubic bone has a horizontal and a descending ramus and forms the anterior inferior portion of the innominate bone. It consists of a body articulating in the median line of the human trunk with the body of the opposite pubic bone and the two branches or rami mentioned above. The body forms the anterior part of the acetabulum, and the superior and inferior rami form the antero-inferior boundary of the obturator foramen. Where the os pubis joins that of the opposite side anteriorly, there is fibrocartilage forming part of the synchondrosis; this generally becomes ossified at puberty. The inferior ramus is separated from the inferior ramus of the ischium by cartilage which becomes ossified about puberty. Together these two rami form the lower border of the obturator foramen.

The ligaments of the pelvis are the following: pubic articulation, superior pubic ligament, inferior pubic ligament, anterior pubic, posterior pubic, and subpubic, and the interposed fibrocartilage; sacro-iliac articulation, the anterior sacro-iliac ligaments, the short posterior sacro-iliac ligaments, the long posterior sacro-iliac ligaments; the connection of sacrum with ischium is by the great or posterior sacrosciatic ligament, the small or anterior sacrosciatic ligament, and the interosseous sacrosciatic ligament. The ilium is joined to the fifth lumbar vertebra by the iliolumbar ligaments.

Surface Markings.—The ala of the iliac bone may be palpated laterally as well as the spine of the pubes anteriorly. Posteriorly may be felt the posterior superior iliac spines, which are on a level with the middle of the sacro-iliac joint, the two tubercles of the last sacral vertebra, the base and tip of coccyx, and the tuberosities of the ischia.

The bladder occupies the anterior part of the pelvis, situated between the pubic bones and the rectum in the male and between the pubic bones and the uterus and vagina in the female. In extraperitoneal rupture of the bladder extravasation of urine is limited by the reflection of peritoneum known as the posterior false and lateral false ligaments of the bladder.

Statistics.—Plagemann's statistics from Müller's clinic at Rostock, based upon the rontgenographic diagnosis of 1393 fractures, shows

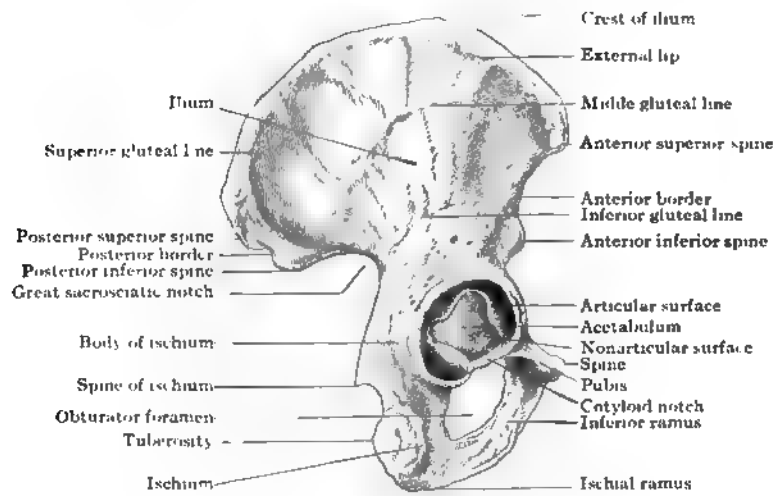

FIG. 560.—Right innominate bone, outer aspect. (Piersol.)

17 cases (1.22 per cent.) of fracture of the pelvis, divided as follows: pelvic girdle fractures, 6 cases; acetabulum fractures, 5 cases; isolated fractures of the pubes, 3 cases; and isolated fractures of the ilium, 3 cases. J. Jensen collected the records of four Copenhagen hospitals for five years, and found 80 cases of fracture of the pubes, shown by röntgenoscopy, operation, or necropsy. Of this number the 25 fatal cases showed that the trauma had more serious consequences at other points, excepting in three cases, in which the patients died as a result of complications of the fracture, and one, a child, who died as a direct result of the accident. In 6 cases the pubes alone was fractured and in 2 cases there were isolated fractures of the sacrum and ilium. In 55 clinical cases there was isolated fracture of the pubes in 22 instances, and pubic fracture associated with fracture of the ischium in

7 instances; isolated fracture of the acetabulum in 5 instances; isolated fractures of the ilium in 9 instances; and in 2 cases either the sacrum or the ischium alone was fractured. In 2 there was a double vertical fracture, in 6 fracture and dislocation, and in 2 dislocation alone. In 21 cases there were complications of the urinary system, including 5 with a fatal result. There was urinary retention in 16 cases, but in 5 cases of this group the urine was normal; dysuria in 2 cases; the urethra was ruptured in 3 cases, and the bladder in 3 cases—the latter all proved fatal.

Fractures of the pelvis, as a rule, require a great degree of violence for their production, although there are reported cases in which the fracturing force was slight. Pelvic fractures may be the result of direct or indirect violence, and rarely of muscular action. Falling

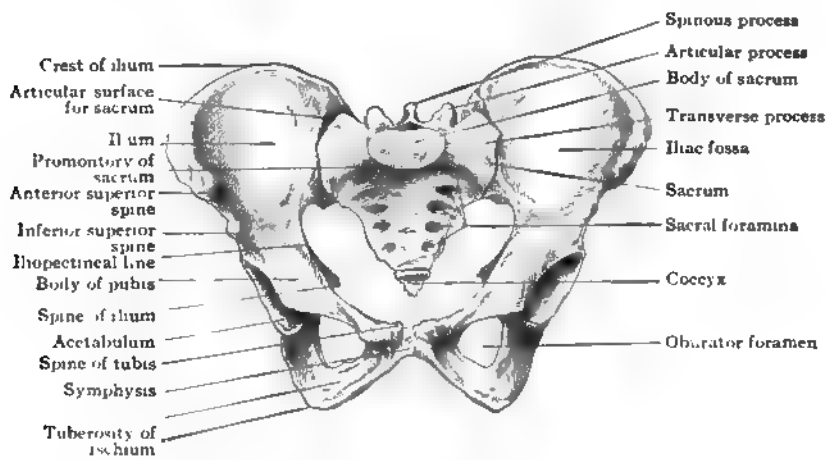

FIG. 561.—Male pelvis, anterior view.

embankments or elevator cars, the passage of vehicles across the pelvis, crushing force such as being caught between the bumpers of cars, blows, falls from a height, and very rarely sudden muscular strain, are the kinds of injuries which generally produce fracture of the pelvis. Transmitted force, such as falls upon the feet or trochanter, may produce these lesions. The fracture lines are usually multiple, rarely compound, and are dangerous to life on account of the damage to the pelvic contents which may result in conjunction with the fracture.

The character of fracture depends upon the direction of the fracturing force, and is usually limited to certain definite areas, except when the fracturing force is an extreme form of crushing. Fractures occur where the thin portions of the bone unite with the thicker portions, or where the pubic, iliac, and ischiatic elements of the bone before adult life are united by cartilage. The pelvis, as shown by Katzenelson, con-

Fig. 562.—Fracture of pelvis. Fracture involves the body and descending ramus of the right pubis, and the ascending and descending rami of the left pubis.



Fig. 563.—Fracture of the pelvis. Lines of fracture go through the junction of the superior and inferior rami of the right pubis and through the inferior ramus of the left pubis and inferior ramus of the left ischium. (Courtesy of Dr. P. G. Skillern, Jr.)

sists of two semicircles, each formed of an anterior and posterior arm, with the acetabulum as the summit. In the anterior arm the line of fracture occurs at the tuberosity of the pubes, the iliopectineal line, the ascending ramus of the ischium, and at the junction of the ascending ramus of the ischium with the descending ramus of the pubes. In the posterior arm the fracture line passes vertically from the pelvic

FIG. 564.—Fracture of the pelvis. The anterior lines of fracture involve the body and descending rami of the pubis, and the posterior line passes vertically through the ilium behind the acetabulum close to the sacro-iliac synchrondrosis, the so-called "double vertical fracture" of Malgaigne.

bone down through the greater sciatic notch of the ilium, through the lateral masses of the sacrum, irregularly diagonal through a portion of the ilium and sacrum, and through the sacro-iliac synchondrosis.

Varieties.—Fractures of the pelvis may be classified:

FRACTURES OF THE RAMI OF THE PUBES (Figs. 562 and 563) occur from direct violence directed from in front either posteriorly or

laterally and are the most common form of fracture. The line of fracture passes, as a rule, through the superior ramus of the pubes anterior to the iliopectineal eminence and through the inferior ramus of the pubes. At times the latter line is very oblique and passes through the inferior ramus of the ischium. There may or may not be an accompanying separation of the sacro-iliac synchondrosis. Displacement of the fragments may be marked.

Fracture of the Rami with Fracture of the Posterior Arm of the Pelvic Arch (Figs. 564 and 565).—In this fracture the

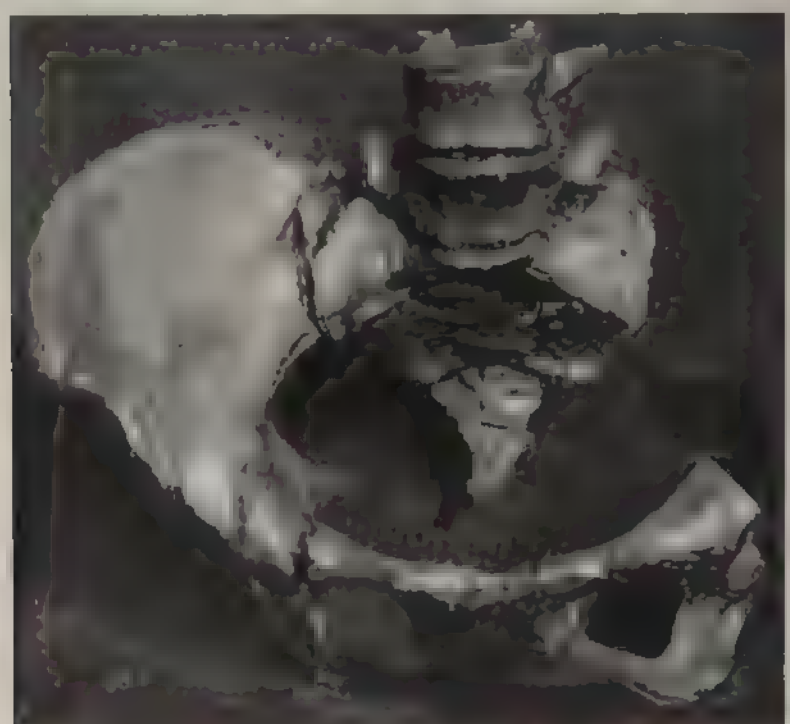

Fig. 565.—Pelvis with fourth and fifth lumbar vertebræ. Fracture of the symphysis, body and ramus of the pubes, of the ramus of the ischium with the sacro-iliac separation and fracture of the fourth body of the sacrum. (Mutter Museum, 1782.0.)

anterior fracture line passes through the superior ramus of the pubes or the ramus of the ischium, and the posterior part of the fracture line passes vertically through the ilium behind the acetabulum, or through the sacrum, or partially through the ilium, the sacrum, and the sacro-iliac synchondrosis. It has been called the double vertical fracture of Malgaigne. The injury occurs from anteroposterior or lateral crushing. Marked displacement of the middle fragment often results. This fragment, consisting of the acetabulum with the attached head of the femur, is generally displaced upward with the leg; and it may rotate

around a vertical or horizontal axis, so that the shape of the pelvis is altered and the extremity of the involved side apparently shortened.

SEPARATION OF THE SYMPHYSIS PUBIS (Fig. 566) occurs between one of the pubic bones and its attached cartilage, rather than between the two cartilages which belong to the joint. This separation may be the result of parturition, forced abduction of the thighs, or by direct external violence. The gap between the two bones may be several inches in width; occasionally the fracture is an open one.

SEPARATION OF THE SACRO-ILIAC SYNCHONDROSIS (Fig. 567) is extremely rare. Cases have been reported by Malgaigne and by Stimson. It is truly a dislocation. Much has recently been written on partial luxation here being frequent and causing painful backs. Dr. Goldthwaite, of Boston, has given this injury great attention.

FIG. 566.—Fracture of the pelvis. The line of fracture involves the body and the symphysis of the pubis with separation of the synchrondrosis of the latter.

SEPARATION OF THE SYMPHYSIS PUBIS AND THE SACRO-ILIAC SYNCHONDROSIS has been observed by Malgaigne, Earle, Crette and Salleron. In the reported cases the injury occurred through a fall from a height upon one foot, or from the pressure of a heavy weight upon the pelvis. Displacement consisted in elevation of the affected half of the pelvis.

SEPARATION OF THE SYMPHYSIS PUBIS AND OF BOTH SACRO-ILIAC SYNCHONDROSES is extremely rare. The few reported cases were



FIG. 567.—Pelvis: fracture of the sacrum and left innominate. The first and second sacral vertebræ are crushed and the body of the pubes and ramus of the ischium are fractured. (Mütter Museum, No. 1467.)

FIG. 568.—Fracture of the floor of the acetabulum with central dislocation of the head of the right femur into the pelvic cavity and partial separation of the pubic symphysis. The greater trochanter is in close relation to the upper rim of the acetabulum. (Case of Dr. W. T. Ellis.)

accompanied by multiple fractures of the pelvis and were the result of extreme violence.

FRACTURES OF THE ACETABULUM (Figs. 568-575) may occur as a radiating fracture in the direction of the conjugal Y-cartilage seen in

FIGS. 569, 570, AND 571.—Photographs of case of fracture of the floor of the acetabulum with central dislocation of the head of the femur. See Fig. 568. Lateral view shows absence of normal prominence of greater trochanter. Anterior view shows tilting of pelvis with shortening of the distance between the anterior superior spine of the ilium and the greater trochanter, and the posterior view shows spinal curvature and flattening of gluteal crease on the right side.

adolescence, in which the fracture line runs into the sciatic notch, the obturator foramen, and over the brim of the pelvis. Other forms of fracture are those associated with fracture through the rami of the pubes and are irregular in character, those involving the rim of the acetabulum in association with partial dislocation of the head of

femur, and those in which there is fracture of the acetabulum with incomplete or complete penetration of the head of the femur through it into the pelvic cavity, the so-called central luxation of the femur. These fractures are usually the result of great violence applied directly over the side of the pelvis and great trochanter or over the external and upper surface of the thigh with the thigh in the position of marked abduction.



FIG. 572.—Fracture of the pelvis. An incomplete form of the so-called "central dislocation of the head of the femur." The line of fracture involves the floor of the acetabulum and extends posteriorly into the great sacrosciatic notch.

ISOLATED FRACTURES OF THE SACRUM are rare and the lesion most frequently reported is a more or less transverse fracture below the sacro-iliac synchondrosis with displacement of the lower fragment into the pelvis. This fracture results from great direct violence applied from behind or from a fall upon the sacrum.

ISOLATED FRACTURES OF THE ILIUM (Figs. 576–579) may consist of a fracture of the expanded portion close to the linea arcuata, in which the line is irregular and more or less transverse, the so-called Duverney fracture, or a fracture of the epiphysis of the crest. Com-

minuted fractures are also seen. These fractures are generally the result of direct violence applied from the lateral aspect; although a case has been reported by Hamilton, in which there was a tearing off of a part of the crest and the anterior superior spine, and one by Cotton in which the anterior superior spine alone was t orn off, the result of muscular action. Other cases have been reported by various authors, all of which occurred in young subjects and were in all probability due

FIG. 573.—Fracture of the pelvis. Incomplete central luxation of the head of the femur due to fracture of the acetabulum. Note the line of fracture extending through the floor of the acetabulum, with central displacement of the floor of the acetabulum and of the head of the femur. Lessening of the distance between the superior rim of the acetabulum and the inner surface of the great trochanter of the femur.

to the action of the sartorius muscle, generally occurring during running.

ISOLATED FRACTURE OF THE ISCHIUM is rare. Few cases have been reported. The lesion consists in a fracture of the entire ischium in some cases, while in others only the tuberosity is fractured. They are usually the result of a fall upon the buttocks.



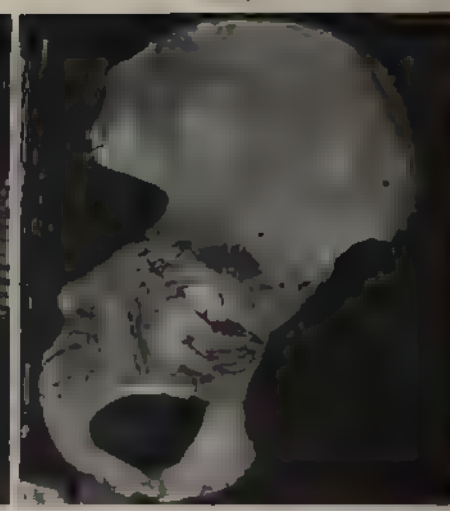

FIG. 574.—Portion of left innominate bone. Multiple fracture recent. All the fractures communicate with the obturator foramen. The ramus of the ischium is fractured in its transverse diameter at the lowest portion of the obturator foramen. The ramus of the pubes is fractured in a line running from the angle downward and to the left. The acetabulum is fractured vertically, line runs from the ilio-pectineal groove to the cotyloid notch. (Mütter Museum, No. 1382.)

FIG. 575.—Right innominate. Fracture of the acetabulum and pubes. (Mütter Museum, No. 1382-4.)

FIG. 576.—Irregular fracture of ala of ilium. The line of fracture runs downward from the crest of the ilium to the superior rim of the acetabulum. Direct violence.

Isolated fractures of the coccyx are the result of a fall upon the buttocks, or a kick, or during parturition. Bony union of the coccyx with the sacrum occurs in late adult life in many cases, so that fracture at that point is possible. Many so-called cases are undoubtedly coccyodynia and partial dislocation.

Symptoms.—Fractures of the pelvis as a rule are not accompanied by considerable displacement of fragments. Shock is a prominent symptom of fractures involving the ring of the pelvis, not so much

Fig. 577.—Fracture of the anterior superior spine of the ilium. Direct violence.

on account of the fracture itself as on account of the great force usually requisite in the production of these injuries, and because of the intrapelvic injuries and associated lesions. Displacement of fragments varies with the variety of fracture. In fractures of the rami, separation of small portions of bone, as of the crest of the ilium, and tuberosity of the ischium, deformity is not evident on inspection. Fracture anteriorly with displacement inward is evident on inspection. In the double vertical fracture of Malgaigne, there is usually marked dis-

placement upward of the middle portion, including the hip, and the anterior superior spine and crest of the ilium are carried upward and outward. This is readily recognized on inspection. In transverse fracture of the ilium, inspection shows displacement upward with apparent lengthening of the leg. Transverse fracture of the sacrum may be recognized by the presence of a ridge at the seat of fracture. Fracture of the upper and posterior arm of the acetabulum simulates pos-

FIG. 578.—Normal epiphyseal line of the crest of the ilium. This epiphysis unites with the diaphysis about the twenty-first year. The line of the epiphyseal cartilage has often been mistaken for a fracture.

terior dislocation of the hip, while fracture of the acetabulum with penetration of the head through the acetabulum into the pelvic cavity shows loss of the normal prominence of the trochanter, shortening of the leg, relaxation of the fascia lata, and approximation of the great trochanter to the acetabular rim, and to the symphysis pubis (Fig. 580). Fracture of the anterior superior spine may also at times be recognized on inspection. Separation at the symphysis pubis shows

broadening of the trochanters, with evidence of bulging at the symphysis.

Of chief importance as symptoms of fracture are the facts derived from careful palpation. Palpation should be carefully made in all cases. By this means abnormal mobility, crepitus, localized pain and tenderness may be elicited. Individual bones may be palpated by studying the uninjured side of the pelvis with one hand and with the other carefully going over the external aspects of the bone in the region of the suspected fracture. Lateral compression of the pelvis in the region of the crests of the ilia or of the trochanters will demon-



FIG. 579.—Left innominate, old fracture, exostosis. It has been doubtless an old fracture of the crest of the ilium. On both sides of the seat of fracture, especially the outer, there are exostoses. There is also an exostosis of the pubis. (Mütter Museum, No. 1382.50.)

strate many fractures (Fig. 581). Pressure directed upward in the line of the thigh with the hip and knee flexed will often produce pain and at times crepitus and abnormal mobility (Fig. 582). Palpation through the rectum or vagina may demonstrate irregularities of outline and abnormal position of fragments, and elicit pain and crepitus. Examination by these routes enables the surgeon to palpate the posterior wall of the symphysis and rami of the pubes, the acetabulum, the arcuate line, the ascending ramus of the ischium, the sciatic notch, and posteriorly the coccyx and the promontory and upper portion of the sacrum.

Of the subjective symptoms of fracture, there may be mentioned

pain, accentuated on pressure or movement, tenderness, inability to move the leg at times or to bear weight on the injured side, ecchymosis, and disturbed function. Inability to flex the leg may be due to nerve injury, to infiltration of the psoas muscle with blood, or to splintering and puncture of the muscle by sharp fragments of bone. This

FIG. 580.

FIG. 580.—Method of measuring the distance from the median line of the abdomen to both trochanters to determine inward displacement of the trochanter in fracture of the acetabulum with dislocation of the head of the femur into the pelvic cavity.

FIG. 581.



FIG. 581.—Method of lateral compression to determine crepitus and mobility in suspected fracture of the pelvis.

FIG. 582.

FIG. 582.—Method of determining crepitus and mobility in suspected fracture of the rim of the acetabulum or in Malgaigne's double fracture of the pelvis.

movement may also be impaired because the head of the femur will not stay in its normal position and has lost its point of purchase, as in fractures of the acetabulum. Walking is difficult and in most cases impossible on account of the pain and inability of the leg to properly support the weight of the body transmitted through the pelvis.

Areas of ecchymosis above Poupart's ligament are diagnostic of fracture of the pelvis and distinguish them from fractures of the neck of the femur, in which the ecchymosis is below the ligament. Later ecchymosis appears in the region of the scrotum, perineum, hip and sacrum, depending upon the site of fracture.

In separation of the symphysis pubis there may be a palpable sulcus or furrow between the two innominate bones. In addition there is localized pain, tenderness on pressure, local ecchymosis, and abnormal movement on alternate rocking of the two sides of the pelvis, and especially on forced abduction of the thigh.

Of particular interest are the fractures of the acetabulum associated with penetration of the fragments by the head of the femur into the pelvic cavity. The characteristic symptoms are apparent shortening of the leg, loss of prominence of the trochanter major, loss of tension of the fascia lata, outward rotation of the thigh with loss of motion, and the presence on rectal or vaginal examination of the fractured acetabular floor and prominence of the head of the femur in the pelvic cavity.

Fractures of the rim of the acetabulum simulate dislocation of the head of the femur, the usual lesion being a breaking off of the posterior and upper edge of the joint socket. The symptoms are those of dislocation of the head of the femur with crepitus, and a tendency toward recurrence of the dislocation after reduction. In this fracture, however, the limb assumes a position of outward rotation and extension at the hip-joint, while in posterior dislocation of the head of the femur the limb lies in inward rotation with flexion at the hip; and in fracture the trochanter is relatively nearer the anterior superior spine of the ilium than it is in this dislocation.

Fractures of the crest of the ilium or its anterior superior spine are readily recognized by the abnormal displacement and mobility of fragments, and the situation of pain,tenderness, ecchymosis and crepitus.

Complications.—Any real gravity of fractures of the pelvis is due, not to the damage done to pelvic bones themselves but to any injury to the pelvic contents, which so frequently accompanies these fractures. The chief complications of pelvic fractures are injury to the bladder and urethra, the rectum, the vagina, the iliac vessels, the vesical and pudendal vessels, the sacral nerves and the intestines.

Lesions of the bladder may be the result of the force producing the fracture of the pelvis, particularly if urine distends the bladder, or may be due to puncture by sharp fragments of bone. When rupture of the bladder is due to direct force and is accompanied by fracture of the pelvis, the bony lesion will usually be found in the pubic rami, to be separation of the symphysis pubis, or occasionally in the sacrum or the acetabulum. Primary ruptures of the bladder are generally intraperi-

Diagnosis of intraperitoneal rupture of the bladder is frequently not made until too late to save the life of the patient.

In a careful survey of the symptoms presented in suspected rupture of the urethra or bladder, one should bear in mind that dysuria or anuria may result from contusion of the abdominal wall or severe concussion of the pelvis, producing paralysis of detrusor vesicæ muscle.

Prognosis.—The prognosis of fracture of the pelvis depends to a great degree upon the site of fracture and the presence or absence of injury to the pelvic contents. In uncomplicated fractures the prognosis is always favorable so far as life is concerned. There is required in ordinary cases from six to eight weeks for union to take place, although the patient usually is incapacitated for a considerable time, depending to a great degree upon the region of fracture. Fractures involving the acetabulum, double vertical fractures of the pelvis, fractures of the sacrum, and those in the region of the sacro-iliac joint, as a rule, require a long time before convalescence is complete; and in many instances the working power of the individual is permanently diminished. In fractures of the acetabulum, permanent disability is often likely on account of immediate limitation of the range of the hip-joint and the possibility of the future development of arthritic changes due to excessive callus. In fractures about the sacro-iliac joint, convalescence may be prolonged several years due to nerve pressure from fragments and callus. Coccyodynia is a usual sequel of fracture of the coccyx.

Fractures of the pelvis with permanent displacement of fragments may, in the female, be followed by difficult labor in subsequent childbirths.

The most frequent complications of fracture of the pelvis are injuries to the bladder and urethra. When present they greatly diminish the likelihood of a favorable prognosis. Intraperitoneal rupture of the bladder is followed by a septic peritonitis, unless prompt laparotomy is performed. Extraperitoneal rupture of the bladder or rupture of the urethra is followed by urinary extravasation, and unless immediate repair is done, necrosis and suppuration of the soft parts occur. When perineal section is done for rupture of the urethra, there may be persistent urinary fistula or stricture resulting. Dr. Roberts has seen death from perforation of a duodenal ulcer secondary to pelvic suppuration in front of the bladder after fracture of the pelvis with cystic laceration.

Injury to blood-vessels may result in rapid and fatal hemorrhage or in subperitoneal hæmatoma, depending upon the vessel injured and whether the peritoneum is also torn. Aneurism of the injured vessel may develop.

Injury to nerves may be followed by persistent motor paralysis, anæsthesia, or neuralgia.

in addition there is trickling of blood from the meatus before catheterization and afterward, the evidence points to incomplete rupture of the urethra.

In extraperitoneal rupture of the bladder, there will be no difficulty in introducing the catheter into the bladder, but catheterization will show bloody urine. In intraperitoneal rupture, catheterization of the bladder will produce at first only a very small amount of bloody urine or at times only blood. Upon further introduction an elastic resistance will be felt which is the collapsed bladder wall. Possibly by deft

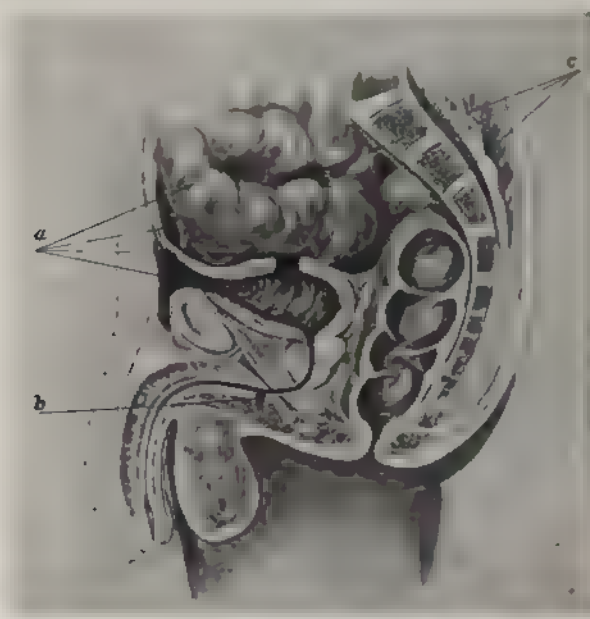

FIG. 583.—Drawing to show rupture of bladder and urethra complicating fracture of the pelvis. *A*—extra- and intra-peritoneal rupture of the bladder with extravasation of blood into space of Retzius and between coils of intestine at *C*. *B* rupture of the urethra anterior to the triangular ligament will give extravasation of blood and urine into penis, scrotum and superficial abdominal tissues as shown by dotted line.

manipulation the tip of the catheter may be introduced into the opening into the peritoneal cavity, when blood and urine will be obtained, if sufficient time has elapsed since the injury for their accumulation. This latter procedure is not advocated.

After twenty-four hours additional symptoms will be present. In rupture of the bulbous portion of the urethra there will be possibly swelling of the scrotum and penis due to urinary extravasation; infiltration above the symphysis and into the groins, and dulness of the lower part of the abdomen are indicative either of rupture of the urethra posterior to the triangular ligament or of extraperitoneal rupture of the bladder. In intraperitoneal rupture of the bladder there will be the symptoms of a rapidly increasing and severe type of peritonitis.

Diagnosis of intraperitoneal rupture of the bladder is frequently not made until too late to save the life of the patient.

In a careful survey of the symptoms presented in suspected rupture of the urethra or bladder, one should bear in mind that dysuria or anuria may result from contusion of the abdominal wall or severe concussion of the pelvis, producing paralysis of detrusor vesicæ muscle.

Prognosis.—The prognosis of fracture of the pelvis depends to a great degree upon the site of fracture and the presence or absence of injury to the pelvic contents. In uncomplicated fractures the prognosis is always favorable so far as life is concerned. There is required in ordinary cases from six to eight weeks for union to take place, although the patient usually is incapacitated for a considerable time, depending to a great degree upon the region of fracture. Fractures involving the acetabulum, double vertical fractures of the pelvis, fractures of the sacrum, and those in the region of the sacro-iliac joint, as a rule, require a long time before convalescence is complete; and in many instances the working power of the individual is permanently diminished. In fractures of the acetabulum, permanent disability is often likely on account of immediate limitation of the range of the hip-joint and the possibility of the future development of arthritic changes due to excessive callus. In fractures about the sacro-iliac joint, convalescence may be prolonged several years due to nerve pressure from fragments and callus. Coccyodynia is a usual sequel of fracture of the coccyx.

Fractures of the pelvis with permanent displacement of fragments may, in the female, be followed by difficult labor in subsequent childbirths.

The most frequent complications of fracture of the pelvis are injuries to the bladder and urethra. When present they greatly diminish the likelihood of a favorable prognosis. Intraperitoneal rupture of the bladder is followed by a septic peritonitis, unless prompt laparotomy is performed. Extraperitoneal rupture of the bladder or rupture of the urethra is followed by urinary extravasation, and unless immediate repair is done, necrosis and suppuration of the soft parts occur. When perineal section is done for rupture of the urethra, there may be persistent urinary fistula or stricture resulting. Dr. Roberts has seen death from perforation of a duodenal ulcer secondary to pelvic suppuration in front of the bladder after fracture of the pelvis with cystic laceration.

Injury to blood-vessels may result in rapid and fatal hemorrhage or in subperitoneal hæmatoma, depending upon the vessel injured and whether the peritoneum is also torn. Aneurism of the injured vessel may develop.

Injury to nerves may be followed by persistent motor paralysis, anæsthesia, or neuralgia.

Treatment.—The treatment of fractures of the pelvic bones consists of reduction of fragments when possible, maintenance of fragments in their normal position until union occurs, and the treatment of attendant shock and of the complications present.

In reduction of displaced fragments, violent manipulations should be avoided, as they tend to increase shock and at times increase the extent of visceral injury. Careful manipulations, made through the rectum or vagina, aided by traction applied to the leg and thigh, may reduce displaced fragments of bone. In fractures of the rim of the acetabulum, double vertical fractures involving the entire pelvic rim, and in fractures of the acetabulum, with perforation of the head of the femur through the acetabulum into the pelvis, reduction should be first accomplished; then the foot of the bed should be elevated for counter-traction and a Buck traction apparatus applied to the leg and thigh with sufficient weights (15 to 20 lb.) to maintain reduction. In fractures of the rami of the pubes or ischium, of the sacrum, in fractures in the region of the sacro-iliac synchondrosis, and in separations of the symphysis pubis, the patient should be placed flat on the back, with knees and thighs partially flexed by a pillow under the knees, and support to the pelvis be made by encircling bands of firm muslin or adhesive plaster strapping (Figs. 584 and 585). In some instances immobilization may best be maintained by the use of a gypsum case applied around the entire pelvis, from a point above the crest of the ilium to below the trochanters. In some cases reduction of fragments may be further accomplished by the use of packing in the rectum, or vaginal packing in women. This rectal support, however, should be carefully applied, and changed at least every other day; the packing should have in its centre a rubber tube to facilitate the escape of flatus.

In fractures of the crest of the ilium the encircling bandage should not be used, as it tends to increase the deformity. Support in this form of fracture is best obtained by the use of properly applied sand-bags. In perforating fractures of the acetabulum, with the head of the femur in the pelvic cavity, lateral traction outward on the upper part of the thigh should be used in addition to counter-traction and the Buck traction apparatus. Fractures of the anterior superior spine of the ilium are best treated by flexion of the hip and leg and the use of an encircling gypsum case. The separation fragment may be held in position by subcutaneous nailing with a wire nail or screw. Fractures of the tuberosity of the ischium should be treated by flexion of the leg on the thigh and by extension of the thigh at the hip so as to relax the ham-string muscles. Fractures of the coccyx are best treated by excision of the coccyx.

When intraperitoneal or extraperitoneal rupture of the bladder is present, exploratory laparotomy should be performed. In intraperi-

toneal rupture a vertical incision should be made in the median line through the abdominal wall, the pelvic cavity cleansed with moist sponges, and the rent in the bladder closed by two layers of interrupted Lembert sutures, the inner layer being of chromic catgut, the outer layer of silk. The abdominal wound should then be closed with a cigarette drain placed in the pelvic cul-de-sac. Catheterization should be performed every eight hours afterward for at least ten days. In extraperitoneal rupture, exposure is best obtained by a transverse suprapubic incision, and the tear when found should be closed in the same manner as described above for intraperitoneal rupture. The after-treatment should be the same

FIG. 584

FIG. 584.—Application of circular adhesive plaster swathe in fracture of the pelvis. Protection of the supra-pubic hair space by a layer of sheet wadding.

FIG. 585

FIG. 585.—Completed adhesive plaster swathe for fracture of the pelvis.

To obtain success in the presence of these two complications, operative interference should be performed within the first twenty-four hours. In rupture of the urethra, perineal section should be done as soon as shock has disappeared. The proximal end of the torn urethra should be sought for, and when found a male catheter should be passed through the urethra from the external meatus to the bladder. When possible the two torn portions of the urethra should be united by chromic catgut and the perineal wound packed. Otherwise a free exit should be left for drainage of urine through the perineal wound. When the proximal end cannot be found a suprapubic cystotomy should be performed and retrograde catheterization done. The catheter should be maintained in the urethra for ten days to two weeks, and after this time careful dilatation with sounds should be made to prevent the occurrence of stricture in the urethra.

CHAPTER XXI

FRACTURES OF THE FEMUR

Anatomy.—The femur (Fig. 586) is the largest of the long bones. It articulates with the innominate bone above and the tibia below. It consists of an upper extremity, a shaft, and a lower extremity.

The upper extremity is divided into the head, the neck, and the greater and lesser trochanters. The head extends inward and upward, surmounting the neck, and consists of about two-thirds of a sphere. It is covered with fibrocartilage, excepting at the attachment of the ligamentum teres just below and to the inner side of its centre. The neck, shaped like an oblique truncated cylinder, is the constricted portion between the head and the shaft, and forms an obtuse angle with the shaft of about 120 degrees in the adult. This varies during life from 160 degrees at birth to 110 degrees later in life. The great trochanter is the upper external portion of the shaft of the femur at its junction with the neck. The small trochanter is a projection at the junction of the inner and posterior surface of the shaft of the femur opposite the great trochanter. Between the two trochanters anteriorly runs a ridge called the intertrochanteric line, and posteriorly a more marked ridge termed the intertrochanteric ridge.

There are separate epiphyseal centres for the head and the greater and the less trochanters, while the condyles have a common epiphysis. The time for union for the great trochanter is the eighteenth year. for the small trochanter the seventeenth year, and for the head the eighteenth year. The condylar epiphysis unites with the shaft about the eighteenth or twentieth year. The femur bears the entire weight of the body in the upright position. The weakest portion of the bone, because of its structure and position, is the neck. This, however, is specially strengthened, not only by its shape, but also by the lateral construction of the spongy structure, which is arranged with trabeculæ to bear pressure and tension in the definite lines needed. The head receives its blood supply through an artery in the round ligament and through the circulation in the cancellated structure.

In later years the vessels in the ligament disappear almost entirely, so that the nutrition of the head is dependent upon the blood supply from the spongy tissue of the neck.

The shaft of the femur is arched convexly anteriorly, is nearly cylindrical, and toward its lower end, becoming broader, presents a three-sided prism with three surfaces, two lateral and one ventral. Posteriorly is seen the longitudinal linea aspera, formed by the junction

of the spiral line and gluteal ridge; below, the linea aspera divides into internal and external condylar ridges.

The lower extremity of the femur is broad and consists of the two masses of bone, the internal and the external condyles. These are more prominent posteriorly and are separated by the deep intercondylar notch, while anteriorly they are united by the trochlear or articular surface of the patella. Upon the condyles on each side there is a

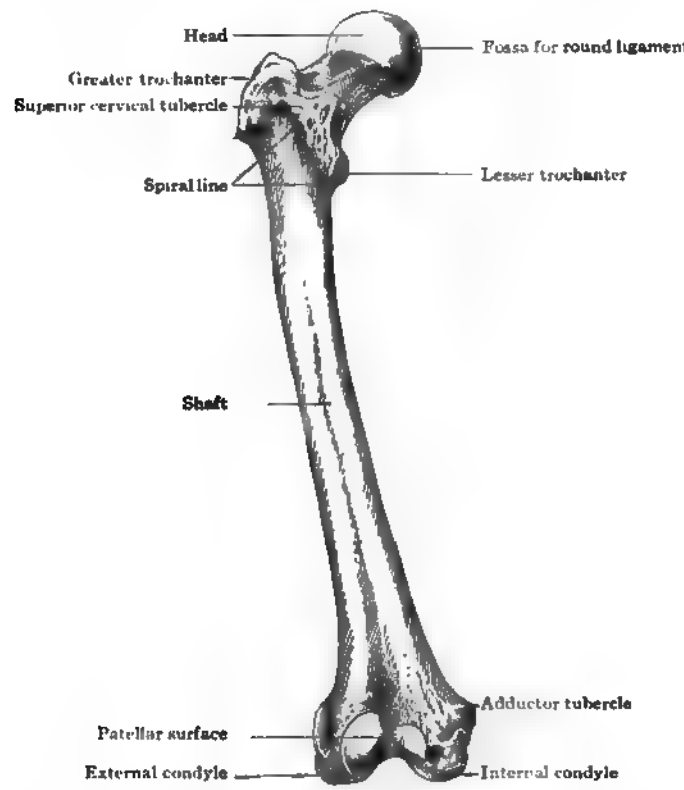

FIG. 586.—Right femur, anterior view.

prominence on the lateral surface, the internal epicondyle and the external epicondyle.

The hip-joint is the articulation between the acetabulum and the upper end of the femur. Its ligaments consist of the glenoidal or cotyloid ligament, which is a circular fibrocartilage deepening the acetabular cavity, the round ligament or ligamentum teres inserted in the head of the femur, and the capsular ligament attached to the outer surface of the glenoid ligament, which surrounds the neck of the femur, excepting a small part posteriorly. In addition are the three accessory ligaments, the iliofemoral or the inverted Y or Bigelow liga-

ment, which strengthens the capsule, the pubocapsular, and the ischiocapsular ligaments. The knee-joint is the articulation between the condylar surface of the femur and the tuberosities of the tibia below and the trochlear surface of the condyles and the posterior surface of the patella in front. Upon the upper articular facets of the tibia are two menisci, called the internal and external semilunar fibrocartilages.

The ligaments of the knee-joint are: the internal lateral ligament, the external lateral ligaments, the posterior ligaments, the ligament of the patella, the capsular ligament, the synovial or alar ligaments, the anterior crucial ligament, and the posterior crucial ligament.

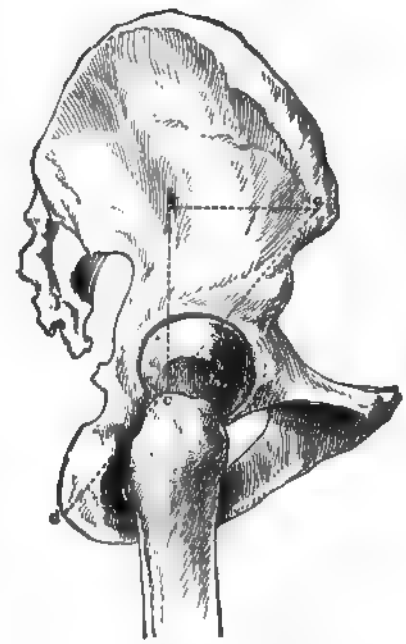

FIG. 587.—View of outer surface of the bones of the hip showing Roser-Nélaton line (*a-d*); Bryant's triangle (*abc*), ilio-trochanteric line (*a-c*) and the ilio-trochanteric angle (*bac*)." (Davis.)

Surface Markings.—The principal landmarks to be remembered in fractures of the femur are the anterior spine of the ilium, the spine of the pubes, the tuberosity of the ischium, the great trochanter of the femur, the umbilicus, the patella and the internal malleolus. These points are of value in determining shortening of the bones of the thigh and leg. On the outside of the thigh about four inches below and posterior to the anterior superior spine of the ilium will be found a marked prominence, just below a depression; it is the great trochanter of the femur. The relations of this trochanter to other landmarks are of great importance, for they determine to a great extent the presence of fracture and luxation.

A number of aids are in use for determining the existence of fracture of the neck of the femur. The most important of these are the relation of the trochanter of the injured limb to the Roser-Nélaton line and the Bryant triangle. These topographical markings are used particularly in determining the presence or absence of elevation of the great trochanter on the injured side. The Roser-Nélaton line (Figs. 587 and 588) is a line drawn from the anterior superior spine of the ilium to the tip of the tuberosity of the ischium. Normally the upper border of the great trochanter should touch this line, and this relation is not disturbed by flexion and extension of the thigh. Comparison of the two sides will usually show a displacement upward of the trochanter

in fracture of the neck of the femur. The two sides must be examined with the two limbs perfectly parallel to each other and at right angle to a line drawn across the top of the pelvis, either at the level of the crests of the ilia or from one anterior superior spinous process to the other (Fig. 589). Abduction or adduction of either side will alter the

FIG. 588. Outer surface of right hip and thigh showing Roser-Nelaton and Bryant's triangl

results and render the test valueless. Bryant's triangle (Figs. 587 and 588) is formed by dropping vertically a line from the anterior superior spine of the ilium to the bed or table on which the patient lies supine; a second line is drawn at right angle to this line, running in the axis of the thigh to the great trochanter to this primary line, and a third line

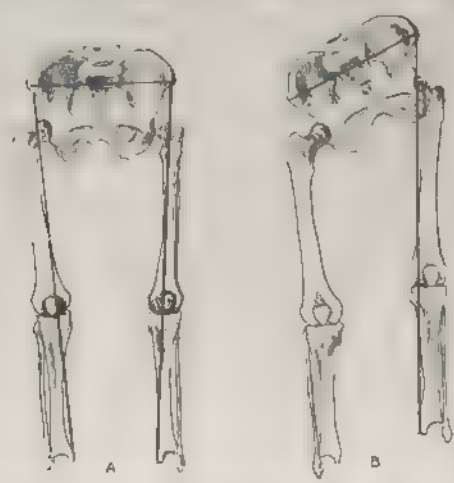

FIG. 589. In making measurements from the anterior superior spine of the ilium to the internal malleolus to determine shortening on the injured side, the two lower limbs should be parallel to each other and at right angles to a line drawn through the anterior superior spines, as in *A*. If tilting of the pelvis is present as in *B* incorrect conclusions will be made

is drawn from the anterior superior spine of the ilium to the great trochanter, thus forming a triangle. In fractures of the neck of the femur the second line is found to be shortened in comparison with that of the sound side (Fig. 509).

Relaxation of the fascia lata as a test or proof of shortening due

to fracture of the femur was first suggested by Allis. This relaxation is best observed between the crests of the ilium and the great trochanter, and also above the outer condyle of the femur (Fig. 591).

Another measurement used to determine shortening of the leg from fracture of the femur is that between the anterior superior spine of the ilium and the internal malleolus (Fig. 592). Comparison with the sound side will determine the presence of shortening in fractures of the femur or of the bones of the leg (Fig. 593). Measurement between the anterior spine of the ilium and the adductor tubercle is at

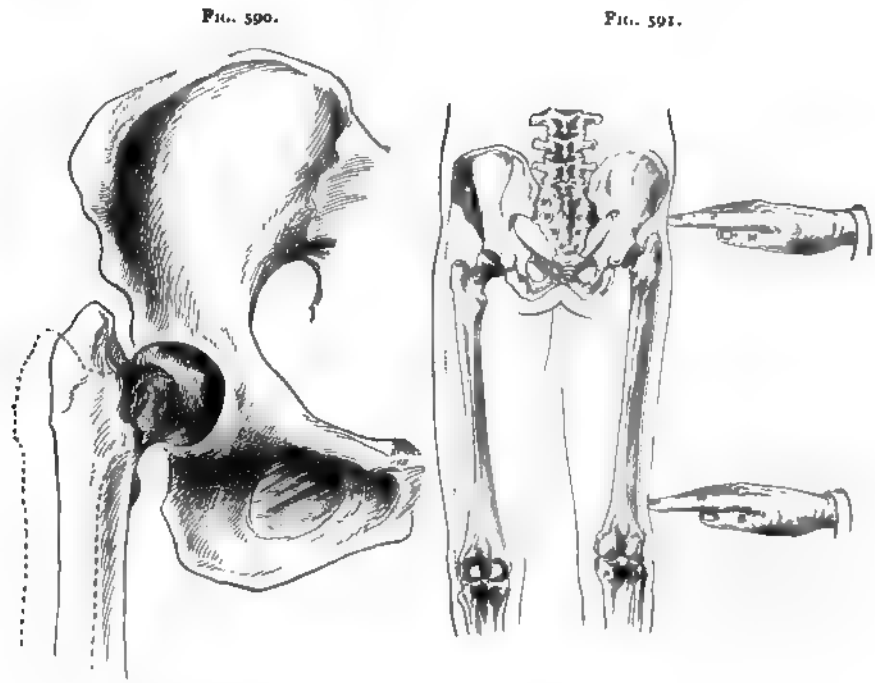

FIG. 590. FIG. 591.

FIG. 590.—To demonstrate elevation of the great trochanter in fracture of the neck of the femur. Not only is there elevation of the trochanter but it is in closer contact with the upper rim of the acetabulum. Dotted line shows normal position

FIG. 591.—Showing relaxation of the fascia lata which occurs in fracture of the femur. Allis method of determining the same. (Roberts.)

times used to demonstrate shortening in fractures of the femur. When making these measurements, the patient should be placed on a flat table and care be taken to place the lower limbs exactly parallel to each other and at right angle with the transverse axis of the pelvis or a line drawn through the acetabula. It must be recollected that uninjured femurs may be asymmetrical in length, and that usually the surgeon has no information whether the longer or shorter femur has been broken. This has been proved by measuring the bones of skeletons in which there has been no injury prior to death. The tibia on one side

may be longer than that of the other leg, therefore a difference in the length of legs after a fracture may be due not to a broken femur but to a normally short tibia. These known anatomical variations must be reckoned with in investigating possible fractures.

The shaft of the femur is well covered by muscles, so that the shaft can be only indefinitely felt with the fingers. At the lower end of the femur the internal and external condyles may be readily palpated, as well as the adductor tubercle.

Statistics.—Plagemann's statistics from Müller's clinic at Rostock, based upon the radiographic diagnosis of 1393 cases, shows that the femur was fractured in 150 instances (10.81 per cent.), as follows:

		Per cent.
1. Fractures at the upper end	84	61.04
(1) Fractures of the neck of the femur	60	4.307
(*a*) Fractures, collo-subcapital	11	0.78
(*b*) Fractures, collo-intermediate	20	1.43
(*c*) Fractures, collo-intertrochanteric	5	0.359
(*d*) Fractures, collo-trochanteric	24	1.79
(2) Separation of the upper femoral epiphysis	4	0.29
(3) Fracture of the femur, per-trochanteric	7	0.509
(4) Fracture of the greater trochanter	2	0.143
(5) Fracture of the femur, subtrochanteric	11	0.78
2. Fractures of the shaft of the femur	55	3.94
3. Fractures of the lower end of the femur	11	0.89
(1) Supracondylar fracture of the femur	7	0.509
(2) Separation of the lower epiphysis of femur	2	0.143
(3) Fractures of the condyles of femur	2	0.143

Fractures of the femur will be considered as follows: fractures of the upper end of the femur; fractures of the shaft of the femur; fractures of the lower end of the femur.

Fractures of the Upper End of the Femur

Fractures of the Head of the Femur.—This injury is extremely rare (Fig. 594). The reported cases occur not as independent fractures but in conjunction with dislocation of the femoral head, especially of dislocations from direct thrust, says Cotton. They partake of the nature of a compression fracture, and are due to such trauma as a direct fall upon the trochanter or being run over by a heavy wagon. A case reported by Riedel showed longitudinal splitting of the head and neck. The symptoms were shortening to about two inches, inward rotation, flexion, and indistinct crepitus. The treatment in this case consisted of excision of the upper fragment with reposition of the remainder of the head into the acetabular cavity. Recovery followed with ankylosis and shortening of 2 cm. Other cases are reported by Braun and by Stimson. It is possible that nailing through the great trochanter and neck might be available.

Fractures of the Neck of the Femur.—Fractures of the neck of the femur (Figs. 595–597) are observed during all decades of life. In children rare, in early adult life they are fairly frequent, but the great majority are found in late adult life, particularly after the age of fifty-five years. Recent investigations based upon radiographic examination have shown a comparative frequency of these fractures during



FIG. 592.—Method of measuring from the anterior superior spine of the ilium to the internal malleolus. A flexible steel tape should be used.

childhood. Before the use of the Röntgen ray these usually were considered to be contusions of the hip or epiphyseal separations of the femoral head. Haldenwang and Whitman's observations on this subject have been very enlightening. Haldenwang collected a series of 25 cases occurring between the ages of one and eighteen years; and

FIG. 593.—Showing the shortening which occurs in fracture of the neck or of the shaft of the femur as compared with the well side.

of these 23 were fractures of the femoral neck. Seven were found in children ten years of age or younger, and 17 were between ten and eighteen years. Of them 15 were observed in females. In the majority the fracture was at the base of the neck, a few were close to the head, and the remainder were intermediate fractures. All excepting

six were only recognized long after the injury, when an operation was about to be performed for the resultant coxa vara. Cervical fracture is, however, one essentially of late adult life, and is more common in women than in men. It constitutes one-third of all fractures occurring in persons over seventy years.

Etiology.—Very few patients are able to tell just how their femurs have been broken. Experiments have been made which show that fractures of the femoral neck may occur from a variety of forces. Some may be produced by direct force applied to the trochanter, by a blow on the knee, by extreme abduction or by undue hyperextension. Some authorities contend that these fractures are in some instances the result of strain exerted through the ligaments when the limb is in an extreme position, and that the fall is the result of the fracture and not the fracture the result of the fall. In the majority of cases, however, the fracture is probably the result of a mis-step, a fall to the ground while walking, or a slight jar. In the very young, moderate forms of violence may be the exciting cause of these cervical fractures. Those observed in early adult life are generally the result of more extreme violence, such as a fall upon the trochanter, or upon the buttocks. In the aged little force is required to cause the injury. Often a mis-step and the subsequent effort to regain one's balance may be the only form of violence to which the femur has been subjected.



FIG. 503.—Femoral Head, portions of. Intracapsular fracture, from a case of seven years' standing. (Mütter Museum, No. 1397.0035.)

Fractures by muscular action are occasionally observed in cases in which the capsule and Y-ligament are unduly stretched by the muscular pull. Dr. Allis, of Philadelphia, has within recent years made some valuable observations on the causation of fractures, but has not yet published them.

The contributing cause of fracture, in persons over fifty years of age, is the change which takes place in the composition of the bones of the entire skeleton. In the neck of the femur these changes are particularly important, in that they greatly lessen the strength of the neck of the femur, which depends upon its anatomical construction to support the whole weight of the body in walking and to repel all sudden strains and stresses placed upon it.

After the fiftieth year there occurs an eccentric atrophy of bone. The cortex of the neck of the femur becomes thinner, and the lamellæ of the spongy interior are to a great measure absorbed and replaced by large cavities containing yellow bone-marrow. This rarefaction of osseous tissue, with the consequent loss of strength, is a much more potent factor in the frequent occurrence of fractures of the neck of

the femur than the changes of angle which occur between the shaft and neck with advancing life. This degenerative change is the predisposing cause which permits slight injuries to have such disastrous results.

Varieties.—Classification of fractures of the femoral neck, based upon radiographic findings given by Plagemann is: (1) fractures collo-subcapital (Fig. 598); (2) fractures collo-intermediate (Figs. 599–601) (the earlier fractures of the neck of the femur); (3) fractures collo-intertrochanteric (Fig. 602) (after Kocher) or basal fractures of neck of femur (after König) without accompanying fracture of the trochanteric region; (4) fractures collo-trochanteric (Figs. 603–605).

The first, or collo-subcapital, form of fracture is intracapsular, located near the head of the bone, with an irregular fracture line running transverse or slightly oblique.

FIG. 595. FIG. 596. FIG. 597.

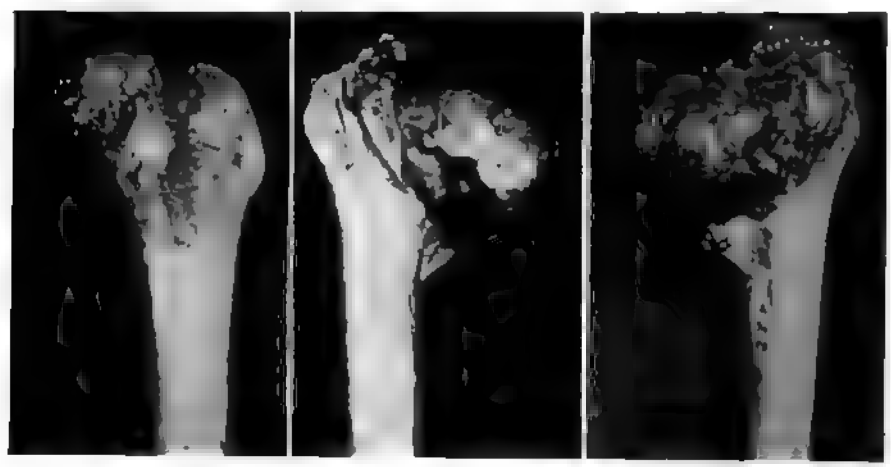

FIG. 595.—Femur, intracapsular fracture of the neck, ununited. The line of fracture is close to the head and is transverse. (Mutter Museum, No. 1397 003.)

FIG. 596.—Femur, right. Fracture of the base of the neck. (Mutter Museum, No. 1397.0255.)

FIG. 597.—Femur, upper third of intracapsular fracture of the neck; ununited. The neck of the femur has been absorbed, allowing the head of the bone to sink so as to nearly touch the trochanter minor. The fracture is wholly within the capsule. There is no bony union. (Mütter Museum, No. 1397 004.)

The second, or collo-intermediate, the so-called mixed fracture of the neck of the femur, has a fracture line irregularly oblique, running through the middle of the femoral neck. This fracture is similar to the partially intra- and partially extracapsular fracture of the earlier classification of mixed fractures. On account of the lower insertion of the joint capsule in front than behind, the line may be intracapsular in front and extracapsular behind.

The third, the fracture collo-intertrochanteric (Kocher), has a line running through the base of the neck of the femur along the intertrochanteric line, ending near the lesser trochanter, without an accompanying fracture of the trochanteric region.

The fourth, the so-called fracture collo-trochanteric, has a fracture line which runs through the base of the femoral neck on one side, and through the region of the trochanter on the other side, and usually takes the form of the letter T, K, or L. In this form there is at the same time a complete or partial breaking off of both trochanters, combined with more or less numerous separate fissures, running into the diaphysis of the femur.

FIG. 598.—Fracture of the neck of the femur (Collo-subcapital junction of the head and the neck.)

In addition to those of the above classification there are fractures which show other than the usual characteristics; but in the main, the classification given above covers the varieties as well as is possible. The exceptions to these four varieties may be looked upon as irregular varieties. Most fractures will be found to come under one of two heads—fractures of the narrow part of the neck, and fractures at the base of the neck. The older terms, intracapsular and extracapsular, should be discarded.

FIG. 599. FIG. 600. FIG. 601.



FIGS. 599, 600 AND 601.—Fractures of the neck of the femur. (Collo-intermediate. Middle of the neck.)

Impaction and fixation of fragments at the time of the injury is very frequent in fractures of the base of the neck and not infrequent in those of the subcapital variety. When impaction occurs, the resulting eversion or inversion depends upon whether the posterior part or the anterior part of the neck suffers greater destruction. When there is eversion present, destruction of the posterior wall of the neck is the greater, and when inversion is present destruction of the anterior part of the neck is present. The presence of eversion or inversion is due to the direction of the fracturing forces and the form of rotation present at the time of fracture. Nearly all fractures of femoral neck if not disturbed by handling will probably be found to be impacted or the fragments at least entangled.

FIG. 602. FIG. 603

FIG. 602.—Fracture of the neck of the femur. (Colo-intertrochanteric—Base of the neck.)
FIG. 603.—See FIGS. 604 and 605.

When the fracture line occupies the apex of the neck there is great liability of interference with the blood supply of the head. Usually there remains some blood supply through the ligamentum teres and through portions of untorn capsule and periosteum. In fractures at the base of the neck, interference with the blood supply is not so liable to take place as the line of fracture is partially without the capsule of the joint. Impaction of fragments is more frequently present as the fracture line approaches the trochanters. Fractures at the apex of the neck show frequently absence of impaction or incomplete impaction. Fractures toward the base are generally impacted. This impaction may be complete or incomplete.

In fractures in which impaction is complete the upper fragment of

the neck is driven into the trochanteric fragments, which are usually twisted backward, and with the shaft of the femur rotated outward. The angle of the shaft and neck approaches more nearly a right angle and the distance between the trochanters and head is lessened. When impaction is incomplete it is due either to violent manipulation of the part or more frequently to the fact that it does not involve the entire circumference of the neck, so that only one side, generally the posterior part, and the upper fragment, is impacted into the trochanteric fragments. When impaction is absent, particularly in fractures at the base of the neck, the trochanteric fragment with the shaft is drawn upward, displaced backward, and rotated outward. This position is



FIGS. 604 AND 605. Fracture of the neck of the femur. (Colo-trochanteric. Involving both neck and portion of trochanters.

due to muscular pull, and the weight of the extremity, which tends to rotate outward from its own weight when the patient is lying on his back.

Symptoms.—Localization of the exact seat of fractures of the neck of the femur is almost impossible by clinical symptoms alone. This is due to the shortness of the fragment and its depth in the tissues. In cases of suspected fracture, and indeed in all injuries about the hip-joint that cause disability, radiographic examination should be made. It is only by adhering strictly to this rule that the exact variety of a fracture and the presence or absence of impaction may be determined. In a small number of cases radiographic examination will not be possible, on account of the age of the patient or

other difficulty of transportation, and in these cases diagnosis must be made from the clinical symptoms.

The symptoms of fracture of the neck of the femur are impairment of motion, muscular relaxation, false motion, eversion or inversion, shortening, crepitus, pain, tenderness on pressure, swelling, ecchymosis.

Impairment of Motion.—As a rule the patient is unable to lift the extremity from the bed or to bear the weight of the body upon it. At times he is able to slightly elevate the thigh from the bed, particularly if he can obtain a purchase on the bed with the heel. Flexion of the thigh is at times possible when the thigh is in a position of abduction. Ability to raise the foot from the bed is usually impossible. When impaction of fragments is absent, motor disability is more marked than in those cases where it is present. In some instances patients

FIG. 600. Showing method of determining false motion in fractures of the neck of the femur. One hand is placed upon the great trochanter while the other produces alternate inward and outward rotation of the thigh. Lessening of the arc of rotation will also be determined.

have been known to walk on the injured limb, but in these instances firm impaction was present.

Muscular Relaxation.—With the shortening of the distance between the iliac crest and the great trochanter muscular relaxation takes place, particularly of the gluteals and of the tensor of the fascia of the thigh. This relaxation is noted by the presence of an abnormal depresssion above the great trochanter, and above the outer condyle of the femur (Fig. 591) (Allis).

Cleemann has called attention to a wrinkling of the skin over the patellar ligament in fractures of the neck of the femur, which will be obliterated when extension is made. This is due to the same physical cause as the lessening of tension of the fascial sheath on the outside of the thigh, namely, the shortening of the length of the thigh bone by over-riding at the point of fracture.

False Motion.—This is demonstrated by rotation of the thigh with one hand while the other hand is placed upon the great trochanter (Fig. 606). In impacted fractures of the neck of the femur this arc of rotation will be less than on the normal side and will be the arc of a circle whose radius is the distance from the line of fracture to the surface of the trochanter. In unimpacted fracture, the shortness of the arc of rotation will be even more marked; it is more evident the nearer the fracture is to the trochanter (Fig. 607).

Eversion and Inversion.—An increased eversion of an injured limb is usually pathognomonic of fracture. When a person lies on his back both thighs are usually slightly everted by gravity. There is usually a slight degree of abduction and flexion at the hip, with marked eversion of the entire extremity, when the neck of a femur has been fractured. In impacted fractures, the limb rests upon its outer side with the little toe almost touching the mattress and the heel is on a level with the hollow between the internal malleolus and the tip of the

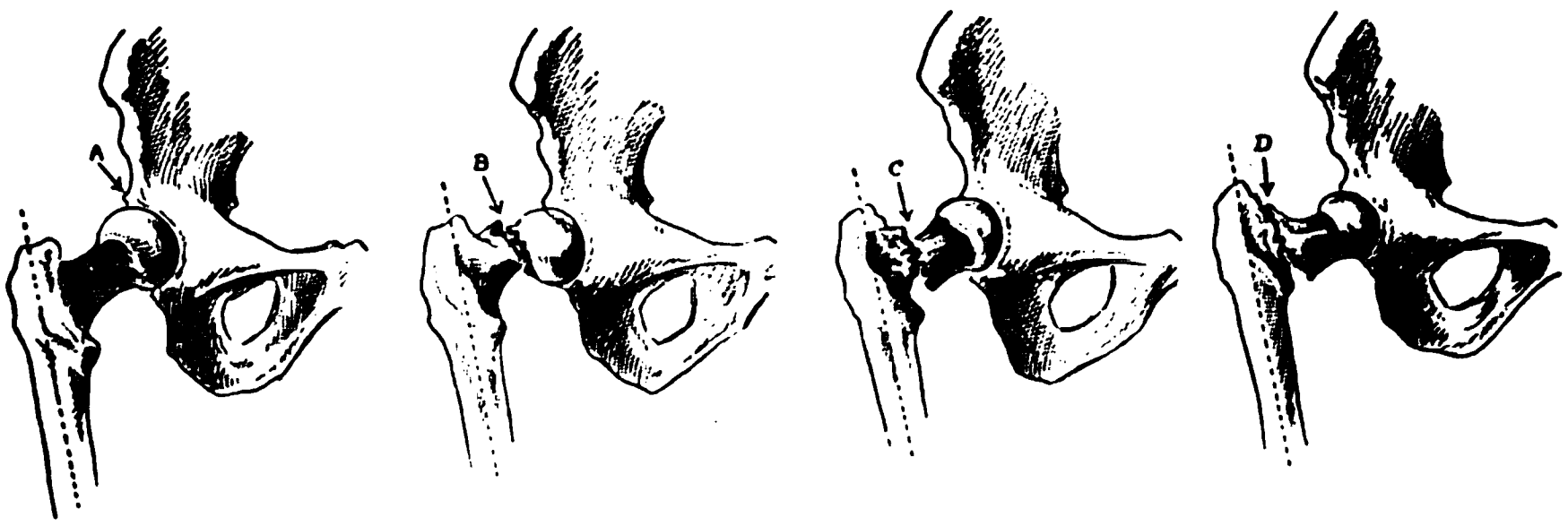

FIG. 607.—Drawing to show why the arc of rotation is shortened in unimpacted fractures of the neck of the femur. In *A* the centre of rotation is at the acetabulum, while in *B*, *C* and *D* the centre of rotation is about the axis of the femoral shaft. In inpacted fractures the centre of rotation is at the acetabulum but the arc is less than normal.

calcaneum of the sound foot. In unimpacted fractures, eversion is absolute and the limb is generally not flexed or abducted at the thigh. This eversion is due to the fact that crushing and impaction of the posterior portion of the neck are usually greater than involvement of the anterior part of the neck, and also by the fact that gravity is unresisted by the normal supporting agencies of the limb. In a few instances inversion, which may be marked, is seen. This is usually due to impaction of the front of the fracture from the trauma being the result of a blow on the back of the hip. In all cases comparison with the uninjured limb should be made to determine whether eversion is apparent or real, whether the extent of possible eversion is greater or less on the injured side, and whether the supposed fracture interferes with or increases toward rotation. Violent manipulation to determine false motion, eversion, or inversion is strongly condemned. It is often wiser to delay making a positive diagnosis than to break up impaction or tear the periosteum at the seat of fracture.

Shortening.—Shortening is one of the most important diagnostic signs in fracture of the neck of the femur. It depends upon changes in the angle of the neck with the shaft and upon over-riding of fragments. In impacted fractures the shortening is usually less than one inch, while in unimpacted fractures it may be from one and a half to three inches. Primary minimum shortening in impacted fractures, changing later to a great degree of shortening, indicates either partial or complete abolition of impaction. Bardeleben states that in fractures of the narrow part of the neck within the capsule, longitudinal displacement is prevented by the action of the intact portion of the capsule or by the impingement of the upper fragment against the small trochanter. Later, if the capsule yields or the fragments are unlocked the shortening increases. In taking measurements to determine the presence of shortening, attention should be paid to the normal differences which exist in the same individual in the length of the two femurs and of the two tibias.

The most trustworthy methods to determine the presence of shortening due to fracture of the neck of the femur are: (1) Measurement of the distance from the anterior superior spine of the ilium to the tip of the internal malleolus (Fig. 592), on both sides. In fracture of the neck of the femur the distance between these two points will be less on the affected side. (2) The relation of the great trochanter to the Roser-Nélaton line (Figs. 587 and 588). In fracture the great trochanter will be above this line. (3) Measurement by means of Bryant's triangle (Figs. 587 and 588). In this test the distance from the tip of the great trochanter to the vertical line dropped from the anterior superior spine of the ilium with the patient flat on his back will be less on the affected side. In making use of the above three tests the patient should lie upon a firm, flat surface, such as a table, the two lower extremities parallel to each other and to the line of the spine and at right angles to a line drawn through the two anterior superior spines of the ilia. Shortening may also be determined by the Allis and the Cleemann tests noted above.

Crepitus.—Crepitation is an important symptom of fracture of the neck of the femur when it can be elicited. It is not obtainable in the presence of impaction of fragments, or in those cases of non-impaction where the fragments are over-riding and cannot be brought into apposition by traction. It should not be sought for, as a rule, because of the danger of separating impaction of fragments and tearing adherent bands of periosteum. When impaction is not present it can generally be demonstrated by pressure back of the great trochanter or by traction with or without rotation. It may be simulated in manipulation by the rubbing of the outer fragments upon the ilium. Crepitus in unimpacted fractures may more readily be determined in fractures

involving the base of the neck and trochanters than in those of the apex of the neck.

Pain.—In fractures of the neck of the femur pain is generally present. It is greater in fractures involving the base of the neck; and in these cases is generally at the outer and upper part of the hip, while in fractures of the neck the pain is generally in the inguinal region. Pain is increased by active or passive movements of the thigh.

Tenderness.—Tenderness on pressure is generally localized outside of the femoral vessels.

Swelling.—Localized swelling is generally present in all fractures of the neck of the femur. It is greater in fractures approaching the trochanteric region. The fold of the buttock is less pronounced than on the sound side.

Ecchymosis—Ecchymosis only appears after several days have elapsed and it appears more constantly in proportion to the proximity of the fracture to the great trochanter. When the line of fracture is mainly intracapsular, the area of ecchymosis is limited to the groin below Poupart's ligament and inner surface of thigh, while in fractures of the base of the neck, which are mostly or wholly extracapsular, the area of ecchymosis is limited generally to the trochanteric region, but may be diffuse by being scattered over the outer surface of the thigh and buttock.

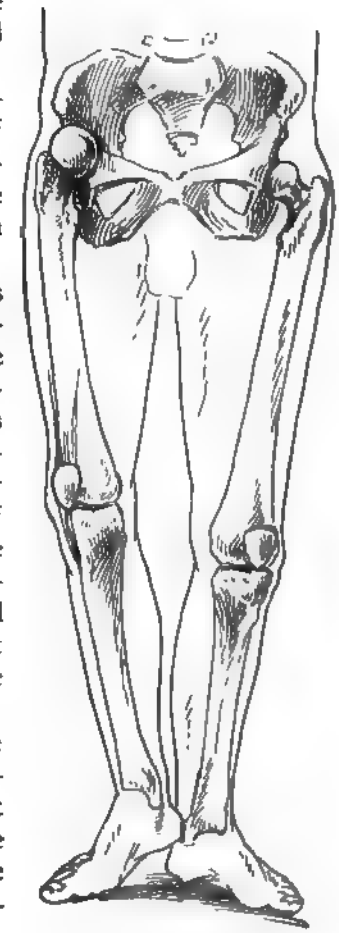

FIG. 608.—Anterior luxation of the right hip-joint. Note typical attitude, apparent shortening, eversion of the foot.

Diagnosis.—In the presence of the above symptoms diagnosis is seldom difficult. Even when the symptoms are slight in character a positive diagnosis of fracture of the neck of the femur usually may be made by careful examination. An anæsthetic is not required and violent manipulations to determine crepitus should never be made. In practically all instances a radiographic examination will determine the presence and site of the fracture. When there is any doubt as to the existence of a fracture, it should be traced as such until an absolute diagnosis is made by the subsequent history. A correct diagnosis of the site of the fracture may often be made from the clinical signs by careful consideration

of the symptoms. The exact line of break is not so important as some surgeons seem to think. The treatment does not vary much in the different varieties of femoral fracture.

Fractures of the neck of the femur should be carefully differentiated from luxation of the hip (Fig. 608), unilateral fracture of the pelvis, and contusion of the hip. Fractures usually may be differentiated from posterior dislocation of the head of the femur by the presence of eversion; for inversion in the fracture is rare. When it is present, flexion adduction and fixation, such as are found in posterior luxations, are absent, and the head of the bone is not found over the dorsum of the ilium or sciatic notch as in posterior dislocation; and in fracture with inversion, traction may break up the impaction, changing the inversion to eversion and correcting the shortening which it would not do in posterior dislocation. Dislocation is rare in the aged but fracture is common as a result of injury. The symptoms already described and the X-ray will reveal the condition. Fractures with eversion may be mistaken for anterior dislocation of the head of the femur. The anterior dislocations are, however, rare and are accompanied by flattening of the trochanteric region, abduction and flexion of the thigh and the presence of an abnormal prominence at the site of the displaced head of the femur on the pubes or in the obturator foramen. In dislocations there is always marked limitation of passive motion, and the limit of possible mobility is always noted by a sudden arrest of movement felt by the hand of the examiner. The axis of the head of the femur and that of the inner surface of the internal condyle normally point always in the same direction; attention to this fact will determine the position of the head of the bone in dislocation of the head of the femur. In fractures the direction of these two areas may be different.

Fracture of the femoral neck should be carefully diagnosticated from fracture of the pelvis. The fractures of the pelvis with which it may be confused are fracture of the rim of the acetabulum and fracture of the acetabulum with partial or complete penetration of the head of the femur through the acetabulum into the pelvic cavity. In these cases a careful examination of the patient and a radiogram will make clear the diagnosis.

Fractures of the neck of the femur should be differentiated from contusion of the hip. In contusion there may be impairment of motion, elevation of the pelvis on the side affected, outward rotation and flexion of the thigh, severe pain, and at times muscular spasm. Fracture, however, it is well to remember, often occurs in elderly people as a result of a moderate degree of violence, and instead of improvement taking place the functional condition becomes worse. In simple contusion a relatively severe degree of violence is present and the function

of the part tends to improve after several days. In addition the symptoms of contusion generally are localized in the area injured.

A recent fracture of the neck of the femur should be differentiated from a previous fracture, or from an arthritis deformans to which a local contusion has been added. Skiagraphy and the clinical circumstances will aid in the determination of the true character of the patient's disability.

Fractures below the trochanters may be differentiated from those of the neck by the fact that rotation of the trochanter does not occur when the shaft of the femur is rotated by the surgeon, and the evidence that rotation of the shaft occurs upon its longitudinal axis.

Prognosis.—Many fractures of the neck of the femur are observed in persons of advanced life. The problem is not so much to obtain perfect anatomical apposition of fragments and a perfect functional result as to prevent the development of conditions which, with confinement to bed and the incidental shock of the injury, may produce death. Many of the deaths in these cases are due to hypostatic pneumonia, to development of mental and physical shock which produces death in a few days, or to sepsis from extensive bed-sores. A few cases are undoubtedly due to fat embolism or to acute dilatation of a fatty degenerated heart. It is unquestionably true that close confinement to bed in the recumbent position, with cumbersome and fixed dressings for a long period, will tend toward hypostatic pneumonia, bed-sores, and fatty degeneration of the heart. Patients of the age in which this form of fracture is so frequent do not take kindly to enforced immobilization in the recumbent position.

The prognosis in the aged in regard to union and subsequent function is an entirely different problem. Impaction of fragments is the rule in these cases, particularly in fractures occurring in the outer half of the neck. In the aged this impaction should seldom be broken up to obtain more satisfactory position of fragments. In these patients anatomical results may be imperfect, but aside from a moderate degree of shortening and an irregular period of discomfort and pain, the patients should be able to get about with a slight limp after a period of several weeks, or at the worst may be obliged to use a cane for partial support. Fractures occurring in the inner half of the neck are more liable to be unimpacted than those of the outer half. In the unimpacted cases of the inner half of the neck, bony union is the exception; fibrous union, pseudo-arthrosis or complete atrophy of the inner half of the neck is perhaps the rule. In impacted cases of this region impaction may be broken up by slight jarring, by the weight of the body, or by secondary necrosis. Unimpacted fractures of the outer half of the neck under appropriate treatment should result favorably in firm, bony union, with a small amount of shortening and loss of function.

Even when non-union occurs in unimpacted fractures of the neck, a fair amount of weight-bearing is possible and with the use of a cane a favorable degree of function is present. There are many fractures in middle life and earlier in which a proper restoration of the anatomical contour is desirable and obtainable to a very great degree. Union in good position is to be sought sometimes even by operative fixation.

Treatment.—There are two considerations in the treatment of fractures of the neck of the femur—the patient and the fracture itself. Fractures, whether impacted or not, inducing a tendency in the patient to the development of hypostatic pneumonia, cardial degeneration, bed-sores, and even those that show no such untoward symptoms except an inability to remain constantly confined in bed, should be disregarded to a certain extent so far as its treatment opposes the health of the patient. Hence apparatus should be removed and the patient set up in bed or placed in a wheel-chair. In many instances, however, no such emergency arises even in the aged.

In impacted fractures in the old, liable to break neck close to head, it is unwise to attempt forcible reduction to secure better position of the fragments. These cases should be handled as carefully as possible, and if there are no contraindications the patient should be placed upon a firm level mattress, the foot of the bed slightly elevated, and the leg immobilized either by sand-bags placed on both sides or by the application of a long external T-splint. If there is muscular twitching, it is advisable to supplement this dressing by the application of a Buck traction apparatus with from three to six pounds fastened to the stirrup (Fig. 609). This weight steadies the part and often gives considerable comfort. This dressing should be used for from four to eight weeks. It may be removed at this time and a short spica of plaster-of-Paris perhaps applied from the waist to mid-thigh, and the patient allowed upon crutches. In the aged it is better to remove all apparatus at the end of about five weeks and allow the patient to get up; at first sitting up in bed a short time daily, later resting in a chair, and at the end of about ten weeks walking with crutches.

Exception to the above rule in the treatment of impacted fractures is in cases occurring in early childhood or middle age, which, if left uncorrected, may result in a deforming coxa vara with considerable subsequent deformity and loss of function. In these cases it is advisable, perhaps only after consultation with another surgeon, to correct the deformity under ether, place the part in extreme abduction and traction, and while in this corrected position to apply a gypsum spica splint from chest to toes of the affected side after the method of Whitman.

There are several methods of treatment for non-impacted fractures that may be used. The usual one employed as a routine is Buck's traction apparatus with from twelve to thirty pounds' weight attached

to the stirrup, elevation of the foot of the bed for counter-traction, and lateral support by sand-bags, boxes of bricks or T-splint. A long external straight splint extending from the axilla to below the foot may be used instead of the sand-bags (Fig. 609). At times this may be supplemented by a posterior splint carefully padded, extending from the crease of the buttock to a point several inches above the heel.

It is probably true that nearly all new fractures in those approaching old age are impacted or the fragments entangled by the breaking force. The non-entangled and non-impacted fractures seen in practice have often, it is believed, been made so by improper handling

A second form of dressing is the use of longitudinal traction with the thigh in marked abduction. The same form of apparatus as in

Fig. 609.—Method of applying Buck's traction apparatus. Adhesive plaster spreader to keep pressure from the malleoli; a padded posterior splint to keep the heel from the bed. This dressing should be supplemented by a Liston or T-splint or by sand-bags to steady extremity. Should have padding to protect malleoli from pressure between skin of ankle and traction straps. By greatly elevating pulley and changing direction of pull, traction may be made in line of upper fragment if it be elevated and rotated outwards.

the method given above may be used except that the external or Liston splint should not reach above the level of the trochanter.

A third form, and this is of especial use in the young and the middle aged who stand immobilization well, is the method of abduction to full normal extent devised and perfected by Whitman. He claims that the abduction method is based upon the anatomical construction of the joint, that its typical application implies the restoration of an approximately normal contour of the bone, which he believes is possible in the great majority of cervical fractures of the femur. Whitman thinks it the only safe and practicable means of correcting

deformity of the uncomplicated or so-called non-impacted type. The patient, usually anæsthetized, is lifted to a pelvic support, preferably furnished with a perineal bar for counter-pressure, and the extended limbs are supported by assistants. The assistant holding the uninjured limb abducts it to the normal limit, in order that it may serve as a guide and incidentally to fix the pelvis. The injured limb is first flexed and rotated sufficiently to disengage soft parts that may be interposed between fragments. It is then completely extended, and the assistant, by direct manual traction, overcomes the shortening, as demonstrated by measurement and by the relation of the trochanter to Nélaton's line, at the same time correcting the outward rotation. Still maintaining steady traction, he then abducts the limb to correspond with its fellow, the operator meanwhile supporting the joint and lifting

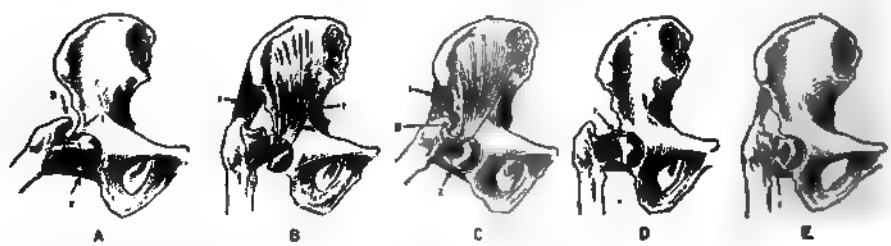

FIG. 610. Principles to be considered in Whitman's abduction method for the treatment of fractures of the neck of the femur. (*A*) Normal range of abduction depends upon the angle of the neck with the shaft of the femur (1), the tension of the capsule (2), and the range of motion possible between the great trochanter and the superior rim of the acetabulum (3). (*B*) The usual displacement in fractures of the femoral neck. The outer fragment is pulled upward and backward by muscular pull (1) and by gravity. (*C*) Full abduction relaxes muscular tension (1), secures ligamentous tension of capsule (2), and forces the inner end of the outer fragment into place by the leverage action of the great trochanter against the superior rim of the acetabulum (3). (*D*) A form of impaction (1) which is broken up and reduction of fragments obtained by full abduction. (*E*) A form of incomplete fracture (1) which is corrected by full abduction of the limb. (Modified after R. Whitman.)

the thigh upward. The pelvis should now be level and the extended limbs in exact correspondence in every particular. A plaster-of-Paris spica is applied from the axilla to the toes. This should be carefully adjusted about the pelvis and trochanter. It should completely cover the buttock and be heavily reinforced beneath the point and thigh, that it may be unyielding to pressure and therefore effective as a posterior splint to hold the limb at its proper plane. This method aims at reducing the fragments and holding them in anatomical position until consolidation occurs (Figs. 610–613).

Another form of treatment that has met with considerable success, especially by its originators, is the Ruth-Maxwell method. This consists in flexing the thigh at a right angle with the trunk to relax the psoas and iliacus muscles, and forcibly correcting the upward and backward displacement while in this position. After such correction,

continuous longitudinal and lateral traction is applied, the former by a Buck extension apparatus, using from fifteen to twenty pounds of weight, and the latter by passing about the thigh on the anterior internal and posterior aspects padded binder's board, and over this a lateral traction apparatus with pulley and weight, pulling outward and upward so as to raise the upper end of the shaft and trochanter to its normal position. Four to eight pounds of weight should be used for lateral traction. Counter-traction is obtained by raising the foot of the bed six to ten inches and the side of the bed corresponding to the injured limb two to four inches. This method has many advantages

FIG. 611.—The elevation of the head of the bed (25°) to provide a semi reclining posture and thus to lessen the danger of thoracic congestion and to improve the nutrition of the injured part (Whitman, in Annals of Surgery.)

and is probably better than the simple Buck longitudinal traction method and as efficient and less troublesome than the Whitman abduction method.

Cotton has recommended operative impaction in some fractures of the femoral neck, without impaction from the injury. He strikes the trochanter with a mallet, thus causing locking of the fragments and encouraging union. This obviates to some extent the probability of disability that may arise if non-union should occur despite the usual treatment in the aged.

In a few cases open operation and nailing of the fragments will be required. The cases calling for this procedure are those of non-union

occurring in the young and middle-aged, robust individuals. In these cases either a nail or a fresh bone peg taken from the crest of the tibia may be used (Albee's method); whichever method is used, immobilization should be obtained by the use of a gypsum spica.

After-Results.—Failure of union does not of itself mean entire loss of function. In many cases impaction has occurred at the time of

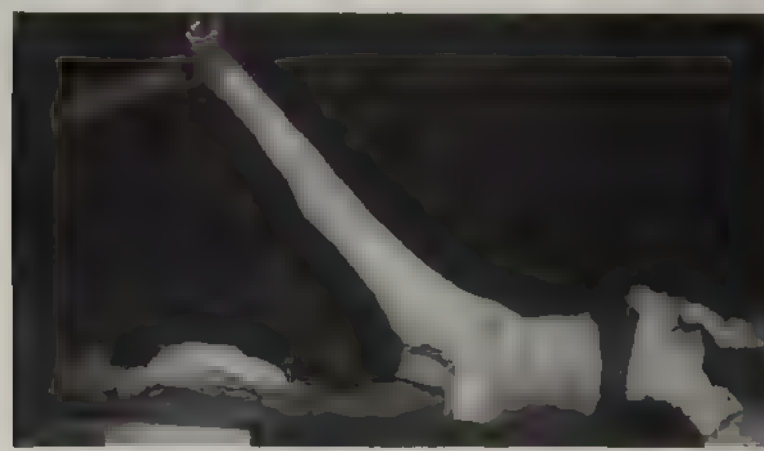

FIG. 612.—The plaster spica holding the limb at the limit of normal abduction, illustrating the adjustment to the pelvis and to the hip. (Whitman, in Annals of Surgery.)

FIG. 613.—Application of plaster-of-Paris case. Whitman's method for fracture of the neck of the femur.

fracture, and a large percentage of patients recover with fair anatomical and functional results. The report of the Committee on Treatment of Simple Fractures of the British Medical Association shows the following results obtained in fractures of the neck of the femur:

Number of cases, 91; anatomical results, good, 18, moderate, 18, bad 39; functional results, good, 24, moderate, 28, and bad, 39. Per-

centage of good anatomical and good functional results 16.4; percentage of moderate or bad anatomical with good functional results 9.8 per cent. Average duration of incapacitation (non-operative) under fifteen years, 7 cases traced, average number of weeks of incapacitation, 26.5; over fifteen years, 65 cases traced, average number of weeks of incapacitation, 53.2 These results are probably much less satisfactory than those usually obtained in American surgical practice, when the surgeon himself takes care of the patients and inspects them frequently.

Separation of the Upper Femoral Epiphysis in Childhood.—Separation of the epiphysis occurs in childhood, and is considered by some authorities to be a rather rare injury. During the past fifteen years, however, articles have been written by many surgeons, notably Hoffa, Hofmeister and Whitman, which prove conclusively the comparative frequency of this injury. By some it is considered a true epiphyseal separation and by others a fracture of the neck of the femur close to the head. Often the lesion has been overlooked at the time of injury, and attention only called to it when there has developed, as a result of the injury and the too early weight-bearing on the part, a traumatic coxa vara. Sprengel, who first called the condition traumatic coxa vara, and Hoffa consider the lesion to consist of a complete or incomplete separation of the epiphysis of the head, while Whitman maintains that the traumatic coxa vara usually is the result of a fracture of the neck of the femur. Radiographic examination shows generally either a true fracture of the neck near the head or a separation of the epiphysis of the head with a portion of the diaphysis of the neck attached. The fracture or the epiphyseal separation is usually incomplete in character. The condition may be observed up to the sixteenth year, but the majority of cases occur from the eighth to the twelfth year.

Etiology.—The lesion occurs after direct injury to the hip.

Symptoms.—The patient, after being confined to bed, perhaps only for a few days, gets up and walks about with a little lameness but not enough to suggest to the parents grave injury to the hip. This is accounted for by the fact that the lesion is incomplete, or when complete, firm impaction is present. Recovery takes place with a slight limp which fails to disappear, and later it is noticed that there is appreciable shortening of the femur, confined to the neck. As time goes on greater bending of the neck of the femur occurs, so that slight disability is replaced by marked disability. There is now added prominence of the great trochanter, slight eversion, marked limitations of abduction, and slight pain.

When these cases are seen shortly after injury and the possibility of grave injury recognized, the symptoms present will depend upon

whether the fracture or separation is complete or incomplete. The differentiation between pure epiphyseal separation or fracture of the neck close to the head can only be made by radiogram.

Diagnosis.—Fracture in or near the epiphyseal line is commonly the result of violence, such as a blow upon the hip or a fall upon the trochanter, a fall upon the feet, or while jumping with marked outward rotation of the lower limb. The early symptoms are shortening, outward rotation of the thigh, prominence of the trochanter; if the fracture or separation is complete, there may be harsh or soft crepitus, depending upon the lesion present. In Scarpa's triangle there may be felt a swelling corresponding to the upper end of the displaced lower fragment.

The condition should not be confused with tuberculosis of the hip-joint in childhood, which it closely simulates; and it should also be diagnosed from the coxa vara due to softening of the neck of the femur, the result of deficiency in lime salts.

In traumatic coxa vara the great trochanter is always above the Roser-Nélaton line; this occurs in tuberculosis of the hip-joint only when the disease is far advanced and diagnosis is unmistakable. A radiographic examination will clear up the diagnosis.

Treatment.—Treatment depends entirely upon whether the condition is recognized at the time of injury or not until a resultant coxa vara is present.

In recent fractures that are incomplete and in which deformity is present, the patient should be anæsthetized, reduction made, and immobilization in the abducted position obtained by the use of the gypsum spica bandage as advocated by Whitman (Figs. 610–613). In complete fractures the treatment should be the same. After application of the plaster spica a radiogram will show whether reduction is satisfactory. In those cases in which reduction cannot be satisfactorily accomplished or maintained, open operation, with bone pegging if necessary, is recommended. Immobilization should be maintained for eight weeks, after which a suitable hip-splint should be worn for six months to a year.

In those old cases in which the condition is only recognized after coxa vara is pronounced and union is firm the line of treatment should be quite different. If the lesion is seen within a few months after injury and the surgeon believes that something may be gained by heavy traction, this may be used for a time in the hope of correcting the condition because union is not firm. When the diagnosis is made later and the condition of bent bone is marked and bony, osteotomy of the neck or in the subtrochanteric region should be performed and immobilization obtained by a plaster spica for eight to ten weeks, after which time a hip-splint should be used for six to nine months.

Fractures Through the Trochanters.—Under this class may be grouped the fractures involving the region of the trochanters (Figs. 614–617). As a rule the fracture line is irregular and runs through the great trochanter, splitting it through the intertrochanteric line to a point above the lesser trochanter. In a few instances the latter will be found split in two or separately detached, or the fracture line may be spiral in character so that the upper fragment extends downward and consists of a pointed piece of bone, a part of the shaft. As a rule moderate comminution is present. These fractures should be separated from those occurring at the base of the neck and from those of the subtrochanteric region; the differentiation from the latter consists in the fact that rarely does the small trochanter form a part of the upper fragment. The clinical difference of this last form of fracture (subtrochanteric) is the fact that the action of the psoas and iliacus muscles tends to tilt the upper fragment upward when the fracture line is below the lesser trochanter. Formerly this form of fracture was considered rather rare, but from a study of radiograms its comparative frequency is manifest.

Etiology.—This fracture is observed frequently in middle adult and early late life, the result of either a direct fall upon the trochanteric region or more commonly a fall in which the extremity is in marked adduction. The lesion sometimes partakes of the nature of a torsion fracture. In torsion fractures the line of fracture is through the great trochanter and intertrochanteric line; and either the lesser trochanter is split into two fragments or it is separately detached by the action of the psoas and iliacus muscles.

Symptoms.—The symptoms of fractures through the trochanters are prominence of the great trochanter, marked thickening in the region of the trochanters, complete disability, shortening of the limb, eversion due to muscular relaxation, the weight of the limb and lack of control, and slight or absent impaction of fragments; rotation of the limb shows rotation about the centre of the shaft of the femur and great trochanter, pain, tenderness on pressure, particularly over the region of the great trochanter and upper part of the shaft. Crepitus may be present in the absence of impaction upon rotation of the shaft of the femur combined with traction.

Prognosis.—Fractures through the trochanters are extra-articular, and are usually followed by firm union, with considerable thickening from excessive callus in the trochanteric region, and a moderate degree of shortening. Some limitation of the normal range of motion is generally permanent, and the patient recovers with a slight limp and has at certain times considerable permanent pain over the trochanteric region and down the outside of the thigh. Under careful treatment permanent eversion should seldom result.

Fig. 614



Fig. 615



Fig. 616.



Figs. 614, 615, 616 and 617. Fractures of the femur through the trochanters.

Treatment.— As union of fragments occurs in this region, the question of impaction or non-impaction is not so important as in

fracture of the neck of the femur. The majority of these fractures will be found to be but lightly impacted or quite unimpacted. Unless there is some marked contraindication, such as the patient's age, all of these fractures should be treated as unimpacted fractures. It is probable that anæsthesia generally should be used for reduction; this is to be accomplished by longitudinal traction in the abducted position and counter-traction by a strap around the perineum. All eversion and shortening should be corrected and parts placed permanently in the abducted position, after the Whitman method, in a gypsum spica. If for any reason this is not considered feasible, a Buck traction apparatus

FIG. 618. FIG. 619



FIGS. 618 AND 619.—Fractures of the great trochanter of the femur.

with from 15 to 25 pounds of weight should be applied with the limb in the abducted position, and an external axillo-tarsal and perhaps a posterior splint. The foot of the bed should be raised and on the affected side the bed should be higher than on the other side of the patient. A heavy moulded gypsum splint from axilla to ankle is better than the wooden splints. After four to six weeks a plaster spica may be applied and a few weeks later the use of crutches may be permitted if the well foot wears a high sole shoe. The weight-bearing of walking should not be begun for at least three or four months.

Fracture of the Great Trochanter, or Separation of the Apophysis.—Isolated fracture of the great trochanter (Figs. 618–619) is a very rare injury. In conjunction with fracture at the base of the neck or through the intertrochanteric line it is occasionally seen. The apophysis unites with the diaphysis of the bone at about the eighteenth year.

Etiology.—Fracture of the great trochanter, or separation of this apophysis, is the result of direct violence or of muscular action. When the result of direct violence, there may be comminution. When the result of muscular action, it partakes of the nature of a tearing off of the cortex of the trochanter, while the same form of injury before the time of union of the apophysis with the diaphysis will result in a complete separation of the apophysis. The amount of displacement is dependent upon the periosteal covering of the trochanter.

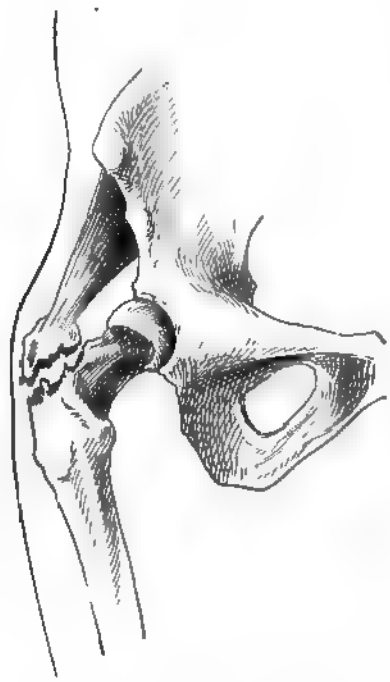

FIG. 620.—Drawing to show the type of displacement which occurs in fracture of the great trochanter. The trochanter is pulled upward and backward by the action of the gluteus medius and minimus muscles.

Symptoms.—At first there may be only the symptoms usually associated with contusion. There is localized pain and tenderness on pressure, and on palpation it may be possible to distinguish the movable fragment. Displacement of the fragment upward and backward by the action of the gluteus medius and minimus muscles (Fig. 620) is present, when the muscular attachments are torn from the diaphysis of the bone; this displacement of the upper fragment may be as much as several inches. In the absence of localized swelling, flattening over the trochanter will be noted. Crepitus may at times be obtained by flexion, abduction, and outward rotation of the thigh and by pressing the fragments together. Primarily, palpation of the fragment and crepitus are not obtainable on account of the localized pain and muscular spasm present. The thigh is generally held flexed and rotated inward, active motion is painful, abduction is limited or impossible, and shortening of the limb seen in cervical or shaft fractures is absent.

Prognosis.—Without operative interference, union is generally fibrous in character, although future functional results are good.

Treatment.—The non-operative treatment of fixation is a plaster spica in the abducted flexed position with the thigh rotated outward.

If radiographic examination shows approximation of fragments is not good by this method, open operation with direct fixation of the fragment by a nail should give good results.

Fracture of the Lesser Trochanter.—Isolated fractures of the small trochanter are extremely rare. It is most frequently seen in conjunction with fractures through the trochanteric region. Isolated cases have been reported by several authors, and in them the condition has been recognized either by radiograms or has been confirmed by autopsy.

Etiology.—Of the reported cases the majority were observed in boys of seventeen years or younger, and were the result of muscular action in running or in avoiding a fall. Three cases were in men beyond middle life, in which the injury was due to muscular pull in falling. In one case the patient was run over by an omnibus. The lesion consisted of a tearing off of the lesser trochanter, and in two of the cases a portion of the shaft was attached to the fragment. The injury is due to the pull of the psoas and iliacus muscles.

Symptoms.—The symptoms of fracture of the small trochanter are local pain and tenderness on pressure, which are increased by attempts at active flexion or passive extension of the hip-joint. In some of the reported cases the patients were able to walk; various degrees of eversion were present. Ecchymosis on the inside of the thigh appearing after twenty-four hours, together with swelling, are usually present. A positive diagnosis of the condition can only be made by radiogram.

Treatment.—This should consist in immobilization in a plaster-of-Paris spica with flexion at the hip-joint. Union should occur in from six to eight weeks and may be fibrous in character.

Fractures of the Subtrochanteric Region.—Fracture of the femur in the subtrochanter region (Figs. 621–622) are relatively frequent. Three varieties of fracture are seen in this region: the transverse, the oblique, and the spiral.

Etiology.—Fractures below the trochanter are the result of either direct violence or indirect force. When resulting from direct violence the fracture line is apt to be transverse, while those occurring from indirect violence are either oblique or spiral in character.

Symptoms.—Fractures of this region are unimpacted. The symptoms are absolute disability, shortening, which is often marked, due to angularity of fragments and over-riding. Shortening is not marked in the transverse variety of fracture. There is marked outward rotation of the thigh and leg, due to gravity and lack of bony continuity, and free mobility of the lower fragment. Rotation of the shaft does not show corresponding rotation of the trochanter. Crepitus may be elicited when the line of fracture is transverse, as in this instance dis-

placement of fragments is not great, but it is difficult to obtain in the oblique and spiral forms of fracture on account of the over-riding displacement of fragments and the interposition of soft parts. Deformity is generally marked, and consists of flexion with outward rotation of the upper fragment, due to the pull of the psoas and iliacus muscles upon the upper fragment, and abduction from action of the gluteus medius and minimus muscles upon the same fragment. In addition to these symptoms there is pain, localized tenderness, swelling, and ecchymosis; and sometimes the sharp point of the lower end of the upper fragment may be felt on the anterior surface of the thigh. Occasionally puncture of the skin is threatened or is actually produced by

FIG. 621. FIG. 622



FIGS. 621 AND 622.—Subtrochanteric fractures of the femur.

this sharp fragment. The exact variety of fracture and position of fragments may be determinable only by radiogram.

Prognosis.—Union takes place in the transverse fractures when there is little or no displacement of fragments with little or no deformity. In a considerable proportion of instances, however, the difficulty of maintaining reduction and accurate approximation of fragments results in some over riding of fragments, with consequent shortening and anterior and external angular deformity. These defects may be largely due to inefficient or careless supervision of the treatment.

Treatment.—The problem of treatment of fractures in this region is often very trying. Reduction as a rule can be readily accomplished,

but the difficulty of maintaining reduction taxes the ingenuity of the surgeon and calls for careful observation of the fracture at all times. In cases in which there is little if any flexion or abduction of the upper fragment, apposition of fragments may be maintained by the use of Buck's traction apparatus, using fifteen to twenty pounds of weight with the hip moderately flexed and the knee extended, a padded posterior splint from the upper end of the thigh to a point above the heel, and a long external splint from the axilla to below the foot; and elevation of the foot of the bed for a distance of ten inches. If there is a tendency toward abduction of the lower end of the upper

FIG. 623.—Modified Zuppinger's apparatus for treatment of fractures in the subtrochanteric region. Traction is obtained through an adhesive plaster dressing applied with the hip- and knee-joints flexed. Coaptation splints preserve to a great extent lateral alignment of the fragments. Sufficient weight should be used to correct overriding of fragments.

fragment, this displacement may be overcome by the use of a pad between the external splint and the lower end of the upper fragment, by traction in the abducted position, or by the use of a plaster spica with traction, applied with the limb in a position of abduction. The long splint with a pad is probably unwise in most cases, unless the fragments can be successfully locked at the time of reduction. Anæsthesia is desirable in most fractures of the shaft, both for a correct understanding of the injury and to permit proper reduction.

In the presence of more marked flexion deformity of the lower end of the upper fragment, several procedures may be adopted. The lower fragment must be brought in line with the upper fragment. This may

Fig. 624. Fig. 625.

Fig. 626

Figs. 624, 625 and 626.—Types of fracture of the upper third of the shaft of the femur.

Fig. 627.

Fig. 628.

Fig. 629.

Figs. 627, 628, and 629.—Types of fracture of the middle of the shaft of the femur. In Fig. 629 note that union has occurred with marked overriding and angular displacement of fragments.

FIG. 630. FIG. 631.



FIG. 632 FIG. 633

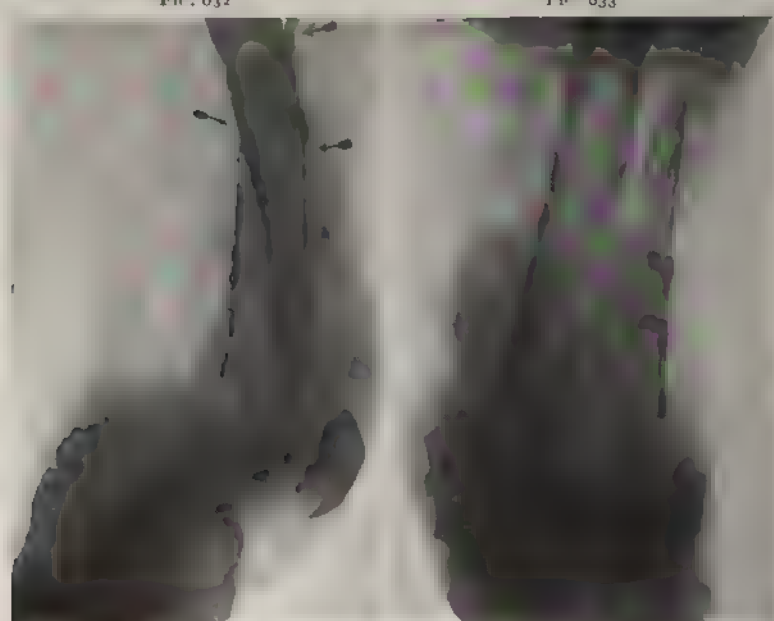

FIGS. 630, 631, 632, AND 633.—Types of fracture of the lower third of the shaft of the femur.

be accomplished in children by vertical extension; adults may not take kindly to this form of extension. In adults, anatomical apposition may be maintained by the use of a plaster spica from the lower chest level to the knee, applied with the thigh in a position of flexion and the use

Fig. 634.



Fig. 635.



Fig. 636.



Figs. 634, 635, and 636.—Types of fracture of the shaft of the femur occurring during childhood

of traction from the thigh. The same position of fragments may be obtained, though less satisfactorily, by the use of the Smith or Hodgen splint or the double-inclined plane. In some fractures here at times longitudinal traction, posterior splint, and a long external splint combined with a bag of shot or sand over the lower end of the upper fragment may give satisfactory apposition, although this method requires considerable attention and is not strongly advocated. If satisfactory position cannot be obtained by one of these methods, operation and direct fixation of the fragments by a steel plate is advocated. These fractures are especially adapted to the plate fixation method because of the difficulty of maintaining coaptation by external apparatus, when displacement is marked.

FIG. 637



FIG. 637.—Type of fracture of shaft of femur occurring in childhood.

Whatever method of treatment is used, it should be continued, if satisfactory, until firm union has taken place; weight-bearing should not be attempted for at least twenty to thirty weeks after the time of injury.

FRACTURES OF THE SHAFT OF THE FEMUR

Fractures of the shaft of the femur include those occurring below the subtrochanteric region and above the supracondylar site. They are most commonly met with during active adult life and in the male sex, and usually affect the middle, occasionally the upper and rarely the lower third of the bone. Of 55 fractures of the shaft of the femur observed by Plagemann, the upper third was involved 9 times, the middle third 40 times, and the lower third 6 times. The fracture line was irregularly

transverse 28 times, spiral 13 times, oblique 8 times, and oblique with a third fragment 6 times. In this series, therefore, one-fifth of all fractures of the shaft are spiral in character.

Etiology.—Fractures of the shaft of the femur are, as are other fractures in the shafts of long bones, the result of direct or indirect violence or muscular action. Fractures from direct violence are most frequently found in the lower third of the bone, and are due to crushing injuries, such as from falling walls or weights and being run over by vehicles. Fractures by direct violence occur most frequently in the middle and occasionally in the upper thirds of the bone, as in a fall upon the feet. Muscular action is found as a cause in fractures in the upper and occasionally in the middle thirds of the femur, which result from a sudden twist of the body and upper part of the thigh with the foot in a fixed position.



FIG. 638. Comminuted fracture of shaft of femur.

Varieties.—The line of break follows certain definite lines, depending upon the position of the fracture and the nature of the violence (Figs. 624–638). Fractures by direct violence are usually transverse; at times there is a three-cornered piece of bone broken off at the point distal to the direction of force. Fractures by indirect violence are generally oblique, while fractures by muscular action are spiral in character; here the fragments are often very sharp and oblique, and at times there is a rhomboidal portion of bone detached at a point of fracture. Oblique and spiral fractures show a tendency to be open, due to the piercing of the soft parts and skin by a sharp fragment; fractures by direct violence are more apt to be comminuted as well as open, and not infrequently are attended with considerable destruction of overlaying soft parts. Incomplete fractures here are extremely rare.

Symptoms.—The symptoms of complete fracture of the shaft of the femur are loss of voluntary motion, or if any motion is present attempts to lift the leg from the bed show angular deformity at the seat of fracture. There are present deformity, abnormal mobility

(Fig. 639) and crepitus at the site of fracture, eversion of the knee, leg and foot, and shortening of the limb. The shortening is due to the obliquity of the fracture line permitting over-riding of the fragments from the muscular pull. There is swelling from infiltration of soft parts beneath the deep fascia about the seat of fracture. Shortening may be overcome by strong, steady traction and counter-traction, and its presence may be estimated by measurement of both extremities from the anterior superior spine of the ilium to the internal malleolus or to the tibial tubercle, or from the umbilicus or ensiform cartilage to the malleoli. Shortening varies from one to five or six inches. In making these measurements the patient should be placed upon a flat, firm mattress and the extremities should be at right angles to a line drawn through the two anterior superior spines of the ilium. The asymmetry in length of normal bones must not be forgotten in estimating shortening in fractures. In transverse fractures there may be

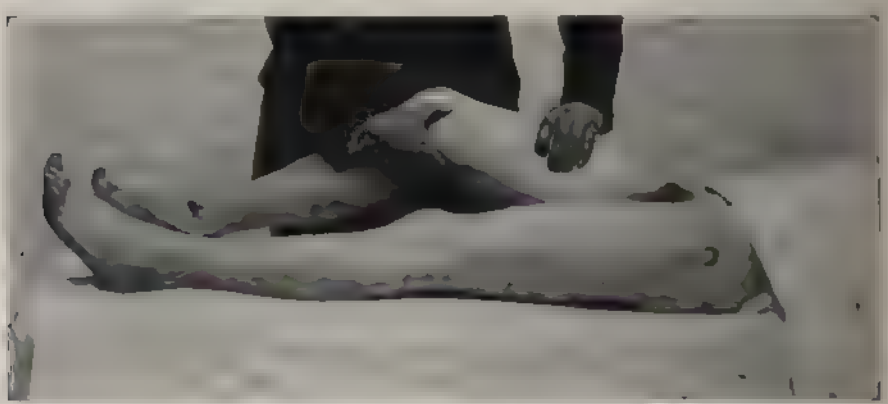

FIG. 639.—Method of determining abnormal mobility and crepitus in fracture of the shaft of the femur.

little or no shortening because of the absence of marked displacement of fragments or of entanglement or impaction of fragments. Displacement of fragments and angular deformity are, however, the rule in complete, unimpacted fractures. Factors acting in the production of displacement are the direction of the fracturing force, the curve of the bone, and the traction of attached muscles. Rotation of the lower fragment externally is the rule in all fractures of the shaft and is due to the weight of the limb (Figs. 640-646).

Typical Displacement in the Different Regions.—In fractures of the upper third of the shaft (Fig. 647) the lower end of the upper fragment tends to be displaced forward and rotated outward. This deformity is due to the action of the psoas and iliacus, and the gluteus medius and minimus muscles, while the upper end of the lower fragment is drawn upward, inward and posteriorly by the action of the

adductor and flexor muscles. Angular displacement is thereby produced. Displacement, however, may be absent in transverse fractures and in those close to the trochanters. In fractures of the middle third (Figs. 648 and 649) close to the upper third, the same type of displacement of fragments may occur as in fractures of the upper third. When, however, the line of fracture is below the attachment of the

FIG. 640. FIG. 641. FIG. 642. FIG. 643.

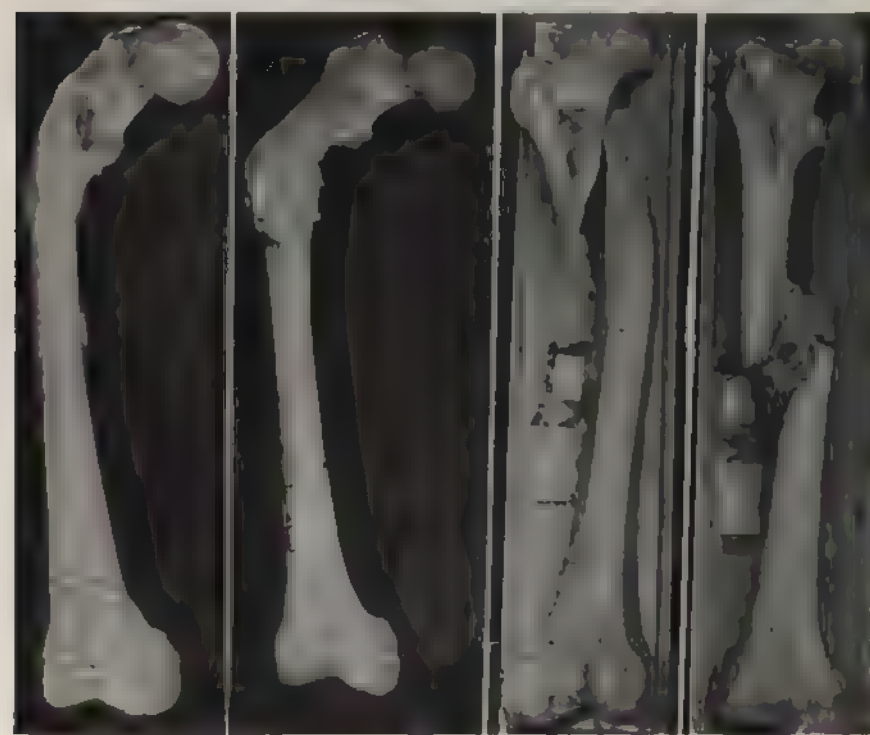

FIG. 640.—Femur. Fracture through trochanters; union has taken place with shortening, angulation, and outward rotation of the lower fragment. (Wister Institute of Anatomy.)

FIG. 641.—Femur, right, fracture of the upper shaft. Union with anterior angular deformity. The fracture occurred at the junction of the middle and upper thirds and was probably nearly transverse. The psoas magnus and internal adductor muscles have elevated the end of the upper fragment 55 degrees so that the bones have united with great anterior deformity. The lower fragment has passed upward and backward. There is no outward rotation of the lower fragment. (Mutter Museum, No. 1397.035.)

FIG. 642.—Femur, right, fracture of the neck, trochanter major and shaft, recent. The injury was a severe one in which, while the trochanter was fractured by direct violence, the shaft was probably broken by twist, leverage being obtained at the knee. The upper fragment consists of the head, neck, trochanters and a portion of the outer shaft, terminating in a point. Passing from this point 13 cm. below the great trochanter we trace a line passing sparely upward and backward. Looking on the external surface of the great trochanter, a V-shaped fracture is seen. (Mutter Museum, No. 1397.041.)

FIG. 643.—Femur, right, transverse fracture of middle shaft. Recent union. The fracture occurred just above the middle. The lower fragment passed upward to the inner side and slightly backward. The shortening amounts to 5 cm. The lower fragment has rotated outward 20 degrees. (Mutter Museum, No. 1397.055.)

short and long adductor muscles, the lower end of the upper fragment is drawn inward and forward and the lower fragment is displaced upward, outward, and backward. In fractures of the lower third the

lower end of the upper fragment is drawn inward and forward by the adductors and extensor muscles, and the lower fragment upward and backward by the flexor muscles. At times the upper end of the lower fragment is also rotated backward by the action of the gastrocnemius muscle.

Other symptoms present are pain, localized tenderness on pressure, swelling, ecchymosis, and muscular spasm. Early effusion into the

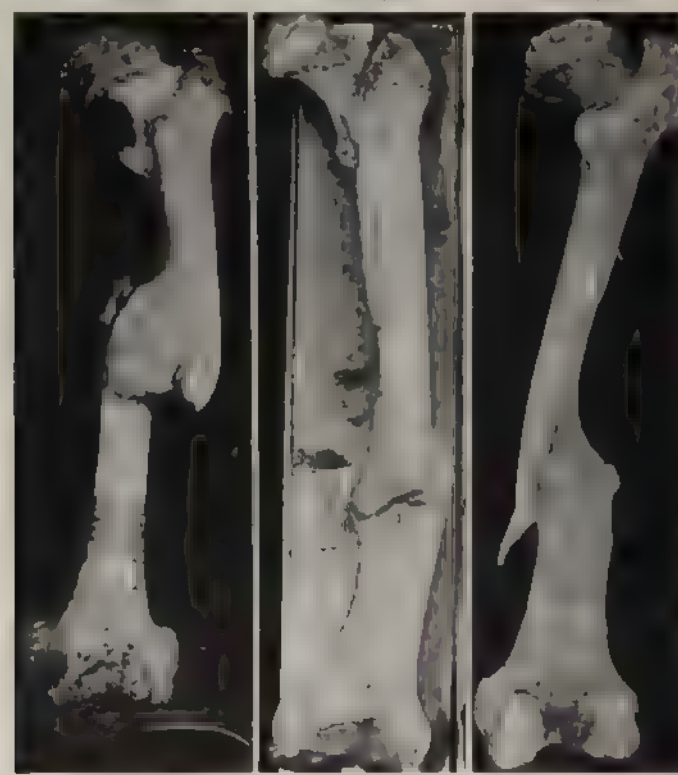

FIG. 644. FIG. 645 FIG. 646

FIG. 644.—Femur, left. Fracture of the middle shaft. There is great shortening and anterior angular deformity. Sharp prominence of the upper fragment. (Mutter Museum, No. 1397-058.)

FIG. 645.—Femur, left, fracture of the lower shaft, union with deformity. The fracture occurred at the junction of the middle and lower third and was probably nearly transverse. The lower fragment points inward 10 degrees but has not rotated. It has passed upward and backward and has united firmly. The upper fragment presents a prominence anteriorly where the lower fragment projects on the outer side. The inner side of the line of junction is grooved. (Mutter Museum, No. 1397-071.)

FIG. 646. Femur, fracture of the shaft, junction of the middle and lower thirds. Union with marked deformity, consisting of overriding and inward rotation of the lower fragment, and the formation of exuberant callus as a spur from the lower end of the upper fragment. (Wister Institute of Anatomy.)

knee-joint is often present in fractures of the lower third of the shaft.

Complications.—In fractures of the upper and middle thirds of the shaft, complications are rare. In fractures of the lower third they are occasionally present. Puncture of the muscles and skin by a sharp-pointed fragment may cause the injury to be an open one. The pre-

patellar bursa may at times be penetrated. Vessel injury, such as rupture or compression of the femoral artery or vein with resulting hemorrhage, aneurism, or gangrene, may happen. Nerve injury is extremely rare from shaft fractures, but occurs to the popliteal or peroneal nerves in condylar or supracondylar breaks.

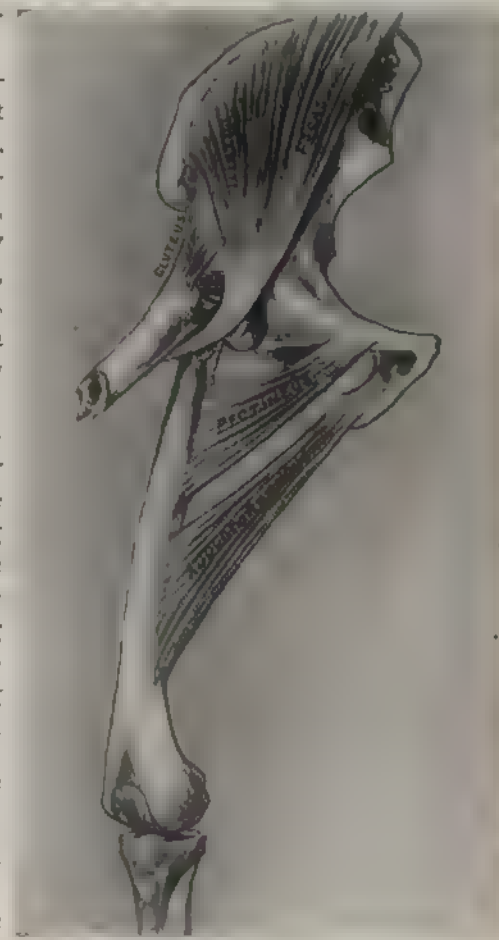

FIG. 647.—Drawing to show type of displacement which may occur in fractures of the upper third of the shaft of the femur. (Made after röntgenogram, Fig. 624.) The upper fragment is pulled upward, forward and outward by the action of the iliopsoas and gluteus medius and minimus and the lower fragment is pulled upward and inward by the quadratus femoris, the biceps and adductor muscles.

Prognosis. — The prognosis in fractures of the shaft of the femur is, as a rule, favorable. Union occurs ordinarily in six to ten weeks, after which time patients may be allowed up on crutches, provided the line of fracture is supported by a plaster spica dressing from waist to below knee, or by a suitable brace. The weight-bearing in walking should be prohibited for four or five months from the time of injury. The arching forward of the shaft of the normal femur should not be forgotten in reconstructing the bone after fracture. Little permanent shortening should follow well-treated fractures of the femur if perfect anatomical apposition of fragments is obtained. This, as a rule, cannot be obtained by non-operative means, except in the most favorable cases. Such absolute reconstruction of the length of the bone is not extremely important. Shortening is the rule in oblique, spiral, comminuted fractures and in fractures uniting in a position of over-riding or angulation. This may vary from a fraction of an inch to several inches. If, however, union is obtained with the fragments in good alignment, without rotary displacement, a shortening of even three-quarters to an inch will cause little limp in gait, and can be considered as a good functional result by non-operative means. A slight addition

to the heel of the shoe or a pad of leather within the shoe under the patient's heel will correct the limp and prevent lateral spinal deviation.

When these fractures are subjected to operative fixation, there should be no shortening angulation or rotary displacement, unless the fracture is comminuted or local necrosis of bone follows operation.

Fig. 648. Fig. 649



Fig. 648.—Fracture of the middle of the shaft of the femur in childhood. Note overriding and angulation of fragments and outward rotation of the lower fragment.

Fig. 649.—Drawing to show the action of the thigh muscles in causing displacement of fragments. (Made after roentgenogram Fig. 648.)

Union as a rule is delayed by operative fixation. In stout people and in the aged the possibility of hypostatic pneumonia, bed-sores, and fat embolus should always be considered.

Effusion into the knee-joint is usual in fractures of the lower third and is the result of the primary violence, the penetration of the joint cavity by sharp fragments of bone, or the extravasation of blood at the

time of fracture. It may occur shortly after the time of injury and may be serous or sanguineous in character. Another form of effusion is that seen when the patient begins to use the knee-joint after convalescence. The effusion is the result of strain of use upon atrophied and quiescent structures about the joint. Œdema of the leg is due to change of position, muscular activity, or to partial venous or lymphatic obstruction at the seat of fracture.

Muscular atrophy, the result of disuse, may persist for some time, while rigidity of the knee may be persistent, particularly in the aged and rheumatic. These sequels often may be averted if early passive and active movements and very careful massage are employed daily or two or three times a week from the beginning of treatment, following the advice of Lucas-Championnière. Hence the defect of prolonged absolute immobilization.

Pseudo-arthrosis is occasionally seen as the result of over-riding of fragments, failure of reduction, interposition of soft parts, faulty immobilization of fragments, operative necrosis, and general systemic diseases. The most frequent cause of poor functional results are failure of reduction, allowing shortening, angulation, rotary displacement, faulty immobilization, exuberant callus, muscular atrophy, stiffness of knee-joint and pseudo-arthrosis.

Treatment.—In the treatment of fractures of the shaft of the femur the method of procedure will depend in a great measure upon the site and the line of fracture, the amount and direction of displacement of fragments, and the age of the patient. Operation and direct fixation of fragments usually give good results in fractures of the shaft of the femur, provided the operator be experienced and have a perfect aseptic technic. They overcome many of the difficulties attendant upon non-operative treatment in difficult cases. This is particularly the case in the fractures of the upper and lower thirds of the bone with marked displacement of fragments. In healthy adults, in whom operation is not contraindicated, this form of treatment would be the choice for fractures in which there is grave difficulty in reduction or in maintaining reduction by non-operative means. Unfortunately the depth of the femur and the strong muscles surrounding it make the operation a difficult one for the occasional operator, and greatly increase the risk of septic complications.

In those cases in which good results reasonably may be expected by non-operative measures, the exact method of retaining the apposition of fragments will be selected according to the site of the fracture. In the majority of cases the reduction of fragments and the application of immobilizing apparatus should be performed under general anæsthesia. The omission of the anæsthesia has been the explanation of many bad anatomical results and has caused the ope-

rative fixation to obtain many advocates. The patient's bed should have a level, firm mattress, which should be additionally supported by several flat boards placed under it running across from the sides of the bed. A wire spring mattress, indeed any form of spring mattress, is an almost inexcusable error.

In many fractures of the shaft, reduction may be accomplished readily by immediate traction and counter-traction, especially if general anæsthesia be used. This is particularly so in transverse and oblique fractures. The pelvis and upper part of the thigh should be held firmly by one assistant, while another makes prolonged and steady traction by grasping the foot and leg with both hands. The surgeon meanwhile endeavors to obtain complete reduction by manipulation. In fractures of the upper third or at the junction of the upper and middle thirds, it will often be necessary to elevate the leg and knee so as to bring the lower fragment in a line with the upper, which may be flexed and abducted by the iliopsoas and the gluteus medius and minimus muscles. In fracture of the lower third, flexion at the hip and knee with steady traction on the flexed leg will generally result in reduction. When there is impalement of the muscles upon the sharp end of a fragment they may be freed by rotation of the fragment. If not thus released, an incision may be required to accomplish this object. After the fracture has been reduced and the ends of the fragments engaged, so as to make the coaptation perfect or nearly so, an immobilizing dressing is to be applied while the patient is relaxed and free from spasm and pain by the anæsthetic.

Various forms of immobilization apparatus may be used to maintain proper reduction of fragments. The one that has the greatest field of usefulness is the modified Buck traction apparatus. It is very satisfactory in fractures of the middle third, of the upper third, when there is little tendency toward flexion and outward displacement of the lower end of the upper fragment, and in fractures of the lower third where the upper end of the lower fragment is not drawn backward. It is applied in the following manner: The leg and thigh are cleansed with soap and water, shaved, and bathed with alcohol and ether. After reduction of the fracture, two strips of rubber adhesive plaster three inches in width and long enough to extend from a point four inches above the seat of fracture to six inches below the foot are smoothly applied along the middle of the internal and external surfaces of the leg and thigh from above the seat of fracture. The malleoli are protected by several layers of a flannel bandage, and three circular strips of plaster one and one-half inches wide are applied circularly almost completely around the limb; one is placed two inches above the malleoli, one below the knee, and the third just below the seat of fracture. Instead of the three circular strips, reinforcement of the lateral strips

may be secured by strips of plaster two inches in width applied diagonally from two inches above the malleoli to the seat of fracture.

Two ends of the longitudinal strips are secured to a spreader or stirrup, made of wood three inches wide, four and a half to five inches long, and perforated at its centre by a hole for the traction rope (Fig. 650). The adhesive dressing is covered by a bandage from just above the malleoli to the level of the upper end of the lower fragment. The ends of the traction strips of plaster are then turned down over the inner layers of bandage, and the bandage carried upward almost to the hip. A posterior or ham splint of wood or metal, well padded, is placed posteriorly, extending from the upper level of the thigh to two

FIG. 650.—Method of applying Buck's traction apparatus. Adhesive plaster spreader to keep pressure from the malleoli; a padded posterior splint to keep the heel from the bed. This dressing should be supplemented by a Liston or T-splint or by sand-bags to steady the extremity.

inches above the calcaneum, and is secured with three strips of adhesive plaster (Fig. 651). This splint is only occasionally needed if the bed is level and firm and a soft pillow is placed under the popliteal space. Coaptation splints to surround the thigh on the internal anterior and external surfaces are applied and held in place by three strips of adhesive plaster or webbing straps. An internal splint is applied, from one inch below the perineum to one inch above the internal malleolus, and a long splint from the mid-chest region to a point two inches below the sole of the foot. These two splints are secured to the thigh and leg by webbing straps, and the external splint is held to the chest wall by a wide swathe, and a similar one is placed about the splint and pelvis (Fig. 652). In applying this apparatus care should be taken to see that the inner surface of the first

metatarsal, the middle of the patella, and the anterior superior spine of the ilium are in a straight line and the foot is not too much everted. After its application the patient may be placed on a Bradford

FIG. 651.—Second stage of the method of Buck's traction apparatus. A cotton roller bandage has been applied from the malleoli to the lower third of the thigh is surrounded by several layers of sheet-wadding and adaptation splints have been applied to the thigh. Sometimes the adaptation splints may be omitted or a gypsum-gauze contour trough substituted. If the fracture is reduced even before applying the dressing, this is essential in the case.

FIG. 652.—The dressing is completed by an internal splint, a Liston or T external splint, a body swathe to hold the upper end of the splint against the pelvis, and bed-blocks to elevate the foot of the bed.

frame, the foot of the bed elevated eight inches or more, a pulley attached to the foot of the bed, over which is carried the rope, connected with the spreader. To the end of the rope from fifteen

to thirty-five pounds weight should be added for keeping up traction on the thigh muscles. Counter-traction is obtained by the weight of the patient; and if this is not sufficient perineal straps connected with the head of the bed may be used. A bed-cradle should be placed over the patient's legs to keep the weight of the bedclothing off the feet.

This form of apparatus requires constant supervision. Care should be taken to see that traction is constant, that over-riding of fragments has not recurred, that outward or posterior angulation at the seat of fracture is prevented, and that inward or outward rotation of the leg and lower fragment is not present. This supervision is more likely to be maintained and deviations at the point of break discerned if the internal lateral splint, the Bradford frame and the Liston external splint are omitted and boxes of bricks or good sand-bag support used instead. This change is permissible in the opinion of one of the authors in many instances. The omission of these adjuncts permits the more frequent application of light massage and passive motion to the muscles and joints. These manipulations are believed to be valuable adjuncts to restoration of function.

In ordinary fractures of the shafts of the femur, this modified Buck apparatus should be followed by a good result, and union should occur in from seven to nine weeks. The apparatus should then be removed and replaced by a plaster spica including the pelvis, thigh and part of leg, and the patient gradually allowed up on crutches with a high shoe on the well foot. Weight-bearing should not be allowed for three to five months from the time of injury. The time depends somewhat upon the body weight of the patient and the type of fracture. A more comfortable form of ambulatory immobilization is some form of convalescent, but expensive, hip splint (see Fig. 659).

In fractures of the upper third with the lower end of the upper fragment in a flexed position and in abducted rotation, it is often impossible to maintain reduction by horizontal traction. It is then necessary to bring the lower fragment in line with the tilted upper one, maintain the two fragments in this position, and use traction to prevent over-riding of fragments (Fig. 623). This may be accomplished by traction applied to the thigh partially flexed at the hip and encased in a plaster-of-Paris spica, which includes the pelvis, thigh, leg, and foot. The gypsum case is applied with the thigh in flexion, with slight abduction and some outward rotation with the leg flexed about 45 degrees on the thigh. This dressing is used for from at least four to six weeks; after this time it may be replaced, if union and position are good, by a plaster spica in the extended position without traction. After ten weeks the patient may be allowed to be out of bed on crutches, and weight-bearing may be permitted at the end of four months. If for any reason it is not considered advisable to use this

form of apparatus, fair results may occasionally be obtained by the carefully watched double inclined plane with traction from the thigh, or the Smith or Hodgen anterior wire splint combining suspension with traction. Fractures in this region, if wisely treated, generally give fair functional results, but there is quite often some shortening and angulation unless they are treated by open operation.

Fractures of the lower third of the femur are not all characterized by posterior displacement of the upper end of the lower fragment. In fractures without this posterior displacement of the lower fragment, good results may be obtained by the use of the already described Buck traction apparatus.

Comminuted fractures of this region are best treated by the same dressing. When there is posterior displacement of the upper end of the lower fragment and it is found impossible to retain the fragments in good position, tenotomy of the Achilles tendon may be performed, if it is thought that the displacement is due to the pull of the gastrocnemius muscle. Good position may also be obtained by the use of a plaster spica dressing including the pelvis, thigh, leg and foot, applied with the thigh and leg in a position of flexion, and the use of traction from the lower part of the thigh and by the use of traction applied with the hip- and knee-joints flexed (Fig. 623). In all adult cases the normal anterior convexity of the femur, marked in muscular subjects, should not be forgotten when applying support posteriorly.

Robert Jones highly recommends the use of the Thomas knee splint for all fractures of the shaft of the femur. He is persuaded the fault lies not in the way the fracture is set in the first instance, but in the fact that the thigh muscles subsequently contract and produce too much movement of the fragments with over-riding and shortening. He believes that if weight and pulley traction be used, as in Buck's method, the muscles of the thigh are suddenly relieved of tension every time the patient moves his body, and thereupon contract. In his opinion a rigid system of extension should be adopted, which results in muscles ceasing to resist in from twenty-four to forty-eight hours. His method is to fix the broken limb in a rigid apparatus from pelvis to foot, which gives traction and counter-traction; then the patient can be moved, lifted, and nursed without the slightest fear of muscular action telescoping the fragments. Thus starting pains are unknown and the alignment of the thigh is as nearly perfect as possible. A properly applied Bradford frame may meet Jones's requirements.

The difficulties met in children in the treatment of fractures of the shaft of the femur are the frequency with which dressings are soiled by urine and fæces, liability to excoriations, and the ease with which dressings become displaced. Fracture dressings suitable for adults are consequently not always available. These troubles may be obviated



FIG. 653.

FIG. 654.

FIG. 655.

FIGS. 653, 654, AND 655.—Vertical extension for the treatment of fractures of the femur in children. Fig. 653: Adhesive plaster traction, overhead traction, weights and Bradford frame. Fig. 654: Cotton bandage applied from the malleoli to the lower thigh, thigh surrounded by sheet-wadding layers and by coaptation splints and straps. Swathe to hold patient still upon Bradford frame is padded about frame and abdomen of the child. Fig. 655: Method of slowly decreasing the angle at the hip-joint after union has occurred.

and good anatomical and functional result obtained by the Bryant vertical traction method (Figs. 653–658). Adhesive plaster strips, an inch or more in width, are applied from the point of fracture to

FIG. 656.

FIG. 657.



FIGS. 656 AND 657.—Another method of vertical extension by Bryant's method for fracture of the shaft of the femur, which may be used, as may that shown in other figures, in adults as well as children.

one inch above the malleoli and continued two inches below the foot, where they are placed over a wooden perforated spreader three inches in length and about one inch in width. These strips are supplemented

by three circular strips two inches in width, one at the seat of fracture, one below the knee, and the third one and a half inches above the malleoli, and by two one-inch straps applied diagonally from above the malleoli to the seat of fracture. This dressing is covered by a flannel bandage from above the malleoli to the upper limit of the thigh, and the entire thigh surrounded by coaptation splints held in place by three webbing straps applied at the two extremities and middle of the splint. A thin rope is passed through the hole in the spreader and through the pulley of the overhead traction gallows, and sufficient weight used to just lift the gluteal region of the affected side off of the bed. Traction should be in a vertical direction. The coaptation

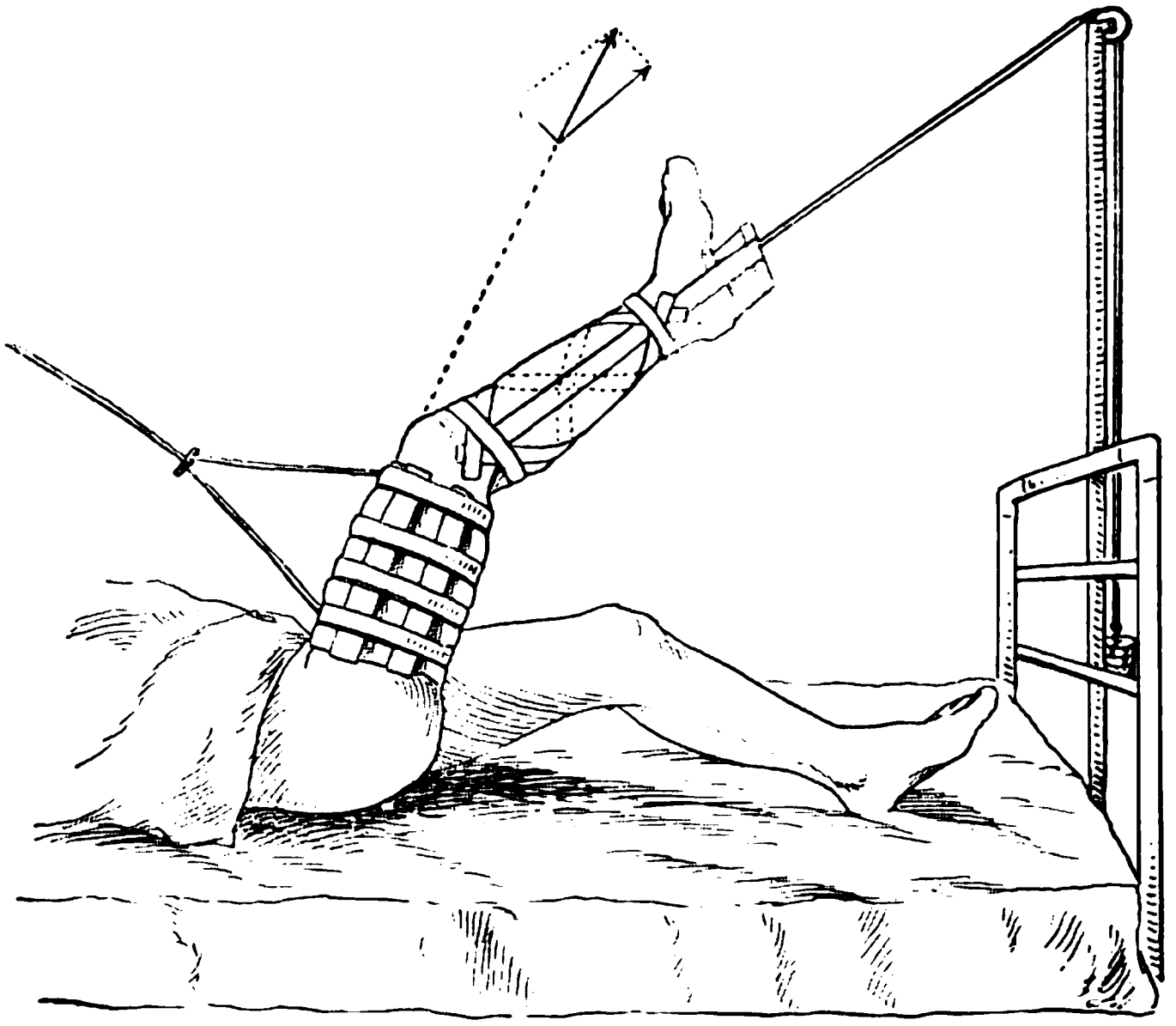

FIG. 658.—Christen's suspension method for treatment of fractures of the shaft of the femur in children.

splints are often unnecessary. The patient is then placed on a Bradford frame and held to it by a swathe including the chest and abdomen. The Bradford frame may often be omitted. This method of traction gives very satisfactory results in children up to ten or twelve years of age, and may be used for fractures of all parts of the shaft of the femur. Attention should be paid to the parts so as to prevent sagging of the leg and inward or outward rotation below the seat of fracture. Excoriations about the malleoli and buttocks should be avoided, and the coaptation splints should be readjusted from time to time. At the end of six to seven weeks the angle of traction may be slowly lowered, so that in the course of a week the horizontal position is attained, after which time a plaster spica including pelvis, thigh and leg, may

be applied and the patient allowed on crutches. Weight-bearing may be started at the end of twelve to fourteen weeks. During late convalescence an ambulatant hip splint should be used (Fig. 659).

Results.—The report of the Committee on Treatment of Simple Fractures of the British Medical Association shows the following results: Non-operative: upper third of femur in 3 cases, good anatomical and good functional results in 3 cases; middle third 27 cases. good anatomical and good functional results in 25 cases; lower third, 2 cases, good anatomical and good functional results in 1 case. Average duration of incapacitation, number of cases in which period was stated in fractures of shaft or femur 196 cases, average number of weeks of incapacitation 16.5 under fifteen years; over fifteen years, number of cases 179, number of weeks of incapacitation 33.6, and number of cases in which incapacitation was permanent 21,—11.7 per cent. The number of operative cases was so small that comparison was not possible. A consideration of the good results of the upper middle and lower thirds according to age periods was as follows: upper third, under fifteen years, 95 per cent.; between sixteen and forty-five years 70 per cent., and over forty-five years 31 per cent.; middle third, under fifteen years 97 per cent., sixteen to forty-five years 58 per cent., over forty-five years 32 per cent.; lower third, under fifteen years 94 per cent., sixteen to forty-five years 68 per cent., and over forty five years 40 per cent. Some statistics on this point from the Report of the Committee of the American Surgical Association will be found in Chapters I and II.



FIG. 650. Convalescent splint to be used in the treatment of fractures of the femur when the patient is first allowed up. Should be used with crutches. If the injured limb is raised from the ground in this manner by the thick sole shoe on the well limb, and the patient kept on crutches when walking, the splint need not be employed to protect the recently broken femur. A gypsum encasement is cheaper.

It is the belief of one of the authors that British surgeons have obtained poorer results in the non-operative treatment of fractures than is the case where long immobilization is less the rule than in Great Britain. Prolonged immobilization is, he believes, a mistake in fracture treatment, as it prevents frequent examination and readjustment of fragments; and tends to articular rigidity and muscular atrophy from which convalescence is slow.

Fractures of the Lower End of the Femur

Fractures of the lower end of the femur are of interest on account of their comparative rarity and the complications that may be present. The line of fracture may be in the shaft just above the condyles, the supracondylar fracture; at the same time this line may connect with one

Fig. 660. Fig. 661.

Fig. 660.—Supracondylar fracture of femur. Note the posterior displacement of the upper end of the lower fragment.

Fig. 661.—Drawing to show the pull exerted by the gastrocnemius muscle in producing posterior displacement of upper end of lower fragment. (Made after rontgenogram, Fig. 660.) The liability to injury of the popliteal vessels and nerve is shown.

running down between the condyles, separating them, causing intercondylar T- or Y-fracture. Either the internal or external condyles may alone be separated from the remaining portion of the bone, or there may be a complete separation of the lower epiphysis of the

Fig. 662.

Fig. 663.

Fig. 662.—Comminuted supracondylar fracture of the femur.
Fig. 663.—Comminuted supracondylar fracture of the femur. Note over-riding of fragments and callus formation.

Fig. 664.



Fig. 665.



Fig. 664.—Supracondylar fracture of the femur. Union with lateral, over-riding and rotary deformity.
Fig. 665.—Comminuted supra-intracondylar fracture of the femur. Anteroposterior view. (See Fig. 666.)

femur. The last condition is only observed before the twentieth year. Another rare form of fracture is the separation of small cortical portions of bone from the surface of the internal or external condyle due to strain on the ligaments, the so-called "spram-fracture." The most typical fractures are the oblique fractures of one or both condyles and the irregular T- or Y-fractures, in which the two condyles are separated from each other and from the shaft of the bone.

Supracondylar and Intercondylar Fractures (Figs. 660–669). Simple supracondylar fractures differ but little from low fractures of the lower third of the femur, except in the position of the line



Fig. 660.—Comminuted supracondylar fracture of the femur. Lateral view. (See Fig. 665.)
Fig. 661.—Supracondylar fracture of the femur in a child aged 3 years.

of fracture, and will not be here differentiated. When, however, they are associated with a split of the lower fragment by a fracture line running from the transverse line through the intercondylar notch, the clinical picture is entirely different.

Etiology.—The cause of intercondylar fractures is severe violence, either direct or indirect, such as a blow upon the knee, a fall upon the knee from a height, or perhaps a violent impact with torsion transmitted from foot to femur. The mechanism of fracture is that the splitting of the lower fragment results from the wedge-like action of the lower end of the upper fragment separating the lower fragment into two or more parts and producing the typical T- or Y-shaped fracture. The line of fracture across the shaft is generally oblique, though

at times transverse, and that of the lower fragment is more or less vertical and in an anteroposterior plane. Comminution of fragments may be present, and the lower end of the upper fragment may pierce

FIG. 668 FIG. 669.



FIG. 668.—Femur, right; fracture of the lower shaft. Union with anterior deformity and shortening. The fracture occurred 8 cm. above the joint and was nearly transverse. The lower fragment passed backward, upward and to the outer side, and union has occurred in that position. (Mutter Museum, No. 1397.079.)

FIG. 669.—Femur, left, comminuted intercondylar fracture. Union with deformity (plaster cast). The condyles are split so that the outer fragment is the smaller. The shaft was broken obliquely immediately above the condyles, from behind, downward and forward, the fragments compressing the condyles passing upward and backward. The lower portion of the shaft was split. A fragment 17 cm. long, composing nearly the entire thickness of the shaft, has united in a bad position. It points downward and outward and presents an anterior prominence. In its union with the condyles the latter has rotated outward 30 degrees. (Mütter Museum, No. 1397.069.)

the soft parts and produce an open fracture. The lower fragments are displaced posteriorly and latterly.

Symptoms.—The symptoms of intercondylar fractures are loss of function, false motion, bony crepitus, widening of the condylar region, separate mobility of the two condyles, at times the sinking in of the

patella between the two condyles, shortening of the extremity, and prominence of the lower end of the upper fragment anteriorly. Sometimes fixation in, and at times puncture of, the soft parts by a sharp upper fragment occurs. In addition there are great swelling, ecchymosis, joint effusion or hemorrhage, and local evidences of direct injury to the soft parts.

Complications.—The complications of intercondylar fracture are injury to the popliteal artery and vein, the internal and external pop-



FIGS. 670 and 671. Fracture of internal condyle of femur. Anteroposterior and lateral views.

liteal nerves (Figs. 670 and 671), and perforation of the soft parts by sharp fragments of bone.

Prognosis.—The prognosis in these cases is serious as regards life and function. Hennequin, according to Stimson, collected 26 cases of this variety, of which 16 recovered, 7 died, and 3 required amputation. The degree of functional restoration will depend upon the perfection of reduction of fragments, the character of fragmentation, and the subsequent amounts of callus formed. Cases in which good apposition of fragments is secured without widening of fragments and little joint callus, should be followed by fair functional result.

Treatment.—Intercondylar lesions call for thorough reduction of fragments. General anæsthesia should be used, and reduction accom-

plished by steady traction combined with manipulation and lateral pressure. The suggestion of F. Cortors, that theoretically mutual impaction of the condylar fragments with mallet and sand-bags is indicated after the best practical reduction has been obtained, may be of some use in lessening the subsequent production of intra-articular callus. A bone peg or a metal nail might be subcutaneously driven through the condyles to hold them together. Retention of fragments in their normal position may best be accomplished by the Buck traction apparatus, combined with posterior internal and external lateral

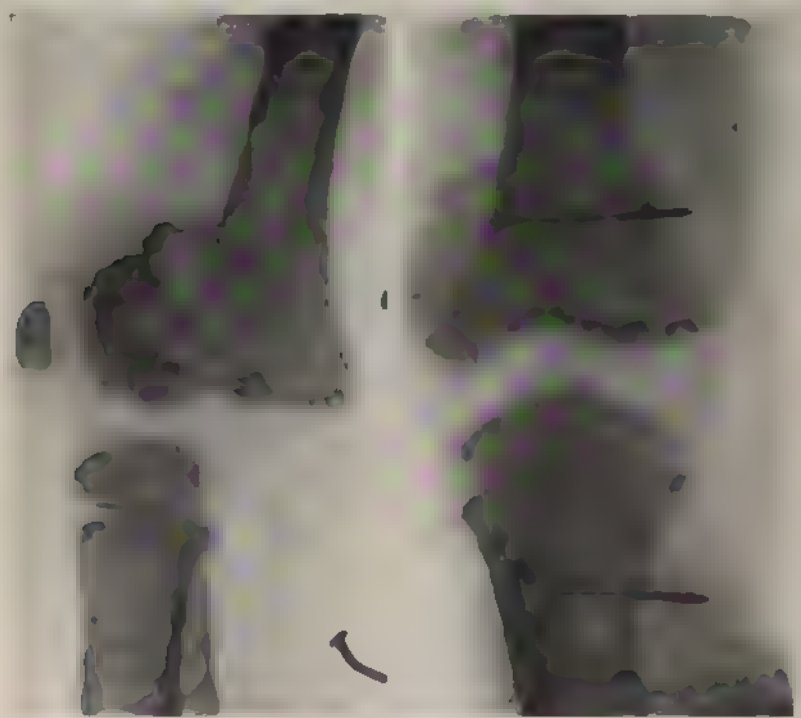

Fig. 672.—Separation of the lower femoral epiphysis. Lateral and antero-posterior views. Characteristic deformity with the lower end of the diaphysis displaced posteriorly. Before reduction. (See Fig. 673).

splints, and from ten to twenty pounds of weight. The suggestion of Robert Jones that the Thomas knee splint be used is worthy of thoughtful consideration. Immobilization should continue for six to eight weeks, followed by the use of a suitable leg brace or gypsum-gauze encasement. When there is marked tendency toward displacement, traction should be made with the hip- and knee-joints flexed.

Fractures of Either Internal or External Condyles (Figs. 670 and 671).—Fracture of a single condyle is a very rare injury. Very few cases have been reported.

Etiology.—These fractures may be the result of direct violence, and usually are due to forced abduction or adduction of the knee, to a twisting of the leg, or to direct force transmitted through the head of the tibia toward the involved condyle. The line of fracture is usually oblique, running upward from the intercondylar notch for a considerable distance, producing a sharp spear-pointed fragment; the line may be very short and end just above the condyle, or at the edge of the articular cartilage.

Symptoms.—The symptoms consist in localized pain, tenderness, swelling, ecchymosis, effusion into the knee-joint, a valgus or varus



FIG. 673.—Separation of the [illegible] epiphysis. Lateral and anteroposterior views. Fragments reduced. (See Fig. 672.)

position of the leg at the knee-joint, crepitus, and at times a moderate degree of displacement posteriorly and upward of the detached fragment.

Prognosis.—The degree of function will depend upon the accuracy of reduction and the amount of intra-articular callus. Function may be expected to be somewhat impaired.

Treatment.—Reduction may generally be accomplished by restoring the leg to its normal axis with the thigh, thereby controlling the position of the detached fragment by the action of the lateral ligaments. Immobilization should be obtained by a posterior splint with a

pad placed above the fractured condyle and pressure by adhesive plaster. If there is little displacement of the fragment the extremity may be immobilized in a plaster dressing. At the end of three to six weeks passive motion may be begun, and at the end of twelve to sixteen weight-bearing may be carefully attempted.

Separation of the Lower Femoral Epiphysis.—The lower epiphysis of the femur includes the entire articular surface of the lower end of the bone. It is the largest epiphysis of the body, and unites with the diaphysis from the twentieth to the twenty-first year. Traumatic separation of the epiphysis is most frequently observed about the tenth to twelfth year of life.

FIG. 674.—Femur; separation of lower epiphysis. Shows normal epiphyseal lines of tibia and fibula. Case of Dr. R. H. Harte. (Mütter Museum.

Etiology.—Separation of the lower femoral epiphysis results from great violence (Figs. 672-674), and as a result of abduction or hyperextension of the knee. The most frequent cause is the catching of the leg in the spokes of a rapidly revolving wheel.

The line of separation definitely follows the epiphyseal cartilage, to which is at times attached small fragments of the diaphysis. At times considerable stripping of the periosteum of the diaphysis occurs. The lesion, by reason of the violence required to produce it, may be complicated with an open wound. The usual deformity is an anterior and lateral displacement of the epiphysis with, at times, rotation of the epiphysis upon a bilateral axis. This is considered by some authorities to be due to the pull of the gastrocnemius muscle inserted on the diaphysis, but in all probability it is due to the primary violence plus the pull of the extensor thigh muscles.

Symptoms.—The symptoms of separation of the lower femoral epiphysis are the history of injury, great swelling, tenderness, and signs of severe local injury about the knee-joint, abnormal mobility at the knee-joint, soft cartilaginous crepitus when it is possible to bring the fragments into contact, marked deformity, and loss of function.

The condition should be distinguished from supracondylar fracture and dislocation of the knee-joint. In supracondylar fracture crepitus is bony in character, the line of fracture is above the adductor tubercle,

while in dislocation the disturbed relation of the tibia with the femur will generally be evident. In no other fracture is a radiogram of more importance for the determination of the exact lesion present. Examination and reduction should be made under general anæsthesia.

Complications.—The complications of epiphyseal separation are rupture or compression of the popliteal artery or vein, injury to nerves, and external wound causing an open fracture. Rupture of vessels may be incomplete, with resulting aneurism, while complete laceration of the vessels may give rise to severe hemorrhage and pressure gangrene. Contusion or pressure of the vessels may result in gangrene, and less frequently in thrombosis. Especial attention should be given to the color of the limb below the seat of fracture, and the presence or absence of pulsation below the seat of injury in the popliteal and tibial arteries should be carefully noted.

Prognosis.—If reduction of the displaced epiphysis is readily accomplished, apposition of fragments maintained, and no vessel injury be present, union should be prompt and functional recovery perfect. From the lack of reported cases it is evident that separation of the epiphysis is not often followed by failure of subsequent development and shortening of the limb. When the epiphyseal separation is accompanied by laceration of large vessels, amputation is often a necessary result.

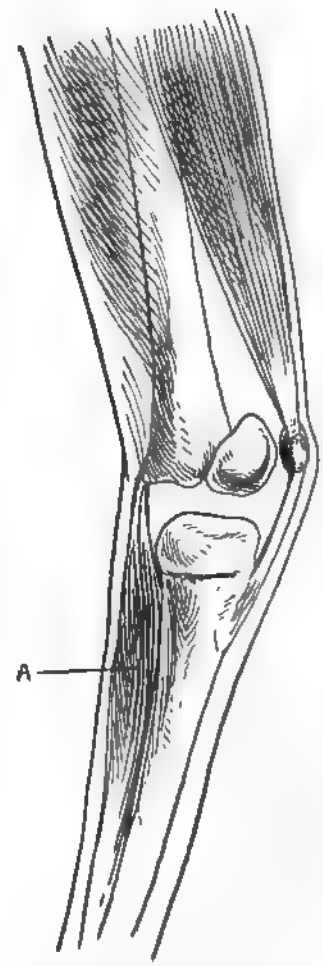

FIG. 675.—Separation of the lower femoral epiphysis. Drawing made after röntgenogram. (Figs. 672 and 673). Note the pull exerted by the gastrocnemius muscle, *A*, in producing posterior displacement of the lower end of the diaphysis.

Treatment.—In anterior displacement of the epiphysis, reduction may usually be accomplished under anæsthesia, by flexion of the thigh and leg. An assistant should make steady traction on the flexed leg in a line downward and at right angle to the long axis of the femur. The surgeon then grasps the lower portion of the thigh with the fingers of both hands in the popliteal space, and with the thumbs presses downward and backward on the epiphysis. This manipulation should be done at once, if there is evidence of pressure on the popliteal vessels; when reduction is accomplished, the leg may be brought into position

of partial extension and immobilized on a posterior splint, gypsum, gauze, wood or metal, or in a gypsum moulded encasement (Figs. 675 and 676). Usually there is no tendency toward displacement after reduction is accomplished, as the rough surfaces of the broadened end of the diaphysis and the epiphysis tend to remain engaged. If reduction tends to recur, the leg should be held flexed on the thigh at right angles and immobilized in a plaster dressing. When reduction cannot be accomplished by conservative measures, an incision should be made on the external surface and reduction accomplished by leverage combined with manipulation.

In lateral and posterior displacements, reduction can usually be accomplished by flexion, manipulation, and traction. Reduction is evident by the assumption of normal contour, soft crepitus at the time of reduction, and loss of tendency to recurrence. Union occurs in from

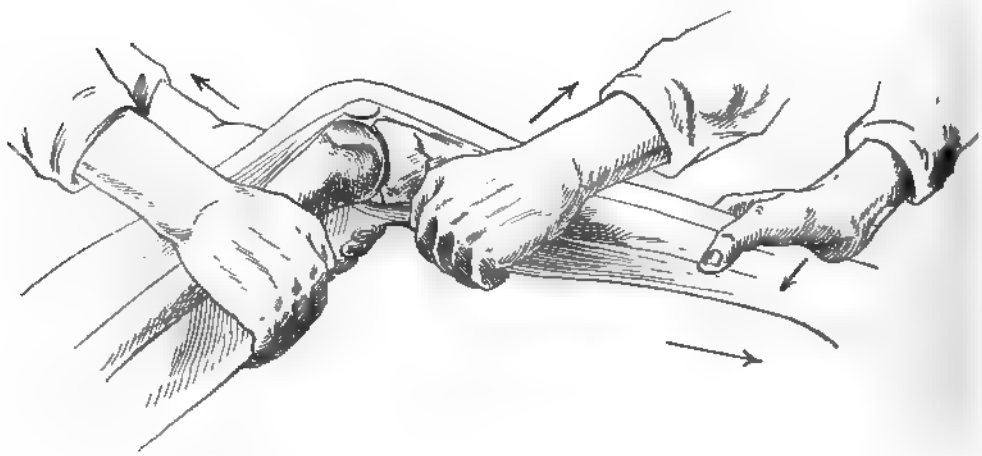

FIG. 676. Method of reduction of separation of the lower epiphysis of the femur.

four to six weeks. After this time a knee splint may be used, passive motion adopted, and weight-bearing allowed at the end of twelve to fourteen weeks.

If after open examination and reduction there is a tendency toward recurrence of the displacement, immobility should be obtained by direct fixation, preferably, perhaps, by a metal plate. As a rule, however, it is not advisable to use an internal method of fixation unless absolutely necessary, owing to the possibility of inducing necrosis and interference with the subsequent development of the epiphysis.

Sprain-Fractures of the Lower End of the Femur (Figs. 677 679).—This rather infrequent form of fracture is a tearing off of a small part of the cortex of the bone in the region of the internal epicondyle, the adductor tubercle or the external epicondyle, or at the attachment of the tendon of the adductor magnus, the tendons of the

Fig. 677. Fig. 678 Fig. 679.



FIGS. 677 AND 678.—Tear fracture of a part of the external condyle of the femur. Lateral and anteroposterior views.
FIG. 679.—Tear fracture of a part of the internal condyle of the femur.

gastrocnemius muscle, or at the point of attachment of the lateral ligaments.

Etiology.—While direct violence may be the cause of a few of these fractures, the majority result from strain brought upon the attachment of tendons and ligaments, and result in a tearing off of irregular portions of bone of varying size.

Symptoms.—The symptoms resemble those of a severe sprain of the knee-joint. There are severe pain, localized tenderness on pres-

FIG. 680.

FIG. 680.—Method of determining abnormal mobility in fracture of the external condyle of the femur by a forced varus position.

FIG. 681.

FIG. 681.—Method of determining abnormal mobility in fracture of the internal condyle of the femur by a forced valgus position.

sure, ecchymosis, and an effusion of serum or blood within the knee-joint. The patient complains of a considerable loss of function due to pain and the effusion; strain brought upon the attachment of the involved tendons by a forced varus or valgus position increases this pain (Figs. 680 and 681); at times crepitus is detected and the presence of a small movable fragment may become evident on painstaking examination. After union has taken place, there may develop, particularly when the fragment has been detached by the pull of the

adductor magnus tendon, an ossifying myositis of the involved tendon and muscle.

Prognosis.—After adequate rest and subsequent careful massage, function should be fully restored.

Treatment.—This consists almost entirely in immobilization in plaster or on a posterior splint for four to five weeks until union is firm. This should be followed by massage, baking, and passive motion, and later the patient should be encouraged to use the parts. On account of the smallness of the detached fragment open operation with direct fixation is rarely demanded.



FIG. 682.—Myositis ossificans traumatica following strain of adductor muscles. Note ossification in substance of adduction muscles at its point of attachment to the femur.

Occasionally after a sprain-fracture occurring at the region of attachment of the adductor muscles, ossification in the substance of the muscle (myositis ossificans traumatica) may occur. This is due to the deposit of bone cells from the detached periosteum (Fig. 682).

Summary of Non-operative Treatment

Firm, level mattress without springs.

Upper End of Femur.—*In aged*, handle with gentleness and care lest impaction be broken up. Do *not* attempt to obtain preternatural mobility or crepitus. Treat as fracture of neck, until X-ray or result disproves diagnosis, with Buck's longitudinal traction of about 6 to 10 lbs., and lateral support on both sides of injured limb. Some lateral traction below trochanter may be added.

When diagnosis of fracture of neck is established, continue same method if patient bears confinement in bed well. If patient loses ground in general health, treat patient rather than fracture and let him carefully assume sitting posture, even out of bed.

In Young or Middle Aged.—May cautiously endeavor to obtain crepitus and abnormal mobility, using little force, but not suddenly.

When X-ray confirms diagnosis and shows character of fracture lines, endeavor to reduce fragments and obtain proper coaptation by cautious flexion and full abduction, using general anæsthesia as an adjunct to the manœuvres.

Use Buck's longitudinal traction method horizontally or in abduction with stable counter-traction; lateral traction outwards below trochanter in addition may be wise; or Whitman's complete abduction method for both legs by means of a gypsum-gauze encasement, confining both sides from nipple line to below knees.

Shaft of Femur.—*Subtrochanteric.*—After reduction under ether and study of lines of break, put up fracture with hip partially flexed and the thigh somewhat everted and abducted to keep the upper and lower fragments coapted. Make traction in axis of thigh while in this posture by Buck's method with pulley placed high over lower part of bed, or with limb on an inclined plane, or with an anterior wire splint properly suspended to give traction in the needed direction.

A gypsum-gauze encasement, including lower chest, abdomen, both hips and thighs, the opposite thigh lying horizontal, may be added to the traction appliance.

Middle.—Reduction under ether, locking fragments if possible. Buck's longitudinal traction with sufficient weight—15 to 40 pounds, not omitting *stable* countertraction, and lateral support. Traction may need to be a little above the horizontal axis of the normal limb. Remember the anterior arching of the femur. Coaptation splints or encasing contour splint about the broken region of the shaft may be necessary, especially in comminuted or double breaks.

Lower End of the Femur including supracondylar. Reduction, Buck's longitudinal traction and lateral support. Perhaps posterior popliteal support with splint needed.

In all fractures of neck or shaft avoid weight bearing for several weeks after the union is believed to be solid.

CHAPTER XXII

FRACTURES OF THE PATELLA

Anatomy.—The patella is a flat, somewhat triangular sesamoid bone in the tendon of the quadriceps extensor muscle of the leg. It has two surfaces, the anterior, which is convex, roughened, and separated from the cellulo-integument of the front of the knee by a bursa, and the posterior or articular surface, covered by articular cartilage. The upper end or base is broad and gives insertion to the tendon of the quadriceps extensor muscle. The lower end or apex gives attachment to the ligament of the patella.

Surface Markings.—Relaxation of the extensor muscle allows palpation of the entire border of the patella, and furnishes a demonstration of its mobility. In flexion of the leg the patella is carried downward over the condyles; in extension it is carried upward, so that in extreme extension only the lower half of the patella is in contact with the condyles of the femur. Laterally there are sulci; and on flexion of the leg the articulating surfaces of the condyles may be palpated.

Statistics.—Plagemann's statistics from the Rostock clinic, based upon the radiographic study of 1393 fractures, showed the patella to be fractured in 35 instances (2.51 per cent.). Of these 35 cases, the fracture involved the upper third 5 times, the middle third 22 times, and the lower third 8 times. In 17 instances the fracture line was transverse; 2 times there was a superficial tearing out of the bone at the apex of the patella, and 4 times there was a fracture at the base of the patella with a separation of a three-cornered fragment at the attachment of the extensor tendon. In 9 cases the fracture line was transverse, with more or less penetrating longitudinal or oblique fissures, and in 2 instances there were typical stellate fractures. A clean longitudinal fracture was not observed during the preparation of this classification, although later he observed two of this character and also saw two subperiosteal fractures.

Etiology.—The etiology of the fractures in individual cases is often difficult to determine. Patients have difficulty in telling whether the fracture preceded the fall or was the result of it. Fractures of the patella are due to muscular action and to direct force. Fractures due to muscular action are occasioned by sudden and forcible contraction of the quadriceps extensor muscle, occurring during a mis-step in an effort to save oneself from falling, in the voluntary use of the leg, as in kicking or lifting a weight with the leg or back, or in resisting forced

flexion of the knee. The patient may attribute the fracture to a fall upon the knee when in fact the fracture preceded the fall and local

Fig. 683. Fig. 684.



Fig. 683.—Incomplete transverse fracture of the patella.
Fig. 684.—Transverse fracture of the patella, lower third.

Fig. 685. Fig. 686.

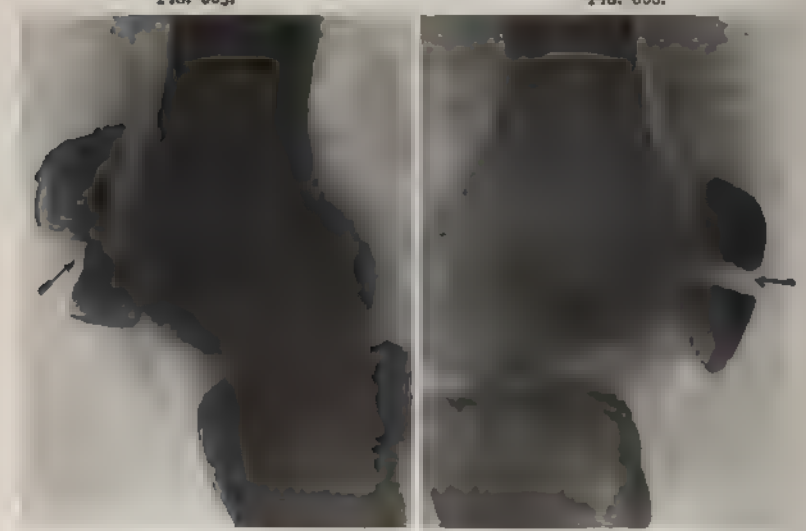

Fig. 685.—Transverse fracture of the patella with marked rotation of the lower fragment.
Fig. 686.—Transverse fracture of the patella, middle third, with separation of the fragments.

evidences of contusion of the region of the knee are absent. The laceration of the fibrous covering of the patella and the tears in lateral expansions of the capsule of the joint, accompanying the break, are

evidently produced by severe muscular pull and not by a local direct violence. Early and late refractures of a united patella may also be occasioned by muscular action.

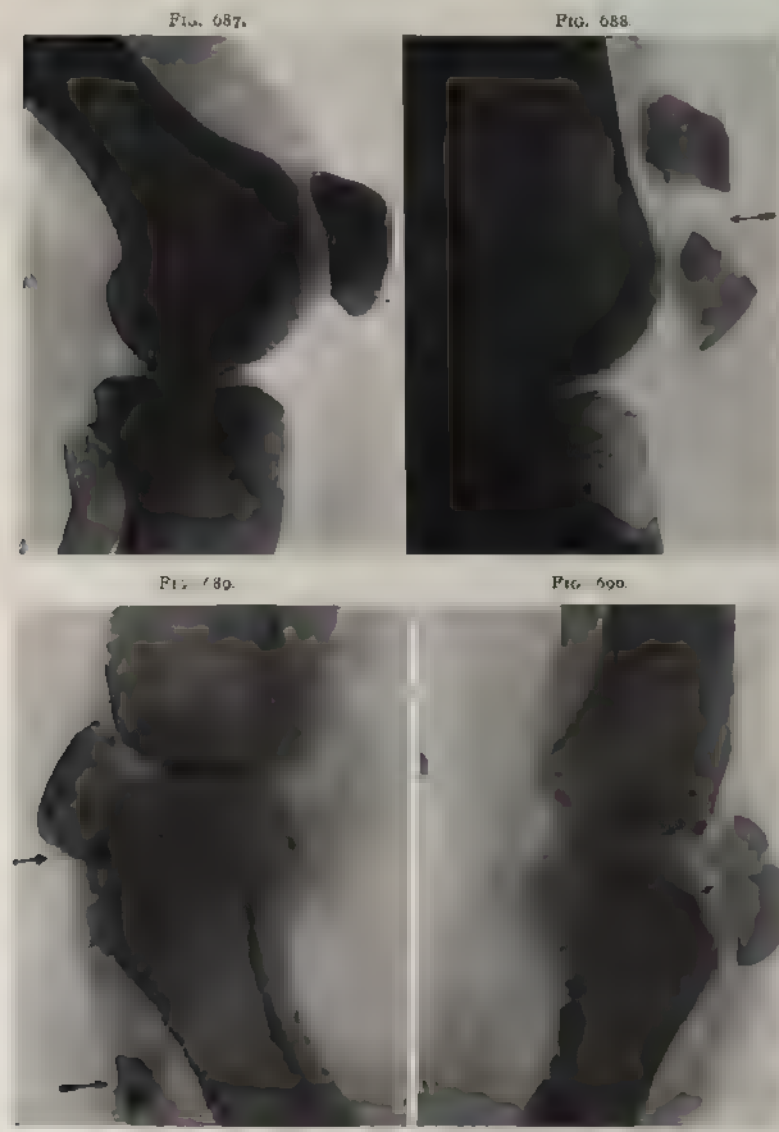

FIG. 687. FIG. 688.

FIG. 689. FIG. 690.

FIG. 687.—Incomplete transverse fracture of the patella, lower third, direct violence.
FIG. 688.—Transverse fracture of the patella, middle third. Marked separation of fragments.
FIG. 689.—Transverse fracture of the patella, with moderate bony union.
FIG. 690.—Old transverse fracture of the patella, upper third, with extreme separation of the fragments.

Fractures by direct violence are due to a direct fall upon the patella and to kicks and blows delivered directly over that bone. Patellar

fractures are rarely seen before the twentieth year, and are most frequently met between the thirtieth and fiftieth years. They occur rarely in children, and more commonly among male adults than in women.

Varieties and Mechanism.—Fractures of the patella (Figs. 683–690) may be transverse, oblique, comminuted, longitudinal, subperiosteal, and closed or compound in character. Those caused by muscular action are usually transverse in direction and closed; occasionally they are merely a tearing off of the upper or lower cortical portion of bone. Fractures by direct violence are usually oblique, but are at times comminuted; and occasionally they are accompanied by a wound, causing them to be open fractures.

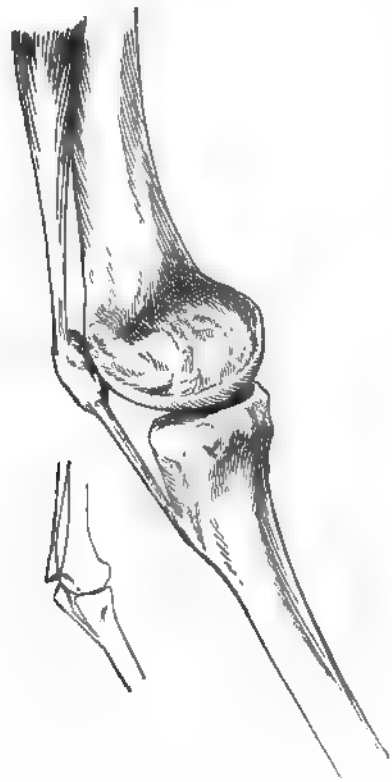

FIG. 691.—Drawing to show the mechanism of fracture of the patella by muscular action.

In transverse fractures the line may occupy the upper, middle or lower third of the bone, but is usually in the middle third. Fractures by direct violence may occupy any portion of the bone and be of any variety.

Without entering into a discussion of the various theories of the mechanism of fractures of the patella, it may be stated that those produced by muscular action occur while the knee is partially flexed. The patella then is held firmly by the quadriceps muscle and the ligament of the patella against the condyles of the femur, a sudden contraction of the quadriceps muscle acts forcibly on the upper edge of the patella and the bone is broken transversely at its point of contact with the condyles. The resulting line of fracture depends upon the degree of flexion of the knee at the time of fracture (Fig. 691). When the patella breaks, the aponeurosis and lateral expansion of the quadriceps tendon also may be torn by the muscular pull. The tear is of varying degree, from a slight tear in the aponeurosis over the patella to a complete rupture of both lateral expansions of the joint capsule. In fractures by direct violence there are, as a rule, very little separation of fragments, very little tearing of the fibrous aponeurosis over the patella, or of the lateral expansion of the joint capsule. In transverse fractures in

which the lateral expansion of the aponeurosis and joint capsule are torn, there is marked separation of the fragments. The lower fragment remains stationary, due to its ligamentous connection with the tibia, but the upper fragment is displaced upward; there may be separation amounting to from half an inch to an inch. This later may be increased greatly by rapidly occurring joint effusion and intra-articular hemorrhage, and the muscular contraction. Tilting of the fragments forward at the fracture is quite usual.

Symptoms.—The types to be described are those due to muscular action, which usually show more or less separation of fragments, and those caused by direct violence, which generally have irregular lines of break with little if any separation of the pieces. In the two classes the symptoms, the prognosis, the form of treatment and the end results are different.

The symptoms of fracture by muscular action, in which there are present separation of fragments and a transverse line of fracture in about 80 per cent. of cases, are sudden loss of power of extension at the knee, so that the patient cannot voluntarily straighten the flexed knee. Although at times he is able to extend the knee by the swinging leg with the thigh, he is unable to raise the foot from the bed when supine. Disability varies, however, with the amount of laceration of the tendinous aponeurosis surrounding the patella. The tendinous fibres of the vastus internus on the inner side and the prolongation of the fascia lata on the outer side are not always completely torn; as a result limited extension of the knee may be possible. Pain not intense, tenderness on pressure, and marked swelling of the entire knee region anteriorly and laterally are found upon examination. This swelling is due to joint effusion and hemorrhage. It extends outside the joint into the soft parts, and can be felt directly beneath the skin in the area between the fragments. Ecchymosis may extend beneath the quadriceps femoris and under the skin of the thigh. The separated fragments may be felt distinctly; and as a rule there is a marked interval between them, forming a transverse cutaneous groove into which one or two fingers may be laid. Crepitus may be obtained, if the effusion is small and muscular pull has not separated the fragments widely. This is readily developed by slowly pressing the fragments together and moving them laterally upon each other. This procedure is somewhat painful, but establishes the diagnosis. Under ether the muscular contraction which causes the separation is easily overcome and crepitus is found without causing pain.

In fractures by muscular action there are no local signs of contusion or abrasion of the soft parts, unless the patient falls directly on the knee after sustaining the fracture.

The symptoms of fracture by direct violence are localized pain,

tenderness on pressure, the presence of a contused, abraded, or lacerated wound over the patella, effusion not only in the knee-joint but also in the prepatellar bursa. The muscular attachments are not torn away and the sesamoid patella is shortened rather than divided transversely. The loss of function is not due to marked inability to extend the leg, as in fracture by muscular action, but is due to pain. Patients are able to bear weight on the leg, and in many cases may walk. As there is little separation of fragments, crepitus and mobility of fragments may be readily determined. There is effusion of synovial fluid and at times blood into the knee-joint. The character of the swelling is, however, different from that seen in fractures by muscular action, in that it is similar to that seen in acute synovitis and rarely extends into the surrounding soft parts.

In vertical, subperiosteal, and cortical fractures, the symptoms present may be only those of an associated traumatic synovitis and the true lesion only recognized by radiogram. Sometimes late ecchymosis over the bone and the development of a local swelling from callus may reveal the true character of the lesion.

Differential Diagnosis.—Fracture of the patella should not be confused with rupture of the quadriceps tendon, rupture of the ligament of the patella, prepatellar bursitis, or traumatic synovitis of the knee-joint. A fracture of the bone is differentiated from rupture of the quadriceps tendon, which occasionally is torn from its attachment to the patella, by the absence of a sulcus above the bone and the presence of downward mobility of the patella; from rupture of the ligament of the patella by the absence of a sulcus below the patella and possibility of upward mobility of the patella. Radiographic examination will clear up the diagnosis.

In prepatellar bursitis there may at times be felt a decided crepitus within the bursa, but it is soft in character, and there is no swelling at the sides of the knee-joint; while traumatic synovitis may be differentiated by failure to discover two fragments of bone with a furrow between them, by the evident floating of an unbroken patella or an intra-articular effusion and the shape of the fluctuating fluid collection. Radiography will aid greatly in establishing a diagnosis.

Prognosis.—The prognosis of fracture of the patella depends upon the character of the fracture, the degree of separation of fragments, the extent of the tear of the lateral expansion of the aponeurosis, and the form of treatment adopted. Bony union results only when anatomical apposition of fragments is obtained. In transverse fractures with separation of fragments, bony union is defeated by the want of coaptation, the interposition of torn edges of the aponeurosis, dropping inward between the fragments, and by the action of synovial fluid, which limits to a great extent the formation of callus. Union in cases

in which there is uncorrected separation of fragments is never bony but fibrous in character. While fairly useful function may be obtained thus, it requires several months or a year for its establishment, and is not of a character to stand much strain. Resulting stretching of the fibrous union often takes place; and approximation, which at first was fairly close, ends in a considerable separation of fragments, so that eventually they may be separated for a distance of from three to four inches. In transverse fracture it is only in those cases, in which there is little or no tearing of the lateral expansion of the aponeurosis, that a completely useful joint is obtained. In fractures by direct violence in which there is an oblique, comminuted line of fracture and no tearing of the aponeurosis and therefore no appreciable separation of fragments, bony union as a rule results and operative treatment is not indicated. In transverse fractures with separation of fragments, operation and direct approximation of fragments with repair of aponeurotic tears should give firm bony union and good functional results. Before selecting the operative method of treatment the possibility of sepsis should be made known to the patient; but he should be informed that by operation firm bony union will be obtained in the majority of cases with consequent shortening of the time of convalescence. The possibility of infection occurring in open treatment on the one hand and the probability of fibrous union with resulting functional impairment and prolonged convalescence by non-operative means on the other hand should be made clear to him. He should realize that the open treatment, which means suture of the fascia and aponeurosis and perhaps of the bone, is dangerous in the hands of the occasional surgeon, but practically free from danger when performed under a skilled modern technic.

Treatment.—To obtain good functional results in fractures of the patella there must be almost anatomical apposition of fragments, which will give bony or a short fibrous union. This is less likely to occur under non-operative treatment, though it is practically possible in fractures with moderate laceration of the tendinous surroundings of the patella. A satisfactory approximation of fragments is liable to be prevented by intra-articular hemorrhage, contraction of the quadriceps extensor muscle, and interposition of torn edges of aponeurosis and periosteum. In fractures by direct violence, in which as a rule there is little or no separation of fragments and no interposition of aponeurosis, and in fractures by muscular action in which the fragments are little separated, the non-operative treatment is satisfying. The non-operative treatment consists in putting the entire extremity at rest on a posterior padded splint, with the knee in full extension, the leg elevated, and the thigh muscles relaxed by flexion at the hip-joint. This form of treatment, combined with local cold inter-

mittently applied, and after the first week moderate compression by bandages, will give firm union, fibrous or osseofibrous, as a rule at the end of about six weeks. At the end of this time the splint may be removed, judicious passive motion and massage instituted, and at the end of three months active use of the leg allowed. This form of treatment has, however, a rather limited degree of usefulness, and should be used only when there is no marked separation of fragments and a competent operative technic is unobtainable.

In transverse fracture of the patella with separation of fragments, two forms of treatment may be adopted—non-operative and operative. Successful non-operative treatment in the average case, as a rule, will give moderately close fibrous union and fair functional results after a prolonged convalescence; it should be adopted only when there is some direct contraindication to operation or after the possibilities of the two forms of treatment have been thoroughly understood by the patient. Operative treatment, on the other hand, should give bony union, good functional result, and a much shorter convalescence. It is advisable when the operator is a surgeon accustomed to carrying out an aseptic technic and can assume with safety the treatment of possible septic complications.

Non-operative Treatment (Fig. 692.)—Place the foot, leg and thigh upon a well-padded posterior wood or wire splint with foot-piece. Bandage the leg and thigh to the same; or use four straps of adhesive plaster two inches in width for that purpose applied as shown in the illustration. Steady the lower fragment by a strap of adhesive plaster passed obliquely around the leg immediately beneath the lower fragment, elevate the splinted limb to flex the hip and relax the thigh muscles, place a second strip of adhesive plaster obliquely around the of apparatus for a period of from four to seven weeks, changing it occasionally and giving light massage to the muscles. From time to time it will be necessary, especially during the first two weeks, to tighten the adhesive stripping above and below the patella so as to maintain approximation of fragments. Do not flex the knee during the treatment. At the end of eight weeks the elevation may be discontinued and the limb brought to the extended position, and at the end of a few days replaced by a light split plaster dressing or posterior ham splint (Fig. 693). Weight-bearing may be begun at about eight weeks while the ham splint is continued. Passive flexion of the knee may be started carefully at about ten weeks. Active motion should not be allowed until about the end of the third to the sixth month.

Operative Treatment.—Strict asepsis is absolutely necessary in operations upon the patella. Unless one is prepared to be most exacting in technic, non-operative methods are advisable. Operations for repair of a broken patella should be done only in well-appointed hos-

pitals and by those who are daily engaged in major operative work. There is no joint which is more prone to infection and in which more disastrous consequences follow it than the knee-joint. Infection means prolonged convalescence at best, and gives rise to suppurative

FIG. 692.

FIG. 692.—Method of non-operative treatment of fracture of the patella or in one plane. The leg is fixed securely by straps of adhesive plaster to the splint, and the fragments of the patella are approximated by two strips of adhesive plaster shown. Elevation of the limb is then made to relax the quadriceps extensor muscle.

FIG. 693.



FIG. 693.—Application of the posterior ham splint in fracture of the patella to be used during convalescence.

arthritis, subsequent ankylosis, suppurative myositis, failure of union, and even death. The end result of suppurative knee-joints, following operation for fracture, is therefore deplorable.

An operation for patellar fracture is best performed at the end of

from three to five days after injury, though there is no great objection to earlier intervention. A transverse semicircular incision with convexity upward, to keep the scar from the kneeling surface, raises a

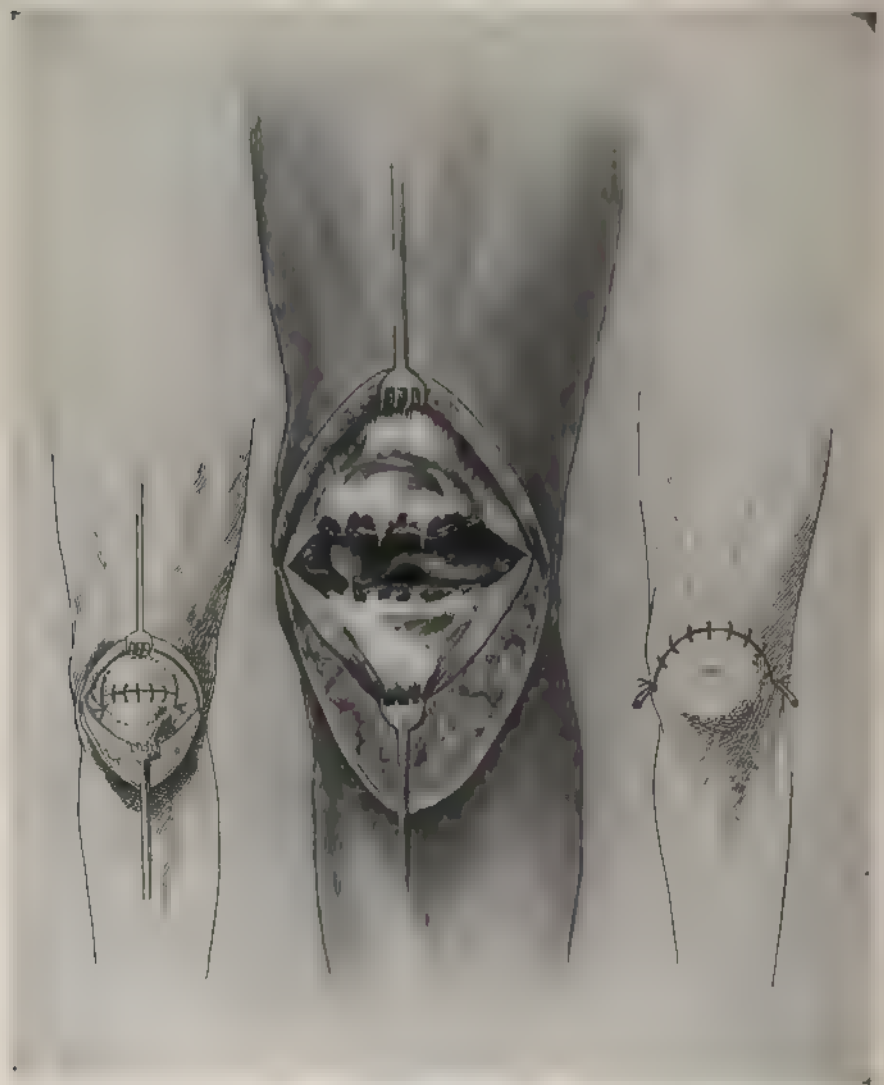

FIG. 694.—Fracture of the patella. Middle dressing shows crescentic incision with edges retracted, transverse fracture of patella with tear of aponeurosis and lateral expansion of the capsule. Lateral figures show method repair with interrupted kangaroo tendon and chromic catgut sutures approximating fragments and torn capsule; interrupted linear sutures in skin and rubber tissue drains in both angles of the wound.

flap over the broken bone and uncovers the seat of fracture. The synovial fluid escapes and the blood-clots should be picked out with forceps. Irrigation of the joint is not advised. The torn edges of the aponeurosis and the periosteum covering the patella are lifted from

the fractured surfaces, which are lightly rubbed with dry gauze to remove adherent blood-clot and fibrin. The fragments of the patella are brought together and held in approximation by a circumferential suture of No. 2 chromic catgut, or by two interrupted sutures of No. 2 chromic catgut placed at the lateral edges of the patella. The lacerated aponeurosis and periosteum covering the patella and the torn margins of the lateral expansions of the joint capsule are sutured with interrupted or mattress sutures of No. 1 chromic catgut, and the skin edges with interrupted sutures of fine silk. The wound is closed with drainage at each angle of the wound, a sterile dressing is applied (Fig. 694), and the leg and thigh, on a padded posterior splint of wood with the hip flexed moderately, are fixed on an inclined plane. Massage and passive motion should begin at the end of the third week and active motion and weight-bearing at the end of three months. The result looked for is bony union, which generally occurs if anatomical approximation is maintained. With proper technic infection is extremely rare.

In transverse fractures Wyeth passes by means of a needle a deep transverse cord through the ligament of the patella and the overlying skin close to the bone. Just above the patella he carries another ligature deeply through skin and muscle across the thigh. These have their ends sticking out of the skin at four points, two above and two below the broken sesamoid bone. Placing a pad of gauze over the seat of the fracture, he ties the respective upper and lower ends of the threads together so as to displace any periosteal fringe lying between them.

Results.—W. C. Quinby reports the results of 30 cases out of 75 treated at the Massachusetts General Hospital, from 1898 to 1904. Six of the cases were treated without suture and 24 with suture, 2 of the latter having a double fracture. Of the 24 cases, 7 were reoperated upon for refracture and two for removal of the suturing wire. The results obtained were as follows:

UNSUTURED, 6 CASES

Result		Per cent.
Perfect	3	50.0
Fair	1	16.5
Poor	2	33.5
Serviceable knees		66.5

SUTURED, 24 CASES, 26 OPERATIONS

Result		Per cent.
Perfect	17	65.5
Fair	5	19.0
Poor	4	15.5
Serviceable knees		84.5

Perfect results included cases having normal voluntary extension and flexion, 8, 18 degrees and 34 degrees, respectively, with perfect function. In fair results were included those having voluntary flexion to a right angle or a little less, with no limp or trouble in walking on the level; and in poor results were those in whom flexion to a right angle was impossible, who limped or became easily tired on the level, or who required a cane or had to go upstairs one step at a time. While this group is rather small, it gives a fair idea of the two classes of treatment, but it should likewise be remembered in a study of these statistics that those cases selected for operation probably had wide separation of fragments and that the non-operated group had little separation of fragments.

End-results.—Delatour reports the following statistics: 87 patients with 103 fractures; 3 cases not operated upon. Two deaths occurred but neither was directly due to operation. In 99 instances the fracture was exposed and sutured. Six had useful joints, but with limited motion; 40 had flexion to, at least, a right angle, with perfectly useful joints. The remainder he was unable to trace. All had motion to at least 45 degrees at the time of leaving the hospital.

Refracture of Patella.—Refracture of a previously fractured patella is sometimes observed and is due to muscular pull from mis-steps or stumbles, or it may be occasioned by a recurrence of the original form of injury. It is seen most frequently in recent cases of fracture, in which the bond of union is not strong or in which the joint structures have not regained their normal pliability and the muscular structures their normal tone. The line of refracture is, as a rule, at the original break. The upper fragment is torn away from the lower fragment, and on flexion of the knee-joint this separation is increased, while hyperextension gives good approximation.

The treatment consists in immobilization of the part on a posterior splint, with approximation of the fragments by the adhesive plaster dressing and an increased convalescence with careful massage and passive motion. Rarely open operation and direct fixation of the fragments by suture of the periosteum or bone or by a circumferential suture of chromic catgut or kangaroo tendon may be required.

Old Fractures of the Patella.—Old fractures of the patella with fibrous union may be characterized by marked separation of the fragments and impaired function. In such cases operation should be performed when the disability is great and the probability of improvement in function evident. Separation of fragments alone in the presence of a fairly useful limb is not an indication for operation. By operating on these patients, it may be possible to obtain union after freshening the fragments and approximating fragments by traction and suture. *In this* class alone is direct drilling of the fragments and the use of

some form of non-absorbable suture, such as silver or iron wire, advisable (Figs. 695 and 696). When approximation of fragments cannot be obtained by traction, the fragments may at times be brought together by lengthening of the quadriceps extensor tendon. This may be accomplished by several lateral transverse incisions in the tendon, by transverse incision of the fascia over the rectus, or by the reflection of a part of the quadriceps tendon downward, placing it over the two portions of the patella and attaching it to the ligamentum patella. Scharrz reports the transplantation of the lower half of the sartorius muscle to a position in front of the patellar fragments and suture to the latter by wire sutures, with a good functional result. A fracture



Fig. 695. Fracture of patella untreated [illegible] See Fig. 696.
Fig. 696.—Fracture of the patella showing moderate approximation by silver wire suture. Good functional result obtained. See Fig. 695.

had occurred five years previously with separation of the fragments at the time of operation of twelve centimetres (Figs. 697 to 700).

Rupture of Quadriceps Extensor Tendon.—Rupture of the quadriceps extensor tendon is always the result of sudden muscular action, usually in an effort to prevent oneself falling or making a mis-step. Cases have been reported in which pathologic conditions have predisposed to rupture.

The rupture may take place at the junction of muscle and tendon, in the tendon itself, or at the point of insertion of the tendon with the upper edge of the patella. In the latter variety there is usually a small cortical fragment detached from the patella. The rupture may be complete or incomplete.

Symptoms.—The symptoms of complete rupture are total inability to extend the leg, pain, localized tenderness, the presence of a sulcus

above the patella, and evidences of joint effusion. When the lateral expansions of the aponeurosis are also torn, the disability is as complete as in similar fracture of the patella, and the other symptoms like those of patellar fracture without separation of fragments.

Fig. 697. Fig. 698



Fig. 699. Fig. 700



Figs. 697, 698, 699, 700.—Examples of suture of patellar fragments in which the silver wire used for suture was either extruded or broken. This form of operative treatment for recent fractures is not advised. These illustrations are only shown to demonstrate unwise methods of treatment.

The symptoms of incomplete rupture are localized pain, swelling, joint effusion, pain on extension of the leg, no distinct failure to fully extend leg, but that movement is done with decreased force, and there is a slight gap, shallow and irregular in character, above the patella.

Prognosis.—When there is complete rupture disability will be

prolonged and as a rule permanent, unless direct suture of the edges of the torn tendon is performed. This procedure should give a good functional result. In incomplete rupture, good functional results are obtained by immobilization for four to six weeks, and direct suture is not always demanded.

Treatment.—In incomplete rupture the leg and thigh should be immobilized upon a splint and the foot elevated so that flexion at the hip-joint is maintained. This procedure relaxes the quadriceps extensor muscle. Local compression should be applied to the knee-joint for one week and followed by massage of the thigh muscles. At end of fifth week splint may be removed and active motions encouraged.

In complete rupture, incision with direct suture of the torn edges of the tendon is indicated. Chromic catgut or kangaroo tendon should be used to overlap the edges of the torn tendon with mattress stitches and post-operative treatment as recommended for incomplete rupture employed.

Rupture of the Ligament of the Patella.—Rupture of the ligament of the patella is usually the result of muscular action, as in fracture of the patella and rupture of the quadriceps tendon, and rarely the result of direct violence.

Rupture may occur in the body of the ligament or at either extremity. When the proximal end is involved, small cortical fragments may be torn from the lower edge of the patella, and when the distal end is torn, small fragments of bone are usually separated from the tuberosity of the tibia. The rupture is usually complete.

Symptoms.—The symptoms of complete rupture of this ligament are localized pain, tenderness on pressure, inability to extend the leg, effusion into the knee-joint, the presence of a distinct sulcus below the patella, and upward displacement of the patella, which is increased by active contraction of the quadriceps extensor muscle. At times the displacement upward of the patella may be from one to two inches.

Prognosis.—Fibrous union occurs with conservative measures, but there is apt to result permanent impairment of function, with atrophy of the extensor muscle, and the patient is obliged to use a cane permanently. Operation and direct suture give better functional results.

Treatment.—Conservative measures are not recommended. Unless there is some distinct contraindication to operation, it should be performed. Direct suture with chromic catgut or kangaroo tendon gives the best results. When the tendon is torn from the tuberosity of the tibia, direct nailing may be adopted. After operation the leg and thigh should be immobilized with the knee hyperextended and the hip-joint flexed. Massage and gentle passive motion may be started at the end of the fourth to fifth week or earlier, and active motion encouraged at the end of the eighth week.

CHAPTER XXIII

FRACTURES OF THE TIBIA AND FIBULA

Anatomy.—The tibia (Fig. 701) is the larger and inner bone of the leg, and supports the weight of the body from the femur to the astragalus. It consists of the upper extremity, the shaft and the lower extremity. The upper extremity of the tibia is the largest and broadest part of the bone and consists of the internal and external tuberosities, which have upon the upper surface the internal and external articular surfaces for articulation with the condyles of the femur. Between the two articular surfaces is a prominence, the intercondylar eminence with two elevations, the internal and external. Anteriorly below the infraglenoid margin there is a large roughened projection, the tubercle.

The shaft of the tibia is three-sided, is largest at its junction with the upper extremity and gradually tapers until near its lower end where it again becomes somewhat increased in diameter. It presents an internal and external surface, separated from each other by the crest, and a posterior surface separated from the inner surface by the rounded inner border, and from the external surface by the interosseous ridge.

The lower extremity of the tibia while smaller than the upper extremity is larger than the shaft. Its lower surface articulates with the astragalus; from its lower inner side there is a process, the internal malleolus, having an articular external surface for the joint with the astragalus. The outer surface of the lower end presents a fibular notch for articulation with the fibula.

The fibula (Fig. 702) is the slender bone of the leg situated external to the tibia. It is slightly shorter than the tibia and consists of the upper extremity, the shaft and the lower extremity. The upper extremity is formed by the head, the upper part forming the apex, and presenting a small articular facet for the tibia. The shaft has three surfaces—the internal, external and posterior, and three crests—the anterior, external and internal. The lower extremity presents an enlarged pyramidal process, the external malleolus, situated a little lower and posterior than the internal malleolus. It presents two facets, one for articulation with the tibia and the other for articulation with the astragalus.

The tibia and fibula are connected in three ways: at the upper tibio-fibular articulation, by the anterior and posterior superior tibio-fibular ligaments; in the region of the shafts by the interosseous membrane, and at the lower tibio-fibular articulation by the inferior interosseous ligament and the anterior and posterior inferior tibio-fibular ligaments.

The ligaments of the articulation of the femur and tibia have been described above.

The ligaments about the ankle-joint in addition to those of the tibio-fibular joint connect the two bones of the leg with the astragalus and os calcis of the tarsus. They are the deltoid or internal lateral ligament, which consists of four separate ligaments,—the anterior talo-tibial, the posterior talo-tibial, the calcaneo-tibial and the tibio-navicular ligaments; and the external lateral ligament, consisting of three parts—the anterior, the middle and the posterior fasciculus.

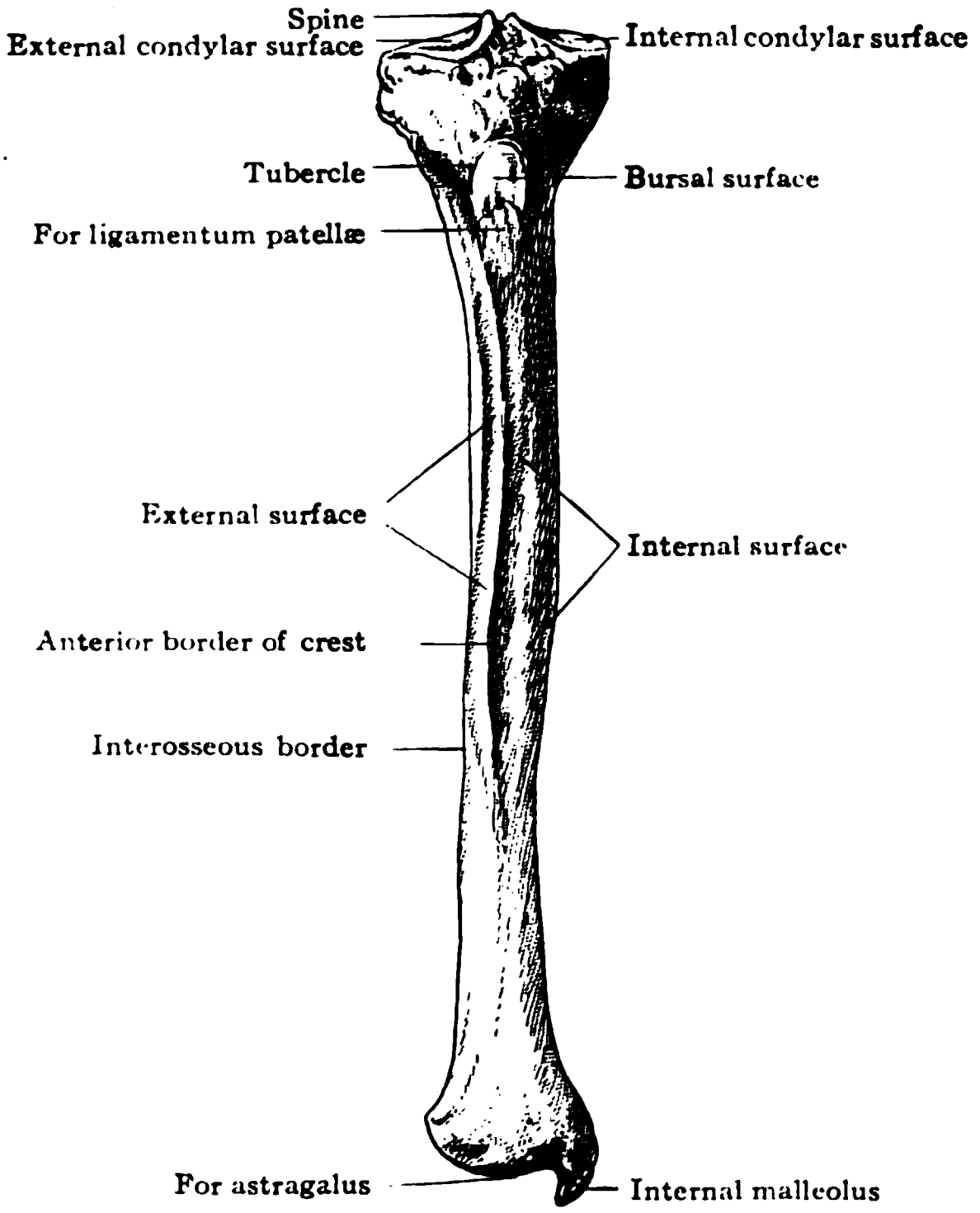

FIG. 701.—Right tibia, anterior view.

Surface Markings.—Palpation of the region of the knee-joint and upper part of the leg discloses the ligament of the patella in the median line and in the line of the tubercle of the tibia to which it is attached. The external and internal tuberosities may be palpated, the external being the more prominent of the two. Between the tuberosities of the tibia and the condycles of the femur are the two respective depressions. In either of these may be felt after certain traumatisms the dislocated semilunar cartilage of the injured side of the joint. On the external and posterior margin of the leg may be felt the head of the fibula at the level of the tubercle of the tibia. Posteriorly is seen

the popliteal space in which may be felt the pulsation of the popliteal artery, which is of importance in supracondylar fractures of the femur.

Anteriorly the prominent crest of the tibia, the shin, may be seen and palpated, as well as antero-internal surface of the shaft of the tibia. The shaft of the fibula can only be indefinitely palpated, except at its lower fourth, where it becomes subcutaneous. At the ankle the most prominent parts are the external and internal malleoli, the external being a little lower and on a plane posterior to the internal. Normally the internal malleolus should be on a line drawn from the

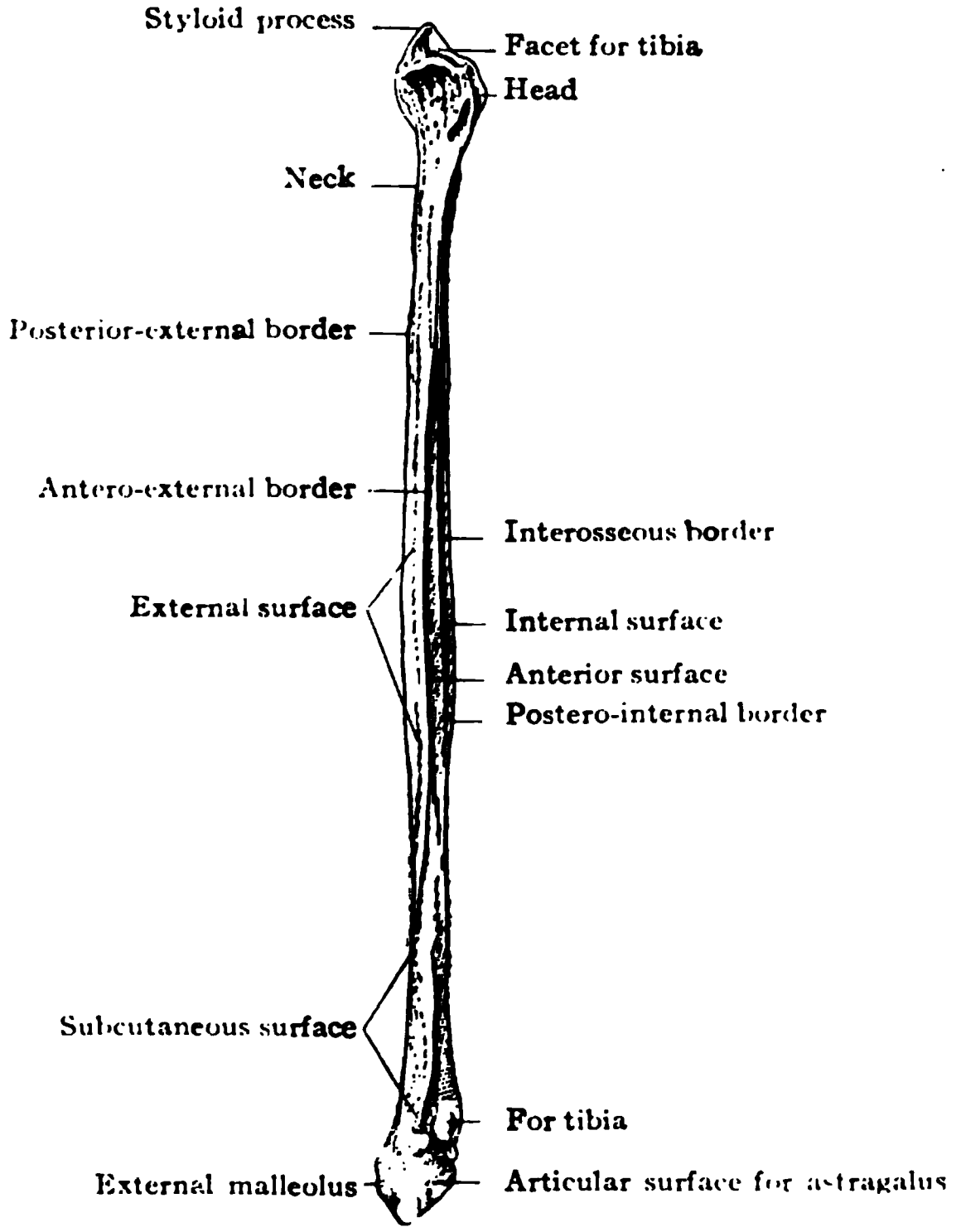

FIG. 702.—Right fibula, anterior view.

inner border of the patella to the inner side of the head of the first metatarsal bone. Posteriorly is seen the tendon of Achilles, which is narrowed at the level of the internal malleolus. At this point it is preferably cut in subcutaneous tenotomy, when this operation is required to prevent displacement of the fragments in fractures of the tibial shaft caused by spasm of the gastrocnemius.

Statistics.—Plagemann's statistics based on radiographic diagnosis of 1393 fractures observed at the Rostock clinic shows that the tibia and fibula were involved in 286 cases (20.53 per cent.), classified as follows:

	Cases	Per cent.
Fractures of tibia and fibula	168	12.06
(1) Fractures of the upper end of the tibia and fibula	4	0.29
(2) Fractures of the shaft of tibia and fibula	92	6.604
(3) Supramalleolar fractures of tibia and fibula (Malgaigne)	22	1.57
(4) Fractures of lower end of tibia and fibula	50	3.59
Isolated fractures of tibia	61	4.38
Fractures of upper end of tibia	19	1.36
Fractures of shaft of tibia	24	1.79
Fractures of lower end of tibia	18	1.29
Isolated fractures of fibula	57	4.79
Fractures of head and neck of fibula	13	0.43
Fractures of shaft of fibula	30	2.15
Fractures of lower end of fibula	14	1.005

Fractures of the Upper End of the Tibia and the Fibula.—Fracture of the upper end of the tibia may occur as an isolated injury or may have an associated fracture of the upper end of the fibula. In a majority of instances fractures of this extremity of the tibia are not accompanied by fracture of the upper end of the fibula.

Etiology.—These fractures are the result of direct or indirect force. Fractures by direct violence result from blows, falls, and crushing injuries applied to the upper part of the leg. Fractures by indirect violence result from lateral or anteroposterior flexion with either the thigh or the leg and foot fixed. These injuries are essentially bending fractures. Forced abduction usually produces a fracture of the internal tuberosity, forced adduction, a fracture of the external tuberosity, and hyperextension an oblique fracture with the line of fracture running downward and forward. A rare form of fracture is the "compression fracture" of Wagner, due to a fall from a height, the patient landing on the foot and producing a fracture of one or both tuberosities with marked crushing of the tuberosities and lateral displacement of the same. Fracture by indirect violence as a rule involves only the tibia, although rarely there are exceptions to this rule.

Varieties (Figs. 703–727).—From a collection of 29 radiographs of fracture of the upper end of the tibia and fibula the following varieties of fracture were found: of tibial tubercle, 2; comminuted of the tibia and fibula, 1; of external tuberosity and of fibula, 1; of fibula alone, 2; longitudinal T-fracture of tibia with separation of both tuberosities, 4; compression fractures of tibia, both tuberosities, 4; lateral oblique fracture of tibia not entering joint with fracture of fibula, 3; lateral oblique of tibia not entering joint, 2; anteroposterior fracture of tibia not entering joint, 1; fracture of external tuberosity of tibia, 2 (large fragment); external tuberosity of tibia, 1 (small fragment); transverse of tibia, 1; transverse of tibia with fracture of fibula, 1; fracture of intercondylar eminence, 1; and in childhood 3



FIG. 704.—Normal epiphysis of upper end of tibia with separate centre of ossification for tibial tubercle.



FIG. 706.—Comminuted fracture of the upper end of the tibia and fibula.

oblique fractures of tibia, not entering joint but involving only the diaphysis, one of these being associated with fracture of neck of fibula.

Symptoms.—The symptoms of fracture of the upper end of the

Fig. 707. Fig. 708.

Figs. 707 and 708.—Fracture of the external tuberosity of the tibia. Lateral and anteroposterior views.

Fig. 709. Fig. 710.



Fig. 709. Fracture of external tuberosity of the tibia.
Fig. 710. Fracture of internal tuberosity of the tibia.

Fig. 711. Fig. 712.



FIGS. 711 AND 712.—Longitudinal T- or Y-fracture of the upper end of the tibia, with separation of both tuberosities. Anteroposterior and lateral views.

Fig. 713. Fig. 714.



FIGS. 713 AND 714.—Fracture of the upper end of the tibia (T-shaped, articular of the head) and of the fibula. Anteroposterior and lateral views.

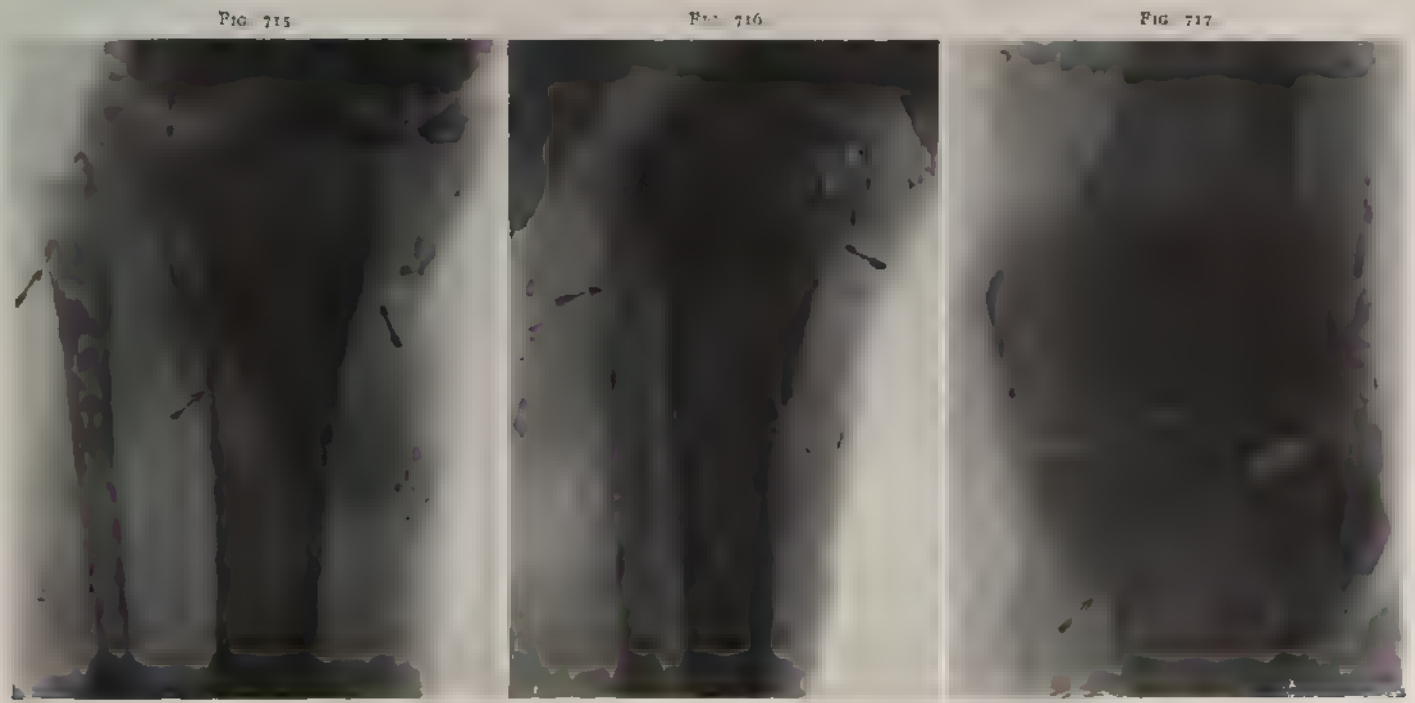

FIGS. 715, 716, AND 717.—Types of compression fracture of the upper end of the tibia, including both tuberosities.

FIG. 718



FIG. 719

FIGS. 718 AND 719.—Transverse anteroposterior fracture of the upper end of the tibia and oblique fracture of the neck of the fibula. Anteroposterior and lateral views.

FIG. 720



FIG. 721



FIGS. 720 AND 721.—Lateral oblique fracture of the tibia with fracture of the fibula. Anteroposterior and lateral views.

tibia vary with the variety of fracture and the size of the fragment. There is always localized pain, tenderness on pressure, localized swelling, and when the fracture line involves the joint effusion of

FIGS. 722 AND 723.—Transverse fracture of the upper end of the tibia. Anteroposterior and lateral views.

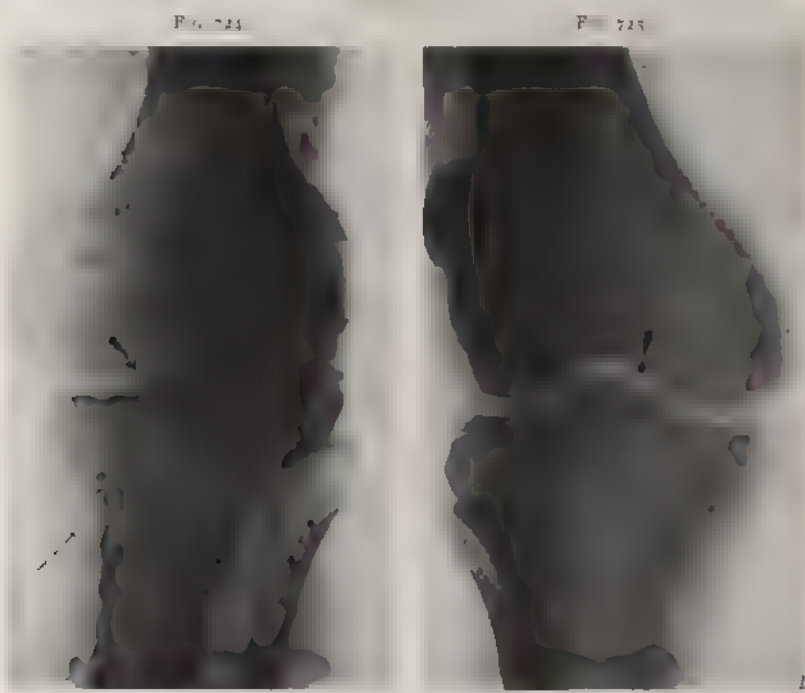

FIG. 724.—Fracture of the internal tuberosity of the tibia.
FIG. 725.—Fracture of the intercondylar eminence.

synovial fluid and blood into the knee-joint. In fractures of either tuberosity there is always abnormal mobility, positive passive abduction or adduction of the leg, and widening of the external measurements of the head; when there is absence of impaction of fragments, which is the rule, crepitus is present on motion. In T-fractures there may be marked widening between the tuberosities, mobility of fragments on each other, and the mobility of the leg in all directions from the seat of fracture. Voluntary motions of the leg are greatly restricted on account of pain and the lack of support. In compression fractures, widening of the tuberosities is more marked than in any of the foregoing varieties, and in addition there is shortening of the entire

Fig. 720. Fig. 721.

Fracture

leg. Displacement of fragments is due to gravity and the fracturing force. Palpation shows irregularity of outline, mobility, and displacement. Positive diagnosis as to the variety of fracture and displacement of fragments should be made by the radiogram.

Fractures occurring in childhood may be incomplete and at times impacted. In the "green-stick" fracture, which is usually oblique and does not involve the joint, the most notable symptoms are localized pain, swelling, tenderness on pressure, angular [illegible] the seat of fracture, absence of widening between the margins [illegible] tuberosities, and absence of crepitus and abnormal mobility.

Prognosis.—When good apposition of [illegible] obtained,

union is usually prompt. There is, however, a tendency toward the production of considerable callus, and as reduction of fragments is rarely complete, the normal joint surfaces are at times interfered with. There may be considerable diminution of function for a long time, if the line of fracture involves the joint, even when the reduction has been satisfactory.

Complications.—In comminuted fractures or in fractures attended by marked displacement of fragments, there is the possibility of injury to the tibial arteries or popliteal vein, which may subsequently lead by gangrene to amputation. The external popliteal nerve may be injured in fractures involving the external tuberosity of the tibia or the head and neck of the fibula, and the subsequent development of callus may involve the nerve. This nerve lesion causes ankle-drop from motor palsy, if the injury to the nerve be severe.

Treatment.—Treatment consists in reduction of fragments, which may be accomplished by traction, manipulation, and lateral jamming, particularly in longitudinal, T-fractures, and compression fractures. In fractures of either tuberosity involving the joint cavity, reduction may be accomplished by forced abduction or adduction as the case requires. Retention of fragments may best be accomplished by the use of a gypsum dressing extending from the toes to the upper thigh. Correction of backward or lateral displacement of fragments is important. Permanent traction is not indicated, except in the compression form of fracture; then it may best be obtained by using a Thomas knee splint. Union occurs in from six to eight weeks, but weight-bearing should not be allowed for three months, although passive motion and massage may be given at the end of the third to the fourth week. Light massage and very careful passive motion may begin in experienced surgical hands a few days after reduction of the fragments.

Isolated fractures of the upper end of the tibia will not be considered separately, because the symptoms, diagnosis, and treatment are identical, whether the fracture is isolated or combined with a fracture of the upper end of the fibula. The only noteworthy fact in this connection is the relative frequency of their occurrence. In 29 fractures of the upper end of these bones fracture of both bones was found 8 times, isolated fracture of tibia 15 times, and isolated fracture of the fibula 3 times.

Isolated Fractures of the Upper End of the Fibula.—Isolated fracture of the upper end of the fibula is extremely rare (Figs. 728–730). In three cases observed the line of fracture involved the neck in two instances, and in the third case the line of fracture involved the upper end of the shaft near the neck. In all, the line of fracture was oblique

FIGS. 728, 729 AND 730.—Fractures of the upper end of the tibia.

in direction and was caused by direct violence in the form of a kick. Muscular action due to pull of the biceps muscle may occasionally produce a fracture.

Symptoms.—The symptoms are localized pain, tenderness, and possibly at times crepitus. Pain is often referred in the course of the external peroneal nerve (Fig. 731).

Treatment.—There is, as a rule, little if any displacement. The fragments are held together by the attachment of the muscles arising from this region. Immobilization on a posterior padded wood splint or in gypsum dressing for four to six weeks should give good results. The development of considerable callus may produce pressure upon the external popliteal nerve, and later require excision of the callus. Weight-bearing may be begun early, because the upper end of the fibula has no part in the formation of the knee-joint.

FIG. 731.—Drawing to show the relation of the external peroneal nerve with the head and neck of the fibula. Fractures in these regions are often associated with severe pain due to nerve injury or pressure.

Avulsion of the Tubercle of the Tibia (Figs. 774 776).—The tubercle and upper epiphysis of the tibia ossifies from a single centre, and unites with the diaphysis from the twenty-first to the twenty-second year. The tubercle at first is cartilaginous, and ossification extends downward from the epiphysis as a long tongue-shaped projection.

Etiology.—The ligament of the patella extends from the tip of the patella to the tubercle of the tibia. Only a portion of the ligament is inserted directly into the tubercle. Avulsion of this tubercle is the result of sudden contraction of the quadriceps extensor muscle, the pull of which is transmitted through the patellar ligament to its point of insertion on the tubercle. In very rare instances it is the result of direct violence, as is undoubtedly seen in cases showing distinct fragmentation of the tubercle. It is essentially an injury of childhood and early adult life.

Symptoms.—There is usually a history of strain, followed by pain and localized tenderness in the region of the tubercle. In addition

there is lameness and inability to fully extend the leg on account of pain; on palpation there may be felt thickening of the region of the tubercle or a movable fragment, with perhaps crepitus, which is cartilaginous in character. Radiographic diagnosis is possible only when there is marked separation of the ossified portion of the tubercle in comparison with the normal side. It is not improbable that errors have been made in the correct interpretation of radiographic plates of this region.

Treatment.—When there is marked separation or humping of the tubercle, immobilization with localized pressure should be used for a period of five to six weeks. The ultimate result of this lesion is good. The feasibility of operation and direct nailing of the displaced fragment is scarcely ever warranted, as the displacement has no effect upon the function of the patellar ligament, which is not entirely inserted into the tubercle of the tibia.



FIG. 732.—Tibia, fracture of the head of; epiphyseal. The specimen consists of the adjacent extremities of the femur and tibia of the left side and removed from a child about ten years old. The separation is complete; the epiphysis is held in position by the crucial ligaments. (Mütter Museum, No. 1442.06.)

Separation of the Upper Epiphysis of the Tibia and Fibula (Fig. 732).—This is a very unusual lesion. There have been found reported only 26 cases. The rarity of the injury is due to the comparative smallness of the epiphysis and the relation of the ligaments to the direct force, usually hyperextension or violent abduction or adduction of the leg. The tongue of cartilage forming the tubercle of the tibia is generally displaced with the epiphyses. The separation occurs in patients from three to twenty years of age. The usual lesion produced by the kind of violence which occasionally produces this epiphyseal separation is a diastasis of the lower epiphysis of the femur or an oblique fracture through the tuberosities of the tibia.

Symptoms.—The symptoms of separation of the upper epiphysis of the tibia are displacement of the upper fragment either laterally or anteroposteriorly forward, causing deformity, mobility of the fragment, soft cartilaginous crepitus, localized pain, swelling, and joint effusion. The separation may be compound or open injury.

Treatment.—Reduction is accomplished by traction and manipulation. Immobilization is best obtained by a gypsum encasement, which should be split and held in place with a bandage, if there is danger of swelling. This should be continued for six to seven weeks and weight-

bearing allowed at the end of twelve weeks. Lateral contour splints of metal or felt or gypsum gauze may be used.

Isolated separation of the upper epiphysis of the fibula has not been recognized.

Fractures of the Shaft of the Tibia and Fibula.—Fractures of the bones of the leg occur in frequency next to fractures of the bones of the forearm. They take place at any time of life, are more frequent in the male sex, and in well-developed adults who lead an out-door life. The tibia actively supports the body; but the fibula acts in a supplementary manner and of itself cannot support the body weight. Hence it is that in fractures of the tibia by indirect force there is generally in addition a fracture of the fibula. Fractures of both bones are most frequent in the middle third of the diaphysis. Plagemann's statistics show 92 fractures of the diaphysis. Of these there were only 5 of the upper third, 54 of the middle third and 33 of the lower third of the shaft. The line of fracture in these lesions was approximately at the same level in both bones 34 times; in 24 instances the line of fracture was higher in the fibula than in the tibia, and in 34 instances it was lower in the fibula than in the tibia.



FIG. 733.—Spiral fractures of the shafts of the tibia and fibula.

Etiology.—Fractures of both bones of the leg may be due to direct force, such as a kick, a blow, the weight of a falling object, or by being run over. They may also be the result of indirect force, as falls from a height, or accidents in which there is torsion or infraction of the leg with the foot held fast. Fractures by compression or mus-



FIG. 734.—Comminuted fracture of the shaft of the tibia and fracture of the shaft of the fibula.
FIG. 735.—Transverse fractures of the shafts of the tibia and fibula.



FIG. 736.—Oblique fracture of the shaft of the tibia with a double fracture of the shaft of the fibula.
FIG. 737.—Oblique fractures of the shafts of the tibia and fibula, considerable overriding of the fragments.

FIG. 738.—Spiral fracture of the shaft (low) of the tibia with spiral fracture of the shaft (high) of the fibula.

FIG. 739.—Double spiral fracture of the shaft of the tibia.

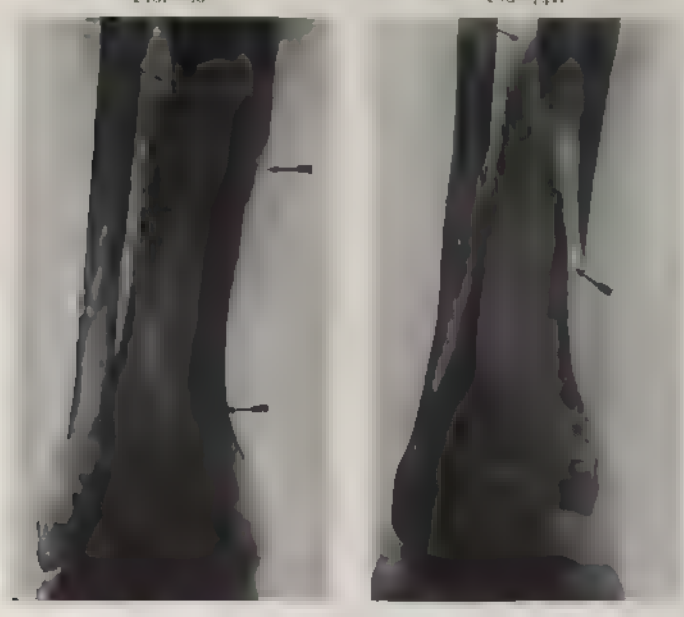

FIG. 740.—Double spiral fracture of the shaft of the tibia.

FIG. 741.—Spiral fracture of the shaft of the tibia.

Fig. 742. Fig. 743.





Fig. 742.—Double spiral fracture of the shaft of the tibia.
Fig. 743.—Old healed fracture of the shaft of the tibia and recent fracture of the shaft of the fibula.

Fig. 744. Fig. 745.

Fig. 744.—Oblique fracture of the shafts of the tibia and fibula. Union has occurred with lateral displacement and overriding.
Figs. 745 and 746.—Incomplete fracture of the shaft of the tibia in a boy aged 12 years. Antero-posterior and lateral views.

cular action are unusual. Fractures by indirect force usually involve the lower portion of the middle third or the lower third of the shaft. Fractures by direct violence are not confined to any portion of the shaft.

Varieties.—The line of fracture (Figs. 733–748) of the tibia may be transverse, oblique, V-shaped, spiral, or comminuted, and the fracture closed or open. Transverse fracture lines are unusual, and when seen are generally due to direct violence. The edges are usually serrated, and at times a three-cornered piece is detached from one or the other fragment. The usual form of fracture line is oblique, generally with the line of fracture running downward, forward and inward, so

FIG. 746. FIG. 747. FIG. 748.

For legend for Figure 746 see Figure 745.

FIGS. 747 AND 748.—Oblique fracture of the shaft of the tibia; boy aged 5 years. Anteroposterior and lateral views.

that the lower end of the upper fragment presents beneath the skin of the inner leg surface as a sharp fragment; at times this fragment perforates the skin. Torsion or spiral fractures are more common in the lower half of the shaft, are occasionally characterized by the separation of a triangular spiral portion of one of the fragments, and are often comminuted. Fractures by indirect violence are often open. This is due to perforation of the skin by sharp fragments. Fractures by direct force are occasionally open, due to either the fracturing force or to the development secondarily of pressure necrosis of the overlying soft parts.

Displacement of Fragments.—The tendency in all fractures of

the shaft of both bones of the leg is toward lateral and over-riding displacement (Figs. 749-751). It is less frequent in the transverse fracture, but even there it may frequently be present. In oblique, spiral, comminuted and multiple fractures, over-riding of fragments



Fig. 749.—Tibia and fibula. Left. Fracture of both bones below middle. Firm union with considerable displacement. The lines of fracture were oblique in both cases, passing from the crest in front downward and backward. There is a decided concavity anteriorly with considerable shortening. (Mutter Museum No. 14—.)

Fig. 750.—Tibia and Fibula (Roth). Fracture of both bones. Union. The plane of fracture starts on the fibular side of the tibia from a point 13 cm. above the ankle-joint, passes downward to a point on the inner side 6 cm. from the malleolus. In the fibula the plane passes from a point in the anterior surface 4 cm. below the styloid process to a point in the posterior surface 10 cm. below that process. (Mutter Museum No. 1427 55.)

Fig. 751.—Drawing to show the characteristic displacement of fragments in oblique fractures of the shaft of the tibia and fibula. (*A*) quadriceps muscle, (*B*) femur, (*C*) patella; (*D*) tibia, (*E*) fibula.

is the rule. The over-riding, lateral, or anteroposterior displacement is due to the fracturing force, the weight of the body, or muscular contraction. The usual displacement is upward, backward and outward of the upper end of the lower fragment. In addition there is

over-riding, angulation at the seat of fracture, and outward rotation of the lower fragment.

Symptoms.—The usual symptoms of fracture of the shaft of the tibia and fibula are inability to use the legs as far as weight-bearing is concerned. While there may be cases in which the patient is said to have walked, it is only likely in incomplete fractures, or comminuted fractures of the tibia alone. When both bones are broken and frac-

FIG. 752.—Method of determining abnormal mobility and crepitus in fracture of the shafts of the tibia and fibula.

ture is complete, attempts at lifting the leg from the bed will show angulation at the seat of fracture, deformity, axial deviation of the fragments, and outward rotation of the foot. Palpation along the crest of the tibia and its inner surface, which can usually be palpated beneath the thin overlying soft parts, will determine the seat of fracture of the tibia as well as the direction and degree of displacement, unless such a time has elapsed since the accident that considerable swelling



FIG. 753.—Method of measurement from the external tuberosity to the internal malleolus of the tibia to determine shortening.

of the soft parts has occurred. Fracture of the fibula may also be determined in its lower half by palpation and direct pressure. In addition to these symptoms there will be localized tenderness, pain, swelling of the soft parts, crepitus, preternatural mobility (Fig. 752) and shortening. The shortening may be determined by measuring from the inner tuberosity of the tibia to the tip of the internal malleolus (Fig. 753), and by comparison with uninjured leg. Late symptoms are the formation of blebs, ecchymosis, cellulitis, and œdema. The appreciation of crepitus may be prevented by interposition of soft

parts or impaction of fragments. In doubtful cases röntgenograms should be taken in anteroposterior and lateral planes to determine accurately the seat and variety of fracture and the degree of displacement of fragments.

Complications.—The complications seen in closed fractures of the tibia and fibula are injury to the anterior or posterior tibial or peroneal arteries, or the nutrient artery of the tibia, and rarely injury to the peroneal or tibial nerves. The complications of open fractures are sepsis, cellulitis, necrosis of fragments, and pressure necrosis of the overlying soft parts.

Prognosis.—Union occurs in closed fractures of the tibia in from five to eight weeks and in the fibula in from four to six weeks. It depends in great measure upon the accuracy of reduction. Persistent displacement of fragments will delay union, and permanent interposition of soft parts may result in pseudo-arthrosis. The usual fracture of bones of the leg treated by non-operative means results in satisfactory union without special deformity or disability if the surgeon has mechanical acumen, anatomical knowledge and surgical experience, and gives attention to his patient. Displacement of fragments, prominence particularly of the lower end of the upper fragment, shortening, axial deviation, and posterior angulation at the seat of fracture may readily occur under other circumstances (Fig. 754). In comminuted fractures there may be excessive callus formation, shortening, and persistent local pain accentuated by weather changes. The presence of some stiffness of the knee- and ankle-joints prolongs the time of convalescence, and is usually due to prolonged immobilization without massage and early mobility of these joints. In open fractures there is the possibility of suppuration developing here as elsewhere, unless sterilization of the wound is primarily effective. If it occurs, union is delayed, there may be necrosis of fragments, sinuses persistent for months, and the ultimate result a shortened leg with some degree of angular deformity, œdema of the soft parts, infiltration of the muscles, with atrophy and stiffness of the ankle-joint. These results are unusual in the hands of well-equipped surgeons who have had a chance to treat the case from its beginning, and have taken advantage of their opportunities. Delayed union or pseudo-arthrosis often persists for a long time.

Treatment.—The treatment to be adopted in fractures of the shaft depends upon the variety of fracture and possibility of obtaining anatomical apposition of fragments. In many fractures reduction should be promptly performed under general anæsthesia. Some delay may be warranted if shock be present to a marked degree. Reduction in closed fractures usually may be accomplished readily by strong, steady traction on the foot, counter-traction at the flexed knee, and

local manipulation of the fractured ends. Interposition of soft parts can generally be removed by this method, and anatomical coaptation of the fragments obtained. Usually there is comparatively little difficulty in maintaining this anatomical position. In transverse fractures and in a few oblique fractures it is possible to interlock the fragments into approximately their normal position. Other cases may show overriding of fragments when traction and counter-traction are stopped.

In the majority of cases it is comparatively easy to devise a suitable apparatus to maintain the fragments in their normal position without producing undue pressure from traction about the ankle. It is in these unusual cases that operation and direct fixation of the fragments by means of a bone inlay or a metal plate are advised. If the

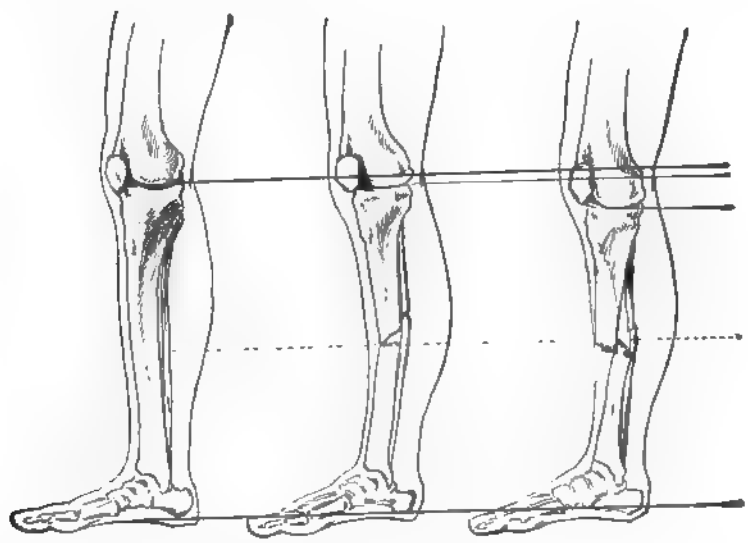

FIG. 754.—Drawing to show how shortening may take place by posterior angulation (middle figure) of fragments, and by overriding of fragments (right-hand figure) (left-hand figure is normal for comparison) (Modified after Zuppinger.)

non-operative form of treatment is used, the careless or inexperienced may expect a certain degree of shortening, over-riding and angulation of fragments with axial deviation. In the operative treatment there is a possibility of mild sepsis delaying union and cure and necessitating removal of the fixation plate, or of severe sepsis leading to amputation or death. Neither form of treatment is likely to be difficult in skilled hands.

Non-operative Treatment.—The foot and leg should be cleaned with water and soap and alcohol, and after reduction should be temporarily immobilized in a pillow and side splints extending from the mid-thigh to below the foot. When maximum swelling has taken place this dressing should be removed, further attempts at reduction made, if deformity still exists, and the foot, leg and thigh immobilized.

in a gypsum case, which should be split down the front or on each side. In the use of a gypsum case, one should be careful to preserve the normal line of foot and leg; there should be no anteroposterior or lateral angulation at the seat of fracture. The foot should be at right angle to the leg and inverted, and the knee-joint included in the gypsum dressing. The case is split down both sides, forming an anterior and a posterior portion, or in front, so that the case may be removed from time to time, the seat of fracture inspected, angulation corrected,



Fig. 755.—Method of treating fractures of both bones of the leg in a swinging fracture box. The flexion of the knee may be altered without disturbing the fracture and the degree of elevation changed when necessary. The patient can readily alter his position in bed and thus avoid bedsores over sacrum. The bed-pan is easily placed under the buttocks. The box should be opened daily for the first week and the leg examined, bathed and rearranged in the box.

and frictions, massage and passive motions used. At the end of three or five weeks in average cases a new gypsum case may be applied and the patient allowed up on crutches. Weight-bearing may be encouraged at the end of eight weeks, except in oblique or spiral or otherwise troublesome fractures. By raising the well foot with a thick-sole shoe, the patient may go about on crutches very early in leg fractures. Early union is probably hastened by early dependant leg and exercise in open air on one's crutches.

A swinging fracture box (Fig. 755) for ten days or two weeks

with frequent inspection, massage and mobility, followed by a gypsum case, may be used. This method is very often a preferable one. By fastening a rope and weight to the foot board of the fracture-box and

FIG. 756a. The modified Zuppinger traction apparatus for treating [illegible] leg.



FIGS. 756b AND 756c. Cabot posterior wire splint used in treating fractures of both bones of the leg unattended by deformity.

having the box to slide on a smooth wooden surface placed on the bed, traction may be added in rebellious fractures. The fracture-box in this method of dressing leg fractures must not be suspended. Tenotomy

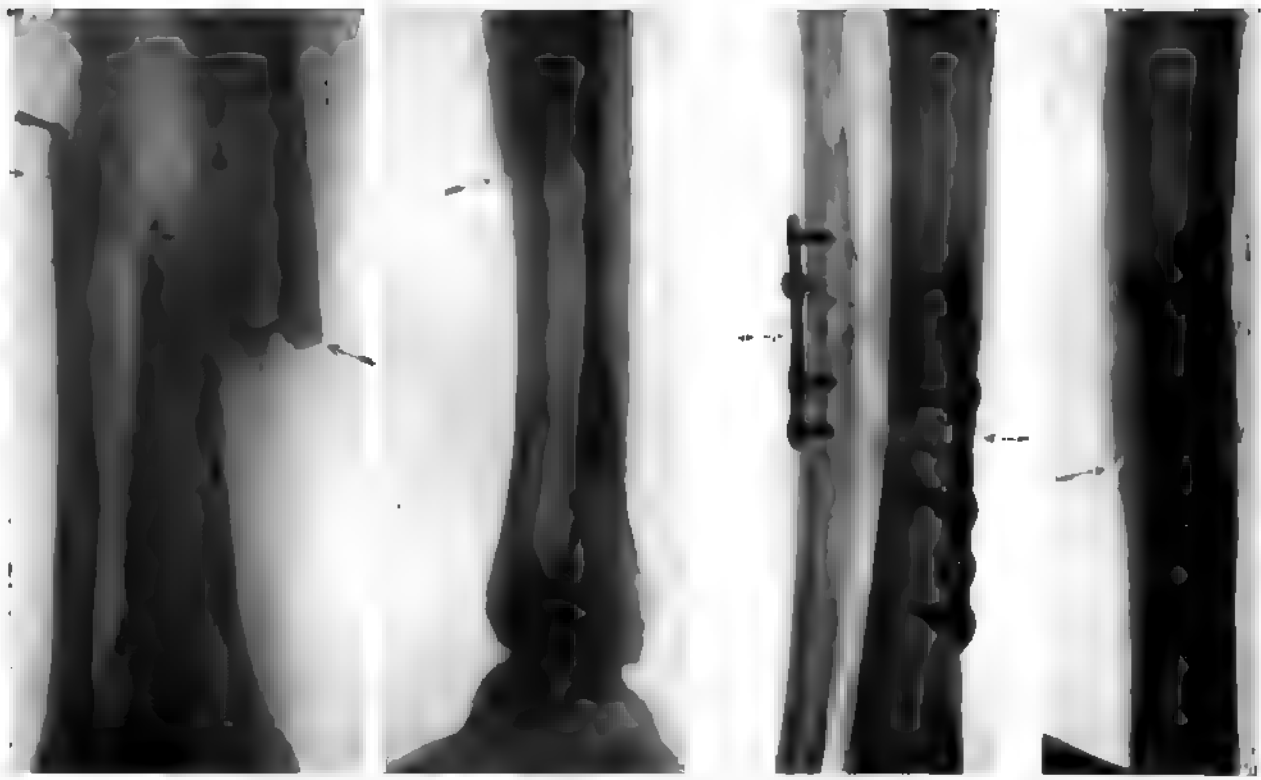

FIG. 757. FIG. 758. FIG. 759. FIG. 760.

FIGS. 757 AND 758.—Transverse fractures of shafts of tibia and fibula. Impossible to reduce fragments by non-operative measures. Anteroposterior and lateral views.

FIGS. 759 AND 760.—Transverse fractures of the shafts of the tibia and fibula. After operative reduction and fixation with Sherman plates and screws. Anteroposterior and lateral views. (Courtesy of Dr. J. M. Spellissy.)

Fig. 761.

Fig. 762.

Fig. 763.

Fig. 764.

Figs. 761 and 762.—Oblique fractures of the shafts of the tibia and fibula. Accurate reduction impossible by non-operative means. Anteroposterior and lateral views.

Figs. 763 and 764.—Oblique fractures of the shafts of the tibia and fibula. Reduction by open operation and fixation by Sherman plate and screws.

of the tendon of the calf muscles at the heel will often relieve displacement caused by gastrocnemius spasm. In ordinary cases the flexion of the knee by swinging the box splint relaxes this muscle enough.

When there is a marked tendency to recurrence of deformity after attempts at reduction and operative measures are contraindicated, traction upon the lower fragment may be made with the hip and knee flexed, using the modified Zuppinger apparatus (Fig. 756). When there is no tendency to displacement of fragments, a convenient form of dressing is the Cabot posterior and side splints.

Operative Treatment (Figs. 757–770).—When it is found impos-

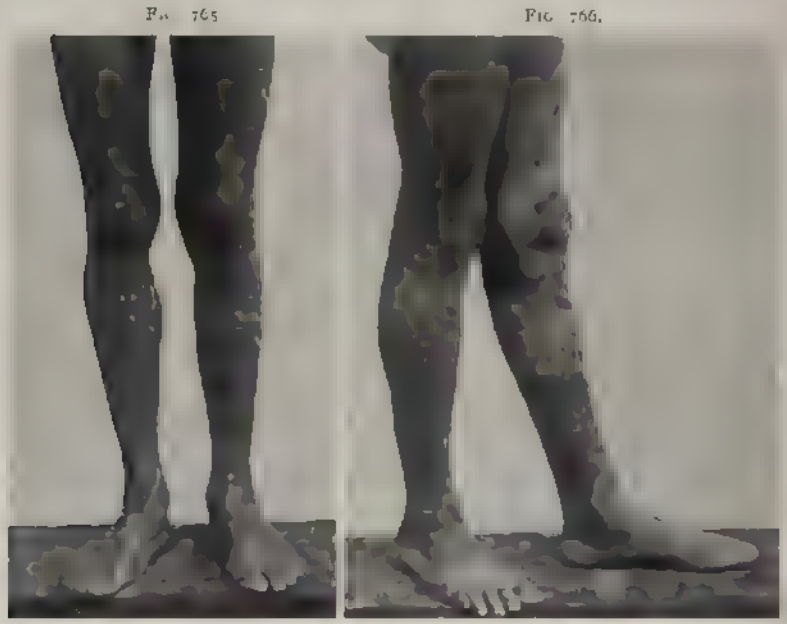

FIG. 765. FIG. 766.

FIGS. 765 AND 766.—Photographs showing result obtained in fracture of shafts of tibia and fibula. (See Figs. 761 to 764.)

sible to maintain anatomical apposition of fragments as proved by inspection and confirmed by radiograph, which is unusual, and there are no contraindications to operation, it is proper to operate and retain the fragments in their normal position by a bone inlay or by a metal plate. This is seldom necessary in the usual fractures. Care should be taken after the application of the plate to continue traction and prevent angulation at the seat of fracture until the wound is closed, and a sterile dressing and gypsum case applied. In operative cases treated by metallic fixation, the time for union is a little longer than when the fragments are correctly apposed and treated without operation for direct fixation. The after-treatment is the same as that given under

Fig. 767

Fig. 768



Figs. 767 and 768.—Transverse fracture of the tibia with incomplete fracture of the fibula. Baseball player injured sliding into second base. Failure of reduction of fragments by non-operative measures. (See Figs. 769 and 770.)

Fig. 769

Fig. 770.



Figs. 769 and 770.—Transverse fracture of the tibia and incomplete fracture of the fibula. Reduction by operative means and fixation of tibial fragments by Sherman plate. (See Figs. 767 and 768.) (Courtesy of Dr. J. M. Speldissy.)

non-operative treatment. The plate is to be buried under the muscles on the outer side of the shaft, according to Lane's technic, who leaves it indefinitely in the tissues. It would seem likely that a superficial plate

on the subcutaneous surface of the bone would answer as well for fixation, and always be easily removed by incision after its usefulness had ended

Open Fractures.—In infected open fractures, the principal objects are to control hemorrhage and primarily to render the wound aseptic, for the details of which treatment the reader should consult the paragraphs on general treatment of open fractures

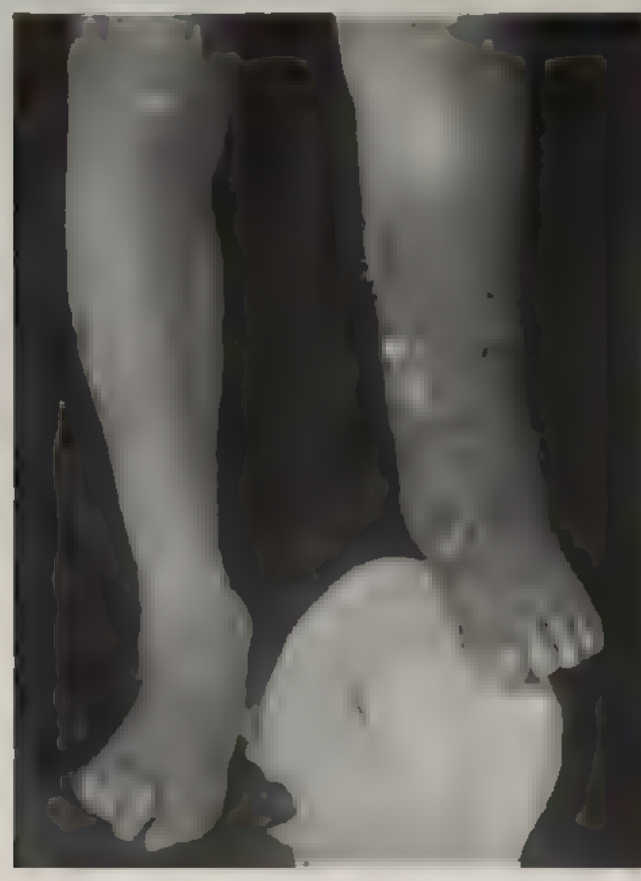

FIG. 771.—Photograph showing a result often obtained in badly comminuted open fractures of the bones of the leg followed by suppuration

Open cases may be treated on a posterior Cabot or wooden splint with foot-piece, and by using side splints or a divided gypsum case extending above and below the seat of fracture.

It is in the opinion of one of the authors proper to treat infected open fractures by the fracture-box and gypsum splint, as are closed fractures. The primary care of the wound if successful will permit it to rapidly heal and the fracture box may then be superseded by the gypsum encasement. If the wound suppurates the fracture box may

Fig. 772.

Fig. 773.

Fig. 774.

Fig. 775.

Fig. 772.—Spiral fracture of the shaft of the tibia.

Fig. 773.—Transverse fracture of the shaft of the tibia.

Fig. 774.—Transverse fracture of the shaft of the tibia with the separation of a three-cornered fragment.

Fig. 775.—Comminuted fracture of the shaft of the tibia.

be used for a longer period and the gypsum case, which is then substituted, may have an opening like a window cut in for inspection and dressing of the wound. Drainage is important in bad infections.

The report of the Committee on Fractures of the British Medical Association shows that in closed fractures of both bones the per-

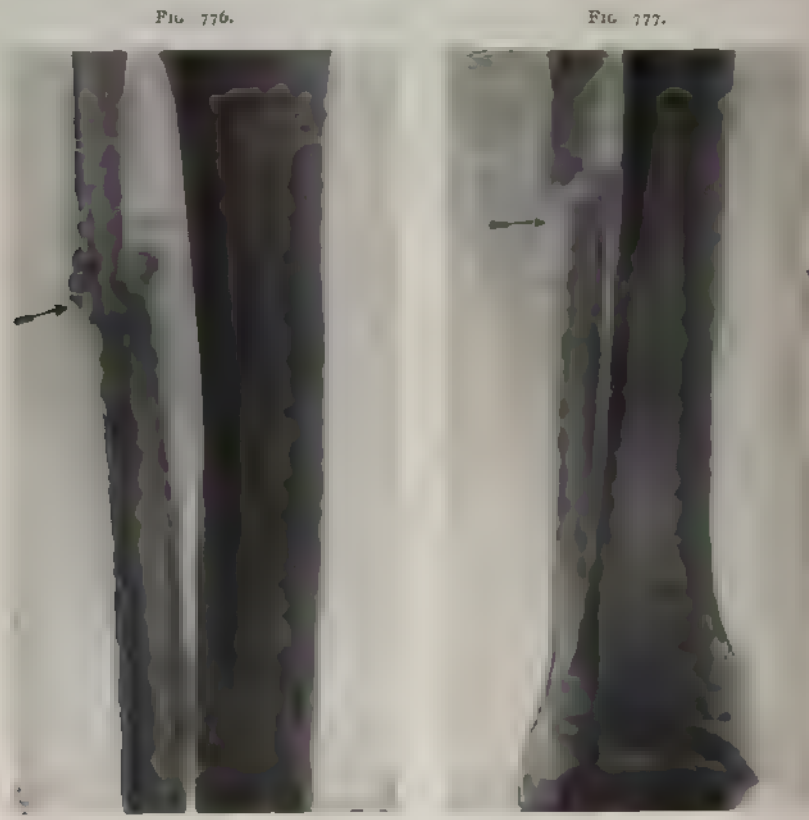

FIG. 776. FIG. 777.

FIG. 776.—Comminuted fracture of the shaft of the fibula. Direct violence.
FIG. 777.—Oblique fracture of the shaft of the fibula.

centage of good anatomical and functional results by non-operative means was 44.4 and by operative means 63.6, that good functional results with poor anatomical results were obtained in 70 per cent. by non-operative means and 68.1 per cent. by operative measures, while in fractures of the tibia alone the percentage was, respectively, 74.4 and 76.4. The improvement in treatment of isolated tibial fractures is due in a great measure to the intact fibula acting as a splint for the tibia.

The poor results found in the non-operative treatment by this Committee is believed by one of the authors to be largely due to prolonged immobilization, infrequent inspection, and negligence of early mild massage and mobility, so frequent in British surgery until Lane's

propaganda for operative treatment caused scientific non-operative treatment to be more usual. The Reports of the Committee of the American Surgical Association for 1913–14–15, etc., will be found of interest in this connection.

Isolated Fractures of the Shaft of the Tibia.—Plagemann's Rostock statistics based on 1393 fractures show isolated fractures of the shaft of the tibia in 24 cases (1.79 per cent.) and of the fibula 30 cases (2.15 per cent.).

Isolated fractures of the shaft of the tibia are rare (Figs. 772-775). When the tibia is broken by direct violence the fibula may

FIG. 778. FIG. 779.



FIG. 778.—Supramalleolar fractures of the tibia and fibula.
FIG. 779.—Supramalleolar fracture of the tibia.

escape injury, but often it is also broken; when the fracture of the tibia is due to indirect violence, the weak fibula is unable to sustain the weight of the body thrown upon it and is also fractured.

Symptoms.—The symptoms of isolated fracture of the tibia are similar to those of fracture of both bones of the leg, but have certain modifications. The patient may be able to bear some weight on the leg if the fracture line is transverse and the fragments interlocked. There is only moderate mobility of fragments, slight over-riding, crepitus, localized pain, tenderness and swelling but not so much deformity, and axial rotation of the lower fragment. The sound fibula tends to act as a splint for the fractured tibia.

Treatment.—As there is not such a tendency to over-riding and



Fig. 780.

Fig. 781.

Fig. 782.

Figs. 778, 779, 780, 781 and 782.—Types of supramalleolar fractures of the tibia and fibula.

deformity as is seen when both bones are broken, ordinary non-operative measures will more often give a good anatomical and functional result. The treatment is the same as given above for fracture of both bones. Weight-bearing in walking need not be postponed so long as in fracture of both bones of the leg. In spiral and oblique fractures in this region, it may occasionally be found necessary to operate and directly fix the fragments.

Isolated Fracture of the Shaft of the Fibula (Figs. 776 and 777).—This injury is generally caused by direct violence.



FIG. 783.—Supramalleolar fracture of tibia and fibula. Oblique fracture occurred in the tibia starting on the fibular side 9 cm. from the ankle joint and passing downwards and inwards to a point 3.5 cm. above the apex. (Mütter Museum No 1427.81).

Symptoms.—There is little if any tendency toward displacement of fragments on account of the firm attachment of muscular structures. Over-riding, axial displacement and angulation are extremely rare. There may at times be some lateral displacement inward of the upper end of the lower fragment. The chief symptoms are localized tenderness, pain on direct pressure, and on forcing the shaft of the two bones together crepitus may be demonstrated. Locally there is generally some bruising of the soft parts, swelling, and later ecchymosis. Walking is often possible but generally attended by considerable pain.

Treatment.—As there is little displacement of fragments, all indications for treatment are met by immobilization in a gypsum splint extending from the toes to just below or a little above the knee. This dressing should be used for from three to five weeks and be followed by a bandage. Weight-bearing may be begun at the fifth to sixth week.

Fractures of Lower End of the Tibia and Fibula. — SUPRAMALLEOLAR FRACTURES (Figs. 778–783).—This class includes all breaks occurring within the lower one and a half to two inches of the lower end of the tibia. Many of them are extra-articular, while a fair proportion involve the tibiotarsal joint. Comminution of fragments is fairly constant.

Statistics.—Plagemann's statistics show 22 cases of fracture. In 13 instances the fractures were extra-articular; and of these the fracture line was transverse 6 times, oblique in 2 cases, spiral 3 times, and in 2 cases there was a transverse fracture with a breaking off of a

three-cornered piece of bone. In 7 cases the line of fracture extended into the ankle-joint, and of these 4 were classified as T- or Y-fractures and 3 as severe comminuted fractures; in 2 cases there was found a transverse fracture of the internal malleolus. The fibula was 11 times fractured approximately at the same level, 8 times in the external malleolus; twice there was a double fracture of the fibula, in one case involving the lower third of the shaft and external malleolus, and in the other the neck of the fibula and the external malleolus.

Etiology.—These fractures may be the result of direct violence, as in severe blows above the ankle, and run-over accidents, but as a rule they result from indirect force, as in falls from a height, with the patient landing on his foot in an inverted or everted position. The result is a fracture, above the malleoli, transverse, oblique, spiral, or longitudinal in character. An accompanying fracture of the fibula is usually present.

Symptoms.—In fractures not involving the joint the symptoms are more or less similar to those of fracture of both bones in the lower third of the shaft. Usually there is marked swelling of the entire lower leg, pain, ecchymosis, deformity, undue mobility, lateral or posterior displacement of the foot and lower fragment, crepitus, and inability to bear weight on the foot. In fractures involving the joint there is, in addition, widening of the ankle-joint; and there may be displacement upward of the astragalus between the fragments into the interosseous space.

Diagnosis.—The condition should be carefully differentiated from dislocation of the foot, fracture of lower third of shaft, and fracture of the lower part of the fibula with posterior dislocation of the foot.

Prognosis.—The prognosis for a good result without deformity and without restriction of the motion at the ankle-joint is particularly grave when the fracture is comminuted or involves the ankle-joint. Even in cases which do not involve the ankle-joint, impairment of motion and deformity are frequent; but this defect may usually be averted by careful attention to reduction and sufficient solicitude about maintaining the integrity of the soft tissues by massage and early mobility.

Treatment.—Treatment consists in reduction of fragments by traction and manipulation, immobilization for one week or more in pillow and side splints or a swinging fracture-box and later in a gypsum case. Care should be taken to secure as nearly normal apposition of fragments as is possible and to correct all external deformity. Immobilization should be continued for at least six to eight weeks, but at the end of two or three weeks or earlier careful massage and passive motion may be given. Weight-bearing may begin about the end of the tenth or fifteenth week, varying with the line of fracture and the weight and work of the patient. A high sole on uninjured side with crutches a few weeks

FIG. 784.



A B

FIG. 784.—Fracture of internal malleolar portion of lower epiphysis of the tibia, anteroposterior and lateral views.

FIG. 785

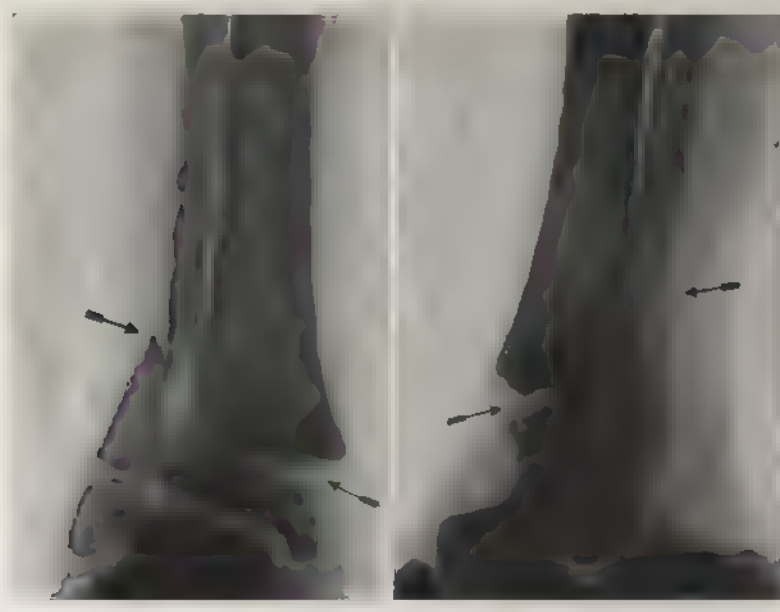

A B

FIG. 785.—Separation of the lower tibial epiphysis with fracture of the fibula, anteroposterior and lateral views.

longer is better surgery than hasty ambulation with resulting bending at the seat of break. It was the bad mechanical results in these fractures that caused Lane to examine London policemen and other constant walkers, who had sustained ankle fractures. He found bad final results with grave disabilities. In many the axis of the limb was permanently altered with resultant change in the bearing of the articular planes on one another. Even after unassisted walking is allowed a high-laced shoe or boot is a desirable support to the ankle for some months. This offers protection against sudden misstep.

Separation and Fracture of the Lower Epiphysis (Figs. 784–786).—Complete separation of the lower epiphyses of tibia and fibula is an extremely rare injury. The lesion which is most frequently observed is not a complete separation, but a fracture through the tibial epiphysis with a tearing off of a small portion of the diaphysis. The line of fracture through the diaphysis is a high fracture through the internal malleolus and through the internal and anterior portion of the diaphysis. These injuries are observed before the twentieth year.

Etiology.—The cause of these fractures is either marked forcible eversion or inversion of the foot, as in jumping or in falls from a height.

Symptoms.—Displacement of fragments is usually very slight. The usual symptoms are those of an acute synovitis of the ankle-joint, or a sprain, and in addition localized pain on motion, tenderness on pressure over the epiphyseal line, and at times cartilaginous crepitus.

Treatment.—In the absence of displacement of fragments the treatment consists in immobilization in a gypsum case for four weeks, after which time the patient may be allowed to use the leg with the ankle region supported by adhesive plaster strapping.

Malleolar Fractures

Fracture by Eversion and by Abduction.—The term Pott's fracture is erroneously given by the majority of physicians to all fractures occurring about the ankle-joint. This is a mistake. The lesion described by Percival Pott is a fracture of the fibula not higher than two to two and a quarter inches above the tip of the external malleolus, which is the weakest point of the fibula and just above the tibiofibular ligament, with a rupture of the internal lateral ligament accompanied by outward dislocation of the foot. The term as now used includes cases in which there is a tear- or strain-fracture of the internal malleolus instead of a mere rupture of the internal lateral ligament. The name Pott's fracture should be dropped and the descriptive anatomical term employed.

Etiology.—Indirect violence is the cause of the majority of these fractures. The injury is the result of a combination of factors—usually eversion of the foot, rotation about its long axis, and abduction

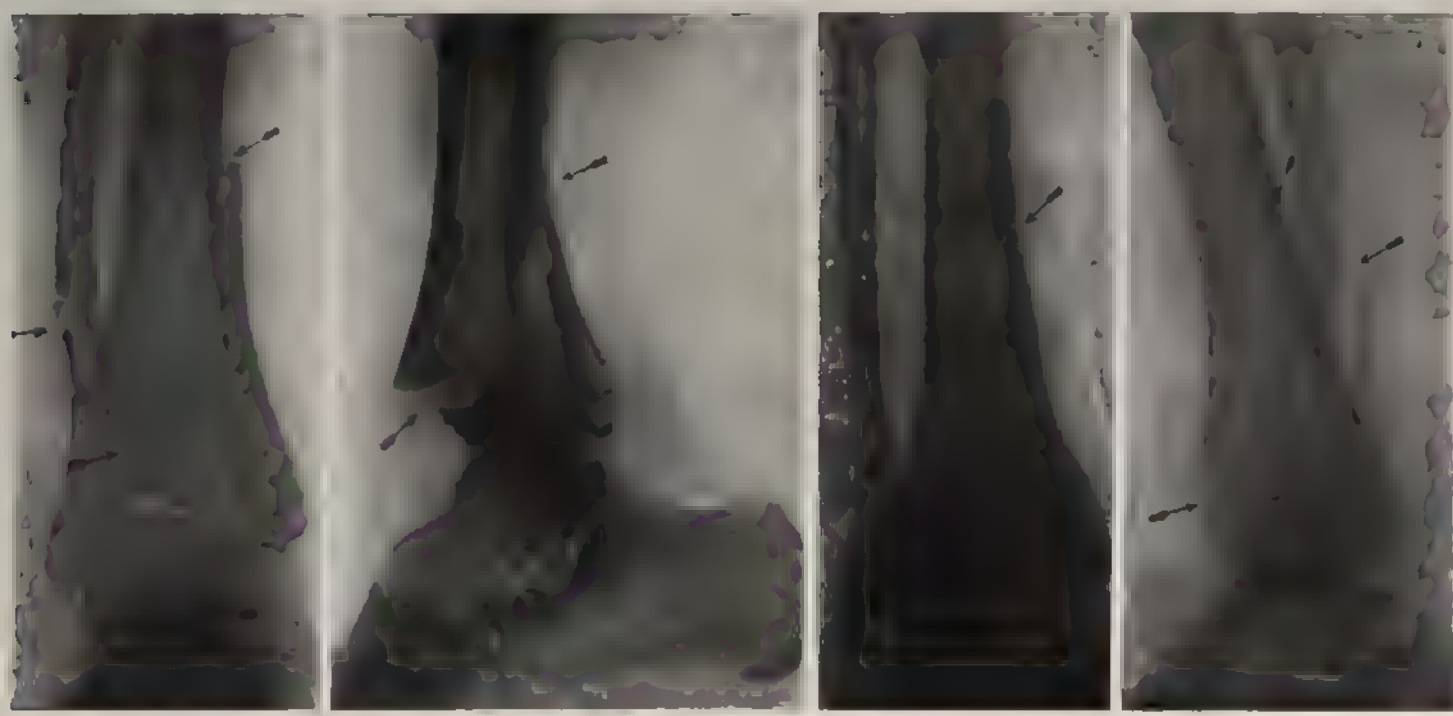

A B C D

FIG. 786.—Separation of lower tibial epiphysis with fracture of lower end of diaphysis and fracture of the lower end of the fibula. Anteroposterior and lateral views (*A* and *B*) before reduction, (*C* and *D*) after reduction.

from the vertical axis of the leg. It is liable to occur when the foot is firmly held, and the body forced outward by violent rotation of the leg when the foot is fixed, and by falls upon the foot when it is everted or abducted.

Mechanism of Fractures.—The mechanism of the fracture is explained as the resultant of two forces—pressure and traction (Figs. 787 and 788). In falls outward with the foot fixed, eversion and abduction of the foot are produced, the internal lateral ligament is stretched, and, as it rarely ruptures, the force tears off the internal malleolus, generally at its base; as the force continues the astragalus is forced against the external malleolus, fixing the latter, at the same time the weight of the body falling outward carries with it the leg and the fibula; the fibula is checked by the astragalus and kept attached to the tibia by the tibiofibular ligament; either the latter ruptures or a line of fracture occurs at the weakest point of the fibula just above the point of attachment of the tibiofibular ligament. It is here that the fixed portion of the fibula meets the potential moving upper portion, and fracture occurs about two to two and a quarter inches above the malleolus. The line of fracture of the fibula depends to a great extent upon whether the fall is directly outward or whether some torsion of the tibiotarsal joint occurs at the moment of fracture. Another result of this mechanism may be fracture of the internal malleolus, as above described, with fracture of the external malleolus just above the level of the tibiotarsal joint by outward pressure of the astragalus.

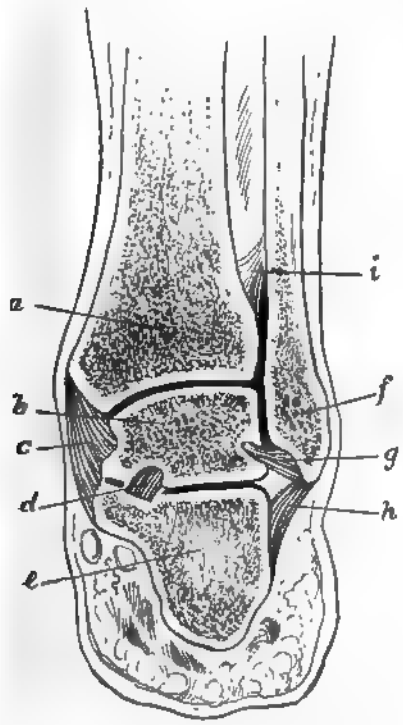

FIG. 787.—Drawing to show the normal structures of the ankle-joint. *a*, tibia; *b*, astragalus; *c*, internal lateral ligaments; *d*, interosseous ligament; *e*, calcaneum; *f*, fibula; *g*, posterior fasciculus and *h*, middle fasciculus of external ligament; and *i*, interosseous or tibia-fibular ligament.

Displacement (Figs. 789–793).—In typical cases the line of fracture of the fibula is oblique or spiral in character and is situated within the lower two and a quarter inches of the lower end of that bone. The foot is usually rotated outward and later abducted. When this displacement takes place the upper end of the lower fragment is displaced inward and the external malleolus outward; when there is

considerable tearing across the anterior capsule of the joint, there is generally posterior dislocation of the entire foot with accompanying displacement of the fibular fragment. When there is, in addition, fracture of the tibial malleolus instead of simple tearing of the internal lateral ligament, the line of break is generally transverse across the base of the malleolus and the separated fragment is displaced outward with the astragalus, and posteriorly if the latter is so displaced. There occurs a variety of this fracture in which the fibula is broken above or through its malleolus and the tibia fracture by a line running oblique upward and outward from the articular surface of the lower end of the tibia. In this injury the break of the tibia is perhaps often

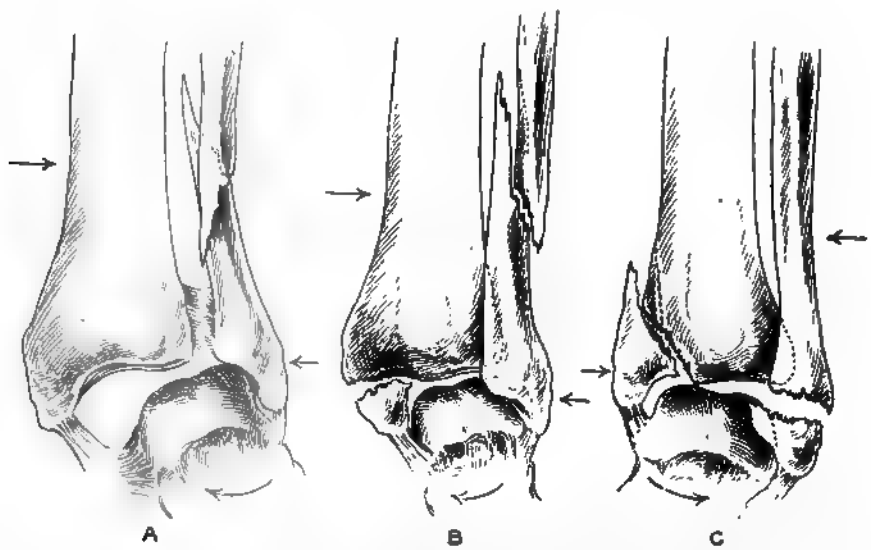

FIG. 788.—Drawing to show the most common types of fracture about the ankle-joint, made after Röntgenograms (Figs. 789, 790 and 802) and methods of reduction of these types of fractures. *A*, fracture of fibula with rupture of the internal lateral and tibio-fibular ligaments; *B*, fracture of the fibula with fracture of the internal malleolus, and *C*, fracture of the external and internal malleolus. Figs. *A* and *B* are types of the classic Pott's fracture by eversion and abduction of the foot and Fig. *C* is of the reversed Pott's fracture by inversion and adduction of the foot. The arrow in each figure shows the direction of force necessary to reduce these fractures.

overlooked. It is liable to permit marked displacement of the foot backward, and may be mistaken for a backward luxation of the tarsus at the astragalotibial joint.

Symptoms.—All of these cases are not characterized by deformity when seen by the surgeon, for in many the deformity has been reduced by a friend pulling upon the foot. The most notable symptoms are generalized swelling about the ankle, localized on the inner side about the tip of the internal malleolus and on the outer side localized not at the tip of the fibular malleolus but somewhat above the malleolus. There is localized pain which is increased on attempts at walking. Palpation reveals tenderness on pressure and crepitus about two inches

above the tip of the external malleolus (Fig. 793) with moderate angulation of fragments; and over the internal malleolus there may be felt the sharp edge of the tibia from which the internal malleolus has been torn. This is particularly noticeable if external lateral displacement of the foot is made. Crepitus may also at times be detected over the internal malleolus. When the lesion is a mere rupture of internal lateral ligament and not a fracture of the internal malleolus, no crepitus is discoverable in this region. By grasping the leg with one hand and the foot with the other, abnormal lateral mobility of the foot in the mortice of the ankle-joint may be obtained in some case (Fig. 794).

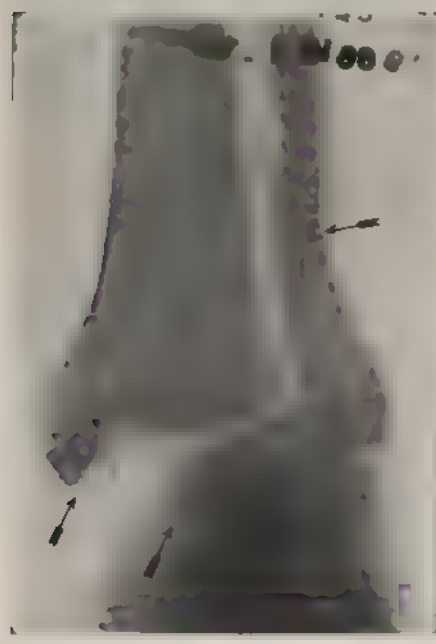

Fig. 789.—Fracture of fibula with rupture of internal lateral and tibio-fibular ligaments.

When there is displacement of the foot, it will be noticed that the foot is slightly abducted and everted in the valgus position. A line drawn through the long axis of the tibia normally is prolonged between the first and second toes; but, in the presence of this displacement of the foot, it falls to the inner side of the foot. There is also prominence of the upper fragment of the tibia at the region of the internal malleolus and apparent broadening of the ankle-joint. On the outer side of the ankle-point there is angular deformity corresponding to the fracture of the fibula.

If there has occurred marked laceration of the anterior and posterior portions of the joint capsule, a posterior as well as an outward displacement of the foot may be present. This may be determined by comparison of the lateral aspects of the injured leg and foot with the sound side by palpation; it will be noticed that the lower articular edge of the tibia may be felt at the ankle, and by grasping the foot and leg with the two hands it is possible to demonstrate the dislocation by pulling the foot forward on the leg. In all cases radiograms should be made in antero-posterior and planes not only to determine the variety of fracture, but also the amount of displacement of fragments. The supra-malleolar fracture of the fibula with fracture of the lower end of the tibia, without its line involving the tibial malleolus at all, but running into the astragalotibial joint, has been called by some the



A *B*

FIG. 790.—Fracture of the fibula with fracture of the internal malleolus: anteroposterior and lateral views.



A *B*

FIG. 791.—Fracture of the fibula (low) with fracture of the internal malleolus. Anteroposterior and lateral views.

drunkard's fracture. It permits marked eversion and posterior displacement of the foot, and is differentiated from luxation by crepitus and the easy reproduction of the deformity after reduction under ether.

Prognosis.—The prognosis of Pott's fracture of the fibula depends upon the accuracy of replacement of fragments, the maintenance of normally apposed joint surfaces, and the original severity of the lesion. Fractures of the internal malleolus with supramalleolar fracture of the fibula should give good results, if the fragments are returned to their relations and held so until union is firm. Even when there is considerable laceration of the joint capsule or of the internal lateral and tibiofibular ligaments, the prognosis for weight-bearing

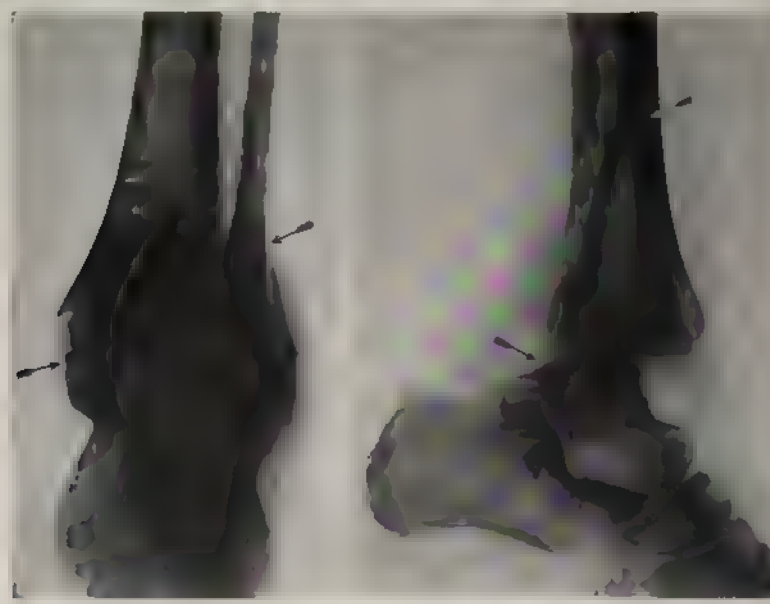

A B

FIG. 792.—Fracture of the fibula with fracture of the internal malleolus. Marked posterior displacement of the foot. Anteroposterior and lateral views.

should be good, but function may be more or less permanently impaired. When there is persistent eversion of the foot, permanent disability results from the weight of the body being carried on the foot out of proper line. This produces a strain upon muscles, ligaments, and joint surfaces, so that there is lameness and increased tendency to deviation from the normal axis, and a permanent valgus position ensues. It is very liable to occur when the nature of the lesion has been misunderstood in the injury called drunkard's fracture of the tibia and fibula.

Treatment.—To obtain good functional results in the different varieties of fracture of tibia and fibula at the ankle, there must be accurate reduction of fragments and a corrected position of the foot

with efficient control of its anatomical relations until union takes place. In all but the cases with little or no displacement, reduction should be performed immediately after the diagnosis is made, and is best obtained with the aid of general anæsthesia. There are three movements necessary in making perfect reduction: The foot must be carried forward to overcome posterior dislocation, and inward in order to bring

FIG. 793.



FIG. 793.—Method of determining crepitus in fracture of the lower end of the fibula by rocking of the lower fragment.

FIG. 794.



FIG. 794.—Method of determining lateral mobility of the ankle joint in fractures of the malleoli.

the base of the tip of the internal malleolus to its proper site on the tibia and to correct outward displacement of the astragalus and that of the lower fragment of the fibula, and slight inversion made to relax the tension of the internal lateral ligament on the internal malleolus and to prevent subsequent valgus deformity (Fig. 795). To do this one should grasp the leg firmly, with one hand above the ankle on the inner side and with the other hand seize the heel and foot; then pull

the latter forward, push it inward, and at the same time pull the leg outward. This procedure will thoroughly reduce the fragments and bring them into their normal relations. The foot and leg are then placed in a pillow and side splints up to the knee and held in this dressing until maximum swelling has ceased, which is about three to four days (Fig. 796). A suspended fracture-box is an exceedingly valuable dressing in fractures at the ankle It is greatly preferred by one of the authors to other means of support for the first two weeks.

FIG. 795.—Method of reduction of classic Pott's fracture by forced inversion of the foot and correction of posterior displacement if it is present



FIG. 796.—Application of a pillow and side splints for temporary immobilization of fragments before placing the foot and leg in a gypsum case. This form of immobilization should be used until the maximum swelling begins to disappear

If a primary radiograph has not been taken, one should now be made in two planes if possible. If anatomical apposition of fragments is known to be present, the foot and leg are placed in a gypsum case, extending from the toes to just below the knee. In applying this case care should be taken to maintain the fragments in their normal position, the foot should be held at right angle to the leg and in a position of slight inversion (Fig. 797). The case should be split down each side, making

an anterior and a posterior portion so that frequent observations may be made, or a single split down the front may be used to enable the surgeon to remove it every day or two. At the end of two and a half weeks a second case should be applied, the patient allowed on crutches, and at the end of from five to seven weeks the case may be discarded and an adhesive plaster dressing used, for maintaining support to the healing fracture. Weight-bearing should not be permitted until the end of eight or nine weeks on account of the possibility of distortion of the ankle due to soft callus. Careful massage and passive motion should be instituted from an early period. Some surgeons believe not till the end of the fourth week. Others believe it better to begin cautiously a few days after the receipt of injury. The longitudinal arch

FIG. 797.—Method of holding the foot and leg while a gypsum case is being applied. The foot should be slightly inverted, held at right angles to the leg and the leg supported by a sand bag as shown.

of the foot should be maintained in ankle fractures and the length of the dorsum restored by complete reduction of posterior displacement of the tarsal fragments of the tibia and fibula.

After-results.—Good results should follow proper reduction and the maintenance of accurate apposition of fragments. Unfortunately, these cases are often improperly reduced, carelessly observed, and it is only when convalescence should be established that deformity is noticed. Convalescence is often prolonged by persistent œdema, stiffness of the joint, and atrophy of muscles due to prolonged fixation. Haenel's statistics, quoted by von Bergmann, based on 40 cases, show 28 recovered (70 per cent.); 12 became disabled (30 per cent.) and the average loss of ensuing efficiency was about 50 per cent. These fractures, like fractures of the lower end of the radius, are often mis-

understood and badly treated. Good surgery will, in many cases, prove its value by obtaining practically ideal results in function as well as in contour by non-operative means.

Fracture of Fibular Malleolus with Fracture of the Posterior Articular Edge of the Tibia (Figs. 798-799).—This injury is no doubt a variation of the typical fracture of the external malleolar region. It consists of a supramalleolar fracture of the fibula, usually about one and a half to two inches above the tip of the malleolus, with fracture of the tibial malleolus and posterior articular surface of the tibia.

Etiology.—The etiology of the fracture is the same as that of the

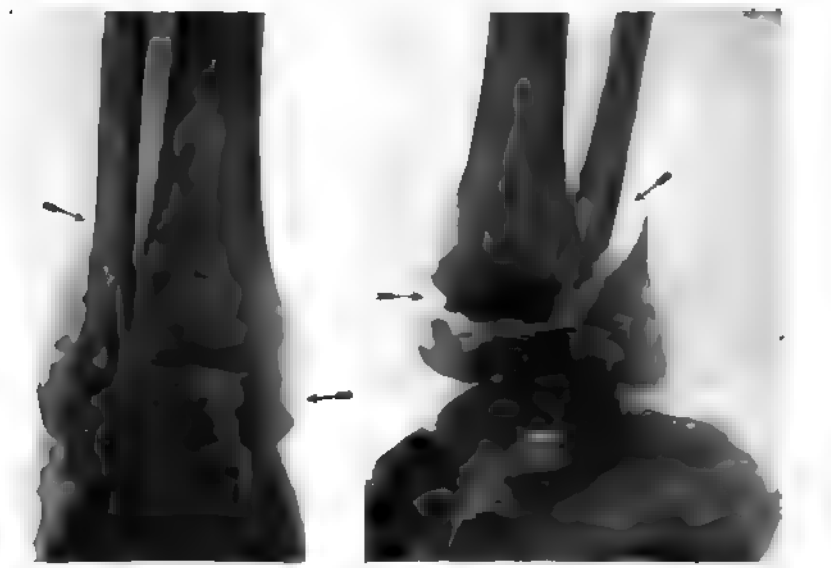

A *B*

FIG. 798. Fracture of the fibular malleolus with fracture of the internal malleolus and posterior articular edge of the tibia. Posterior displacement of the foot, anteroposterior and lateral views.

typical fracture just described, but in addition there is usually some plantar flexion of the foot.

Mechanism.—In addition to the usual mechanism of fracture of the fibular malleolus, the trochlear surface of the astragalus is forced against the posterior edge of the tibial articulating surface and a fragment, usually consisting of the internal malleolus and posterior edge, is broken off. Two fragments, one consisting of the internal malleolus and the other of the posterior articulating edge of the tibia, may be occasionally broken off. This condition is the exception. The anterior portion of the joint capsule is ruptured and the foot is not only dislocated inwardly, but also posteriorly, and usually is drawn upward by the calf muscles, so that in some instances the remaining articular surface of the tibia is displaced anteriorly to the trochlear surface of

the astragalus and rests upon the head of the latter, with consequent shortening of the leg.

Symptoms.—In addition to the usual symptoms of external malleolar fracture, there is marked dislocation backward of the foot. With this posterior displacement, there is a marked tendency for recurrence and there can be felt anteriorly the prominence of the anterior edge of the articulating surface; in some cases there may be distinct dislocation in addition to the fracture. Measurement from the inner tuberosity of the tibia to the tuberosity of the scaphoid will

FIG. 799. FIG. 800

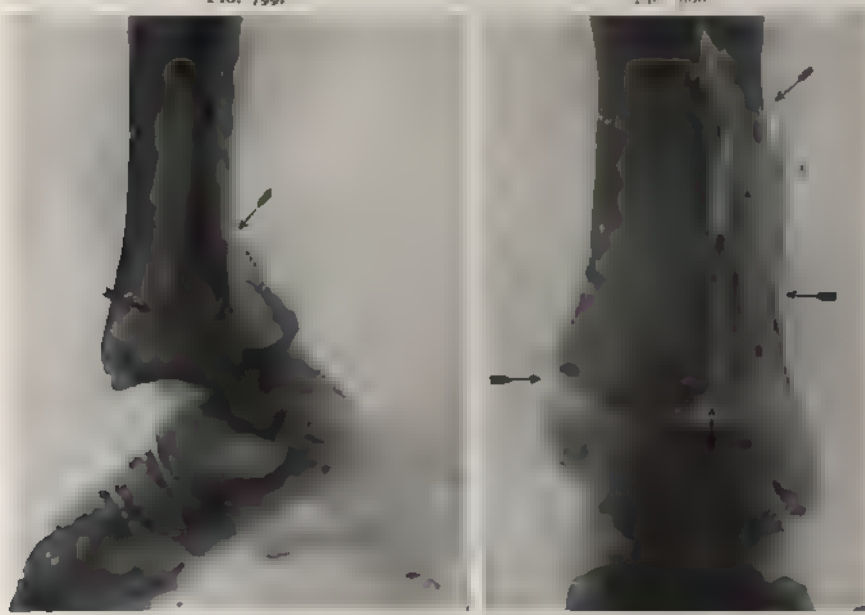

FIG. 799.—Fracture of the fibular malleolus, internal malleolus, and posterior articular edge of the tibia. Posterior displacement of the foot. Note the prominence of the anterior edge of the articulating surface of the tibia and evident shortening of the leg, due to upward and posterior displacement of the foot.

FIG. 800.—Fracture of the fibula, of the internal malleolus and of the external articulating edge of the tibia.

show shortening as compared with the other side. A radiographic examination should be made if practicable. The differential diagnosis from the usual fracture can ordinarily be made upon the tendency to prompt posterior and upward dislocation of the foot upon relaxing one's anterior pull of the foot.

Prognosis.—This depends in great measure upon primary recognition of the condition, and efficient treatment. Owing to involvement of the supporting surface of the tibia, there will be a more prolonged convalescence and lessened function as compared with the usual fracture in the malleolar.

Treatment.—Owing to the liability to recurrence of displacement of fragments after reduction, it is advisable to immobilize the foot and leg in a fracture-box after reduction and later to use a gypsum dressing, preferably a gypsum case, from the toes to the knee. Reduction should be performed under general anæsthesia. In addition to the method of reduction described under the treatment of malleolar fracture, the foot should be carried also into a position of dorsal flexion. After the application of the gypsum case it should be split so as to form two splints, or a fracture-box should be so used as not to cause too great constriction and to allow daily inspection. The accuracy of anatomical reposition of fragments should be gauged by the radiogram or by frequent inspection. Flexion of the knee in a swinging fracture-box, and even subcutaneous section of the tendon of Achilles, may be required to prevent recurrent displacement of the foot backward. Traction on the foot by means of a plantar footboard and pulley extension may be needed. Steinmann's nail traction from the heel may be used. Weight-bearing should be postponed for ten to fifteen weeks in severe cases or in heavy patients and then very cautiously permitted.

Fracture of Fibula with Fracture of External Articular Edge of Tibia (Fig. 800).—This is a rare fracture and must be considered as a variant of the fracture by eversion and abduction.

Etiology.—This lesion generally is due to a fall from a height in which there is an eversion and abduction of the foot. The weight of the body is of chief importance in its production.

Mechanism.—In addition to the mechanism described above under fibular fracture, there is the effect due to the weight of the body being applied simultaneously with the violence causing the supramalleolar fracture of the fibula; by this force the outer trochlear surface of the astragalus is carried sharply against the outer portion of the articular surface of the tibia, by external rotation and abduction of the foot, so that either the tibiofibular ligament must give way or the outer edge of the tibia be broken away from the shaft. Dislocation upward of the astragalus between the tibia and fibula may occur.

Symptoms.—The symptoms of this fracture are those of a simple fibular fracture with, in addition, an unusual widening of the joint. This widening is due to the separation of the tibia from the fibula when there is rupture of the tibiofibular ligament, or separation of the outer tibial fragment from the remaining portion of the lower end of the tibia. Accurate diagnosis usually requires a radiographic examination

Prognosis.—The recovery of good function will depend entirely upon the completeness of reduction and the maintenance of accurate apposition of fragments until union is firm.

Treatment.—On account of the possibility of upward and posterior displacement of the astragalus between the tibia and fibula, the

primary retention of the leg and foot in a pillow and side splints after reduction is not advocated. General anæsthesia should be used for reduction, which is to be accomplished as in the usual fibular fracture. Subsequently immobilization should be secured by a gypsum case applied from the toes to just below the knee. The plaster-of-Paris encasement should be immediately split into anterior and posterior portions.

Immobilization should last for at least six weeks and weight-bearing be allowed only cautiously at the end of about nine weeks. A swinging fracture-box for ten days or two weeks, followed by a circular gypsum encasement, is exceedingly satisfactory. Section of the tendon of Achilles may be used to prevent the displacing influence of grastrocnemius spasm.

Inverted Pott's Fracture or Fracture of the Fibula by Inversion and Adduction (Figs. 801 to 804).—This variety is not as common as fracture by eversion and abduction.

Etiology.—The fracture is the result of indirect violence, and usually is due to a fall with the foot in a position of inversion or adduction. It occurs in mis-steps, in jumping, and in sudden force applied to the outside of the leg when the foot is fixed.

Mechanism.—Potentially this particular fracture should be frequent, because often one makes a mis-step, the foot is inverted, and one feels a sharp, sudden strain at the point of attachment of the external lateral ligament. When fracture occurs there is a tear-fracture of the external malleolus and a pressure fracture of the internal malleolus due to forced inversion of the astragalus against the tibial malleolus. The line of fracture of the external malleolus is lower than that seen in the true fibular fracture with eversion, being usually transverse or slightly obiique, and occurring in a line continuous with the articular surface of the tibia; the line of fracture in the internal malleolus is higher than that seen in the eversion fracture, being triangular in shape and running from the lower articular surface of the tibia upward and inward. At times a portion of the weight-bearing surface of the tibia may be included in the detached fragment. Displacements of fragments and of the astragalus are not nearly so frequent as in the eversion fracture. The foot is often held in a varus position.

Symptoms.—The majority of these fractures show little displacement of the foot. When it is present it is always inward and there is also moderate inversion. Lateral mobility may be detected, as in the eversion fracture; it is, however, not so pronounced and is always inward while in Pott's or eversion fracture it is outward. Posterior dislocation of the foot is extremely rare. There is localized pain and tenderness over the lower internal end of the tibia above the malleolus, and a small movable fragment of bone may be palpated and crepitus



FIG. 803.

FIG. 802.

FIG. 801.

FIGS. 801, 802, AND 803.—Types of fracture of the malleoli by inversion and adduction of the foot. Inverted Pott's fracture.

is elicited. Over the external malleolus a loose fragment may also be discovered, but it is smaller than that seen in eversion fractures, and crepitus may be demonstrated by making lateral motion with the foot There is generalized swelling about the joint and effusion within the joint.

Prognosis.—These fractures usually should be followed with good functional results. There is not the same degree of injury to joint capsules and dislocation of fragments as there is in eversion fractures. Union occurs about the same time, and deformity is not so apt to be extreme. Efficient treatment is more likely to be obtained by the

A B

FIG. 804.—A typical inverted Pott's fracture. Note the high and transverse line of fracture of the fibula.

patient because the damage to soft parts and the tendency to displacement are less formidable.

Treatment.—In the majority of cases there is little displacement of fragments. Reduction may be accomplished without general anæsthesia. Reduction is obtained by inward pressure above the ankle on the outer surface of the leg and outer pressure at the ankle and foot on the inner surface. The over-correction need not be used on account of the possibility of subsequent malposition. The foot should be placed at right angle to the leg. The foot and leg should be placed in pillow and side splint after reduction, and this form of dressing should be used for three to four days. After this time the leg and foot should be kept in a moulded gypsum case, which should be split into anterior and

posterior portions for observation of position. In fractures in which the internal malleolar fragment includes a part of the supporting tibial articular surface, it may be necessary to apply a gypsum case immediately after reduction on account of the tendency to recurrence of displacement of this fragment.

Isolated Fractures of the Internal Malleolus (Figs. 805 and 806).—Isolated fractures of the internal malleolus are relatively infrequent. Many cases are probably considered to be sprains. They are usually the result of a fall upon the foot when it is everted and abducted, or of a fall outward with the foot fixed. The injury is in essence of the

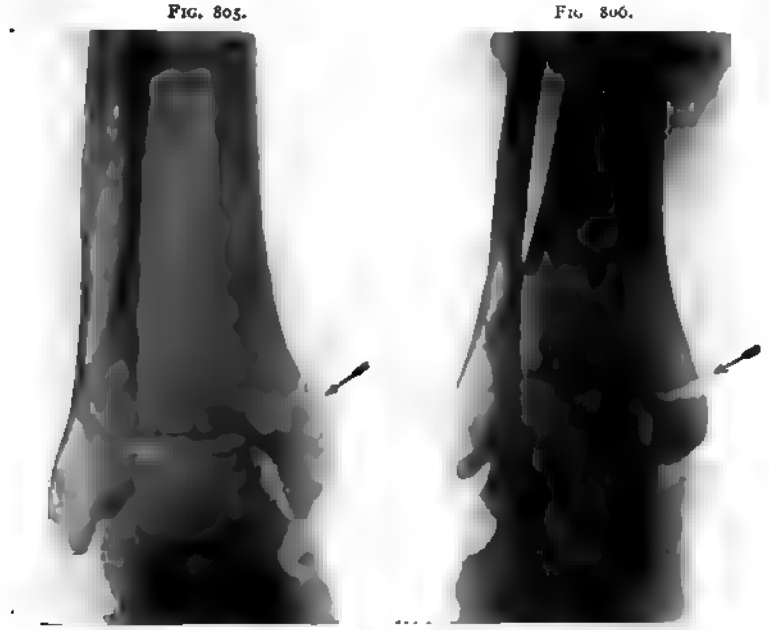

FIG. 805. FIG. 806.

FIGS. 805 AND 806.—Isolated fracture of the internal malleolus.

same character as that seen in eversion fracture of the fibula, but it is not so severe a lesion. The osseous lesion is due to a forcible pull of the internal lateral ligament upon the malleolus, and the line of break usually is limited to the malleolus. At times only a small particle of bone is detached. There is very little displacement of the fragments and little if any deformity. In such cases sprain-fracture is a very appropriate term for the injury.

Symptoms.—The usual symptoms are pain and tenderness limited to the region of the internal malleolus. There is generally a moderate degree of swelling in the region of the internal malleolus. Some lateral mobility of the foot may be possible in an outward direction, and with this movement crepitus may at times be developed. The lack of dis-

placement of the fragment is due to untorn portions of periosteum or ligament holding the fragments together. Patients are often able to walk.

Prognosis.—With proper reduction and immobilization a good anatomical and functional result is the rule.

Treatment.—Owing to the absence of displacement in the majority of cases, the only treatment necessary is immobilization in a gypsum case until union is firm, which occurs in about five weeks. Cases of slight gravity may be treated with adhesive plaster straps carried around the instep and heel so as to give support, as in sprains

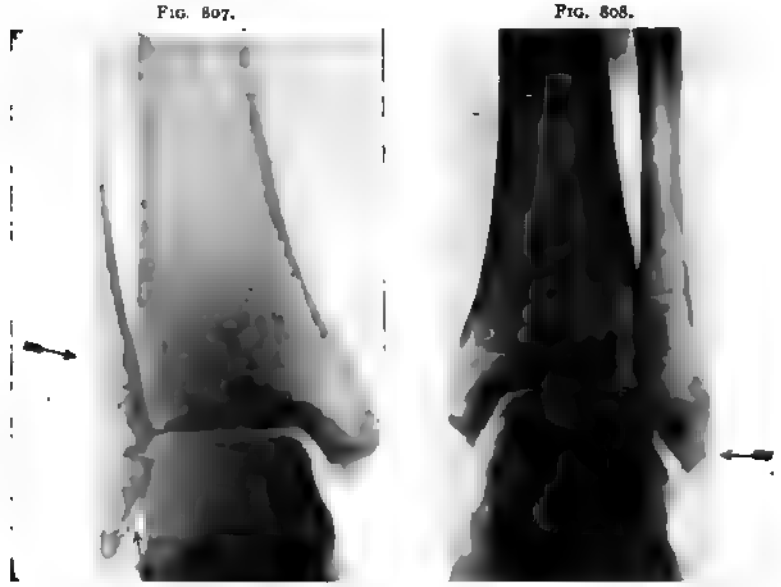

FIG. 807. FIG. 808. Isolated fracture of the external malleolus.

of this region. If there is any displacement of the fragments of the malleolus, the same rules for reduction and immobilization hold good as given under eversion fracture. Care should be taken for some weeks to avoid slips during walking, which might throw strain on the union. If the lower fragment shows a marked tendency to displacement, it may, if comparatively large, be kept in position with a slender screw or nail.

Isolated Fractures of the Lower End of the Fibula (Figs. 807 and 808).—Isolated fractures of the lower end of the fibula are frequent. They may be produced in two ways—by marked eversion of the foot as in the eversion already described, as a result of direct pressure of the astragalus upon the external malleolus, or by inversion of the foot, thus partaking of the nature of a tear-fracture. In the first variety

the line of fracture is usually about one and a half inches above the malleolus and may be oblique or spiral in direction; in the second form the fracture involves the external malleolus itself, and the line is more transverse in direction and may consist of a tearing off of the tip or but a small piece of the cortex of the bone.

Fractures by direct violence are extremely rare, and may involve any portion of the lower end of the bone. In only one of the above-mentioned types is there any tendency toward displacement. This occurs in the form due to eversion of the foot, where the line of fracture is well above the external malleolus. The astragalus may be slightly rotated outward, and the upper end of the lower fragment displaced inward toward the tibia.

Symptoms.—The symptoms of fracture of the lower end of the fibula are localized pain, tenderness and swelling *above* the tip of the external malleolus. Crepitus may at times be discovered and abnormal mobility demonstrated by a finger placed on the extreme end of the lower fragment and rocking it inward and outward. When the fracture is limited to the very tip of the bony process, the only symptom present may be pain, tenderness and swelling limited to the malleolus. Some cases are very difficult to recognize from sprains.

Prognosis.—The result, both anatomically and functionally, is usually good.

Treatment.—As there is rarely any displacement of the lower fragment, treatment consists in the use of a gypsum case applied from the toes to just below the knee, after the maximum swelling has disappeared. This dressing should be used for four weeks, and after the first few days removed daily for massage and passive motion. After the fourth week a supporting dressing of adhesive plaster is all that is necessary. Weight-bearing may be allowed at the end of the fifth week, but for several weeks care should be taken to avoid sudden strains on the external or fibulotarsal ligament or the broken process caused by mis-steps in walking. A laced shoe coming above the ankle in malleolar fractures should be worn for some time after cure.

Fractures of the Anterior Articular Edge of the Tibia (Figs. 809 and 810).—Fracture of the anterior articular edge of the tibia is an extremely rare injury. In a patient seen by one of the authors, the injury resulted from the fall of a heavy beam upon the anterior region of the ankle-joint when the foot was fixed.

Symptoms.—The symptoms of fracture are pain, swelling, and tenderness limited to the anterior region of the ankle-joint. Flexion and extension of the foot demonstrate crepitus, and with plantar flexion abnormal mobility of the fragment may be determined.

Treatment.—Reduction is accomplished by direct pressure backward of the displaced fragment, the corrected position maintained by

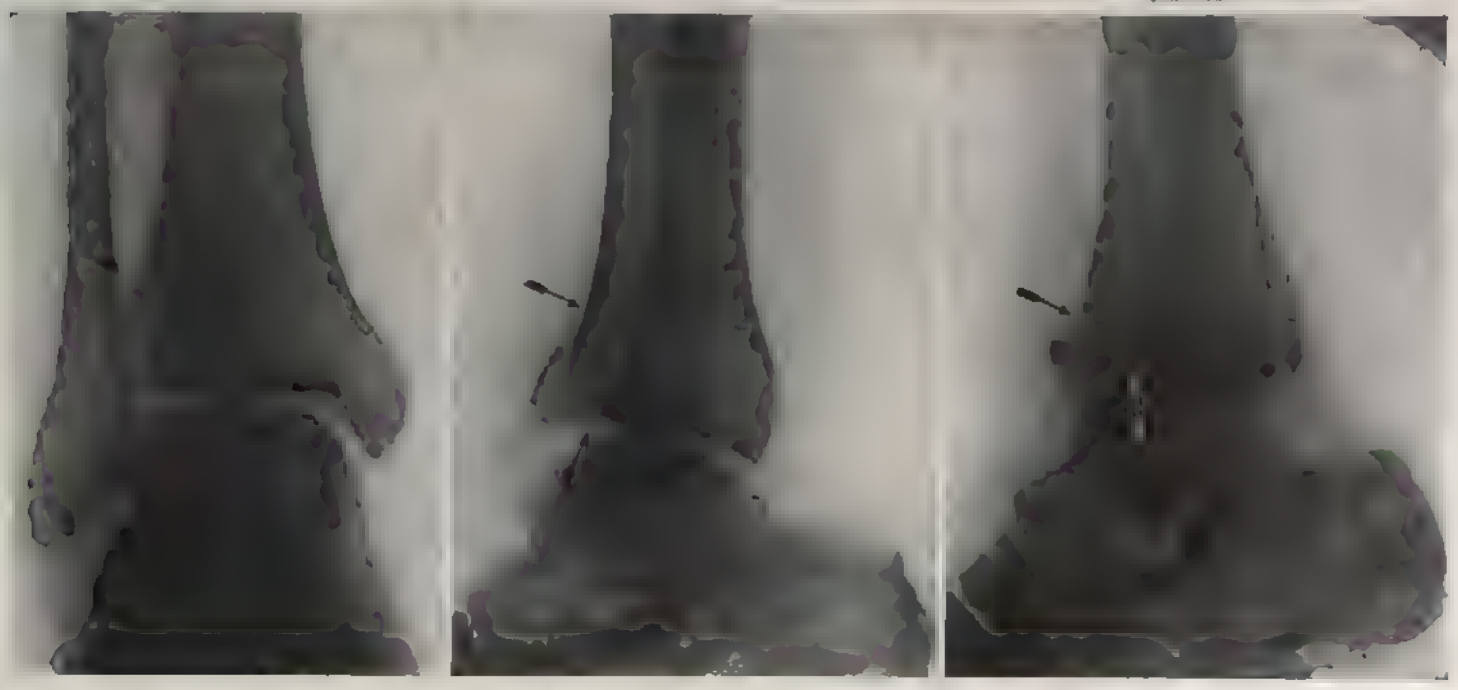

FIGS. 809 AND 810.—Fracture of the anterior articular edge of the lower end of the tibia. Direct violence.

immobilization of the foot and leg in a gypsum case, or an adhesive plaster cuff. A small pad or an indentation in the gypsum may assist in holding the fragment in place. Union occurs in from four to five weeks. Weight-bearing may be allowed at the end of five weeks.

Summary

REDUCTION FIRST ALWAYS

Upper End.—Fracture-box, not suspended, extending above knee; Cabot, lateral and posterior splints to control knee-joint in a similar manner; or a gypsum gauze encasement if not much swelling to be expected. In longitudinal fracture of head of tibia may, if needed, use drill pointed nail introduced through the skin to hold fragments in place.

Shaft.—Suspended fracture-box; inclined-plane fracture-box; Cabot posterior and lateral splints, lateral and posterior contour splints; or perhaps Buck's traction (with counter-traction) from ankle, sole, or footboard of fracture-box. Gypsum encasement later. Division of tendon of Achilles occasionally. Operative treatment and fixation with Sherman plate in rebellious fractures.

Lower End.—Suspended fracture-box, or Cabot lateral and posterior splints. Gypsum gauze encasement later. Do not permit weight-bearing early. Operative treatment occasionally for reconstruction of mortise-joint at ankle.

Deformed union should be treated, if bad, by osteotomy for restoration of weight-bearing in normal line.

CHAPTER XXIV

FRACTURES OF THE TARSAL BONES

Anatomy (Figs. 811 813).—There are seven tarsal bones: astragalus, calcaneum, cuboid, scaphoid, and the external, middle and internal cuneiform.

The astragalus articulates above with the tibia and fibula, below with the calcaneum, and in the front with the cuboid and scaphoid.

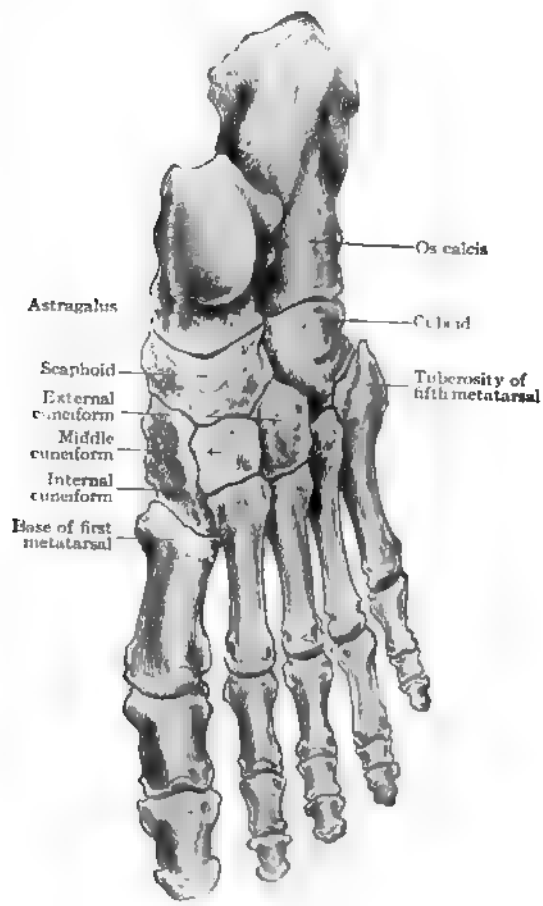

FIG. 811.—Anterior view of bones of foot. (Davis.)

It is an irregularly shaped bone, composed of a head, body, and neck. It has the trochlea for articulation with the tibia and fibula, the external and internal processes, a posterior process, and the sulcus tali.

The calcaneum is the largest of the tarsal bones and projects downward and backward to form the heel. It articulates with the astragalus by three articular facets, and with the cuboid. The various parts are the body, the tuberosity or posterior process, the internal and external processes, and the sustentaculum tali which projects toward the astragalus and bears the middle facet for articulation with the same.

The cuboid is placed on the outer side of the foot between the calcaneum and the bases of the fourth and fifth metatarsal bones. It is an irregular cube in form. The scaphoid is situated at the inner side of the foot between the astragalus posteriorly and the three cuneiform bones anteriorly. Its long axis is placed transversely to the long axis of the foot.

The three cuneiform bones are placed between the scaphoid pos-

FIG. 812.—Röntgenogram showing bones of normal foot, lateral view.

teriorly and the bases of the first three metatarsal bones. They are wedge-shaped, the internal being the largest and the middle the smallest.

Surface Markings.—Examination of the foot will show the following bony landmarks: Posteriorly may be felt the tuberosity of the calcaneum. Proceeding forward from this point on the external surface palpation discloses the external tuberosity of the calcaneum, the external malleolus of the fibula, the tubercle on the peroneal ridge of the calcaneum about two and a half centimetres below the external malleolus, and the tubercle at the base of the fifth metatarsal bone. On the internal surface of the foot one can palpate the internal tuberosity of the calcaneum, the internal malleolus of the tibia, the sustentaculum tali two and a half centimetres below the internal malleolus, the tubercle of the scaphoid about two and a half centimetres anterior to the in-

ternal malleolus, the internal cuneiform, and the prominence at the base of the first metatarsal bone.

Statistics.—Plagemann's statistics based upon 1393 fractures observed at the Rostock clinic and diagnosed by radiographs show 114 fractures (8.17 per cent.) of the bone of the foot, and of these 37 fractures 2.65 per cent. were of the tarsal bones, divided as follows:

	Cases	Per cent.
(1) Isolated fractures of the calcaneum	17	1.22
(2) Isolated fractures of the astragalus	5	0.359
(3) Fractures of the astragalus and calcaneum	4	0.290
(4) Isolated fractures of the scaphoid	7	0.509
(5) Isolated fractures of the cuboid	1	0.07
(6) Isolated fractures of the first cuneiform	3	0.21

Fractures of the Astragalus.—Fracture of the astragalus is frequently associated with fracture of the calcaneum or of the fibula or with dislocation at the ankle-joint.

Etiology.—Fractures of the astragalus are usually the result of great violence, which is occasionally direct; hence, they are often associated with severe injury to the soft parts, by which the fracture may even be made open. The fractures often are due to a fall from a height, in which the astragalus is broken by being crushed between the tibia and the calcaneum. Forcible dorsal flexion and direct injuries, in which other fractures are produced, may also be the productive agency.

Varieties.—Fractures of the astragalus may be divided as follows: Fractures of the neck, fractures of the body, and fractures of the posterior (Stieda's) process.

Fractures of the neck (Figs. 814–817) are usually transverse in direction and may be complete or incomplete. Usually there is very little displacement of fragments, unless the fracture is the result of great crushing violence, in which case there may be dislocation of one fragment and associated fracture of other bones or of the soft parts. The usual deformity in such cases is due to displacement of the body backward.

Fractures of the body (Figs. 818–821) of the astragalus follow no definite lines. The injury is usually comminuted, although at times there may be three definite fragments, consisting of head and neck, body, and the posterior process. Marked displacement of fragments is rare.

Fractures of the posterior process (Fig. 822): In some instances the supposed fracture of the posterior process is not a fracture at all; the apparent fragment is an independent bone, the "os trigonum," an anomaly in man, which occurs, however, in the lower vertebrates as a normal component of the tarsus. In many instances, however, this process is an integral part of the human astragalus and is subject to

fracture, either independently or in association with other fractures of the astragalus or of the tibia or fibula.

Symptoms.—In the absence of displacement of fragments the symptoms of astragalus fracture consist of swelling about the ankle-joint, tenderness on pressure limited to the region of the astragalus, pain upon attempt at weight-bearing, and flexion of the foot. Crepitus may at times be detected by lateral motion. In some cases a positive diagnosis cannot be made clinically until swelling has ceased, and there is found evidence of callus, which may be palpable, and persistent limitation of motion at the ankle-joint.

FIG. 813.—Röntgenogram showing normal bones of foot, anteroposterior view.

When there is actual displacement of a fragment, the piece generally may be felt in its abnormal position. There is loss of contour of the normal ankle, at times marked limitation of motion, and in compression fractures the level of the malleoli is lower than normal. The foot is usually everted and a moderate degree of valgus is present. In fractures of the posterior process there is pain, localized tenderness, and thickening behind the internal malleolus; at times crepitus and some limitation of motion. All suspected cases of fracture of the astragalus should be skiagraphed, and the variety of fracture and the degree of displacement of fragments thereby ascertained.

Prognosis.—As the majority of fractures of the astragalus are unattended by any marked degree of deformity, union should occur in

a few weeks' time and the functional result should be excellent. When there is marked displacement of the fragments or comminution of the bone, the condition is serious as to satisfactory restoration of mobility of the ankle-joint. Staley collected 122 isolated fractures of the astragalus and 68 in which there were associated fractures of other bones. In 50 instances the displaced fragment or the entire astragalus was removed; amputation was performed in eight cases. In many of the severe fractures, mobility at the ankle-joint is permanently impaired; occasionally necrosis of the unreduced fragment takes place. There may be permanent ankylosis, and in open fracture death may result from septicæmia. Von Bergmann considers that the earning capacity is impaired, at least, 15 to 20 per cent. or more, and on an average 30 per cent.

FIG. 814.—Fracture of neck of astragalus.

Treatment.—In fractures unattended by displacement of fragments, treatment consists in immobilization in a gypsum case applied after maximum swelling has subsided. The foot, if possible, should be placed at right angles to the leg and in slight inversion. The case should extend from the toes to just below the knee; it should be split down on both sides for observation of the soft parts and correction of unsatisfactory position; and at the end of two weeks massage and passive motion should be instituted. Immobilization should be continued for from four to five weeks, and after this time should be replaced by an adhesive plaster supporting dressing. Weight-bearing should be instituted at the end of the seventh week.

In closed fractures attended by displacement of fragments, a general anæsthetic should be given for reduction. By means of traction applied to the foot and manipulation, it may be possible to obtain satisfactory reduction. If this is not possible, open operation should be performed, and the fragments reduced by leverage. When this cannot be effected, the displaced fragment should be removed. In open fracture attended by displacement of fragments, in which reduction is impossible, the troublesome fragments should be excised. Satisfactory functional results attend removal of part or of the entire astragalus. After operation, the treatment will consist of immobiliza-

FIG. 815.—Compression fracture of neck of astragalus.

FIG. 816.—Fracture of neck of astragalus.

tion, followed by massage and passive motion. Cases may occur, perhaps, in which a fragment showing a tendency to slip out of place after reduction could be nailed in position by a drill or nail thrust through the skin. It is left in that position under an aseptic dressing for two or three weeks.

Results.—Stealy reviews 122 isolated fractures of the astragalus from the literature; 8 were direct fractures. In 18 cases the head was extirpated and in 31 cases the body was dislocated and extirpated. In 8 cases the entire astragalus was removed. Either malleolus was fractured in 11 cases and in 2 cases both malleoli were fractured. The os calcis was fractured in 15 cases and in two cases the os calcis was entirely removed. Twenty-four cases succumbed to septicæmia. Eight of these were classified in the isolated cases due to pressure necrosis. The foot was amputated in 8 cases, and in 1 case both feet were amputated.

Fractures of the Calcaneum.—Fractures of the calcaneum are the most frequent of the tarsal fractures. Formerly fractures of this bone were considered to be rare injuries, but the present frequent use of the Röntgen ray in examining injuries of the lower leg and foot has demonstrated their comparative frequency.

Etiology.—Fractures of the calcaneum result from falls from a height upon the foot in which the weight of the body is transmitted through the calcaneum, from falls upon the foot plus muscular action of the calf muscles, from sudden contraction alone of the calf muscles, from direct violence, and from forcible inversion of the foot.

FIG. 817.—Fracture of external process of astragalus.

Varieties (Figs. 823–832).—The following types of fracture are observed: avulsion, transverse, compression, and of the sustentaculum. Avulsion fractures are due to sudden contraction of the gastrocnemius and soleus muscle with the foot in a flexed position. The line of fracture is not on the walking surface of the bone, the detached fragment consisting either of a considerable portion of the upper and posterior part of the posterior process or of a small cortical piece at the point of insertion of the tendon of Achilles. The displacement of the fragment may be very slight, which is usually the case when the fragment is large; or it may be extreme in those cases in which only a small cortical fragment is torn loose. The fracture line may rarely involve a portion, or the entire epiphysis, of the posterior process. Transverse fractures are due to direct violence. The line involves the walking surface of

the bone, and usually runs from a point about midway on the upper surface downward and backward, so that a large posterior fragment is produced. This is rotated about a transverse axis, the upper end of the posterior fragment being somewhat displaced upward while the lower anterior portion of the calcaneum is displaced somewhat downward. Marked displacement is limited by the attachment of the plantar fascia. Compression fracture occurs. These fractures may be recognized radiographically only by changes in the density of the shadow, in the shape of the os calcis or its typical lamellar structure, and the evidence of unusual angularity of the bone. In the more severe types of this



A *B*

FIG. 818.—Fracture of the body of the astragalus with outward dislocation of anterior fragment.

fracture, distinct compression, comminution and displacement of fragments may be readily recognized. The favorite site of this fracture is the anterior half of the bone; in some cases the fracture line involves the entire calcaneum. Irregularity of comminution of fragments is characteristic and vertical compression usual. These fractures are usually the result of falls upon the foot and only rarely of direct violence. The astragalus seems to act as a wedge and is forced through the calcaneum. The degree of compression and of comminution is in direct ratio to the distance of the fall and the weight of the patient. Associated fractures of the malleoli are occasionally seen. The site of the lesion is dependent, to a great degree, upon the position of the foot at the time of injury. Fractures of the shelf on which the

astragalus rests (sustentaculum tali) are rare and usually associated with fracture of other portions of the calcaneum. Isolated fractures of the sustentaculum are extremely rare. The fracture results from a



FIG. 819.—Compression fracture of body of astragalus.

FIG. 820.—Compression fractures of body of astragalus and of calcaneum with dislocation at astragalo-scaphoid joint.

fall upon the foot when it is in position of marked inversion. The resulting deformity is a pes valgus.

Plagemann's statistics of 17 isolated fractures of the calcaneum shows 10 compression fractures of the entire body of the calcaneum

with a partial or complete tearing off of the sustentaculum tali; 4 fractures of the posterior process; 2 fractures of the anterior portion and



FIG. 821.—Compression fracture of body of astragalus.

FIG. 822.—Fracture of the posterior process of the astragalus.

body, and 1 fracture of the posterior process and body of the calcaneum. In 4 of these 17 cases there was an associated fracture of the astragalus, consisting twice of a fracture of the neck, once a frac-

FIG. 823.

FIG. 824.

FIGS. 823 AND 824.—Types of tear-fracture of the posterior process of the calcaneum.

ture of the posterior process and once a fracture of the posterior process and neck of the astragalus. In these cases the fracture line of the calcaneum was a continuation of the fracture line of the astragalus.

Symptoms.—The frequency with which fracture of the calcaneum

FIG. 825.

FIG. 825.—Type of tear-fracture of the posterior process of the calcaneum.

FIG. 826.

FIG. 826.—Type of fractures of posterior process of calcaneum.

Fig. 827.

Fig. 828.

Figs. 827 and 828 Types of fracture of posterior process of calcaneum.

is overlooked is due in a great measure to the fact that unless there is marked displacement of fragment the symptoms are slight and unattended by absolute disability Careful inspection and examination

FIG. 829.

FIG. 830.

FIG. 831.

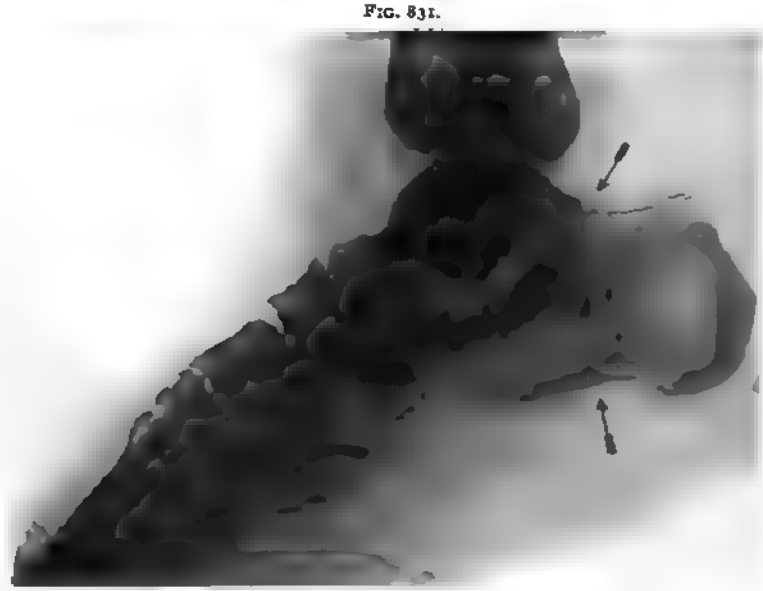

should render the diagnosis positive in the majority of cases, and in the remaining this may be done by the use of the roentgenogram. The characteristic symptoms are swelling in the region of the astragalus and about the ankle, thickening posterior to the malleoli, usually on the internal and external surface of the foot below the

malleoli, and marked limitation or at times entire absence of lateral motion of the foot (Fig. 833), although flexion and extension at the ankle-joint are free. Cotton lays great stress upon the thickening found, in nearly all fractures of the body of the calcaneum, on the external surface of the bone beneath the external malleolus, and considers it to be due to the detachment and forcing outward of a thin cortical fragment from spreading of the bone beneath it. At times there is upward displacement of the posterior fragment with corresponding flattening of the foot, so that a valgus position is present. Crepitus at times may be detected. In many cases the weight of the body can be borne upon the injured foot. In severe compression fractures, the malleoli may be nearer to the sole of the foot than is normally present. There are in addition localized pain, tenderness on pressure, ecchymosis, and usually characteristic broadening below the malleoli, seen best from a posterior view (Fig. 834). In avulsion fracture the displaced fragment may generally be felt in its abnormal position. When practicable, radiographic examination should be made

FIG. 832.—Fracture of epiphysis (posterior process) of calcaneum.

FIG. 833.—Method of determining lateral normal motion in the foot.

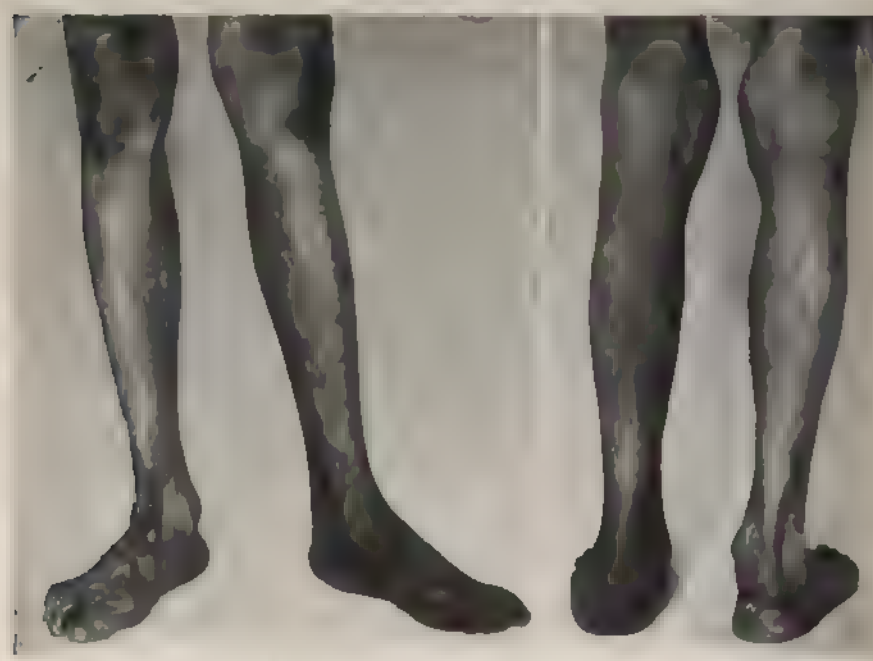

A B

FIG. 834.—Fracture of left calcaneum, anterior and posterior views. Note loss of normal contour and widening of calcaneam region with tendency to flattening of the anteroposterior arch of the foot.

to determine not only the variety of fracture but also the degree of displacement of fragments and to reveal associated lesions of other bones.

Prognosis.—In fractures unassociated with displacement of frag-

ments the prognosis is good as regards function. The same cannot be said of fractures in which there is comminution or displacement of fragments. In these cases non-operative methods of treatment are apt to be attended by poor functional results and marked decrease in earning efficiency. This is due to loss of the arch of the foot, to the projection of fragments into the sole of the foot, making walking painful, to loss of lateral motion of the foot and to pain due to relaxation of ligaments.

Treatment.—In fractures unattended by displacement of fragments, treatment consists in immobilization in a gypsum case applied from the toes to below the knee for a period of three to four weeks. This is to be associated with, or followed by, massage and passive motion; weight-bearing should be allowed at the end of six or eight weeks. In many cases, however, there is displacement of fragments. Four forms of displacement are amenable to treatment by reduction. A general anæsthetic is usually required for reduction of fragments.

If displacement cannot be corrected by traction and manipulation, operative measures should be adopted. In fractures attended by upward displacement of the posterior process, reduction may be accomplished by the introduction of a spindle through puncture holes just in front of the point of insertion of the tendon of Achilles as suggested by Cotton (Fig. 835). Traction is made on this spindle and the fracture reduced. If reduction cannot be maintained, tenotomy of the tendon of Achilles, either alone or combined with nailing of the fragments in their normal position, should be done. After reduction, immobilization with the foot in slight plantar flexion of the ankle in a gypsum case should be used. Fractures attended by lateral broadening below the malleoli should have this displacement corrected by Cotton's operative method (Fig. 836). This consists in placing the inner surface of the foot upon a sand-bag, and protecting the outer surface of the calcaneum by a felt pad; after which impaction of fragments is obtained and reduction of displaced fragments accomplished by repeated blows with a wooden mallet. A gypsum case is used after reduction. In fracture attended by displacement of sharp fragments from the weight-bearing surface of the calcaneum into the plantar muscles,

FIG. 835.—Cotton's method of reduction of a fracture of the posterior process of the calcaneum with upward displacement of the fragment.

open operation should be the plan of procedure, with excision of these fragments.

Fractures attended by upward displacement of a portion of the posterior process due to pull of the tendon of Achilles may be subject to open operation. This consists in exposure of the fragments through a curved posterior incision, approximation of the fragments, and suture

FIG. 836.—Cotton's method of correcting lateral broadening below the malleoli by compression of fragments with a hammer and piece of felt.

with kangaroo tendon. Tenotomy of the tendon of Achilles may also be necessary (Figs. 837 839).

Fractures of the Tarsal Scaphoid.—Fractures of the tarsal scaphoid (Figs. 840-845) are rather rare injuries and usually are the result of direct violence, in which there may also be associated fractures of other bones of the foot. These fractures may be comminuted and open, or may partake of the character of avulsion fractures. Fractures by indirect force are due to falls upon the foot in which the foot is in a position of plantar flexion and the weight is received upon the

FIG. 837 Fracture of the body of the calcaneum with upward displacement of the fragment.

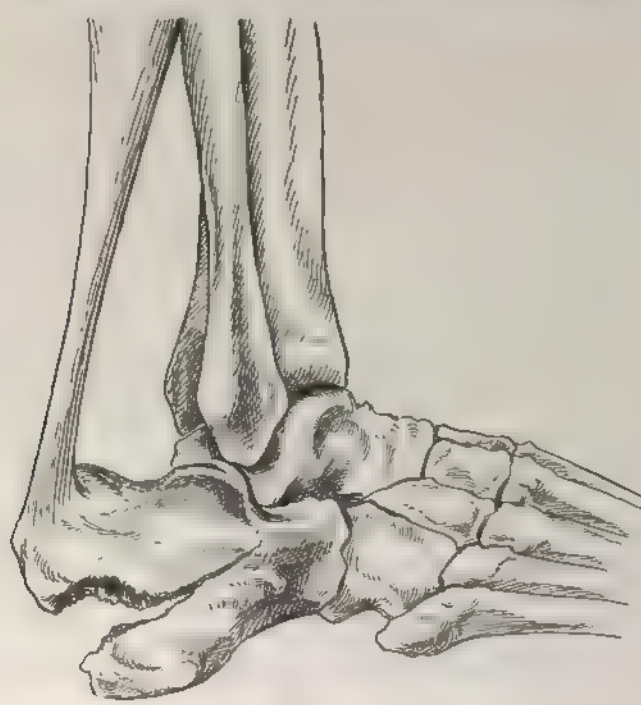

FIG. 838 Drawing to show the pull exerted by the tendo Achilles in fracture of the posterior portion of the body of the calcaneum. (Made after roentgenogram Fig. 837)

toes. As a result the scaphoid is cushioned between the astragalus and the internal cuneiform. In a few instances the fracture is the result of a twist of the foot or a mis-step. The insertion of the posterior tibial muscle into the bone accounts for some of the tear-fractures of the tubercle of the scaphoid. The usual site of fracture is the tubercle, although in fractures due to direct violence any portion of the bone may be the seat of injury. Usually there is a moderate degree of displacement of the fragment of the tubercle; in some instances the dorsal fragments may be pushed upward under the tendons on the dorsal surface of the foot.

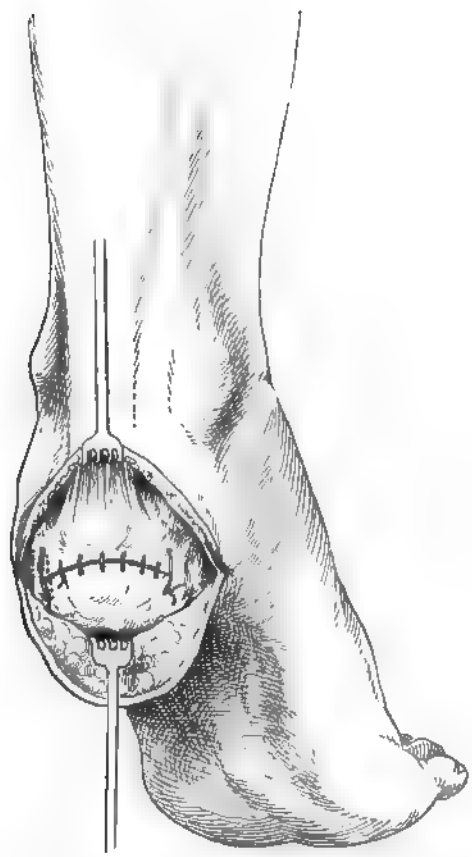

FIG. 830.—Method of approximation of fragments in fracture of posterior portion of body of calcaneum by open operation. The fragments are secured by two interrupted sutures of kangaroo tendon passed through drill holes in the bone and the torn periosteum is united by interrupted chromic catgut sutures and the skin by interrupted linen thread. Immobilization is maintained by a gypsum case.

Symptoms.—The symptoms of fracture of the tarsal scaphoid depend in some degree upon the site of fracture. There is always marked pain and tenderness on pressure over the inner and dorsal surface of the instep, that is, in the region of the scaphoid. Pain is increased by weight-bearing. Some local swelling and possibly ecchymosis are present. The foot presents a valgus position, and abduction is usually marked. Pain is usually referred up the leg along the course of the posterior tibial muscle, and on account of the attachment of this muscle to the tubercle of the scaphoid the latter is pulled inward; the antagonistic peroneus muscles pull the foot into a valgus position, and after a time rigidity of the foot in the valgus position results. Forced abduction of the foot increases pain at the site of fracture, as this motion separates the fragments of the scaphoid. Displacement of fragments can always be recognized by palpation. When severe compression or dislocation of fragments is present, the inner measurement of the foot is shortened. Suspected cases should be radiographed. Occasionally there is a sesamoid bone in the tendon

Fig. 840.

Fig. 841.

Fig. 842.

Figs. 840, 841 and 842.—Types of fractures of the tuberosity of the tarsal scaphoid.

of the posterior tibial muscle; its presence should not mislead one into assuming the presence of fracture. Examination of many radiographs leads to the belief that the tubercle of the scaphoid is not developed from an individual centre of ossification.

Prognosis.—In the majority of unrecognized and unreduced cases of fracture of the tarsal scaphoid, traumatic flat-foot is the result. Severe compression fracture of this bone is followed by markedly poor function and a painful, weak foot.

Treatment.—When there is no marked displacement of fragments, treatment consists in immobilization of the foot and leg in a gypsum splint for three to four weeks. The foot splint should be applied with the foot in moderate inversion and adduction. Slight massage should be performed from the beginning of treatment or from the end of the second week, and weight-bearing allowed at the end of the sixth week. Cases complicated by marked displacement of fragments demand open operation, reduction of fragments, and later immobilization. Most of the patients should use a felt pad for supporting the arch of the foot for several months. Metal arch supports are not recommended.

CHAPTER XXV

FRACTURES OF THE METATARSAL BONES

Anatomy.—The five metatarsal bones consist of a base, a shaft, and a head. The first metatarsal is the largest and the second the longest. The bases of the first and fifth metatarsal bones present a broad projection called the tuberosity.

Surface Markings.—The first and fifth metatarsal bones can be readily and the other three fairly well palpated throughout their entire length. The tuberosity of the fifth metatarsal is prominent on the outer surface of the foot.

Statistics.—Plagemann's statistics show 49 fractures of the metatarsals in 1393 cases, distributed as follows: first metatarsal, 9 times; second metatarsal, 12 times; third metatarsal, 3 times; fourth metatarsal, 4 times; fifth metatarsal, 9 times; first and second metatarsals, 4 times; first, second, third, fourth and fifth metatarsals, 2 times; first, second and fourth metatarsals, once; second and third metatarsals, 3 times; fourth and fifth metatarsals, once; and first, second and third metatarsals, once.

Etiology.—Fractures of the metatarsal bones (Figs. 846–852) are usually the result of direct violence, as from falling objects, and crushing injuries, and occasionally from indirect violence, as in jumping and prolonged marching. Fractures of the fifth metatarsal, while occasionally produced by direct violence, are usually due to a sudden throwing of the weight of the body upon the foot, when the latter is in a position of inversion, as in dancing, jumping from a moderate height, or in a mis-step.

Symptoms.—Fractures from direct violence are generally accompanied by considerable bruising of the overlying soft parts, so that there is marked swelling, localized pain, tenderness on pressure, and ecchymosis. Crepitus can frequently be detected and the fragments may be moved in any direction. Some of these fractures can be determined positively only by the radiogram, and many of them are overlooked. After swelling of the soft parts has disappeared, displacement of fragments can be recognized. The lines of fracture may be oblique, transverse, or comminuted, and rarely are longitudinal. Multiple fractures are frequent. Longitudinal fractures are seen only in the first metatarsal.

Fig. 846 Fig. 847

Fig. 846.—Comminuted fracture of the first metatarsal.
Fig. 847.—Comminuted fracture of the first metatarsal, longitudinal in type.

Fig. 848. Fig. 849.

Fig. 848.—Transverse fracture of the first and second metatarsals.
Fig. 849.—Longitudinal fracture of the first metatarsal.

Of particular interest are fractures of the fifth metatarsal. Isolated fracture of this bone when not the result of direct violence is due to inversion of the foot under the weight of the body. It is produced by

Fig. 850.—Fracture dislocation of the base of the first and fracture of the shafts of the second, third and fourth metatarsals.
Fig. 851.—Transverse fracture of the shaft of the second metatarsal.
Fig. 852.—Fracture of the shafts of the second, third and fourth metatarsals.

direct pressure upon the outer part of the foot. As the foot is turned inward and the weight of the body brought upon the outer surface of the foot, strain is brought to bear upon the base of the bone, which is held firmly to the fourth metatarsal and cuboid bones by strong ligaments. As a result of this strain, fracture usually occurs at the base. The following varieties of fracture may be recognized: fracture through the tip of the tuberosity (Figs. 853–855); fracture through the base of the tuberosity (Figs. 856 and 857); transverse fracture through the proximal end of the shaft (Figs. 858 and 859); and fracture through the shaft of the bone (Figs. 860 864).

The symptoms of inversion fracture of the fifth metatarsal are localized pain, tenderness on pressure, partial disability, localized swell-

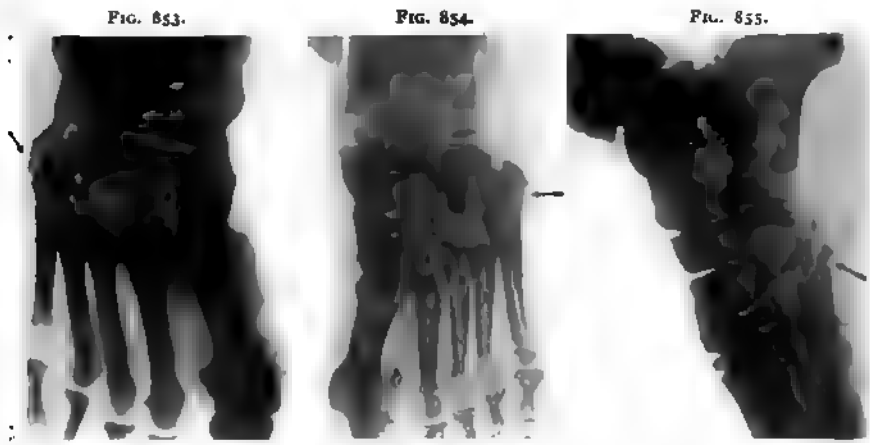

FIG. 853. FIG. 854. FIG. 855.

FIGS. 853, 854, AND 855.—Types of fractures of the tip of the tuberosity of the fifth metatarsal.

ing, and pain referred to the seat of fracture upon lateral squeezing of the foot just above the heads of the metatarsals. Crepitus may at times be determined, particularly when the line of fracture occupies the shaft of the bone (Fig. 865). Radiograms will make a positive diagnosis, although in many cases it may be made from the character of the injury, and the localized tenderness, pain, swelling and late ecchymosis.

Prognosis.—Fractures by direct violence are usually attended by marked displacement of fragments. Unless such displacement is reduced, union takes place with deformity, and there is the presence of a marked projection, either dorsally, which gives considerable discomfort on account of shoe pressure, or the fragment may be displaced into the plantar region of the foot, with secondary nerve pressure and



FIGS. 856 AND 857.—Types of fracture of the base of the tuberosity of the fifth metatarsal.

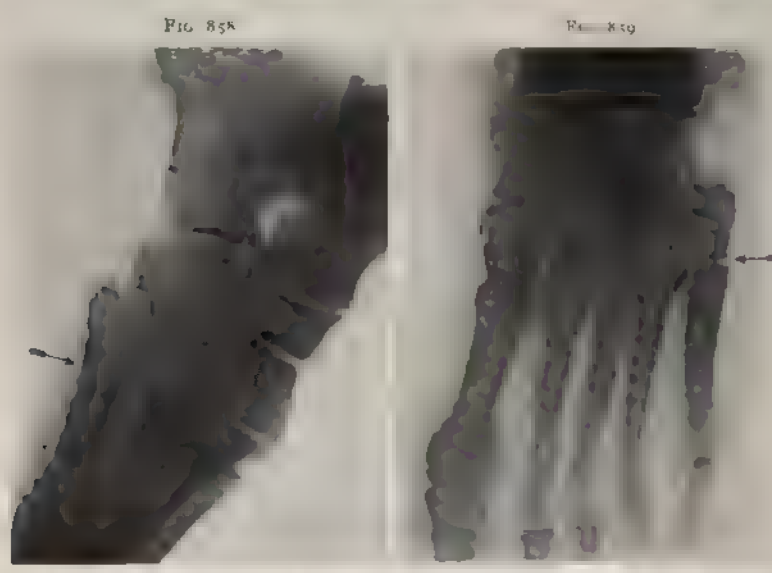

FIGS. 858 AND 859.—Types of fracture through the proximal end of the shaft of the fifth metatarsal.

consequent disability. In fracture of the fifth metatarsal by inversion, union usually occurs with very little deformity and the functional results are good.

Treatment.—Reduction of fragments should be accomplished by traction and manipulation. Anteroposterior displacements should

Fig. 860. Fig. 861.

Fig. 862 Fig. 863.

Figs. 859, 861, 862, and 863.—Types of fracture of the shaft of the fifth metatarsal. These fractures when caused by inversion of the foot are spiral in character. When due to direct violence they are usually transverse or oblique in character.

always be corrected, even if open operation is necessary. Immobilization after reduction should be by means of a well-moulded plantar gypsum splint or a carefully padded wooden splint. If incision is necessary for reduction, fixation should be accomplished by direct suture with chromic catgut followed by the use of an external gypsum

splint. Immobilization with frequent light massage should be continued for from four to five weeks. Weight-bearing may be instituted at the end of six or seven weeks.

Old cases, in which there is union with deformity and loss of



FIG. 864.—Type of fracture of the shaft of the fifth metatarsal



FIG. 865.—Method of determining abnormal mobility and crepitus in fracture of the shafts of the metatarsals

function due to pressure, call for operation and excision of projecting spurs of bone.

In fractures of the fifth metatarsal by inversion, there is little displacement of fragments, and treatment consists in immobilization by a gypsum encasement or splint for four weeks.

CHAPTER XXVI

FRACTURES OF THE PHALANGES

FRACTURES of the phalanges (Figs. 866-870) are the result of direct violence. Exceptions to this statement are those fractures which occasionally result from stubbing the toe; in these the force is received on the point of the distal phalanx. These fractures may be subcutaneous, or open, comminuted and complicated. The line of fracture may be transverse, oblique, comminuted, T or Y, or longitudinal. Of particular interest have been two cases observed by one of the authors. One consisted of a fracture of an exostosis of the distal

FIG. 866. FIG. 867.

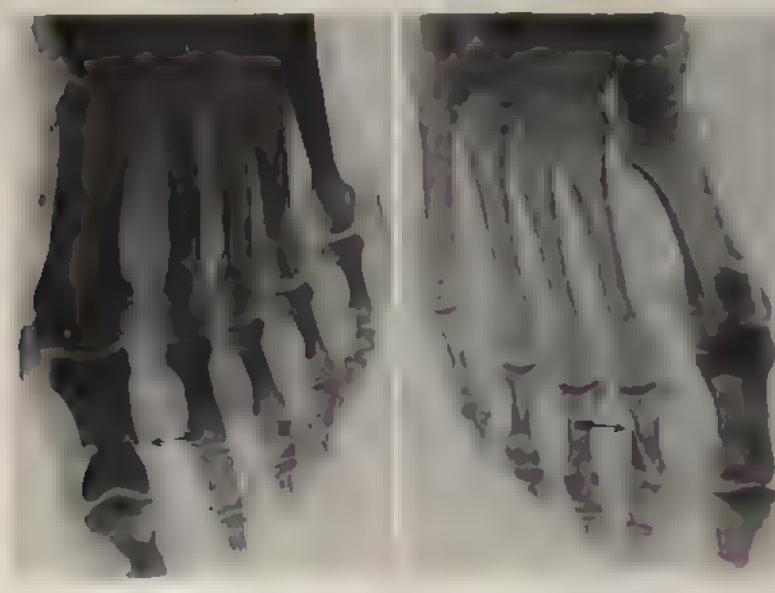

FIG. 866.—Transverse fracture of the proximal phalanx of the great toe.
FIG. 867.—Oblique fracture of the proximal phalanx of second toe.

phalanx of the great toe, and the other a longitudinal fracture of the distal phalanx of the great toe involving epiphysis and diaphysis, the result of direct violence. Open comminuted fractures are frequent from crushing of the toe by machinery or impact of heavy objects on the foot.

Symptoms of phalangeal fractures are localized pain, swelling, ecchymosis, tenderness on pressure, crepitus, and abnormal mobility.

Treatment.—Displacement of fragments is rarely great. Reduction is readily accomplished, and immobilization made either by strapping the toe to the adjoining one, or by using a plantar splint. Union occurs in three to four weeks and functional results are good.

Fig. 868.—Spiral fracture of the proximal phalanx of the fifth toe.

Fig. 869.—Comminuted fracture of the distal phalanx of the great toe, involving the epiphyses of the base.

Fig. 870.—Fracture of the distal phalanx of great toe.

CHAPTER XXVII

FRACTURES OF THE SMALL SESAMOID BONES

Anatomy.—Sesamoid bones are small osseous structures developed in tendons, are situated at that part where tendons play over joints, and are subject to considerable pressure. They make their appearance as osseous structures about the twelfth year. These small structures may be ossified or they may be represented by fibrocartilage. One surface of the bone is usually covered with cartilage and enters into the formation of the joint, or is separated from the latter by a bursa. Many of the sesamoid bones are constant and are ossified; and as such

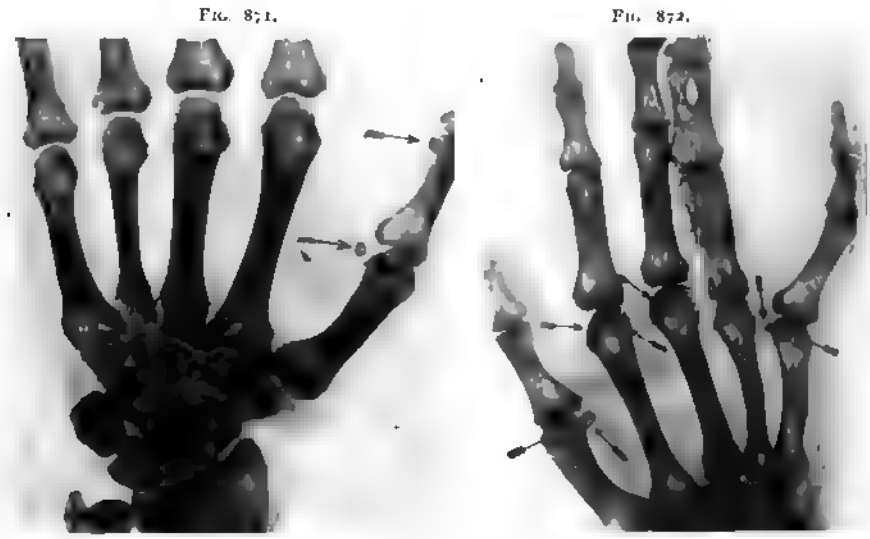

FIG. 871. FIG. 872.

FIG. 871.—Constant sesamoid bones of the thumb.

FIG. 872. Shows only one constant sesamoid bone at the metacarpophalangeal joint of the thumb, one accessory sesamoid at the head of the second metacarpal, one at the head of the third metacarpal, and two at the head of the fifth metacarpal.

show by radiography, when formed of fibrocartilage no shadow is found. The largest sesamoid is the patella.

The constant sesamoid bones (Figs. 871–874) of the hand are those occurring at the metacarpophalangeal joint of the thumb. They are two in number, are joined together by fibrous tissue and form the floor of the groove of the flexor longus pollicis tendon.

The constant sesamoid bones of the foot (Fig. 875) are two in number and are situated on the plantar surface of the head of the first metatarsal bone near the metatarsophalangeal articulation. They are united by fibrous tissue and form the floor of the groove for the tendon of the flexor brevis ballevia.

Fig. 873.

Fig. 874.

Figs. 873 and 874.—Shows two accessory carpal sesamoid bones in tendon sheaths of flexor tendons to fifth finger.

Fig. 875.

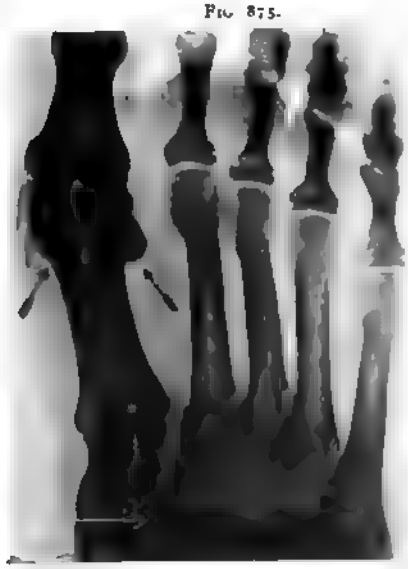

Fig. 876.

Fig. 875.—Inconstant sesamoid bones at head of the first metatarsal bone.
Figs. 876.—Type of os trigonum. This is often mistaken for the so-called Shepherd's fracture of the posterior process of the astragalus.

Of the inconstant or accessory sesamoid bones of the hand, may be mentioned the following: There is sometimes found a third or accessory sesamoid at the metacarpophalangeal joint of the thumb, also one at the interphalangeal joint of the thumb; one between the flexor tendon and the head of the second metacarpal; one between the

flexor tendon and the head of the fourth metacarpal, and one between the flexor tendon and the head of the fifth metacarpal. Two accessory sesamoids have been noted at the head of the fifth metacarpal and accessory carpal sesamoids in flexor tendons at the wrist.

Fawcett's statistics, based upon röntgenologic examination of 38 pairs of hands, show the sesamoids in the index-finger in 55.2 per cent.; in the fifth finger in 71 per cent., and in the interphalangeal joints of the thumb in 69.3 per cent.

Geist examined the feet of 100 persons who never had an injury or foot complaint, and of these there were 30 presenting accessory sesamoid bones, which he divides as follows: Important group: os trigonum, os tibiale externum, os peroneale, and os Vesalii. Unimportant group: secondary os calcis, os intermetatarsale, and os intercuneiforme.

The os trigonum (Figs. 876 and 877) is situated at the back part of the astragalus. It may be small or large, double or single. The so-called Shepherd's fracture as a rule is nothing more than this os trigonum. This bone was found 7 times in this series, was always unilateral, while in 3 of the 7 cases a larger posterior process was noted in the other foot. The os tibiale externum (Fig. 878) was formerly considered as accessory bone in the tendon sheath of the tibialis and situated behind and slightly below the tubercle of the scaphoid. It is often unilateral and is often mistaken for a fracture of the tubercle of the

FIG. 877.



FIG. 877.—Type of os trigonum. This is often mistaken for the so-called Shepherd's fracture of the posterior process of the astragalus.

FIG. 878.

FIG. 878.—Os tibiale externum, in the tendon sheath of the tibialis posticus tendon.

FIG. 879.

FIG. 879.—Double os peroneale, situated in the tendon of the peroneus longus muscle.

scaphoid. Fourteen cases were seen in the series of 100; single in 9, double in 5. On one side there may be an absolutely loose tibiale externum, and on the other side it may be represented by a large tubercle of the scaphoid. The os peroneale (Fig. 879) is apparently a true sesamoid bone, being situated in the tendon of the peroneus longus muscle. It was found present in 7 cases, being single in 3 and double in 4 cases. In two of these cases it was bipartite.

The os Vesalii is situated at the base of the fifth metatarsal bone. It is very rare and was found once in 100 cases. The secondary os calcis occurs extremely rarely. In this series it was found twice.

Fig. 880.—Accessory sesamoid in the tendon of the gastrocnemius muscle.
Fig. 881.—Shows the two constant sesamoids at the head of the first metatarsal and accessory sesamoids at the heads of the second, third, fourth and fifth metatarsals.

When present it may simulate a broken off part of the sustentaculum tali. The intercuneiforme is a small wedge-shaped bone situated between the internal and middle cuneiform bones. It was found in two cases. The intermetatarsaleum is considered by Dwight to occur in 10 per cent. of all cases. It is difficult to recognize by radiograph and is found between the bases of the first and second metatarsal bones.

Pfitzner found sesamoid bones on the fibular side of the fifth toe in 6.2 per cent.; on the tibial side of the fifth toe in 5.5 per cent. and on the tibial side of the second toe in 1.8 per cent.

Occasionally there is observed in addition to the two constant sesamoids of the great toe a third or accessory sesamoid. Frequently there is seen an apparent fracture, particularly of the tibial sesamoid of the great toe, which is considered by many authorities to be an anomalous division of the sesamoid into two parts. This may be

definitely ascertained at times by having radiographs of both feet taken not only in anteroposterior planes but also laterally An unusual situation of accessory sesamoid is in the tendon of the gastrocnemius muscle

A *B*

FIG. 882.—Comminuted fracture of the tibial sesamoid of the great toe Run over by motorcycle Anteroposterior and lateral views

B

FIG. 883. Fracture of the tibial sesamoid of the great toe Injured while playing basket ball.

(Fig 880) Pancoast considers that it is present in about 12 5 per cent. of cases and usually found in the outer head of the muscle. It has been mistaken for a loose body in the popliteal bursa or in the

knee-joint. Accessory sesamoids are also found at the heads of the metatarsal bone

Fig. 884. Fig. 885.



Fig. 884.—Fracture of tibial sesamoid, accompanying comminuted fracture of the head of the first metatarsal. Injured by a falling weight striking foot.
Fig. 885.—Fracture of the tibial sesamoid. Form of injury not ascertained.

Fig. 886. Fig. 887.



Fig. 886.—Fracture of tibial sesamoid. Run over by a motor cycle.
Fig. 887.—Fracture of the tibial sesamoid. Injured while playing baseball.

Etiology.—Fractures of the sesamoids other than the patella have been observed involving those of the thumb and the great toes. Fractures of the sesamoids of the great toe (Figs. 882–887) result from

direct violence, such as jumping on the toes, run-over accidents, sudden falls upon the feet, and the impact of falling objects on the foot. Fractures of the sesamoids of the thumb (Figs. 888 and 889) may be the result of catching rapidly moving objects, such as a baseball, or they may accompany dislocation at the metacarpophalangeal and interphalangeal joints. Stumme (quoted by Mütter) showed on the cadaver that fracture of the tibial sesamoid bone may be produced by forcible dorsiflexion with abduction.

Symptoms.—The symptoms of fracture of the sesamoid bones of the great toe are persistent pain and tenderness on walking on the plantar surface of the foot over the region of the sesamoid, usually this tibial sesamoid bone. In addition there is generally history of an injury either from a direct fall upon the foot or by a falling weight

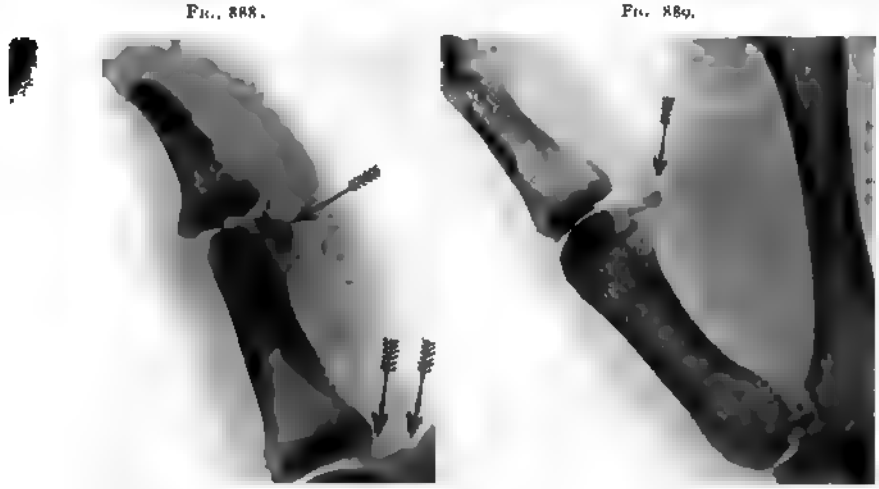

FIG. 888. FIG. 889.

FIG. 888.—Old fracture of interphalangeal sesamoid in a baseball player.
FIG. 889.—Fracture of the sesamoid of the thumb. Patient fell upon extended thumb. (Courtesy of Dr. P. G. Skillern, Jr.)

striking the foot over the sesamoid region of the great toe. Similar symptoms are caused by fracture of manual sesamoids. An absolute diagnosis may be made only with the radiogram, which will show the dentated margin of fracture. Anteroposterior and lateral views of both feet should be made for a comparison so as to avoid diagnosing an anomalous division of the sesamoid as a fracture. Occasional ossification of portions of tendons near joints may be mistaken for sesamoids, and fractures of osteophytes may be erroneously diagnosticated as broken sesamoids, and vice versa.

Treatment.—This consists in immobilization of the foot or hand upon a moulded gypsum plantar or palmar splint for three or four weeks. If pain and soreness on use of the hand or in walking persist, excision of the fragment should be performed.

CHAPTER XXVIII

BIRTH FRACTURES

BIRTH FRACTURES are observed rather infrequently. E. D. Truesdell, in a study of about 9000 cases delivered at the New York Lying-in Hospital, has found 14 fractures of the humerus, 10 fractures of the clavicle, and 2 fractures of the femur. He later reports a separation of the lower femoral epiphysis, and G. W. Kosmak, from the same institution, reports four cases of depressed fractures of the skull.

Depressed Skull Fractures—Etiology.—Depressed fractures of the skull in the new-born occur in difficult labor and are the result of pressure from forceps in instrumental delivery or of some projecting deformity in the pelvis.

There are frequently areas of subdural hemorrhage and of œdema after difficult labor with or without forceps delivery, but in time these areas disappear by absorption without any permanent injury to the brain. In depressed fracture of the cranial bones this does not readily occur. Although at times the brain may accommodate itself to small areas of permanent depression, subsequently these deformities of the surface of the skull may possibly exert a deleterious effect on the functions of the brain. The depressed areas sometimes disappear of themselves; as a rule they persist and may leave the patient the subject of nervous disturbances, epilepsy, idiocy, and other mental changes.

Symptoms.—In some of the cases there will be entire absence of symptoms, excepting the presence of the depressed area of bone. If the depression is sufficiently marked to cause compression, or over important cerebral centres, the respirations may be slow and labored, the heart action slow and weak, and irritative or paretic symptoms arise. The child may not cry, and the pupils may be unequal and fail to react to light. Partial asphyxiation may be present, and there may be at first muscular twitchings or paralysis, depending upon the degree and extent of the depressed area or its location over motor centres.

In all cases of prolonged labor, contracted pelvis, or instrumental delivery, the head of the child should be carefully examined for areas of depressed fracture. The presence of a caput succedaneum may conceal an area of compression, so that, when it is present, repeated examination should be made. When areas of depression are found to persist, they should be elevated promptly by operation, for it is unwise to expect intracranial pressure to force the depressed area of the skull out to its normal contour.

Treatment.—When an area of depression is found, correction should be made as soon as recognized. Kosmak has devised an instru-

ment for the correction of depressed fractures of the skull, which consists of a hook with a handle. The hook is placed at a right angle to the shaft of the instrument and is mounted on a handle for convenience in using. The hair over the depressed area is clipped with scissors, the area painted with tincture of iodine, and the point of the instrument forced by firm and constant pressure into the centre of the depressed fracture. When the point has penetrated the inner table of the skull, the handle of the instrument is turned at right angle to the surface and steady traction made outward until the depressed area is elevated. A sterile dressing and bandage complete the operation. A small trephine may be used to gain admission for an elevator which can then be used to prize up the depressed portion of the calcaneum.

Fracture of the Humerus—Etiology.—Truesdell's observations upon fractures of the humerus in the new-born show, of the 14 cases observed, that 10 occurred during version and breech extraction, 3 during simple breech extraction, and 1 in spontaneous vertex delivery in which difficulty was met in extracting the anterior arm on account of a narrowed pelvic outlet.

The line of fracture in 13 of these cases was transverse in direction, near the centre of the shaft, or just below the insertion of the deltoid muscle; in the other case the fracture was produced by the application of a fillet to the prolapsed arm in a shoulder presentation followed by traction upon the limb while version was being performed. The fracture was produced by torsion of the arm across the child's back. The line of fracture in this case was oblique.

Deformity.—In the majority of cases this was primarily absent but later occurred, either by the child's muscular efforts or by the manipulations of the nurse in handling the child. The deformity then assumed one of external angulation. In a few cases there was lateral deviation of fragments. Over-riding of fragments was extremely rare (Fig. 890).

Every fracture of the humerus observed by Truesdell was accompanied by wrist-drop. This is considered by the author to be due either to posterior pressure upon the nerve occurring before the production of the fracture, or to implication of the nerve between the fragments. Of two cases which died the author was able to examine the seat of fracture, and in neither of these two was there any evidence of violence to the brachial plexus or the musculospiral nerve. In one case the author noted the occurrence of an Erb birth palsy in the injured arm.

Symptoms.—The presence of fracture of the humerus may be readily recognized by the evident disability to use the arm, wrist-drop, deformity, localized pain at the seat of fracture, and crepitus.

Treatment—Prophylaxis.—While Kosmak considers that frac-

ture of one of the long bones is never a very serious lesion in comparison with depressed skull fractures, he thinks that it may often be possible to avoid the complication by correct diagnosis of the exact position of the arms of the child before the body is born. A correction of the brachial malposition is then possible before extraction of the child. He urges that so soon as the umbilicus is born in a breech extraction with or without previous version, the fingers of the examining hand should be introduced over the posterior vaginal commissure

FIG. 890.—Fractures of right humerus and both clavicles. The fracture of the humerus is situated at its centre, the usual site; the line of fracture is oblique. The outward rotation of the lower fragment may be prevented by fixation of the forearm to the front of the chest wall. (Courtesy of Edward D. Truesdell, M.D., New York Lying-in-Hospital.)

and the position of the arms in relation to the head determined. If the arms are extended, or one of them is caught behind the neck in the form of a nuchal hitch, it is much easier to sweep them over the face into a position of flexion before final delivery than to attempt this manœuvre after the greater portion of the trunk has been born. At this time the head has not been wedged into the pelvic entrance, and the arms, if extended, can usually be released without much difficulty. It has been found practical never to rely on any flexion of the arms being maintained through pressure exerted on the fetal head through

the lower abdominal segment. Nearly always the arms will become extended during version, and this fact might as well be recognized before the posture of the arms becomes a source of danger to either mother or child.

In the treatment of these fractures the difficulty of maintaining immobilization of fragments is apparent. The simplest form of treatment consists in surrounding the arm with coaptation splints, and fixing

FIG. 891.—Fracture of shaft of femur at end of ten weeks, showing union, uncorrected anterior angulation, and lateral displacement. (Courtesy of Edward D. Truesdell, M.D., New York Lying-in-Hospital.)

the arm and forearm to the chest by means of a bandage applied to the shoulder and arm as suggested by Velpeau. Union occurs in about three weeks. Truesdell has devised a splint made of sheet aluminum, cut and folded in such a manner that the external angular deformity is corrected. The splint at the same time fixes the arm to the body, flexes the elbow, and entirely immobilizes the arm.

Truesdell concludes from an observation of his cases that union is

FIG. 892.—Radiograph of the normal and injured femur for comparison. In the normal bone the lower epiphysis with its nucleus of bone is shown occupying its usual position. In the injured femur the lower epiphysis has been displaced backward and upward, its position being indicated by the contained ossification nucleus. The periosteum has been stripped up from the lower portion of the shaft of the bone, and beneath this new-bone formation is already taking place. (Courtesy of Edward D. Truesdell, M.D., New York Lying-in Hospital.)

FIG. 893.—At the fourth month the new formed femur compares quite favorably with its fellow of the opposite side. The new and original portions of the femoral shaft, differ but slightly in density. Indications of the new internal and external condyles are evident, the ossification nucleus occupying its usual position in the depression between them. (Courtesy of Edward D. Truesdell, M.D., New York Lying-in Hospital.)

prompt in birth fractures of the humerus, complicating injuries are usually insignificant, and lateral displacement even if marked is not unfavorable. He thinks angular deformity should be guarded against or corrected if possible, but that when uncorrected and even when excessive, nature will do much to remedy the defect during the first years of life, effecting a final result never possible under corresponding conditions in an adult patient. Fractures of the shaft of the femur may do well by hyperflexing the knee and holding the limb thus with a bandage or an adhesive plaster strap.

Fracture of the Clavicle—Etiology.—Of the 10 cases observed by Truesdell 8 occurred during version with breech extraction, 1 during forceps delivery and 1 during a normal vertex delivery. The latter was unrecognized at the time of birth, and later attention was called to its presence by the pressure from callus.

The site of fracture (Fig. 890) is usually about the middle or at

FIG. 894.—Long side splint used in fracture of shaft of femur. The use of this splint should correct external angular deformity and afford traction. Coaptation splints may be used about the thigh. (Courtesy of Edward D. Truesdell, M.D., New York Lying-in-Hospital.)

the junction of the middle with the outer third. In most of the cases displacement was very slight, and in those in which it was moderate it assumed that seen in corresponding fractures in the adult.

Treatment—This consisted in the majority of cases of the Velpeau bandage and retention in corrected position by a posterior figure-of-8 bandage.

Union was prompt, and occurred with the formation of visible callus. In one case union failed to occur at the end of the fifteenth month, and a false joint had formed at the seat of fracture.

Fracture of the Femur.—Two cases of fracture of the femoral shaft and one of separation of the lower femoral epiphysis were observed by Truesdell.

Etiology.—One of the cases of fracture of the femur occurred during version and breech extraction; the other patient was delivered by a midwife. The delivery was spontaneous, but as the child did not start to breathe as promptly as was thought desirable by the attendant,

it was seized by the ankles and swung about in the air with a resulting fracture of the femur. The separation of the lower femoral epiphysis occurred during internal podalic version and breech extraction. Con-

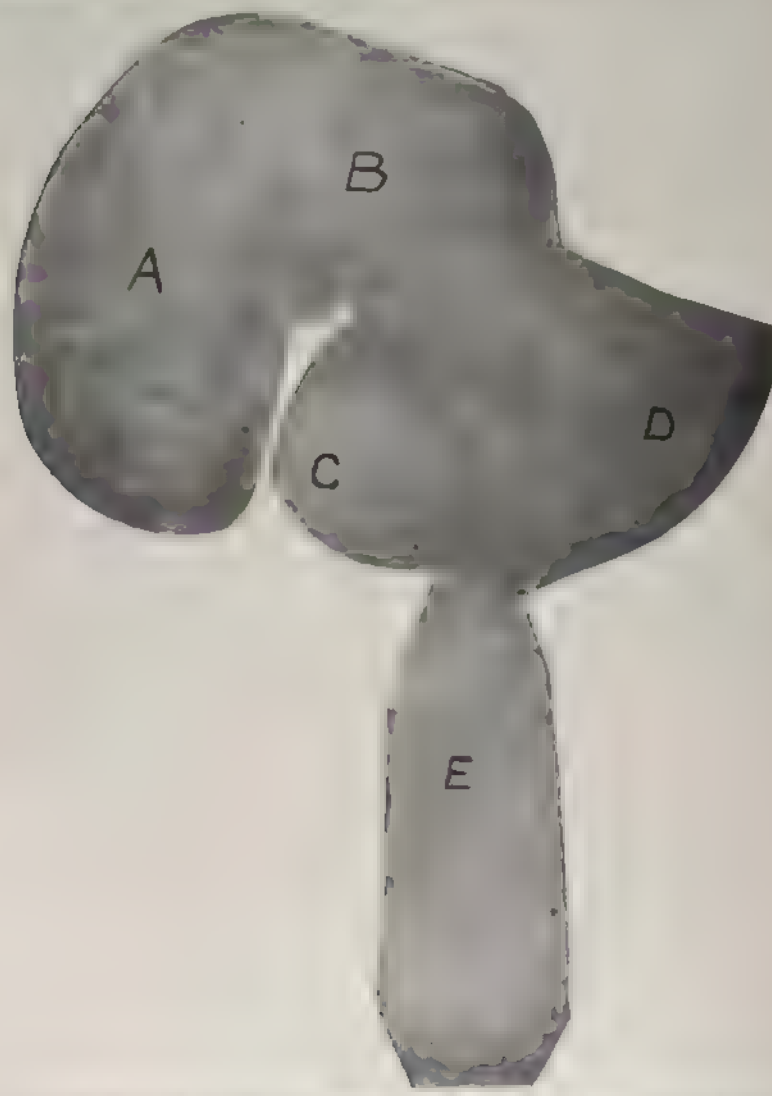

FIG. 805.—Aluminum splint used in fracture of humerus. *A*, Part secured behind back by adhesive plaster. *B*, Part behind shoulder. *C* and *D*, Flaps which fold about arm, press upper fragment inward and lower fragment outward. *E*, The splint is lined with canton flannel or sheet wadding. (Courtesy of Edward D. Frosden, M.D., New York Lying-in Hospital)

siderable difficulty in delivering the after-coming head resulted in prolonged manipulation of the child's body.

The symptoms of fracture of the shaft of the femur (Fig. 891)

are those usually seen in fracture of the shaft in the adult. In the separation of the lower femoral epiphysis (Figs. 892 and 893) the lower thigh presented an appearance of an infraction and the radiograph showed a dislocation of the cartilaginous lower epiphysis of the femur inward, outward, and backward.

Of the fractures of the shaft, one was treated by splints and bandages without any attempt at extension. Then the patient disappeared from observation before union had occurred. When seen at the end of eighteen months, there was firm union, anterior angular deformity, shortening, and a decided limp.

In the second case the fracture was not observed until one month after its occurrence. Union was firm, there was external and anterior angular deformity, shortening, and abundant callus. In the case of separation of the lower femoral epiphysis, full reduction of fragments was impossible. Callus formation occurred along the course of the stripped off periosteum, which was attached to the lower epiphysis and detached from the junction of the middle and lower thirds of the shaft downward. This resulted in the formation of a new shaft and condyles, with atrophy of the denuded portion of the shaft.

Treatment.—In all fractures of the shaft of the femur, correction of the deformity should be performed and immobilization made with a suitable dressing which includes traction if necessary. A good dressing is that described by Truesdell (Figs. 894 and 895). The articles by Drs. Truesdell and Kosmak have been freely used in the preparation of this chapter.

CHAPTER XXIX

GUNSHOT FRACTURES

GUNSHOT FRACTURES (Figs. 897–909) are relatively infrequent in civil life. Those seen are inflicted by accident or with homicidal or suicidal intent. The usual weapons are revolvers, pistols, shot-guns, occasionally the Flobert rifle, and very rarely the military rifle. The type of revolver used is generally of moderate calibre and is not as powerful as the heavy service weapon. Fractures by the military rifle occur in civil life from attempts at suicide, and as the weapon is held near the body the character of injury is entirely different from that seen in military life, where the wounds are inflicted at considerable distances. This statement is, however, modified by the fact that the firearms used by sportsmen are becoming more and more like those used in military service. The arms of civil life, however, probably have usually missiles of less weight and calibre, lower velocity and less energy than those of the soldier.

The characteristics of a bullet wound depend upon the velocity of the missile, its size, the distance it travels before impact, its mode of impact, its stability, and the resistance of the part struck.

The usual type of weapon producing fractures in civil life is the revolver, usually of a 32 or a 38 calibre. The projectile from this weapon has no great velocity, the distance travelled by the missile is short. The injury is often characterized by a wound of entrance without a wound of exit. There is damage in the track of the bullet, perhaps deformity, and the bullet, possibly fragmented or distorted by contact with bone, is lodged under the skin at a point opposite to the point of entrance. Frequently the bullet can be detected beneath the surface by careful palpation.

Industrial injuries from explosions of dynamite and similar agencies represent quite well analogous fractures and wounds of soft parts resulting from shell and hand grenades used in war.

Makins gives five types of fracture (Fig. 896) which are observed in military life; these are simulated to some extent in civil life.

Stellate fracture: The bullet perforates the bone centrally and from the bullet tract four oblique fissures radiate to the surfaces of the bone, separating a wedge-shaped fragment from each side, and causing the ends of the main fragments to be pointed. This is commonly termed the " butterfly " fracture.

The irregular stellate fracture, due to low degree of velocity of bullet. Here there is suppression of the two left-hand limbs with the substitution of a transverse line of fracture.

Typical complete wedge fracture.

Incomplete wedge fracture. In this variety the line of fracture is oblique or lateral and the two left-hand lines of the stellate fracture are suppressed.

Oblique single line fracture: In this variety one right-hand and one left-hand line of the stellate fracture are suppressed. The weight of the body probably has some influence in the production of this type. To fully recognize these types by radiogram the rays should be directed in the exact line of the track of the bullet.

While many of the gunshot fractures may be stellate in character, marked comminution is present and the lateral main fragments are broken up into numerous smaller fragments. Perforated fractures

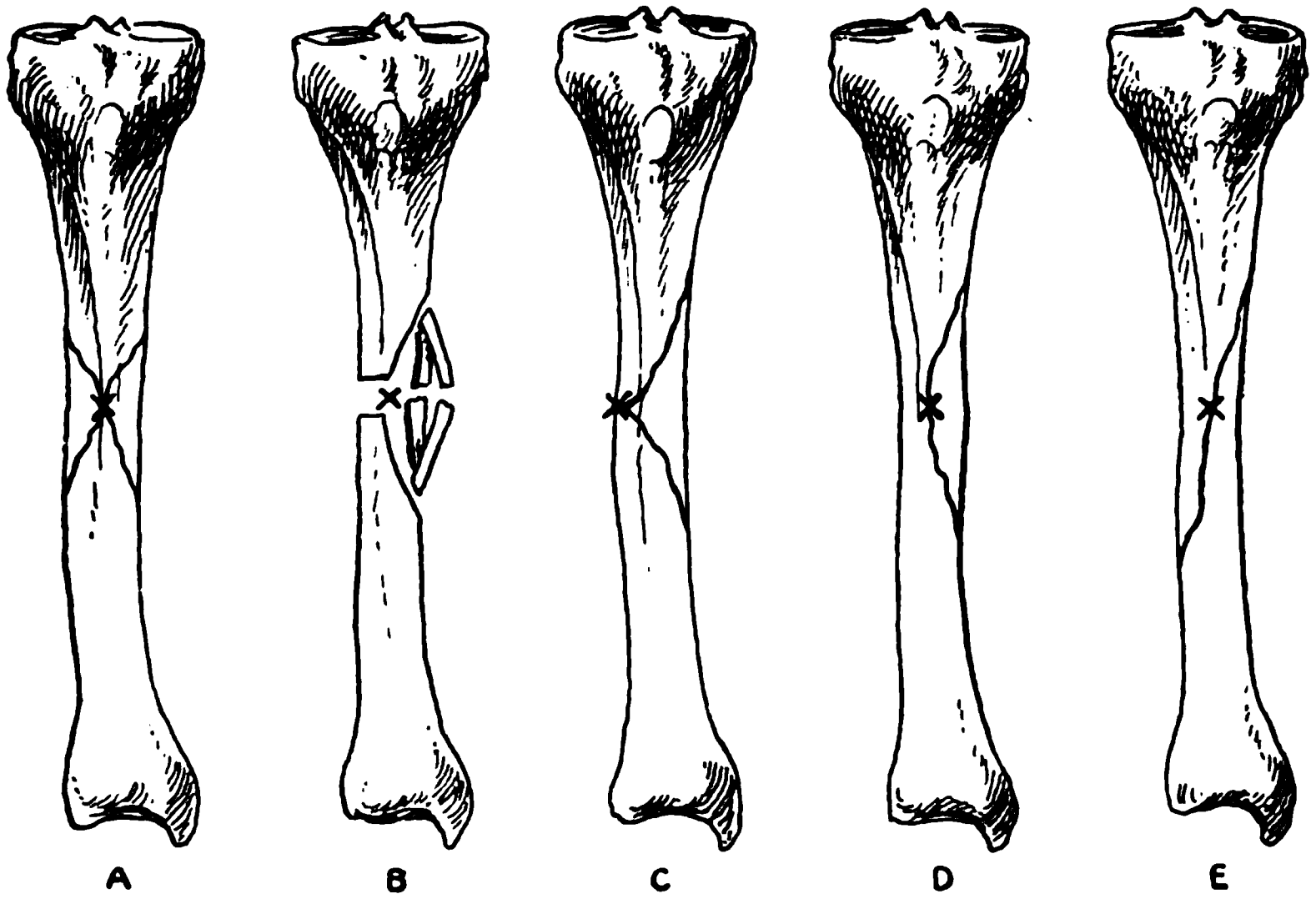

FIG. 896.—Makin's five types of fracture observed in military life: *A*, stellate fracture; *B*, irregular stellate fracture; *C*, typical complete wedge fracture; *D*, incomplete wedge fracture; and *E*, oblique single line fracture.

are particularly observed when the fracture occupies the epiphyseal end of a bone; comminution is apt to be absent here on account of the small proportion of compact bone in this locality.

The displacement of fragments in all comminuted fractures is toward the exit side, which is due to the propulsive effect of the bullet. Slight lateral displacement may also occur from the wedge action of the bullet as it traverses the bone. In many of the gunshot wounds of civil life the fracture is characterized by little if any displacement of fragments, but by imbedding of the bullet in the bone and by fragmentation of the bullet. In fractures produced by shotguns the distance travelled by the shot is very short and as a rule the shot strikes as a compact mass. Marked comminution of fragments is characteristic.

Gutter and groove fractures may be considered as incomplete perforations, the roof of the terminal being absent. They are rarely seen in the shaft, but more commonly in the articular ends of the bone.

The present European War has served to change somewhat radically surgeons' views in regard to gunshot wounds received in warfare. The mutilating character of shell and shrapnel injuries and the coincident life of the soldier in trenches produce with great frequency severe comminution of bone accompanied by crushing of the

FIG. 897.—Gunshot fracture of the palate and the body of the sphenoid bones. Wound self-inflicted by a 32-calibre bullet which passed through the palate bone and lodged in the body of the sphenoid bone. Patient recovered. Anteroposterior view. (See Fig. 897a.)

soft parts and immediate infection with pyogenic and perhaps tetanus and gas bacillus organisms. Such lesions are comparable to machinery and railroad crushes of limbs so frequent in civil life. These lesions are air exposed, and, therefore, may be called infectious osteomyelitis almost from the reception of injury. The English term, "compound" comminuted fracture applied to open fractures of this kind, is scarcely descriptive, nor is infected comminuted fracture sufficient. "Infected pulpified fracture" might be a better term. Such injuries, whether

obtained in military service or otherwise, present far different problems from other complicated fractures.

Symptoms.—The symptoms of gunshot fracture are pain and shock. The former depends upon the site of fracture and of the wound of entrance, the sensitiveness of the individual, and the mental preoccupation of the patient at the time of injury. The shock varies

FIG. 897 a.—Gunshot fracture of the palate and the body of the sphenoid bones. Wound self-inflicted by a 32-calibre bullet, which passed through the palate bone and lodged in the body of the sphenoid bone. Patient recovered. Lateral view. (See Fig. 897.)

greatly with the site and seriousness of the fracture. In perforated fractures without comminution or loss of continuity of bone, diagnosis will depend upon the line of the bullet and the radiographic examination. In complete fractures there will be abnormal mobility of fragments and crepitus, which at times may be difficult to elicit on account of fragmentation and separation of the ends of the bone. In suspected fractures, radiograms in two planes should be taken.

Gunshot fractures depend upon the character of the projectiles. The modern service rifle has small calibre and projects a jacketed bullet of lessened diameter compared with the bullets formerly used. Thus the velocity of the projectile is increased, and its trajectory relatively flat, though the revolution of the projectile on its long axis is increased by reason of its length. The severity of the wound produced by this

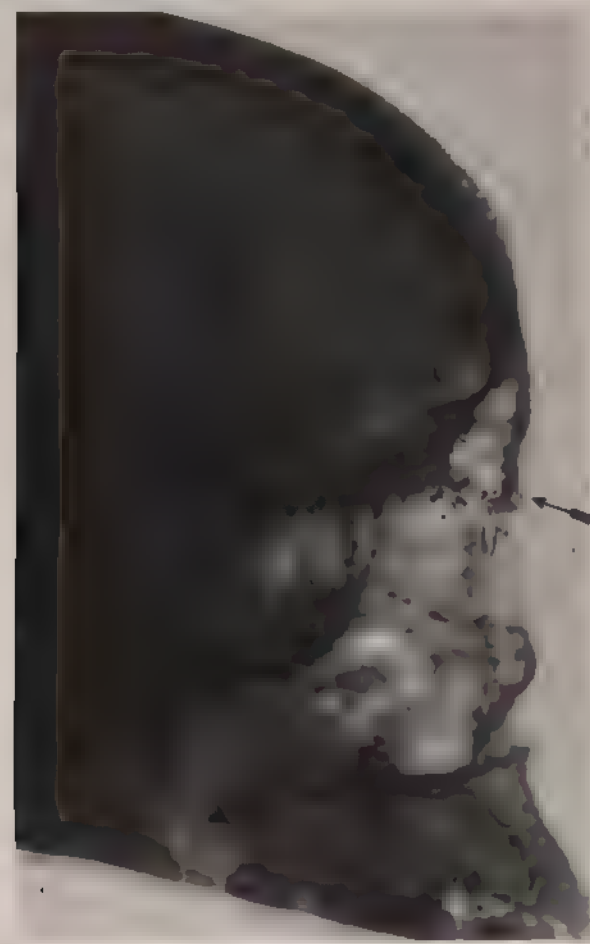

FIG. 897 b. Perforating gunshot fracture of the frontal and the nasal bones. Small fragments of lead may be seen imbedded.

bullet decreases in indirect proportion to the distance of the object struck from the muzzle of the rifle; that is, the greater the distance, the less the injury. The more pointed the bullet, the greater is its penetrating power, and its ability to perforate bone. Bullets of low velocity have less penetrating power than those of high velocity. Thus it is that less injury is done the greater the distance from the muzzle

of the rifle. Bullets of low velocity may lodge in the tissues without being deformed, because they have little penetrating power. A bullet which strikes an object before entering the skin may richochet and, being deformed by the first impact, will probably cause more damage than a bullet which has not richocheted. Soft spongy bone allows perforation by reason of its lessened resistance more readily than compact bone. The bullet track is like a hole bored in soft wood. Compact bone is more split up, and the broken particles, acting as secondary

FIG. 898.—Gunshot fracture of the mandible

missiles from assuming the unexpended velocity of the arrested projectile, greatly increase the explosive effect of the bullet.

The skin wound of entrance and that of the underlying soft parts may be trivial in appearance, while the bone itself is greatly damaged. The bone shattered into fragments may greatly lacerate the soft tissues near it, especially on the side opposite the point of impact. This corresponds with the usual well known smaller wound of entrance of bullets of low velocity and the greater size of the wound of exit. A

missile travelling with great velocity and meeting little resistance makes a narrow track with small entrance and small exit wound with little deflection within the tissue.

The experience of military surgeons with rifle wounds such as have just been described proves that the jacketed small calibre bullets

FIG. 899.—Gunshot fracture of the left humerus. The bullet is lodged in the axilla.

of high velocity cause less dangerous wounds, though they temporarily
he soldier. Smokeless powder is said to add to the humanity
wounds from small arms.
ions.—The complications of gunshot fractures are in-
injury to blood-vessels, nerves, tendons, or muscles, or
al or distal viscera. In pulpified and comminuted

fractures infection with pyogenic, gas bacillus and tetanus germs is frequent in war zones.

The modern change in shape of bullets has influenced the character of the wound in bones as well as soft parts. Soft lead bullets, and even hardened lead bullets which are jacketed, are liable to change shape when striking the bone and therefore, whether deflected or perforating, do more damage to hard and soft tissues. Bullets composed of a single piece suffer less change from contact with hard structures. This change in shape, when it occurs, gives rise to more splinters, a

FIG. 900.—Gunshot fracture of the humerus; note butterfly type of fracture and fragmentation of the bullet.

larger wound of the soft parts and bone, and by making the fragments of bone secondary missiles, enlarges the wound of exit more than would otherwise be the case.

The extensive comminution of gunshot fractures which occurs especially in shafts is a complication of less moment than might be expected, provided no primary infection occurs from particles of clothing entering the wound, and the wounds of entrance and exit are protected from admitting infection from without. Primary hemorrhage, due to the fracturing missile, may be serious from injury to large vessels. The present opinion appears to be that attempts on the part of the

soldier himself or non-medical attendants to apply constrictive apparatus to stop hemorrhage is unwise. The danger of unnecessarily severe pressure causing distal gangrene is great. This is seen also in civil practice from tourniquets and constriction with rubber or cotton bandaging for open fractures and other wounds complicated by bleeding. It would be well if non-medical attendants giving first aid remembered that stopping bleeding from a blood-vessel is usually as easy as stopping water escaping from a punctured hose. Slight continuous pressure with the finger or a pad on the opening, or broad circular constriction of moderate amount with any bandage-like material about three inches wide is usually sufficient. Gangrene from unwise pressure to stop bleeding often occurs in open comminuted fractures due to gunshot or industrial accidents. Amputation would often be less extensive, or avoidable, if such pressure were omitted.

FIG. 901.—Gunshot fracture of the carpus.

In gunshot wounds, civil and military, tetanus is a not uncommon complication. Trench fighting and soiled hands make infection from its anaërobic bacillus in the ground an easy matter. Immediate treatment with full doses of anti-tetanus serum is a wise precaution. Small pistols used by boys for celebrating holidays have been accountable for many deaths from tetanus in America. Sailors' open fractures are said to be less frequently infected than soldiers. The less tendency to be contaminated with soil and by filthy contacts is evidently the reason for sailors' immunity.

Prognosis.—Unless complications of a grave character occur, the prognosis as to life is good. Union usually is slow, and there is a large mass of callus found where there are many fragments. Consolidation requires a long time, if there be infection. Cure may be accompanied by shortening, some angulation of fragments, and persistent sinuses with necrosis of fragments. These incidents depend largely upon the occurrence of infection or of unrelieved muscular displacement from spasm.

Infection of the wound occurs in the majority of gunshot fractures in civil life. This is said to be unusual in military life where small jacketed bullets of high velocity are used. First aid aseptic dressings

are often used by the wounded themselves in time of war. Infection is due to the septic missile, the introduction of foreign bodies with the bullet, such as portions of the clothing, or is carried in from the skin. Death is common in infected shot fractures from osteomyelitis. Especially is this true in the pulpified fractures due to large shot, shell fragments and shrapnel. Exposure after injury, delay in first aid, careless and ignorant dressing and hasty operative treatment add to the fatalities in war times.

Small pointed bullets, by causing small entrance wounds, relatively less danger of infection and less movement of fragments of clothing

FIG. 902. FIG. 903.

FIG. 902.—Gunshot fracture of the carpus.
FIG. 903.—Gunshot fracture of the proximal phalanx of middle finger.

within the tissues, and the adoption of antiseptic and aseptic methods of treatment have led to less morbidity, a lowered mortality and better end results in gunshot wounds of bone. Such rifle wounds often heal with little or no sepsis, and, though markedly comminuted, may be expected to act like closed fractures. The prognosis, however, is quite different in deflected and soft-nose bullet wounds of bone and in fractures from shell and similar projectiles. These often are followed by infection with local phlegmons and other septic and pyæmic results.

Gunshot fractures involving joints are particularly important because of secondary septic arthritis involving risk to joint function, and affording rapid absorption of toxic products. It is important that conservation of motion in a joint be thought of in fractures near

parts is infected. A general anæsthetic should as a rule be used. The part should be shaved and the skin thoroughly scrubbed with brush, soap and water, followed by alcohol, 70 per cent. If there is a wound of exit the tract of the bullet should be irrigated with official tincture of iodine, a dry sterile dressing applied, the fracture reduced, and the part immobilized in a gypsum case. The wound should never be explored unless there is considerable hemorrhage or evidence of injury to important nerve structures, in which case the wound of entrance



FIG. 905.—Aëroplane bracket splint for holding arm in abduction and forearm in extension, used in infected open fracture of humerus with much loss of bone. (Courtesy of Dr. R. B. Osgood.)

should be enlarged, after irrigation with tincture of iodine, all bleeding controlled with ligature, and tendons and nerves sutured with silk. If drainage is considered advisable, it should consist of folded rubber tissue, and under no consideration should gauze be used, as it simply acts as a plug, prevents drainage, and spreads infection. Amputation is seldom required in gunshot fractures in civil life. When disinfection of the wounded surface or the bullet track has been effected, the wound or wounds dressed, and replacement of fragments accomplished,

rigidity to the broken bone should be given by retentive appliances as in ordinary fractures, closed, open or infected.

LaGarde truly says that gunshot injuries are not a special department of surgery, but may be met by the civilian surgeon as well as his military colleague under similar circumstances, since the weapons used by the sportsman closely resemble those of the soldier. The open fractures of war, however, show more injury to the soft parts, more breaking up of bone, more inclusion of foreign bodies in the wound, and greater impairment of vitality of tissues from molecular concussion.

FIG. 906.—"Aeroplane" bracket splint to hold arm in abduction and forearm flexed in infected fractures of humerus, or of forearm or elbow injury (Courtesy of Dr. B. Osgood.)

While it is true that rifle wounds differ from those received from artillery, and that men fighting in trenches are more subject to contamination from necessarily filthy habits and contact with the earth (perhaps under manurial cultivation for years), the underlying surgical principles involved are the same as those of industrial and other accidental injuries to bone. Some of the differences in the present war, recorded by surgical officers, may undoubtedly be attributed to the circumstance that the young surgeon of the twentieth century has gained his experience almost exclusively in what may be called Listerian surgery. The survivors of the old regime will doubtless recognize and understand, perhaps to the profit of their soldier patients, the necessity for drainage by gravity, frequent and copious dressings, and abundant irrigation in the treatment of the foul wounds and fractures now met on the firing line and at the base hospital.

Non-contaminated fractures should be managed by the prompt application of the first-aid dressing of the soldier and no attempt should be made to investigate the wound of entrance or exit with finger or probe. Fixation by some external immobilizing dressing should be used and transportation provided as promptly as possible. The upper extremity may usually be immobilized temporarily by using the thorax for support. The lower extremity may often be similarly steadied by using the opposite leg as a splint. These methods of temporary character apply to both military and non-military accidents. Foreign

bodies driven into the wound by the projectile should not be searched for on the firing line nor at the seat of accident, but allowed to remain until suitable time and care can be given to the study of the injury, and suitable fixation apparatus and definite treatment made available.

Delorme, speaking of the expediency of extracting a metallic foreign body, holds that those causing neither uneasiness nor pain should as a rule be let alone particularly at the beginning of treatment, because extraction may greatly protract operation. If, however, it is badly tolerated or lies in contact with vessels or nerves or is situated in a focus of suppuration, it should be removed. A bullet that is discovered lying beneath the skin may be taken out, if aseptic precautions may be obtained.

A shell fragment that is large, irregular and sharp and also a shrapnel bullet, according to Delorme, must always be removed shortly after the injury. This in war should be done in a permanent shelter



FIG. 907.—Gypsum encasement with basket braces of wire and gypsum-gauze for immobilization of infected open and comminuted fractures, in which the knee is to be kept extended. Used for fractures of femur or of tibia and fibula. (Courtesy of Dr. R. B. Osgood.)

either at the front or in the rear of the fighting line. His reason given for this peremptory rule is that shrapnel wounds are so frequently complicated by foreign bodies carried in from the clothing. After removal of the metal the bottom of the wound should be methodically explored for materials carried in by the missile.

It will be seen by these statements that there is a distinct difference between the aseptic open fractures caused by small calibre encased bullets and those due to hardened shrapnel bullets or irregular pieces of metal. The latter are accompanied by much more laceration and are pretty sure to be infected, as are wounds received from any sort of projectiles obtained during trench life.

The danger comes from the septic contamination giving rise, in pulpified and comminuted bone, to an infectious osteomyelitis, which overshadows the loss of continuity and rigidity in the bone. After a patient with a gunshot wound has been transported to a base hospital, or brought out of the woods where he has been hunting, to a fairly equipped modern hospital, the problem is the same. The temporary

immobilization is to be substituted by reduction, which previously need not be insisted upon, and by permanent immobilization.

In non-infected gunshot fractures, the treatment is practically the same as in ordinary subcutaneous fractures or open fractures which have been preserved from becoming infected.

In infected fractures, comminuted or otherwise complicated, the treatment is the same whether the injury be received in military or non-military life.

In the severe open comminuted fractures with crushed tissues which above have been called "infected pulpified fractures," the treatment is the same for a man brought from filthy trenches with crushed limbs as it is for a man who has been wounded by a railroad train, a machinery crush, or the explosion of nitroglycerin or other such agents of modern industry.

FIG. 908. Tibia and fibula, upper extremities of right. Gunshot fracture of the tibia. A battered conoidal ball impacted. The ball struck a little below the tubercle of the tibia on the fibular side where it is seen imbedded. Vertical lines of fracture pass down the fibular side of the shaft. Intermediate amputation at lower third of thigh. (Mütter Museum, No. 1442.01.)

These observations mean that early in the case occlusion of wounds to prevent infection, the use of tetanus antitoxin, prompt and efficient morphia administration and the use of remedies for shock are essential. At first temporary immobilization with any rigid material or with gypsum gauze splints, if there be time and conveniences, and careful transportation are required. Later, ordinary surgical principles combined with experience in the treatment of desperate infections will meet the indications of those cases, in which are met the burrowing abscesses, the absorption of pyogenic toxins, and the other results of septic or true pyæmic infection.

Dr. R. B. Osgood, of Boston, lays stress on the need of frequent, copious dressings and constant efficient drainage in the severe comminuted infected bone injuries. He employed in the French hospital service what he terms "aeroplane" splints for the upper and "basket" splints of gypsum gauze and wire for the lower limb.

The "lymph lavage" of Almroth Wright with hypertonic solution of 0.5 per cent. sodium citrate and 5 per cent. solution of salt, as a cleanser of wounds, and the coincident use of vaccine treatment may perhaps equal or exceed the value of the older methods of treating virulent bone infections. Time only will settle the question.

Antiseptic solution, powders and oils now being employed by Cheyne, Carrel and others may prove efficient. It is, however, not

likely that these will take the place of free incisions with trephining and splitting open the bone for evacuating purulent and other septic cavities, removal of saturated dressing every 2 or 3 hours, irrigations and gravity drainage. These old reliances of pre-Listerian surgery will probably keep their hold on those surgeons who have seen their efficiency. Indeed it is not improbable that the worst crushed fracture may be well treated with constant immersion in baths of pure water or mild antiseptic lotions after the manner of treating amputation wounds employed by F. H. Hamilton years ago.

FIG. 909.—Basket plastic splint with steel bones arranged for immobilization with extended knee and some traction on fracture. Applied to infected comminuted fracture of bones of leg. (Courtesy of Dr. R. B. Osgood.)

Amputations and joint resections would doubtless be rare in gunshot fractures if the injured could have immediate attention at the hands of experienced surgeons and be given transportation of a proper kind and efficient after-treatment. Operative fixation with Hey Groves's bolting apparatus might save the limb in bad comminutions; and other less complicated direct fixations will often be of service. Bone grafting will at times be a means of restoring function lost by the injury. When circumstances furnish a reasonable change, it is well to defer mutilating operations for gunshot fractures.

INDEX

Adhesive plaster dressing for maintaining Jones' position, 346
Albee, F. H., method in the treatment of fractures, 109
instruments used, 110
technic of using inlay bone grafts in fresh fractures, 111
technic of using inlay bone graft in ununited fractures, 112
Albee's method of bone inlay in treatment of non-impacted fractures of the neck of the femur, 480
Allis's method of determining shortening in fracture of neck of femur, 460
Ambulatory treatment of fractures, 83
advantages, 83
disadvantages, 83
American Surgical Association,quoted; conclusions in the operative treatment of fractures, 114, 115
Anæsthesia in the reduction of fragments, 59
cocaine, novocaine, 60
ether, 60
nitrous oxide gas and oxygen, 60
Anæsthesia in reduction of elbow fractures, 341
Anæsthesia in reduction of fractures at lower end of radius, 407
Ankylosis, secondary, following fractures of lower end of humerus, 342
Arteries and veins, injury to, in fractures, 28
Artery, middle meningeal, 117
Artery and vein, popliteal, injury to, in fractures of lower end of femur, 515
Ashhurst, A. P. C., quoted; end-results in fractures of lower end of humerus, 350
Ashhurst, A. P. C., quoted nerve, median injury in fractures of lower end of humerus, 340
Astragalus, 601
etiology, 601
prognosis, 602
results, 605
symptoms, 602
treatment, 602
varieties, 601

Bardenheuer's method of extension, 73
principles involved, 73
advantages, 74
disadvantages, 75
Bardenheuer, quoted; statistics on clavicle fracture, 264
Barton bandage, 201
Barton's fracture, 392
Barton's, reversed fracture, 393
Battle, quoted; mortality of skull fractures, 157
Bayonet deformity in fractures at lower end of radius, 404
Beds, fracture, 58
Bennett's fracture, 427
Berghausen, quoted; statistics on fractures of the vertebræ, 214
Bergmann, quoted; cerebrospinal fluid, amount, in basal fractures, 141
Bergmann, quoted; hypoglossal and spinal accessory nerves, injury in basal fractures, 144
Bergmann, quoted; eye changes in middle meningeal hemorrhage, 146
Bergmann, quoted; mortality of skull fractures, 158
Bergmann, quoted; operative mortality in middle meningeal hemorrhage, 167
Bladder and urethra, rupture of, in fractures of pelvis, symptoms of, 452
Bladder and urethra, injury to, in fractures of pelvis, 451
Blake, quoted; operative mortality in middle meningeal hemorrhage, 167
Bleichsteiner, quoted; statistics on fractures of mandible, 189
Birth fractures, 638
clavicle, 643
etiology, 643
treatment, 643
femur, 643
etiology, 643
symptoms, 644
treatment, 645
humerus, 639
deformity, 639
etiology, 639
statistics, 639
symptoms, 639
treatment, 639
skull, 638
etiology, 638
symptoms, 638
treatment, 638
operative, 639

Bowen, quoted; operative mortality in intracranial hemorrhage, 170
Bradford frame, in treatment of fractures of femur, 505
British Medical Association, statistics of individual fractures as reported by committee of, showing results of operative and non-operative treatment, 53
British Medical Association, Fracture Committee, quoted; cause of failure in operative treatment, 114
British Medical Association, committee on fractures, quoted; results in the treatment of fractures of the shaft of the femur, 510
British Medical Association, committee on fractures, quoted; statistics of results in fractures of neck of femur, 480
British Medical Association, committee on fractures, quoted; results in the treatment of fractures of the tibia and fibula, 572
Broca and Mouchet, quoted; nerve injury in fractures of lower end of humerus, 340
Brown-Séquard, paralysis, in vertebral fractures, 240
Brun, Hans, quoted; skull fractures, 132
Bruns, quoted; showing liability of individual bones to fracture, 1
Bruns, quoted; results produced by pistol bullet, 130
Bruns, quoted; statistics, failure of union following fractures of humerus, 319
Bruns, quoted; nerve injuries complicating fractures, 314
  musculospiral, 314
  ulnar, 314
  radial, 314
Bryant's vertical extension, 75
Bryant's triangle, in determining fractures of the neck of the femur, 460
Buck's extension, 73
Buck's extensions in fractures of neck of femur, 477
Burkhard, quoted; mortality of skull fractures, 157
Burnham, A. C., quoted; mortality in skull fractures, 158
Burrell, quoted; mortality in vertebral fractures, 244

Calcaneum, 605
  etiology, 605
  prognosis, 614
  statistics, 607
  symptoms, 609
  treatment, 615
    non-operative, 615
    operative, 615
  varieties, 605
Cardiovascular changes, in fractures, 38
Carpal bones, etiology, 418
  statistics, 418
  surface markings, 418
  symptoms, 419
    cuneiform, 421
    scophoid, 419
    semilunar, 421
  treatment, 421
Carrying angle (Ashurst, quoted), 350
Cerebrospinal fluid, amount, in basal skull fractures, Bergmann, quoted, 141
Cerebrospinal fluid, amount of, in skull (basal) fractures, MacCormac, Sir W., quoted, 141
Cerebrospinal fluid in skull (basal) fractures, Phelps, quoted, 140
Chauffeurs' fracture, 397
Chipault, quoted; operative mortality in vertebral fractures, 245
Chudowsky, quoted; showing liability of individual bones to fracture, 1
Clavicle, 264
  anatomy, 264
  complications, 270
  etiology, 265
  prognosis, 271
  statistics, 264
    Freeman quoted, 264
  surface markings, 264
  symptoms, 265
    inner third, 269
    middle third, 266
    outer third, 267
  treatment, 271
    claviculo-humeral dressing, 275
    dorsal recumbency, 273
    operative, 276
    reduction in children, 271
    reduction in adults, 272
    Sayre dressing, 274
    summary of, 277
Clavicle, statistics on fracture of, Malgaigne, quoted, 264
Clavicle, statistics on, Pitha, quoted, 264
Codivilla's method of nail extension, 76
Coenen, quoted; nerve musculospiral injury in fractures of lower end of humerus, 340
Coler, quoted; explosive action upon brain by bullet, 130
Colles's fracture, 386, 387
Colles's reversed fracture, 390
Coma in head injuries, differential diagnosis from other forms of unconsciousness, 155
Complications of fractures, 28
  arteries and veins, injury to, 28
  cardiovascular, 38
  delirium, alcoholic, 37
  delirium, traumatic, 36
  dislocation, association of a, 34
  embolism, fat, 34
  infection, 35
  joints, injury to, 33
  lesions of soft parts, 28
  muscles, injury to, 31

Complications of fractures, nerves, injury to, 30
pulmonic, 37
shock and hemorrhage, 36
symptoms, 29
thrombosis and embolism, 35
treatment, 30
Concussion, cerebral, 148
etiology of, 148
symptoms of, 148
Contraindications to operative treatment in closed fractures, 87
those due to the fracture, 87
those dependent upon the patient's general condition, 87
those pertaining to the operator, 87
those relating to the environment, 87
Contusion, cerebral, 150
location of, 150
symptoms of, 152
Cortors, F., method of operative impaction of fragments in intercondylar fractures of femur, 516
Cotton's method of palpation of anterior surface of bodies of cervical vertebræ, 214
Cotton's method of operative impaction in treatment of non-impacted fractures of neck of femur, 479
Cotton's method of operative reduction of fractures of the calcaneum, 615
Coxa vara, traumatic, 481
Crandon and Wilson, quoted; hemorrhage and mortality in basal fractures, 139
Crandon and Wilson, quoted; cerebrospinal fluid in basal fractures, 140
Crandon and Wilson, quoted; mortality of skull fractures, 157
Craniocerebral localization, 119
Cranium (see skull), 116
Crepitus in fractures of neck of femur, 472
Cubitus valgus, 345, 350
Cubitus varus, 345, 350
Cullen, quoted; optic nerve injury in basal fractures, 142
Cuneiform, fractures of, 421
Cushing, quoted; location of injury in spinal cord lesions, 232
Cushing, quoted; operative mortality in middle meningeal hemorrhage, 167
Cryer's method of splinting mandibular fractures, 201

Decompression in fractures of skull, 161
Definitions, 1
Delatour, quoted; end-results in the operative treatment of fractures of the patella, 536
Delayed union, 26
Delirium, alcoholic, in fractures, 37
Delirium, traumatic, in fractures, 36
Delorme, quoted; treatment of imbedded particles in gunshot fractures, 659
Dejerine, quoted; relationship of segments of spinal cord and nerve roots to bodies and spines of vertebræ, 226, 230
Destot, Vignard and Barlatier, quoted; nerve injury in fractures of lower end of humerus, 340
Diagnosis, differential, 22; general, 21
Diaphysis and epiphysis, rules of bony union of, Gerrish, quoted, 39
Disability, average period of, in subcutaneous fractures as reported by the committee of the B. M. A., 56
Disability following fractures, Estes, W. L., quoted, 56
Diseases, constitutional, in the prevention of union, 107
Dislocation, adjacent, associated with a fracture, 34
Dislocation, definition, 1
Displacement of fragments, 16
absence of, 16
etiology of, 17
varieties of, 16
Duchain, quoted; operative mortality in middle meningeal hemorrhage, 167
Dwight, quoted; hemorrhage in basal fractures, 139
Dwight, quoted; hemorrhage from middle meningeal in skull fractures, 144

Eguchi, quoted; epilepsy, traumatic, following skull injuries, 158
Epiphyseal separations, 38
anatomy, 38
complications, 49
date of ossification and time of union with diaphysis, 39
diagnosis of, 49
etiology, 46
occurrence, 47
radiographic findings, 49
sequelæ, 49
symptoms, 48
treatment, 49
Epiphysis, separation of lower radial, 390
Epilepsy, traumatic, following skull injuries, Eguchi, quoted, 158
Estes, quoted; statistics showing period of disability in open fractures, 56
Etiology of fractures, 6
exciting causes, 7
predisposing causes, 6
Eversion and inversion in fractures of neck of femur, 471
Extension or traction dressings and methods, 73
Buck's extension, 73
Bardenheuer's method, 73
Bryant's method of vertical extension, 75
Steinmann's method of nail extension, 76
Codivilla's method of nail extension, 76
Zuppinger's method of extension, 78

Face, bones of, fractures of, 172
anatomy, 172
Fat embolism, 34
Femur, fractures of, 457
anatomy, 457
methods of determining shortening in fractures of neck of femur, 459, 460, 461
statistics, 462
surface markings, 459
upper end, 462
head, 462
etiology, 462
symptoms, 462
treatment, 462
neck, 463
diagnosis, 474
diagnosis, differential, 474
etiology, 464
prognosis, 475
symptoms, 469
treatment, 476
impacted fractures, 476
non-impacted, 476
Buck's extension, 477
traction and abduction, 477
Whitman's abduction, 477
Ruth-Maxwell, 478
Cotton's method, 479
Albee's bone inlay, 480
nailing, 479
after-results, 480
epiphysis, separation of upper, 481
diagnosis, 482
etiology, 481
symptoms, 481
treatment, 482
Whitman's abduction method, 482
trochanters, through the, 483
etiology, 483
lines of fracture, 483
symptoms, 483
treatment, 484
Buck's traction, 485
Whitman's method of abduction, 485
great trochanter, 485
etiology, 486
lines of fracture, 486
prognosis, 486
symptoms, 486
treatment, 486
lesser trochanter, 487
etiology, 487
symptoms, 487
treatment, 487
subtrochanteric region, 487
etiology, 487
prognosis, 488
symptoms, 487
treatment, 488
Zuppinger method, 489
Femur, fractures of,
surface markings,
shaft, 494
complications, 498
displacements, types of, 496
etiology, 495
prognosis, 499
results, 510
statistics, 494
symptoms, 495
treatment, 501
Buck's traction, 502
Christen's suspension, 509
gypsum dressing, 505
non-operative, 501
operative, 85
reduction, 502
Thomas knee-splint, 506
vertical traction, 507
lower end, 511
varieties, 511
supracondylar and intercondylar, 513
complications, 515
etiology, 513
prognosis, 515
symptoms, 515
treatment, 516
internal or external condyles, 516
etiology, 517
prognosis, 517
symptoms, 517
treatment, 517
epiphysis, separation of, 518
complications, 519
etiology, 518
prognosis, 519
symptoms, 518
treatment, 519
sprain-fractures, 520
etiology, 522
prognosis, 523
symptoms, 523
treatment, 523
types, 520
Femur, neck of, fractures of, in childhood, 463
Femur, neck of, statistics on, in childhood, Haldenwang, quoted, 463
Femur, supracondylar fracture, results in, Hennequin, quoted, 515
Femur, fractures of, summary of treatment, 523
Fibula, upper end, fractures of, 551
etiology, 551
symptoms, 553
treatment, 553
Fibula, shaft of, isolated fractures of, 575
etiology, 575
symptoms, 575
treatment, 575
Fleming, quoted; hemorrhage in basal fractures, 139
Fracture-box in treatment of fractures of bones of leg, 564

Freeman, quoted; statistics on fractures of clavicle, 264
Functional impairment and loss of earning capacity, 57
Functional results in relation to anatomical results, 61
Functional treatment of fractures, 82

Gangrene in fractures, 30
General considerations, 1
Gerrish, quoted; rules of bony union of the diaphysis and epiphysis, 39
Gibbs, quoted; statistics on fractures of hyoid, 205
Gunshot fractures, 8, 646
complications, 652
displacement of fragments, 647
prognosis, 654
shell and shrapnel injuries, 648
symptoms, 649
treatment, 656
types of fractures, 646
types of projectiles, 650
Gunshot fractures of skull, 127
lesion produced, 127, 130
skull, 129, 130
brain, 131
Gurlt, quoted: statistics on fractures of mandible, 189
statistics on fractures of hyoid, 205

Hanging, judicial, type of fracture of vertebræ in, Wood-Jones, quoted, 223
Hæmothorax in rib fractures, 260
Haenel (quoted by von Bergmann): results after malleolar fractures, 587
Haldenwang, quoted: statistics on fractures of the neck of the femur in childhood, 463
Hawley's traction table, 91
Heer, Anna, quoted; cerebrospinal fluid in basal fractures, 140
Heer, Anna, quoted; facial nerve injury in basal fractures, 143
Hemorrhage, intracranial, in fractures of the skull, 144
etiology, 144
source, 144
internal carotid, 147
intracranial sinuses, 146
middle meningeal, 144
amount, 144
blood-pressure changes, 145
diagnosis, 144
eye changes, 146
hæmatomas, resulting, 144
pulse changes, 145
respiratory changes, 146
mortality, operative, Bowen, quoted, 170
Hemorrhage, middle meningeal, 144
cause of death, 167
eye, changes in, Bergmann, quoted, 146
Krönlein's points of election for trephining, 145, 166
Hemorrhage, middle meningeal, mortality, operative, Bergmann, quoted, 167
mortality, operative, Blake, quoted, 167
operative mortality, Cushing, quoted, 167
operative mortality, Duchain, quoted, 167
in skull (basal) fractures, Dwight, quoted, 144
treatment of, 165
Hemorrhage, prearachnoid, 147
in fractures of skull, treatment of, 170
Hæmatomas in middle meningeal hemorrhage, Krönlein, quoted, 144
Hennequin, quoted; results in supracondylar fracture of the femur, 515
Hernia of the lung in rib fractures, 261
Hitzrot, quoted; results in fracture of head of radius, 381
results in fracture of neck of radius, 383
Hoffmann, quoted; mortality in fractures of cartilage of larynx and trachea, 210
statistics on fractures of cartilage of larynx and trachea, 208
Hoffmann and Lesser, quoted: statistics on fractures of cartilage of larynx and trachea, 209
Holder, quoted; injury to optic foramen in basal fractures, 142
Humerus, fractures of, 290
anatomy, 290
surface markings, 291
statistics, 292
upper end of humerus, 294
varieties, 294
head, 295
etiology, 295
symptoms, 295
treatment, 295
anatomical neck, 296
etiology, 296
symptoms, 296
diagnosis, 296
prognosis, 296
treatment, 296
tuberosities through, 297
etiology, 298
symptoms, 298
treatment, 298
tuberosity, isolated of greater, 299
etiology, 299
symptoms, 300
diagnosis, 300
treatment, 300
tuberosity, isolated of lesser, 300
symptoms, 300
diagnosis, 301
treatment, 301

of,
... of humerus,
...s,
epiphysis, separation of upper,
etiology, 301
symptoms, 301
diagnosis, 303
treatment, 305
after results, 305
surgical neck, 306
etiology, 307
symptoms, 308
diagnosis, 309
complications, 309
treatment, 309
after results, 312
shaft of humerus, 313
etiology, 313
symptoms, 313
diagnosis, 313
complications, 313
musculospiral nerve injury, 314
treatment, operative, 316
treatment, 316
after results 318
failure of union, 319
pseudarthrosis, 319
lower end of humerus, 319
etiology, 319
forms found in childhood, 319
forms found in adults, 319
varieties, 319
supracondylar, 322
statistics, 322
varieties, 322
symptoms, 323
diagnosis, 324
mechanism of fracture, 322
diacondylar, 324
mechanism of fracture, 324
symptoms, 324
diagnosis, 326
intercondylar, T, Y, or atypical, 326
etiology, 326
symptoms, 327
diagnosis, 327
epiphysis, separation of lower, 328
anatomy, 328
etiology, 328
symptoms, 328
diagnosis, 330
epicondyle, external, 331
etiology, 331
symptoms, 331
condyle, external, 331
etiology, 332
symptoms, 332
capitellum, 333
etiology, 333
symptoms, 333
epicondyle, internal, 334
etiology 334
symptoms, 335
diagnosis, 335

Humerus, fractures of,
lower end of humerus,
varieties,
condyle, internal, 335
statistics, 335
etiology, 336
symptoms, 336
diagnosis, 336
trochlea, 336
etiology, 338
symptoms, 338
complications of fr. lower end of humerus, 338
open fractures, 338
Volkmann's ischæmic contracture,338
blood-vessel injuries, 340
nerve injuries, 340
statistics, 340
treatment, 340
treatment, 340
anæsthesia, 341
ankylosis, 342
reduction, 342
hyperflexion and supination, 343
Jones' position, 343
right angle anterior splint, 344
cubitus varus, 345, 350
cubitus valgus, 345, 350
after results, 349
treatment, operative, 351
summary of treatment, 352
Hyoid, 205
anatomy, 205
complications, 206
diagnosis, 207
etiology 205
prognosis, 207
statistics, 205
surface markings, 205
symptoms, 206
treatment, 207
Hyoid, statistics on, Gibbs, quoted, 205
Gurlt, quoted, 205

Immelmann, quoted, liability of individual bones to fracture, 1
Immobilization temporary, of fragments, 58
Impairment of motions in fractures of neck of femur, 470
Indications for operative treatment, closed fractures, 86, 88
Infection in fractures, 28
in closed fractures, 35
in open treatment of closed fractures, 86
Infolding fracture of lower end of radius, 393
Internal carotid hemorrhage
Internal carotid, hemorr
skull fractures treatme
Intracranial sinuses hem
Intracranial sinuses, her
treatment of, 167

Intrapartum fractures, 11
Intrauterine fractures, 10
Inversion fracture of fifth metatarsal, 625
Ischæmic muscular atrophy, 31, 32
  etiology, 32
  symptoms, 32
  treatment, 33
    mechanical, after, 33
    operative, 33
    preventive, 33

Jensen, J., quoted; statistics on fractures of pelvis, 436
Joints, injury to neighboring, in fractures, 33
Jones, R., position in treatment of fractures of lower end of humerus, 343
  use of the Thomas knee splint in the treatment of fractures of the shaft of the femur, 506
  quoted; use of Thomas knee splint in treatment of fractures of lower end of femur, 516

Katzenelson, quoted: anatomy of pelvic archs in relation to lines of fracture, 438
Kocher, quoted: classification of vertebral fractures, 216
  location of fractures of bodies of vertebræ, 217
Kocher's classification of supracondylar fractures of humerus, 322
Kohler, quoted; facial nerve injury in basal fractures, 143
Kosmak's method of correction of depressed skull fractures, 638
Krönlein's points of election for trephining in middle meningeal hemorrhage, 145, 166
Krönlein, quoted; hæmatomas in middle meningeal hemorrhage, 144

La Garde, quoted: gunshot injuries, 658
Lane's plates in fractures, 96
  technic of application, 96
Larynx and trachea, cartilages of, 208
  anatomy, 208
  complications, 210
  etiology, 209
  prognosis, 210
  statistics, 208
  surface markings, 208
  symptoms, 209
  treatment, 210
Larynx and trachea, cartilages, mortality on, Hoffmann, quoted, 210
  statistics on, Hoffmann, quoted, 208
Lente, quoted; statistics on fracture of mandible, 189
Lerda and Quénu, quoted; use of cocaine and novocaine in reduction of fractures, 60
Ligament of the patella, rupture of, 539
  etiology, 539
  prognosis, 539
  symptoms, 539
  treatment, 539
Liston T-splint, 504
Lloyd, Samuel, quoted; operative mortality in vertebral fractures, 245
Lothrop's, H. A., method of reduction in depressed malar fractures, 183
Lowman's bone clamp, in fractures, 98
Lumbar puncture in fractures of skull, 161

MacCormac, Sir W., quoted: cerebrospinal fluid, amount, in basal fractures, 141
Makin's types of gunshot fractures, 646
Malar bone, 180
  anatomy, 180
  complications, 182
  diagnosis, 182
  methods of examination, 180
  prognosis, 183
  surface markings, 180
  symptoms, 182
  treatment, 183
  varieties of fracture, 180
Malgaigne, quoted: statistics on clavicle fractures, 264
Malgaigne, double vertical fracture of pelvis, 440
Malleolar fractures, results after, Haenel (quoted by v. Bergmann), 587
Mandible, 188
  anatomy, 188
  complications, 196
  diagnosis, 198
  etiology, 190
  methods of examination, 194
  prognosis, 199
  statistics, 188
    Gurlt, quoted, 189
    Lente, quoted, 189
  surface markings, 188
  symptoms, 194
  treatment, 199
    reduction of fragments, 200
    retention of fragments, 200
      external dressings, 201
      interdental splints, 202
      mandibulomaxillary splints, 203
      suture, wire, 204
Martin, E. A., quoted: rapid fall of blood-pressure in application of traction, 106
Massage and passive motion, in the treatment of fractures, 81
Matas' method of reduction of depressed fractures of zygomatic arch, 184
Maxilla, superior, 185
  anatomy, 185
  complications, 186
  diagnosis, 186
  methods of examination, 185
  prognosis, 187
  surface markings, 185
  symptoms, 186
  treatment, 187
  varieties, 185
Menard, quoted: statistics on fractures of the vertebræ, 214

tacarpal bones, 422
anatomy, 422
diagnosis, 428
etiology, 426
results, 430
statistics, 422
surface markings, 422
symptoms, 426
first metacarpal, 426
second to fifth metacarpals, 428
treatment, 429
Metatarsal bones, 622
anatomy, 622
etiology, 622
prognosis, 625
statistics, 622
surface markings, 622
symptoms, 622
treatment, 625
Middle meningeal, hemorrhage, 144
treatment of, 166
Muhlenberg and Berenger-Feraud, quoted: pseudarthrosis in fractures of mandible, 199
Muscular relaxation in fractures of neck of femur, 470
Muscular system, injury to, in fractures, 31

Nasal bones, 172
anatomy, 172
complications, 177
diagnosis, 176
displacement of fragments, 174
etiology, 174
methods of examination, 176
prognosis, 177
symptoms, 176
treatment, 177
old unreduced fractures, 179
recent fractures, 178
varieties, 174
Nerve (abducens), injury in skull (basal) fractures, Schröder, quoted, 143
Nerves, cranial, involved, in basal fractures, 142
anterior fossa, 142
middle fossa, 142
posterior fossa, 143
Nerve (facial), injury, in skull (basal) fractures, Heer, Anna, quoted, 143
Nerve (facial), injury, in skull (basal) fractures, Kohler, quoted, 143
Nerve, hypoglossal, injury in skull (basal) fractures, Stierlein, quoted, 144
Nerves, hypoglossal and spinal accessory, injury to, in basal skull fractures, v. Bergmann, quoted, 144
Nerve, median, injury of, in fractures of lower end of humerus, Ashhurst, A. P. C., quoted, 340
Nerve, musculospiral, injury, in fractures of lower end of humerus,
Nerve, musculospiral, injury, in fractures of shaft of humerus, 314
Nerve, musculospiral paralysis, 314
primary paralysis, 314
intermediate paralysis, 314
secondary paralysis, 314
reactions of degeneration, 315
treatment, 316
operative, 316
Nerve (optic), injury, in basal skull fractures, Cullen, quoted, 142
Nerve, popliteal, injury to, in fractures of the lower end of femur, 515
Nerves, injury to, in fractures, 30
Nerve injuries complicating fractures, 314
musculospiral, 314
radial, 314
ulnar, 314
Nerve injury complicating fractures of the lower end of humerus, 340
statistics, 340
treatment, 340
Nerve injury, in fractures of lower end of the humerus, Destot, Vignard and Barlatier, quoted, 340
Nerve injury, in fractures of lower end of the humerus, Broca and Mouchet, quoted, 340
Nerve, injury to, in fracture of pelvis, 452
Nichols, E. H., quoted: hemorrhage from middle meningeal in skull fractures, 144
Non-union, 27
in fractures of mandible, Norris, quoted, 199
Norris, quoted: non-union in fractures of mandible, 199

Oliver, J. C., quoted: mortality in vertebral fractures, 245
Open (compound) fractures, 79
treatment of, 79
types of, 79
conservative treatment, 79
wisdom of primary suture or plating of fragments, 80
Operative procedures for fractures of vault of skull, 162
Osgood, quoted: treatment of gunshot fractures, 660
Optic foramen, injury to, in skull (basal) fractures, Holder, quoted, 142

Paralysis, Brown-Séquard, in vertebral fractures, 240
Paralysis, motor, in vertebral fractures, 228
sensory, in vertebral fractures, 230
Passive motion, in fractures about elbow, 347
Patella, 525
anatomy, 525
diagnosis, 530
diagnosis, differential, 530

Patella, etiology, 525
prognosis, 530
statistics, 525
surface markings, 525
symptoms, 529
treatment, 531
non-operative, 532
operative, 532
results, 535
results, end, 536
varieties and mechanisms, 528
rupture of quadriceps, extensor tendon of, 537
rupture of patella ligament, 539
Patella, ligament of, rupture of, 539
etiology, 539
prognosis, 539
symptoms, 539
treatment, 539
Patella, refracture of, 536
Patella, results of operative treatment, Delatour, quoted, 536
Patella, results after treatment, Quinby, W. C., quoted, 535
Patella, old fracture of, 536
Pathologic fractures, 9
aneurysms, 10
inflammatory processes, 9
new growths, 10
resulting from a general disease, 10
Pelvic arches, anatomy of in relation to lines of fracture, Katzenelson, quoted, 438
Pelvis, 435
anatomy, 435
character of fracture, 437
complications, 451
injury to bladder and urethra, 451, 452
injury to blood-vessels, 452
injury to nerves, 452
etiology, 437
prognosis, 454
statistics, 436
surface markings, 435
symptoms, 447
treatment, 455
of the complications, 455
of the fracture, 455
varieties of fracture, 439–445
Pelvis, statistics on fractures of, Jensen, J., quoted, 436
Phalanges of foot, 629
etiology, 629
symptoms, 629
treatment, 629
Phalanges of hand, 431
anatomy, 431
diagnosis, 433
etiology, 431
statistics, 431
symptoms, 431
treatment, 433
results, 434
Phelps, quoted: cerebrospinal fluid in basal fractures, 140
Pia-arachnoid hemorrhage, in fractures of skull, treatment of, 170
Pitha, quoted; statistics on clavicle fractures, 264
Plagemann, quoted; liability of individual bones to fracture, 1
Pneumothorax, in rib fractures, 260
Posture in bed, in vertebral fractures, 227
Pott's fracture, 578
Prearachnoid hemorrhage, 147
Priapism, in vertebral fractures, 236
Prognosis, general, in fractures, 51
Pseudarthrosis in fractures of mandible, Muhlenberg and Berenger-Feraud, quoted, 199
in fractures of neck of femur, 475
following fractures of shaft of humerus, 316
Pulmonic complications in fractures, 37

Quadriceps extensor tendon of patella, rupture of, 537
etiology, 537
prognosis, 538
symptoms, 537
treatment, 539
Quinby, W. C., quoted; operative and non-operative results in the treatment of fractures of the patella, 535

Radiographic examination as a guide in treatment, 57
epiphyseal separations, 49
Radius and ulna, 353
anatomy, 353
statistics, 355
surface markings, 355
upper end, 356
Radius and ulna, combined, 356
complications, 360
diagnosis, 360
displacements, 358
etiology, 356
results, 363
statistics, 356
symptoms, 359
treatment, 360
non-operative, 360
operative, 363
ulna, isolated fractures of, 364
statistics, 364
olecranon process, 364
displacements, 365
etiology, 364
results, 370
symptoms, 367
treatment, 368
non-operative, 368
operative, 370
coronoid process, 371
displacements, 373
etiology, 371
mechanism, 372
results, 374
symptoms, 373
treatment, 373

Radius and ulna,
ulna, shaft of, 374
displacements, 375
etiology, 374
symptoms, 375
treatment, 375
radius, isolated fractures of, 376
statistics, 376
head of radius, 377
displacements, 378
etiology, 377
results, 380
symptoms, 379
treatment, 379
non-operative, 379
operative, 379
epiphysis, separation of upper, 381
epiphysis, fracture of upper, 381
neck of radius, 382
displacements, 382
etiology, 382
results, 383
symptoms, 382
treatment, 382
radius, shaft of, 383
displacements, 383
etiology, 383
symptoms, 384
treatment, 385
radius, lower end, 386
diagnosis, 402
diagnosis, differential, 405
etiology, 386
results, 414
statistics, 386
symptoms, 397
treatment, 407
anæsthesia, 407
reduction, 407
retention, 408
splints, 408–412
after treatment, 413
summary of treatment, 415
varieties of fracture, 387
Radius, head of, results in fracture of, Hitzrot, quoted, 381
neck of, results in fracture of, Hitzrot, quoted, 383
Rawling, quoted; cerebrospinal fluid in basal fractures, 140
deductions in head injuries from temperature changes, 149
escape of brain tissue in basal fractures, 141
eye changes in middle meningeal hemorrhage, 146
hemorrhage from middle meningeal in skull fractures, 144
mortality of skull fractures, 157
mortality of skull fractures in relation to temperature changes, 158
Rawling's rules as to the probable line of transbasal fracture, 134
Reduction of fragments, 58
anæsthesia, 58, 60
obstacles to reduction, 60
methods of reduction, 60
non-operative, 60
operative, 60
time of reduction, 60
Reflexes, disturbance of, governing bladder and rectum, in vertebral fractures, 235
in vertebral fractures, 233
Reid's base line, 119
Relationship to age, sex, and season, 6
Remer, quoted; statistics on fractures of cartilages of larynx and trachea, 209
Repair of fractures, 23
in recent closed fractures, 23
in recent open fractures, 25
in recent closed fractures treated by aseptic operation, 25
Results in fractures of lower end of humerus, Ashhurst, A. P. C., quoted, 350
Results in treatment of fractures of neck of femur, British Medical Association, fracture committee, quoted, 488
Results in treatment of fractures of shaft of the femur, British Medical Association, fracture committee, quoted, 510
Results in treatment of fractures of tibia and fibula, British Medical Association, fracture committee, quoted, 572
Retention of fragments, 61
temporary dressings, 62
permanent dressings, 62
Retentive dressings in fractures, 62
fixation dressings, 62
traction dressings, 62
fixation and traction dressings, 63
Retentive dressings, rules to be observed in the application of, 63
Reversed Barton's fracture, 392
Reversed Colles's fracture, 390
Ribs and costal cartilages, 255
anatomy, 256
statistics, 256
surface markings, 256
ribs, 256
complications, 258
intrathoracic, 258
intraabdominal, 261
diagnosis, 261
etiology, 256
pathology, 256
prognosis, 262
symptoms, 257
treatment, 262
varieties, 256
costal cartilages, 263
diagnosis, 263
etiology, 263
prognosis, 263
symptoms, 263
treatment, 263

Röntgen rays in diagnosis of fractures, 22
in diagnosis and treatment, 85
Roser-Nélaton line in determining fractures of the neck of the femur, 459
Ruth-Maxwell method in treatment of fractures of neck of femur, 478

Sayre dressing, 274
Scaphoid, carpal, fractures of, 419
Scaphoid (tarsal), 616
etiology, 616
prognosis, 621
symptoms, 618
treatment, 621
Scapula, fractures of, 278
anatomy, 278
surface markings, 278
statistics, 278
body of scapula, 279
etiology, 279
prognosis, 280
symptoms, 279
treatment, 281
varieties, 279
superior angle of scapula, 281
etiology, 281
symptoms, 282
treatment, 282
varieties, 282
inferior angle of scapula, 282
etiology, 282
symptoms, 282
treatment, 283
spine of scapula, 283
etiology, 283
symptoms, 284
treatment, 284
varieties, 284
acromion process of scapula, 284
etiology, 284
prognosis, 285
symptoms, 285
treatment, 285
varieties, 284
neck of scapula, 285
diagnosis, 287
etiology, 286
symptoms, 286
treatment, 287
varieties, 285
coracoid process of scapula, 287
etiology, 287
symptoms, 288
treatment, 288
varieties, 288
rim of glenoid cavity of scapula, 288
etiology, 288
symptoms, 289
treatment, 289
varieties, 289
Schröder, quoted: abducens nerve injury in basal fracture, 143
Semilunar, fracture of, 421
Sesamoid (small) bones, 631
Sesamoid, anatomy, 631
etiology, 636
statistics, 633
symptoms, 637
treatment, 637
Sherman's plates in fractures, 96
screws, 98
Shepherd's fracture, 633
Shock and hemorrhage in fractures, 36
Shortening in fractures of the neck of the femur, 472
methods of determining shortening, 472
Silver-fork deformity in fractures at lower end of radius, 397
Skull, 116
anatomy, 116
base of skull, divisions, 119
craneocerebral localization, 119
density and rigidity of skull, 120
fissures, 118
landmarks, 116
diagnosis, 155
diagnosis, differential, 156
etiology, 121
general considerations, 116
cerebral contusion, 150
symptoms, 152
hemorrhage, intracranial, 144
amount, 144
diagnosis, 144
etiology, 144
source, 144
injury to brain, 147
cerebral concussion, 148
symptoms, 148
temperature changes, 148
mechanism of fracture at base, 132
Aran's theory of irradiation, 133
bursting theory, 133
contrecoup theory, 134
Rawling's theory of direct violence, 134
mechanism of fracture at vault, 132
mortality, 157
prognosis, 156
symptoms of fracture at base, 138
brain tissue, 141
cerebrospinal fluid, 140
cranial nerves, 142
emphysema, 141
hemorrhage, 138
anterior fossa, 138
middle fossa, 139
posterior fossa, 139
symptoms of fracture of vault, 137
temperature changes, 148
Skull, fractures of,
treatment, 159
general, 159
decompression, 161
lumbar puncture, 161
venesection, 160

Skull, fractures of the vault, 161
operative procedures for, 162
fractures of the base, 165
intracranial hemorrhage, 166
middle meningeal, 166
intracranial sinuses, 167
internal carotid, 170
pia-arachnoid, 170
types of fracture, 121
Skull fractures, Brun (Hans), quoted, 132
Skull (basal) fractures, cerebrospinal fluid in, Crandon and Wilson 140
Heer, Anna, quoted, 140
Skull fractures, depressed, Kosmak's method of correction of, 638
Skull injuries, epilepsy, traumatic following, Eguchi, quoted, 158
Skull (basal) fractures, hemorrhage in, Dwight, quoted, 139
Skull (basal) fractures, hemorrhage in, Fleming, quoted, 139
Skull (basal) fractures, hemorrhage and mortality in, Crandon and Wilson, quoted, 139
Skull fractures, mortality of, Battle, quoted, 157
Bergmann, quoted, 158
Burkhard, quoted, 157
Burnham, A. C., quoted, 158
Crandon and Wilson, quoted, 157
mortality in relation to temperature changes, Rawling, quoted, 158
Smith's fracture, 390
Soft parts, injury to, overlying, in fractures, 28
Spinal cord lesions, location of injury, Cushing, quoted, 232
Spinal cord segments and their nerve roots, relationship of, to the bodies and spines of the vertebræ, Dejerine, quoted, 226, 230
Sprain-fracture, lower end of radius, 395
Splint, right angle anterior, in treatment of fractures of lower end of humerus, 344
Splints, angle, 187
Hammond, 187
Gunning, 187
Goffre and Gräfe, 187
Splints, Cabot's posterior wire, use of, in fractures of bones of leg, 565
Splints, finger, 434
Splints, Lewis metal chin, 201
angle, 202
Cryer, 201
Gunning, for mandible fractures, 201
Hammond, 202
Hern, for mandible fractures, 201
Hohl, 202
interdental splints, 202
Martin, 202
Sauer, 202
Schauber, 202
Splints, metal, 64
aluminum, 64
wire, 64
wire gauze, 64
tin, perforated, 64
zinc, perforated, 64
Spints, moulded, 65
celluloid, 65
felt, poroplastic, 65
leather, 65
Splints, nasal, 179
Splints, plaster-of-Paris, 65
advantages of, 72
encasements, 65
for fracture of clavicle, 66
for fractures of upper extremity, 67, 68
for fractures of lower extremity, 69–71
for shoulder cap, 66
method of using, 68
moulded "contour," 65
use in open fractures, 72
Velpeau dressing, 66
Splints, pillow and side, in treatment of fractures of bones of leg, 564
Splints, types of, 64
Splints, use of gypsum case in treatment of fractures of bones of leg, 564
Splints, wood, 64
Sprain, definition, 1
Sprain-fracture, 1
of lower end of radius, 395
Statistics, general, 52
birth fractures, Truesdell, E. S., quoted, 638, 639
Chudowsky, quoted; skull fractures, 121
clavicle, 264
humerus, 292
radius and ulna, 355
ribs, 256
scapula, 278
sternum, fractures, 251
failure of union following fractures of humerus, Bruns, quoted, 319
Immelmann, quoted; clavicle fractures, 264
humerus, 292
scapula, 278
radius and ulna, 355
of British Medical Association, fracture committee, results of operative and non-operative treatment, 53
on fractures of clavicle, Bardenheuer, quoted, 264
on fractures of mandible, Bleichsteiner, quoted, 189
on fractures of the vertebræ, Berghausen, quoted, 214
on open fractures, showing period of disability, 56
121
Plagemann, quoted; skull fractures,

Statistics, Plagemann quoted,
calcaneum, 607
carpal bones, 418
clavicle, 264
femur, 462, 494
humerus, 292
metacarpal bones, 422
metatarsals, 622
patella, 525
pelvis, 436
phalanges of hand, 431
radius, lower end, 386
radius and ulna, 355, 356
radius, 376
radius, shaft, 383
ribs, 256
scapula, 278
shaft, 555
sternum, 251
tarsal bones, 601
tibia and fibula, upper end, 542
tibia shaft, isolated, 572
tibia and fibula, lower end, supramalleolar, 575
ulna, 364
showing liability of individual bones to fracture, 1
sesamoid (small) bones, Fawcett, quoted, 633
Geist, quoted, 633
Pfitzner, quoted, 634
Bruns, quoted, skull fractures, 121
clavicle, 264
humerus, 292
radius and ulna, 355
ribs, 256
scapula, 278
sternum fractures, 251
Steinmann's method of nail extension, 76
modifications of method, 76
value of method, 76
disadvantages of method, 77
technic of applications, 77
Sternum, 252
anatomy, 251
complications, 253
diagnosis, 253
etiology, 251
prognosis, 253
statistics, 251
surface markings, 251
symptoms, 252
treatment, 254
varieties, 252
Stierlein, quoted; hypoglossal nerve injury in basal fractures, 144
Stimson, quoted; statistics on fractures of cartilages of larynx and trachea, 209
Symptomatology, general, 17
constitutional, 21
objective, 18
subjective, 20

Tarsal bones, 599
anatomy, 599
statistics, 601
Tarsal bones, surface markings, 600
astragalus, 601
etiology, 601
prognosis, 602
results, 605
symptoms, 602
treatment, 602
varieties, 601
calcaneum, 605
etiology, 605
prognosis, 614
statistics, 607
symptoms, 609
treatment, 615
non-operative, 615
operative, 615
varieties, 605
scaphoid, 616
etiology, 616
prognosis, 621
symptoms, 618
treatment, 621
Temperature changes in head injuries, 148
Tendon of quadriceps extensor, rupture of, 537
etiology, 537
prognosis, 538
symptoms, 537
treatment, 539
Thrombosis and embolism, in fractures, 35
Thomas, T. T., quoted: results in fractures of head of radius, 380
Thorburn, quoted; operative mortality in vertebral fractures, 245
Tibia, avulsion of tubercle, 553
anatomy, 553
etiology, 553
symptoms, 553
treatment, 554
Tibia, and fibula, fractures of, 540
anatomy, 540
surface markings, 541
statistics, 542
TIBIA AND FIBULA:
lower end, fibular malleolus, isolated, 595
etiology, 595
prognosis, 596
symptoms, 596
treatment, 596
fibular malleolus and posterior articular edge of tibia, 588
etiology, 588
mechanism, 588
prognosis, 589
symptoms, 589
treatment, 590
fibula and external articular edge of tibia, 590
etiology, 590
mechanism, 590
prognosis, 590
symptoms, 590
treatment, 590

ND FIBULA:
er end, internal malleolus
ated, 594
etiology, 594
prognosis, 595
symptoms, 594
treatment, 595
malleolar, Pott's, 578
displacements, 580
etiology, 578
mechanism, 580
prognosis, 584
results, 587
symptoms, 581
treatment, 584
Pott's, inverted, 591
etiology, 591
mechanism, 591
prognosis, 593
symptoms, 591
treatment, 593
supramalleolar, 575
diagnosis, 576
etiology, 576
prognosis, 576
statistics, 575
symptoms, 576
treatment, 576
tibia, anterior articular edge, 596
etiology, 596
symptoms, 596
treatment, 596
shaft, 555
complications, 562
displacements, 559
etiology, 555
prognosis, 562
results, 572
statistics, 555
symptoms, 561
treatment, 563
non-operative, 564
operative, 565
open fractures, 568
upper end, 543
complications, 551
etiology, 548
prognosis, 550
symptoms, 544
adults, 544
children, 550
treatment, 551
varieties, 543
treatment, summary of, 598
lower end, 598
shaft, 598
upper end, 598
Tibia, shaft of, isolated of, 573
etiology, 573
statistics, 573
symptoms, 573
treatment, 573
Traction, longitudinal, in marked abduction in fractures of neck of femur, 477
Traumatic asphyxia in rib fractures, 261
Treatment, ambulatory, of fractures, 83
functional, of fractures, 82
general considerations, 56
operative, cases designated for, 87
Albee's inlay bone graft, 109
instruments used, 110
technic, 111
American Surgical Association, quoted; conclusions in the, 114, 115
cause of failures of, quoted from
cal Association, fracture committee, quoted, 114
cause of failures of, quoted from fracture committee of the B. M. A., 114
Treatment, operative, conclusions of American Surgical Association, quoted, 114, 115
contraindications to, 87
importance of external splinting, 109
indications that call for, 88
of closed fractures, 85
time of operation, 89
in recent closed fractures, 89
in fractures impossible of retention, 89
in non-union, deficient union, or faulty union, 90
technic of operation in closed fractures, 91
repair without internal fixation, 93
repair with internal fixation, 93
Trophic and vasomotor disturbances in vertebral fractures, 236

Union, delayed, 26
vicious, 27
non-, 27
Uterine fractures, 10

Varieties of fractures, 11
in relation to condition of surrounding soft parts, 11
in relation to degree, 11
in relation to direction and character of lines of fracture, 12
in relation to epiphyseal lines, 15
in relation to neighboring joints, 14
in relation to number of fragments, 15
in relation to position of the fracture, 14
Velpeau dressing for fractures of clavicle, 275
Venesection, in fractures of skull, 160
Vertebræ, 212
anatomy, 212
diagnosis, 243
etiology, 215
prognosis, 244
statistics, 214, 244
surface markings, 214

Vertebræ, symptoms,
those associated with the fracture, 225
those due to injury to spinal cord and nerve roots, 227
posture in bed, 227
paralysis, motor, 228
paralysis, sensory, 230
reflex disturbances, 233
trophic and vasomotor disturbances, 236
lesions of various segments, 238
hemorrhage in dura and spinal cord, 242
treatment,
non-operative, 246
in absence of injury to spinal cord, 246
in presence of injury to spinal cord, 246
care of bladder and rectum, 247
operative, 247
indications, contraindications, 247
lammectomy, technic, 248
postoperative, 250
varieties, 216
Vertebræ, fractures, disturbances of reflexes governing bladder and rectum, 235
mortality in fractures of, Oliver, J. C., quoted, 245
mortality, operative, in fractures of, Lloyd, Samuel, quoted, 245
operative mortality in fractures of, Thornburn, quoted, 245
statistics on fractures of, Menard, quoted, 214
Vertebral fractures, mortality in, Burrell, quoted, 244
mortality in, Chipault, quoted, 245
Vicious union, 27
Volkmann's contracture, 31, 32
(See ischæmic-muscular atrophy)
Volkmann's ischæmic contracture, 338
etiology, 338
pathology, 338
symptoms, 339
treatment, 340
Vogt's rule, for trephining points in middle meningeal hemorrhage, 166

Wagner, quoted; mortality of skull fractures, 158
Weight-bearing after fractures of tibia and fibula, 565
Wendt, quoted; statistics on supracondylar fractures of humerus, 322
Whitman's method of abduction in the treatment of separation of the upper femoral epiphysis, 482
Whitman's method of abduction in fracture of neck of femur, 477
principles and mode of application, 478
Wiesmann, quoted; operative mortality in middle meningeal hemorrhage, 167
Wood-Jones, quoted; type of fractures of vertebræ in judicial hanging, 223
Wright, Almroth, quoted; use of hypertonic sodium citrate solution, in gunshot injuries, 660
Wrist-drop, musculospiral nerve injury complicating fracture of shaft of humerus, 314
Wyeth's method of suture for fracture of patella, 535

Zuppinger's apparatus in the treatment of fractures of tibia and fibula, 565
Zuppinger's method of extension, 78
principles of method, 78
disadvantages of method, 79
Zuppinger's modified method in the treatment of subtrochanteric fractures, 489

LANE MEDICAL LIBRARY

To avoid fine, this book should be returned on or before the date last stamped below.

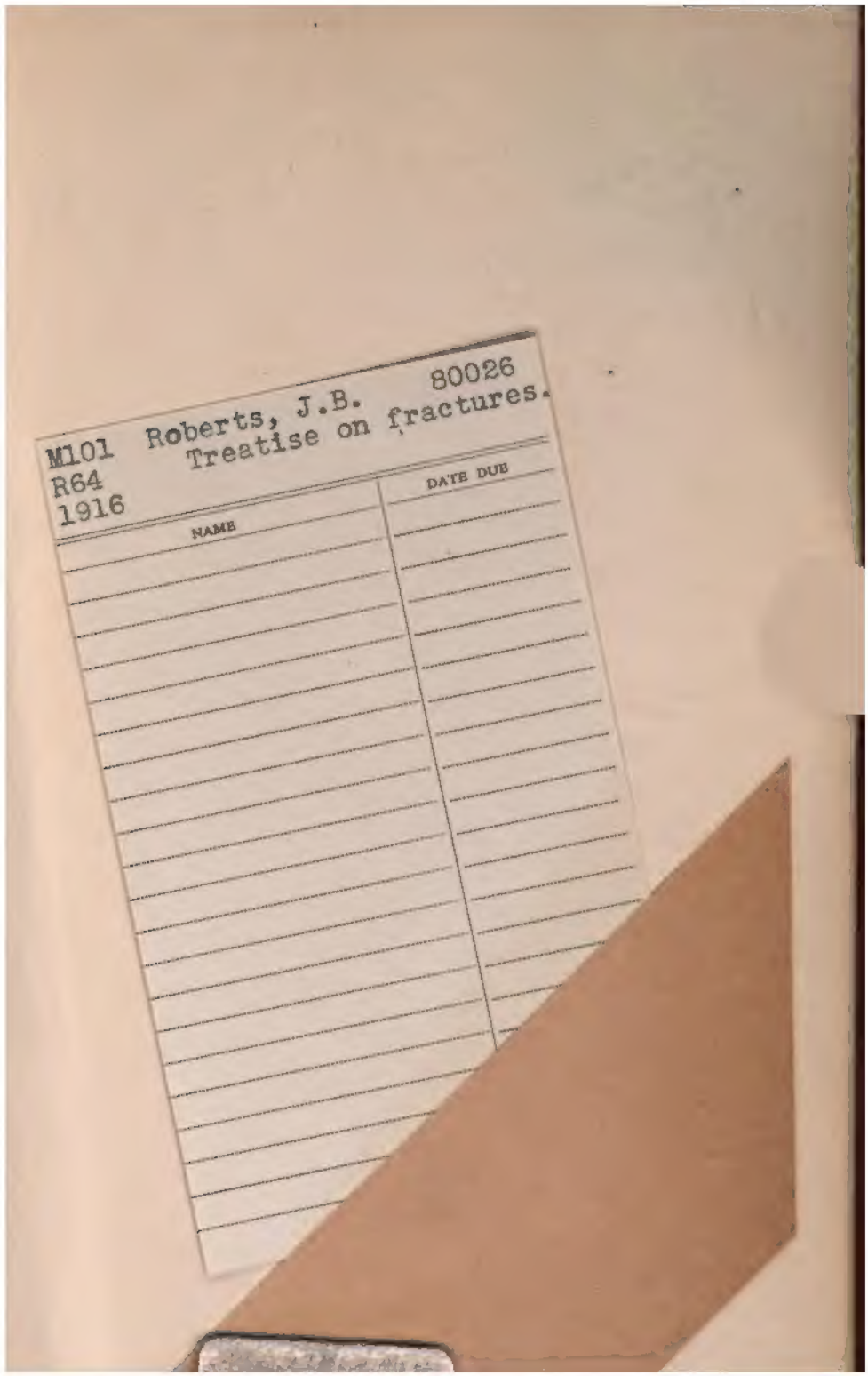
M101
R64
1916
Roberts, J.B.
Treatise on fractures.
80026
NAME
DATE DUE